

## CASE REPORT

# Traumatic avulsion of the tricuspid valve after gas bottle explosion

Francesca Tedoldi<sup>1</sup>, Maximilian Krisper<sup>2</sup>, Clemens Köhncke<sup>2</sup> and Burkert Pieske<sup>2,3</sup>

<sup>1</sup>Universita degli Studi di Verona, UOC Cardiologia OCM Borgo Trento, Verona, Italy

<sup>2</sup>Charite Universitätsmedizin Berlin, Medizinische Klinik m.S. Kardiologie, Berlin, Germany

<sup>3</sup>Deutsches Herzzentrum Berlin, Klinik für Kardiologie, Berlin, Germany

Correspondence should be addressed to F Tedoldi  
**Email**  
[francescated@yahoo.it](mailto:francescated@yahoo.it)

## Summary

We present a very rare example of chronic right heart failure caused by torrent tricuspid regurgitation. Massive right heart dilatation and severe tricuspid regurgitation due to avulsion of the tricuspid valve apparatus occurred as a result of a blunt chest trauma following the explosion of a gas bottle 20 years before admission, when the patient was a young man in Vietnam. After this incident, the patient went through a phase of severe illness, which can retrospectively be identified as an acute right heart decompensation with malaise, ankle edema, and dyspnea. Blunt chest trauma caused by explosives leading to valvular dysfunction has not been reported in the literature so far. It is remarkable that the patient not only survived this trauma, but had been managing his chronic heart failure well without medication for over 20 years.

## Learning points:

- Thorough clinical and physical examination remains the key to identifying patients with relevant valvulopathies.
- With good acoustic windows, TTE is superior to TEE in visualizing the right heart.
- Traumatic avulsion of valve apparatus is a rare but potentially life-threatening complication of blunt chest trauma and must be actively sought for. Transthoracic echocardiography remains the method of choice in these patients.

## Background

Physicians should be aware of cardiac valve lesions following chest blunt trauma, especially because tricuspid valve lesions may sometimes have an insidious onset of symptoms. All patients sustaining major chest trauma should undergo echocardiographic evaluation and follow-up, which is important because other chest wall injuries (e.g., hemothorax with drainage insertion) may result in initially poor echocardiographic windows, and hence non-diagnostic initial transthoracic echocardiography (TTE). The patient should be advised to return to the hospital if symptoms of palpitation, dyspnea on effort, or fatigue become evident.

## Case presentation

A 40-year-old Vietnamese male was referred to the emergency room because of a worsening of dyspnea and chest pain along the costal arch bilaterally for 3 weeks. In the weeks before admission, the patient had progressively gained up to 10kg in weight, had lost appetite, and had developed a yellowish skin color. The patient reported dyspnea class III according to the New York Heart Association (NYHA) classification and presented with lower extremity edema. To date, the patient had been in good health. The patient was admitted to the internal medicine ward.

## Investigation

On physical examination, the patient showed sub-jaundice, a prominent cardiac apex beat shifted to the right and an important bilateral pulsating jugular distension. A 3/6 holo-systolic murmur was heard on both sides of the sternum, and on palpation, hepatomegaly was detected.

The ECG showed atrial fibrillation with a rate of 90bpm. Vital parameters were within normal limits: blood pressure was 100/80mmHg, oxygen saturation was 97%, although the patient was breathing ambient air.

Blood analysis showed polycythemia (Hb 18.9g/dL, hematocrit 55%) and discretely elevated transaminase and index of cholestasis (alanine aminotransferase (ALT) 68U/L, aspartate aminotransferase (AST) 73U/L, gamma-glutamyl transpeptidase (GGT) 250U/L and alkaline phosphatase 240U/L). Apart from these results, laboratory findings were unremarkable.

Transthoracic echocardiography showed a massive dilation of the right heart chambers and a severe tricuspid regurgitation. In three-dimensional echocardiography, flail of posterior and septal leaflets could be well appreciated with prolapse of the thickened and shortened leaflet remainder into the right atrium. Consequently, the valve showed a coaptation deficit

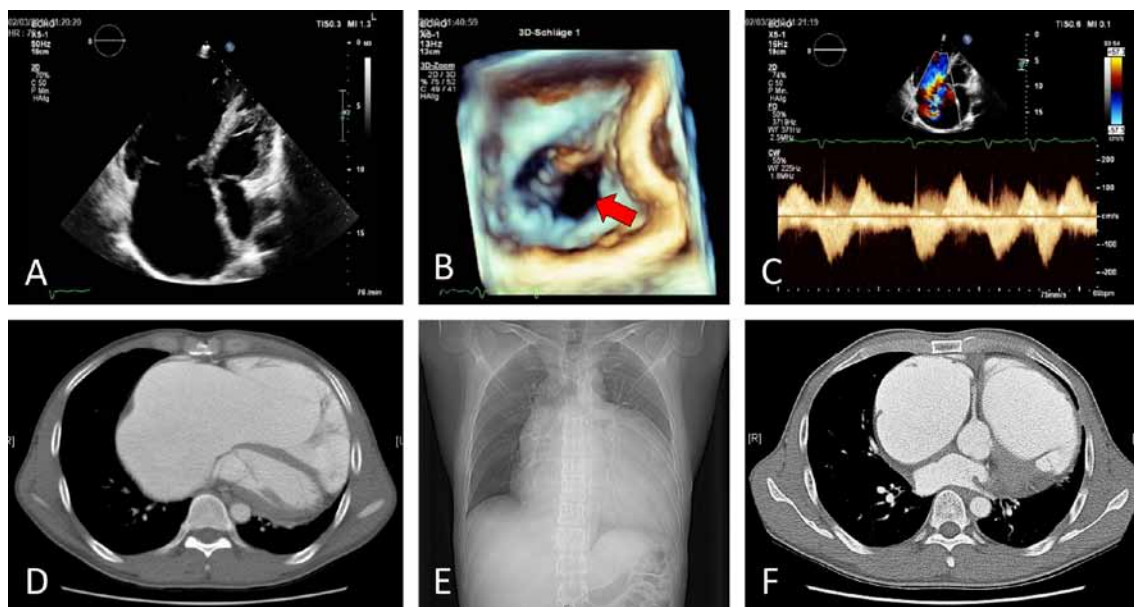
and severe torrent regurgitation. Pulmonic valve function was normal. Pulmonary artery pressure (PAP) measurement was not creditable because of the massive regurgitation, with a typically intense triangular-shaped continuous Doppler signal. All these findings were compatible with an avulsion of the tricuspid valve. The paradoxical septum movement and D-sign were noted, and the right ventricular free wall showed hypertrophy of 7–8mm. The ejection fraction of the left ventricle was reduced (LVEF 40%) with global hypokinesia.

A CT scan of the thorax was performed to rule out pulmonary embolism. Right heart dilatation was impressively confirmed; hepatic veins were distended with signs of contrast stasis due to right ventricular failure.

A transesophageal echocardiography was also performed, confirming the TTE findings. No interatrial or interventricular septal defects were found, ruling out relevant shunt.

Coronary angiography revealed normal coronary arteries. On angiography, left ventricular function was shown to be moderately impaired, with cardiac output decreased at 1.6L/min.

During clinical examination, a round scar on the patient's chest was noticed. When questioned, the patient recounted a heavy blunt chest trauma following the



**Figure 1**

(A) Apical four-chamber view demonstrating dilatation of right ventricular chambers and showing prolapse of septal and anterior tricuspid leaflets. (B) Three-dimensional image from the apical perspective showing the coaptation deficit and defect in the area of the septal leaflet (arrow). (C) Continuous-wave Doppler of tricuspid valve demonstrating low-amplitude triangular flow signals characteristic of severe regurgitation. (D) CT scan illustrating massive dilatation of right-sided heart chambers, with prominent right ventricular trabeculation. (E) Chest radiograph illustrating enlargement of the heart shape. (F) CT scan with origin of right coronary artery between enlarged right atrium and ventricle; pulmonary embolism was ruled out.

explosion of a gas bottle 20 years ago. At that time, he had been working with gas bottles in Vietnam. When he accidentally dropped one of the bottles he was carrying, it exploded and smashed into his chest. Thereafter, the patient went through a phase of illness with chest pain, shortness of breath, and edema. Interestingly, these symptoms resolved completely over time.

This story is highly suggestive of traumatic avulsion of the tricuspid valve apparatus with consecutive acute right heart decompensation.

We presume that in the following two decades, the patient developed high-grade right ventricular dysfunction and dilatation due to torrent tricuspid regurgitation. Left ventricular impairment as a consequence of chronic right heart failure may have accelerated symptom onset.

## Treatment and outcome

The patient was started on metoprolol and ramipril and received i.v. diuretics. Symptoms improved rapidly so that the patient could be discharged and under regular follow-up in the cardiologic outpatient clinic. The patient is currently undergoing evaluation for heart transplantation.

## Discussion

Injuries of the cardiac valves because of blunt chest trauma are relatively rare. There are few cases reported in the literature, many of them being related to a car or motor vehicle accident (1, 2). As the right ventricle is situated just behind the sternum, it has a predisposition to an anteroposterior compression injury. A sudden increase in right ventricle pressure during the end diastolic phase causes serious traction on both the valvular and subvalvular apparatuses. Traumatic tricuspid insufficiency may be easily tolerated for a long time, but sometimes it requires urgent intervention (3). Usually, the anterior papillary muscle is damaged following blunt cardiac trauma; however, in this case, septal and posterior leaflets had suffered the most damage. The clinical presentation depends on the type of injury. Subvalvular apparatus injuries, such as the rupture of papillary muscles and chordae tendineae, become symptomatic quickly. Alternatively, valvular damage, for example, a torn leaflet, may have a delayed onset of symptoms. Published descriptions of traumatic tricuspid valve rupture range from acute presentation to diagnoses that were made some 25 years after the incident (4).

TTE is fundamental to diagnosis when conducted by an experienced physician. Three-dimensional TTE and three-dimensional transesophageal echocardiography (TEE) may provide beneficial information on the anatomy of the valve, thanks to their better anatomic and spatial resolutions (5) (Fig. 1, Videos 1, 2 and 3).

### Video 1

Apical four-chamber view showing massive right heart dilatation and coaptation deficit of the prolapsing tricuspid leaflets; small left heart. View Video 1 at <http://movie-usa.glencoesoftware.com/video/10.1530/ERP-16-0014/video-1>.

### Video 2

Three-dimensional image demonstrating a view of the tricuspid valve as seen from the apex; near septum, a large coaptation defect representing the effective regurgitation area can be appreciated (arrow). View Video 2 at <http://movie-usa.glencoesoftware.com/video/10.1530/ERP-16-0014/video-2>.

### Video 3

Pulsating jugular veins, illustrating systolic backflow into the central veins due to severe tricuspid regurgitation. View Video 3 at <http://movie-usa.glencoesoftware.com/video/10.1530/ERP-16-0014/video-3>.

### Declaration of interest

The authors declare that there is no conflict of interest that could be perceived as prejudicing the impartiality of this case report.

### Funding

This research did not receive any specific grant from any funding agency in the public, commercial or not-for-profit sector.

### Patient consent

The patient gave his written informed consent for publication of the submitted article and accompanying images.

### Author contribution statement

F Tedoldi and M Krisper performed the echocardiographic examination, reviewed the original data, and wrote the manuscript; C Köhncke is responsible for the follow-up; B Pieske is the head of the Department of Cardiology (Charité University Clinic Berlin) and Director of the Department of Cardiology (Deutsches Herzzentrum Berlin).

---

## References

- 1 Aykut K, Kaya M & Acikel U 2013 Rupture of the tricuspid valve due to smashing the chest into the steering wheel. *Annals of Thoracic Cardiovascular Surgery* **19** 222–224. (doi:10.5761/atcs.cr.11.01857)
- 2 Khurana S, Puri R, Wong D, Dundon BK, Brown MA, Worthley MI & Worthley SG 2009 Latent tricuspid valve rupture after motor vehicle accident and routine echocardiography in all chest-wall traumas. *Texas Heart Institute Journal* **36** 615–617.
- 3 Katz NM & Pallas RS 1986 Traumatic rupture of the tricuspid valve: repair by chordae replacement and annuloplasty. *Journal of Thoracic Cardiovascular Surgery* **91** 310–314.
- 4 Mehrotra D, Dalley P & Mahon B 2012 Tricuspid valve avulsion after blunt chest trauma. *Texas Heart Institute Journal* **39** 668–670.
- 5 Acar B, Suleymanoglu M, Burak C, Demirkan BM, Guray Y, Tufekcioglu O & Aydogdu S 2015 Severe tricuspid regurgitation diagnosed 13 years after a car accident: a case report. *Journal of Tehran Heart Centre* **10** 50–52.

---

Received in final form 22 March 2016

Accepted 18 April 2016