



## Case Report

# Middle temporal vein access for transvenous embolization of cavernous sinus dural arteriovenous fistula: A case report and review of literature

Su-Chel Kim, Jae-Hyun Kim, Chang-Hyun Kim, Chang-Young Lee

Department of Neurosurgery, Keimyung University Dongsan Medical Center, Daegu, Korea

**J Cerebrovasc Endovasc Neurosurg.**  
**2022 March;24(1):44-50**

Received: 24 June 2021

Revised: 22 July 2021

Accepted: 3 August 2021

### Correspondence to Chang-Young Lee

Department of Neurosurgery, Keimyung  
University Dongsan Medical Center,  
1035 Dalgubeol-daero, Dalseo-gu,  
Daegu 42601, Korea

Tel +82-53-258-7846

Fax +82-53-258-4388

E-mail [nslyc@dsmc.or.kr](mailto:nslyc@dsmc.or.kr)

ORCID <https://orcid.org/0000-0001-6046-2571>

Transvenous endovascular treatment is the first choice for treating most cavernous sinus dural arteriovenous fistulas (CDAVFs). Among several available venous routes, the inferior petrosal sinus is the most commonly used. We report a case of CDAVF treated with endovascular treatment via the middle temporal vein (MTV). A 65-year-old man presented with unilateral chemosis and exophthalmos for approximately two months. Digital subtraction angiography showed a right CDAVF with predominant venous drainage toward the right superior ophthalmic vein. The superior ophthalmic vein primarily drained into the dilated MTV. Both sides of the inferior petrosal sinus were occluded; therefore, transvenous embolization was performed via the MTV route. The fistula was completely obliterated. The patient's symptoms improved and the postoperative course was uneventful. The transfemoral approach via the MTV to treat CDAVF provides a crucial alternative when other venous routes are difficult or impossible to navigate with a catheter.

**Keywords** Carotid-cavernous arteriovenous fistula, Cavernous sinus, Endovascular treatment, Middle temporal vein

## INTRODUCTION

Transvenous embolization is an effective treatment option for cavernous sinus dural arteriovenous fistulas (CDAVFs).<sup>1,3</sup> Inferior petrosal sinus (IPS) is the most commonly used venous route for the treatment; other routes include the superior ophthalmic vein (SOV), superior petrosal sinus, pterygoid venous plexus, inferior petrooccipital vein, and intercavernous connections.<sup>4</sup> In cases with IPS occlusion, other venous approaches should be attempted to access CDAVF. A few reports have suggested using the trans-facial vein approach or direct percutaneous transorbital puncture of the SOV or inferior ophthalmic vein.<sup>6</sup>

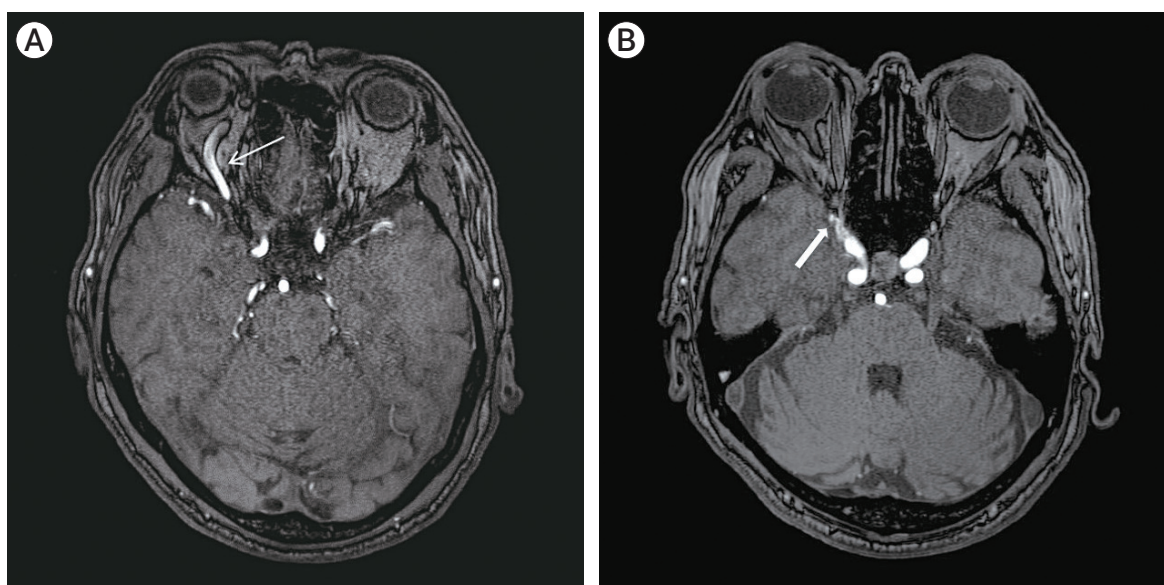
This is an Open Access article distributed under the terms of the Creative Commons Attribution Non-Commercial License (<http://creativecommons.org/licenses/by-nc/4.0/>) which permits unrestricted non-commercial use, distribution, and reproduction in any medium, provided the original work is properly cited.

In the case presented below, we adopted a rare transvenous approach to the CDAVF via the middle temporal vein (MTV) as IPS was not accessible.

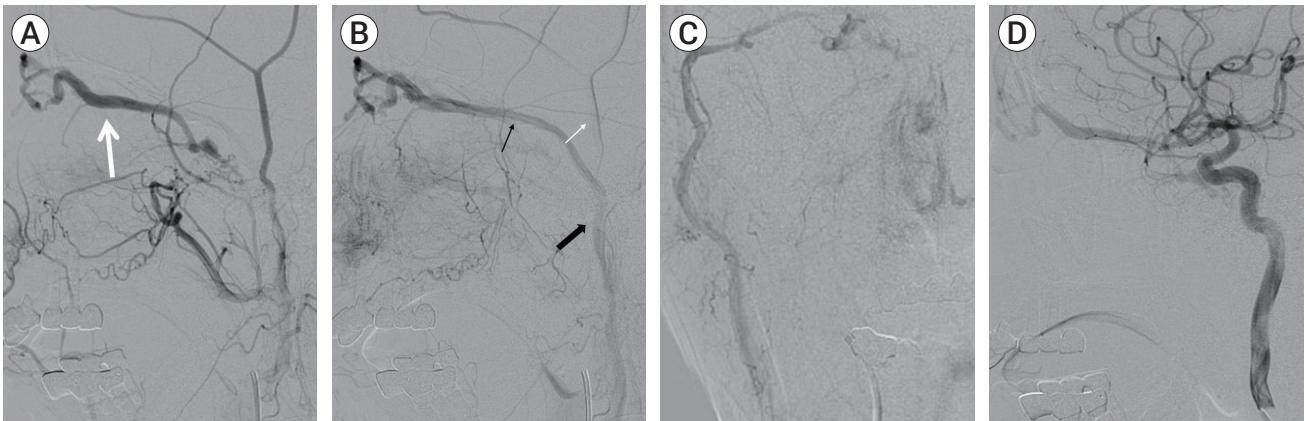
## DESCRIPTION OF CASE

A 65-year-old man presented with unilateral blurred vision in the right eye, chemosis, exophthalmos, and bruit for one month. There was no history of trauma, infection, or skull-base surgery. He visited the ophthalmology outpatient department and was treated conservatively; however, it was not effective. Magnetic resonance angiography (MRA) revealed a dilated SOV with prominent vascularity in the right anterior cavernous sinus region, suggesting CDAVF (Fig. 1). Digital subtraction angiography (DSA) confirmed the presence of CDAVF with prompt opacification of the SOV with venous reflux. Multiple arterial feeders supplied the CDAVF, including foramen rotundum artery through internal maxillary artery, and distal dural branch of the inferolateral trunk through internal carotid artery. CDAVF had predominant venous drainage toward the SOV, which drained into the MTV (Fig. 2). IPS, presumably thrombosed, was not observed. Although the angio-

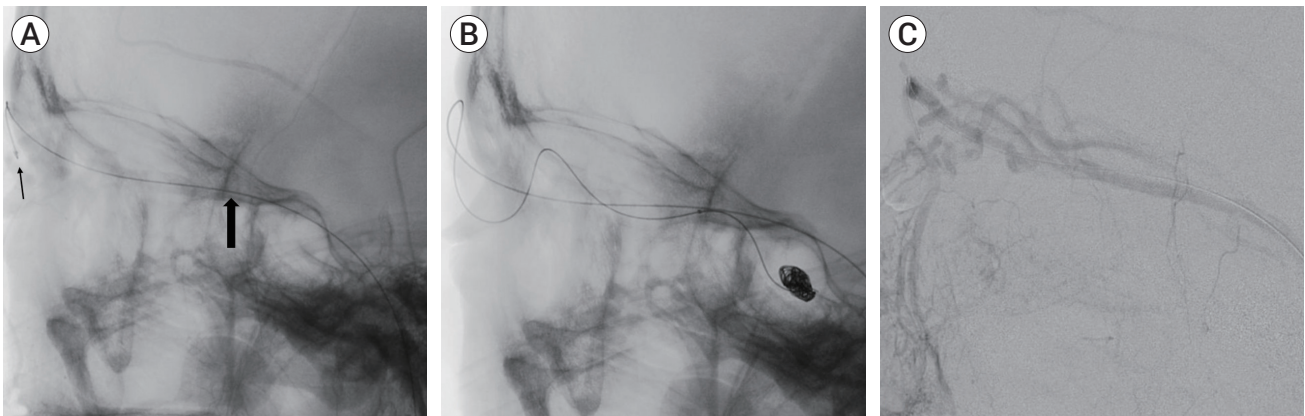
gram showed indirect CDAVF, the patient showed persistent blurred vision symptoms, and we decided to treat it through transvenous embolization. During the procedure, both the femoral artery and vein were punctured, a 5 F sheath was placed in the artery, and a 6 F sheath was placed in the femoral vein. And 6 F Envoy guiding catheter (Codman & Shurtleff, Rayham, MA, USA) was advanced to the external jugular vein just before the entrance of the retromandibular vein, thus microcatheter was accessed through the retromandibular vein. The headway 17 advanced microcatheter (MicroVention, Valencia Avenue Tustin, CA, USA) was placed at the distal MTV and advanced to the cavernous sinus via the nasofrontal vein and SOV (Fig. 3A). Then, it could finally enter the venous pouch of the arteriovenous fistula, which was completely obliterated with detachable coils packed within the venous pouch (Fig. 3B). After the endovascular treatment, DSA showed complete occlusion of the CDAVF (Fig. 4A). A detachable coil was observed on postoperative MRA near the right anterior cavernous sinus (Fig. 4B). The patient's symptoms improved, and the postoperative course was uneventful. Follow-up MRA obtained one year after treatment showed persistent occlusion of the arteriovenous fistula.



**Fig. 1.** Axial magnetic resonance angiography source image showing (A) superior ophthalmic vein dilatation (white arrow) with (B) prominent vascularity at the cavernous sinus (thick white arrow).



**Fig. 2.** Right cavernous sinus dural arteriovenous fistula in a 65-year-old man. (A) Lateral-view angiogram from the right external carotid artery, obtained before embolization, shows predominant venous drainage toward the superior ophthalmic vein (white arrow). (B) Lateral-view angiogram from the right external carotid artery shows middle temporal vein dilatation (thin black arrow), superficial temporal vein (white arrow), retromandibular vein (thick black arrow). (C) Anteroposterior-view angiogram of the right external carotid artery. (D) Lateral-view angiogram from the right internal carotid artery shows multiple arterial feeders.



**Fig. 3.** Lateral-view angiogram of the right external carotid artery showing transvenous embolization via the MTV vein route. (A) A microcatheter advanced into the MTV (thick black arrow) and shows gentle progression to the nasofrontal vein (black arrow). (B) During detachable coil packing at the cavernous sinus. Fistula was completely obliterated with the detachable coil. (C) Angiogram with advanced microcatheter via MTV. MTV, middle temporal vein.

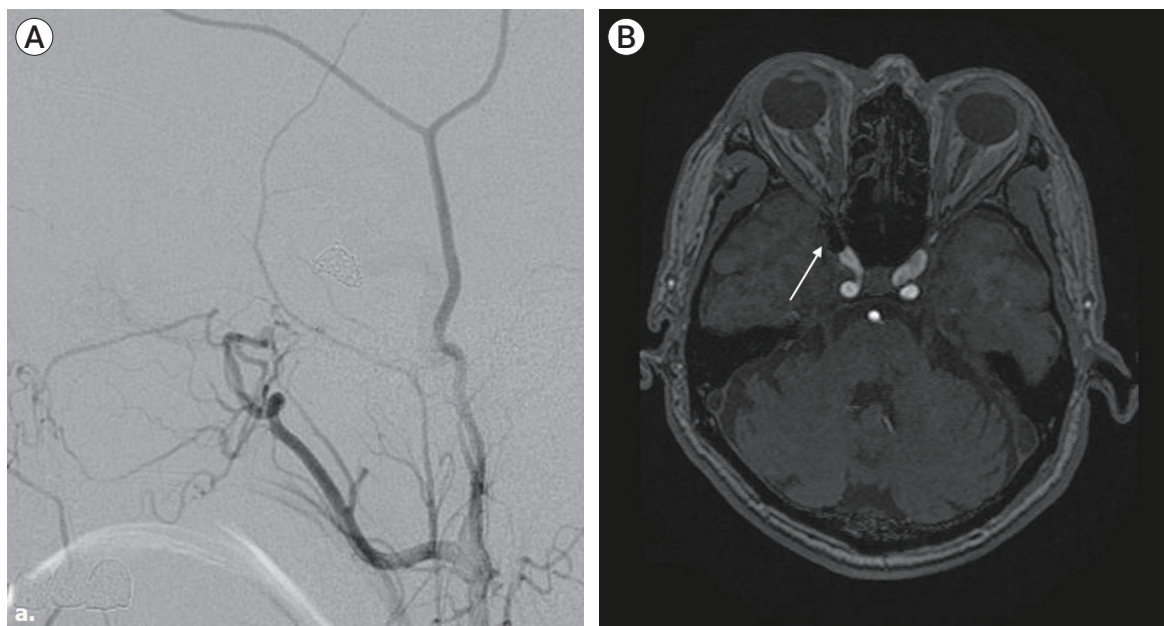
## DISCUSSION

We searched for literature using the PubMed database (until May 2021) to identify studies in humans that described an MTV approach to treat CDAVF and examined the clinical outcomes. To maximize search sensitivity and identify all relevant studies, combinations of terms, such as ‘MTV,’ ‘superficial temporal vein,’ ‘superior ophthalmic vein,’ ‘carotid cavernous fistula,’ ‘trans-venous approach,’ and ‘embolization’ were searched as either keywords or Medical Subject Headings (MeSH) terms. Furthermore, reference lists of all retrieved arti-

cles were reviewed to identify potentially relevant studies.

The articles identified were systematically assessed for inclusion in our review. Studies in which the patients had CDAVF and the treatment plan was transvenous embolization via a superficial middle temporal approach were included. Studies describing various transvenous approaches for CDAVF were included if the outcomes of the middle temporal approach group were reported separately. Reports describing transvenous approaches, including inter-cavernous, direct SOV, sphenoparietal sinus, superior petrosal sinus, and pterygoid plexus, were excluded. All the included publications were available in





**Fig. 4.** Postoperative digital subtraction angiography (DSA) and magnetic resonance angiography. (A) The final DSA shows complete occlusion of the cavernous sinus dural arteriovenous fistula. (B) Axial magnetic resonance angiography source image shows coil (white arrow) in the right anterior cavernous sinus area.

the English language.

A total of 75 articles were identified using the search criteria. After applying the eligibility criteria, eight studies were included in the final review (Table 1). Twenty patients underwent CDAVF treatment via a MTV approach. Overall, 23.6% of the patients were men, and the weighted average age of all patients was 58.1 years. The primary approach used for the MTV approach was transvenous embolization via the SOV, performed in 20 patients. The direct MTV approach was described in four cases, and all others used a transfemoral approach.

CDAVF is an abnormal communication between the cavernous sinus and the nearby arterial system.<sup>5)</sup> It is the most commonly involved site in intracranial dural arteriovenous fistulas.<sup>11)</sup> CDAVF has a wide variety of symptoms, depending on the route of venous drainage, pouch location, and size.<sup>20)</sup> Venous reflux into the ophthalmic vein can lead to orbital venous hypertension, resulting in increased intraocular pressure and intraorbital fluid retention. These abnormalities eventually lead to visual (e.g., diminished visual acuity and visual loss) and ocular (e.g., exophthalmos, proptosis, chemosis, subconjunctival hemorrhage, and corneal damage) symptoms.

Venous reflux into the IPS causes symptoms, such as tinnitus or bruit. Venous reflux into the middle cerebral vein can cause seizures or hemorrhage due to venous congestion and infarction. Cranial nerve deficits, such as ptosis, diplopia, anisocoria, and ophthalmoplegia, may occur due to the steal phenomenon of the nerve's vascular supply.<sup>16)</sup>

In CDAVF, invasive treatment can be considered when visual symptom degeneration or intolerable pain occurs.<sup>9)</sup> Various treatment modalities, including direct surgery, radiosurgery, and endovascular access (transarterial or transvenous embolization), have been proposed to treat this pathology.<sup>15)</sup> In patients with mild symptoms, conservative management and external manual carotid compression can be considered. Among these methods, transvenous embolization is now accepted as the first treatment for most symptomatic CDAVFs.

IPS, one of the most commonly used transvenous pathways for embolization, has the advantage of easy access to the cavernous sinus due to its short and straight course. However, if the cavernous sinus is not accessible through the IPS due to occlusion, thrombosis, anomaly, or cavernous sinus compartmentalization, other

**Table 1.** Summary of cases in which a MTV approach was used for endovascular management of carotid cavernous fistula

Article	Age/Sex	Symptom	No. of cases	Approach site	Post-op	Puncture site	Complications	Follow-up outcome
Komiyama et al. (1990) <sup>12)</sup>	49/F	Ocular symptoms, visual disturbance	1	EJV > RMV > MTV > SPOV > SOV > CS	Symptoms improved	Femoral vein	None	Complete (f/u 3 months)
Agid et al. (2004) <sup>1)</sup>	39/M	Ocular symptoms	1	IJV > common FV > RMV >> MTV > SPOV > SOV > CS With transarterial embolization	Symptoms improved	Femoral vein	None	Complete
Cheng et al. (2003) <sup>2)</sup>	48/F	Ocular symptoms	1	Common FV > RMV > MTV > SOV > CS	Completely resolved	Femoral vein	None	Complete
Matsubara et al. (2007) <sup>14)</sup>	60-78/ 2M, 2F	Ocular symptoms, visual disturbance	4	MTV > SPOV > SOV > CS	NR	Direct MTV	NR	1 case: complete Extra case: NR
Yu et al. (2007) <sup>22)</sup>	NA	Ocular symptom, visual symptoms	3	IJC > MTV > SOV > CS > EJV > MTV >> SOV > CS	Completely resolved	Femoral vein	NR	NR
Singh et al. (2009) <sup>19)</sup>	44/F	Headache, Ocular, visual symptoms	1	EJV > MTV >> nasofrontal vein > SOV > CS	NA	Femoral vein	NR	NR
Han et al. (2019) <sup>10)</sup>	55/F	Ocular, visual symptoms	1	MTV > SPOV > SOV > CS	Symptoms improved	Femoral vein	NR	Complete (f/u 8 months)
Shimizu et al. (2021) <sup>18)</sup>	37-73/ 1M, 7F	Ocular, visual symptoms	8	EJV or IJV > RMV > MTV > SPOV > CS	Symptoms improved	Femoral vein	NR	7 case: complete 1 case: subtotal occlusion

MTV, middle cerebral vein; SPOV, supraorbital vein; CS, cavernous sinus; EJV, external jugular vein; IJV, internal jugular vein; RMV, retromandibular vein; SOV, superior ophthalmic vein; FV, facial vein; NR, not recorded; M, Male; F, Female; f/u, follow up

pathways must be considered for CDAVF embolization. Several alternative venous routes are available: through the medial side of the lesion, the anterior or posterior intercavernous sinus can be attempted via the contralateral cavernous sinus; the passageway to the anterior side of the lesion through the SOV; the anterosuperior side, which can be accessed through the sphenoparietal sinus; the posterior side can be accessed through the superior petrosal sinus; and finally, the inferior side can be accessed through the pterygoid plexus.

The SOV, a frequently considered pathway when the IPS is occluded, can be accessed through the facial vein and has a high success rate.<sup>1)</sup> If the facial veins are not sufficiently dilated in the endovascular approach, a direct surgical approach to the SOV or inferior ophthalmic vein is possible.<sup>21)</sup> However, it can be tedious, difficult, and has potential complications, such as acute exophthalmos and subsequent visual loss.<sup>3)8)</sup> Therefore, even though it is a tortuous pathway, the approach through the surrounding venous channel (trans-femoral or peripheral approach) is preferred because it has the advan-

tage of being safe and having fewer side effects.

When an IPS approach is not available for the transvenous embolization treatment of a CDAVF, the use of the SOV via the MTV as an alternative route has rarely been reported (Table 1). It may be difficult to get through venous catheterization of the SOV via the MTV because of its narrow caliber, tortuous course, and formation of an acute angle at the junction of the MTV, nasofrontal vein, and SOV. However, a venous approach through this location was not impossible.<sup>7)</sup> We also had difficulties placing the catheter in the procedure, but could insert the guiding catheter by bending it into a J-shape and pushing it in gently. DSA often showed MTV dilatation and straightening; therefore, these venous channels provide an alternative route for transvenous embolization. Dilated MTV has been previously reported in other studies that treated CDAVF using the MTV approach.<sup>18)</sup> In CDAVF with characteristic retrograde venous drainage and ocular symptoms, MTV dilatation is frequently observed due to venous reflux and hypertension through the SOV.<sup>20)</sup> Therefore, the venous channel provide an

alternative route for transvenous embolization, and it is necessary to identify superficial middle temporal venous approach routes when planning endovascular treatment.

The veins that are located on the lateral aspect of the skull include the superficial temporal vein (STV), MTV, and transverse facial vein (TFV), which share the same running path as the artery with a similar name. MTV is the frontal branch of the STV and connect to the SOV through the nasofrontal vein and can access the cavernous sinus (Fig. 2B). It can be confused with the TFV, but TFV travels to the inferior border of zygoma, similar to transverse facial artery. The STV drains into the retro-mandibular vein and eventually flows into the common facial vein. The average MTV diameter was 1.88-3.1 mm. MTV branched out from the superficial temporal vein at  $12.7 \pm 6.6$  mm above the upper border of the zygomatic arch and ran  $52.0 \pm 6.5$  mm to the bony lateral canthus.<sup>17)</sup> In our case, the diameter of the MTV showed an extended finding of 3.5 mm.

A total of 20 CDAVF patients, summarized in Table 1, and our patient was also treated using the MTV approach. Access through the femoral vein was performed in 16 cases, and direct MTV puncture was performed in 4 cases. In the approach pathway, depending on the anatomical variation, the external or internal jugular vein can access the MTV. Neither our patient nor the reviewed cases (Table 1) reported any perioperative or postoperative complications. It is evident that this is a safer method than the direct ophthalmic puncture procedure. Compared with other alternative approach methods, no studies describing the complete occlusion rate were found; however, in review of the other cases of using the MTV approach, all of the cases except for the 7 cases that did not describe the results showed complete occlusion. Complete occlusion seemed sufficiently possible in treatment of CDAVF via MTV approach.<sup>18)</sup>

Therefore, when IPS occlusion and venous reflux to SOV are present in CDAVF patients, MTV dilatation can often be observed, and an approach using MTV can be provided as a sufficiently safe and effective method to treat CDAVF.

## CONCLUSIONS

Transfemoral catheterization of the cavernous sinus via the MTV is a safe and effective approach, which increases technical success by providing an alternative route for transvenous embolization of CDAVF when other venous routes, such as IPS, are difficult or impossible to navigate with a catheter. Therefore, we should be aware of the presence of MTV on a diagnostic angiogram when it is challenging to reach CDAVF through the conventional route.

## Disclosure

The authors report no conflict of interest concerning the materials or methods used in this study or the findings specified in this paper.

## REFERENCES

1. Agid R, Willinsky RA, Haw C, Souza MPS, Vanek IJ, terBrugge KG. Targeted compartmental embolization of cavernous sinus dural arteriovenous fistulae using transfemoral medial and lateral facial vein approaches. *Neuroradiology*. 2004 Feb;46(2):156-60.
2. Cheng KM, Chan CM, Cheung YL. Transvenous embolisation of dural carotid-cavernous fistulas by multiple venous routes: a series of 27 cases. *Acta Neurochir (Wien)*. 2003 Jan;145(1):17-29.
3. Devoto MH, Egbert JE, Tomsick TA, Kulwin DR. Acute exophthalmos during treatment of a cavernous sinus-dural fistula through the superior ophthalmic vein. *Arch Ophthalmol*. 1997 Jun;115(6):823-4.
4. Dye J, Duckwiler G, Gonzalez N, Kaneko N, Goldberg R, Rootman D, et al. Endovascular approaches to the cavernous sinus in the setting of dural arteriovenous fistula. *Brain Sci*. 2020 Aug;10(8):554.
5. Fattahi TT, Brandt MT, Jenkins WS, Steinberg B. Traumatic carotid-cavernous fistula: pathophysiology and treatment. *J Craniofac Surg*. 2003 Mar;14(2):240-6.
6. Fu ZY, Feng Y, Ma C, Chen JC, Krings T, Zhao WY. Endovascular treatment of cavernous sinus dural arteriovenous fistulas via direct transorbital puncture using cone-beam computed tomography image guidance: report of 3 cases. *World Neurosurg*. 2019 Oct;130:306-12.

7. Gemmete JJ, Ansari SA, Gandhi DM. Endovascular techniques for treatment of carotid-cavernous fistula. *J Neuroophthalmol.* 2009 Mar;29(1):62-71.
8. Gupta N, Kikkawa DO, Levi L, Weinreb RN. Severe vision loss and neovascular glaucoma complicating superior ophthalmic vein approach to carotid-cavernous sinus fistula. *Am J Ophthalmol.* 1997 Dec;124(6):853-5.
9. Halbach VV, Hieshima GB, Higashida RT, Reicher M. Carotid cavernous fistulae: indications for urgent treatment. *AJR Am J Roentgenol.* 1987 Sep;149(3):587-93.
10. Han W, Kim JH, Kang HI, Kim DR, Moon BG, Kim JS. Transvenous embolization of dural carotid cavernous fistula through the supraorbital vein. *J Cerebrovasc Endovasc Neurosurg.* 2019 Jun;21(2):101-6.
11. Henderson AD, Miller NR. Carotid-cavernous fistula: current concepts in aetiology, investigation, and management. *Eye (Lond).* 2018 Feb;32(2):164-72.
12. Komiyama M, Morikawa K, Fu Y, Yagura H, Yasui T, Baba M. Indirect carotid-cavernous sinus fistula: transvenous embolization from the external jugular vein using a superior ophthalmic vein approach. A case report. *Surg Neurol.* 1990 Jan;33(1):57-63.
13. Korkmazer B, Kocak B, Tureci E, Islak C, Kocer N, Kizilkilic O. Endovascular treatment of carotid cavernous sinus fistula: A systematic review. *World J Radiol.* 2013 Apr;5(4):143-55.
14. Matsubara S, Kazekawa K, Aikawa H, Onizuka M, Tsutsumi M, Ikou M, et al. Direct superficial temporal vein approach for dural carotid cavernous fistula. *Interv Neuroradiol.* 2007 Mar;13(Suppl 1):64-7.
15. Miller NR. Dural carotid-cavernous fistulas: epidemiology, clinical presentation, and management. *Neurosurg Clin N Am.* 2012 Jan;23(1):179-92.
16. Miyachi S, Negoro M, Handa T, Sugita K. Dural carotid cavernous sinus fistula presenting as isolated oculomotor nerve palsy. *Surg Neurol.* 1993 Feb;39(2):105-9.
17. Nokovitch L, Devauchelle B, Peyrachon B, Vacher C, Deneuve S. Anatomical characteristics of the superficial temporal venous system and implications in microsurgery. *Ann Chir Plast Esthet.* 2021 Jun;66(3):250-6.
18. Shimizu Y. Superficial middle temporal vein as a pivotal route to embolize dural carotid-cavernous fistulas. *J Clin Neurosci.* 2021 Feb;84:106-10.
19. Singh J, Morris PP. Superficial temporal vein: route to embolization of cavernous dural arteriovenous fistula. *J Neuroimaging.* 2011 Jul;21(3):251-4.
20. Suh DC, Lee JH, Kim SJ, Chung SJ, Choi CG, Kim HJ, et al. New concept in cavernous sinus dural arteriovenous fistula: correlation with presenting symptom and venous drainage patterns. *Stroke.* 2005 Jun;36(6):1134-9.
21. Trivelato FP, Manzato LB, Filho PMM, Ulhoa AC, Vanzin JR, Abud DG, et al. Transorbital cavernous sinus direct puncture: Alternative to treat dural arteriovenous fistula. *Clin Neuroradiol.* 2018 Mar;28(1):55-61.
22. Yu SC, Cheng HK, Wong GK, Chan CM, Cheung JY, Poon WS. Transvenous embolization of dural carotid-cavernous fistulae with transfacial catheterization through the superior ophthalmic vein. *Neurosurgery.* 2007 Jun;60(6):1032-7; discussion 1037-8.