

Available online at [www.sciencedirect.com](http://www.sciencedirect.com)

ScienceDirect

journal homepage: [www.elsevier.com/locate/radcr](http://www.elsevier.com/locate/radcr)

## Case Report

# Fortuitous discovery of isolated tuberculosis of the tenth and eleventh costotransverse joints: A case report<sup>☆</sup>

Adnene Benammou, MD<sup>a,\*</sup>, Ahmed Elloumi, MD<sup>a</sup>, Chrif Kamoun, MD<sup>a</sup>, Mehdi Bellil, MD<sup>a</sup>, Walid Balti, MD<sup>a</sup>, Siwar Ben Dhia, MD<sup>b</sup>, Ines Mahmoud, MD<sup>b</sup>, Leila Abdelmoula, MD<sup>b</sup>, Khaled Hadhri, MD<sup>a</sup>, Mondher Kooli, MD<sup>a</sup>, Mohamed Ben Salah, MD<sup>a</sup>

<sup>a</sup> Orthopedic surgery department, Charles Nicolle's Hospital, Boulevard 9 avril, Tunis, Tunisia

<sup>b</sup> Rheumatology department, Charles Nicolle's Hospital, Boulevard 9 avril, Tunis, Tunisia

## ARTICLE INFO

## Article history:

Received 16 February 2022

Revised 25 February 2022

Accepted 2 March 2022

## Keywords:

Koch's spine

Posterior elements

Tuberculosis

Spine

## ABSTRACT

Involvement of posterior elements of the spine in spinal tuberculosis is rare. We report a case of a 56-year-old woman who presented with asymptomatic tuberculosis of the tenth and eleventh costotransverse joints. The latter was discovered with a CT scan made to look for a pulmonary embolism. Magnetic Resonance Imaging (MRI) showed liquid in the costotransverse joints with a paravertebral abscess. The patient was managed conservatively. Although rare, posterior tuberculosis of the spine should be known by spine surgeons. MRI is the key to the diagnosis. Conservative treatment is the standard treatment, and surgery is reserved for patients with neurological deficit.

© 2022 The Authors. Published by Elsevier Inc. on behalf of University of Washington.

This is an open access article under the CC BY-NC-ND license (<http://creativecommons.org/licenses/by-nc-nd/4.0/>)

## Introduction

Tuberculosis of the spine represents the most frequent localization of osteoarticular tuberculosis [1]. The classical tuberculosis of the spine is a spondylodiscitis which is an affection of the vertebral body and involves the intervertebral disk [2].

Concomitant involvement of posterior elements is found on MRI in 24% [3]. Isolated involvement of the posterior elements (neural arch tuberculosis) is even rarer; occurring in <1% to 6% of spinal tuberculosis [4].

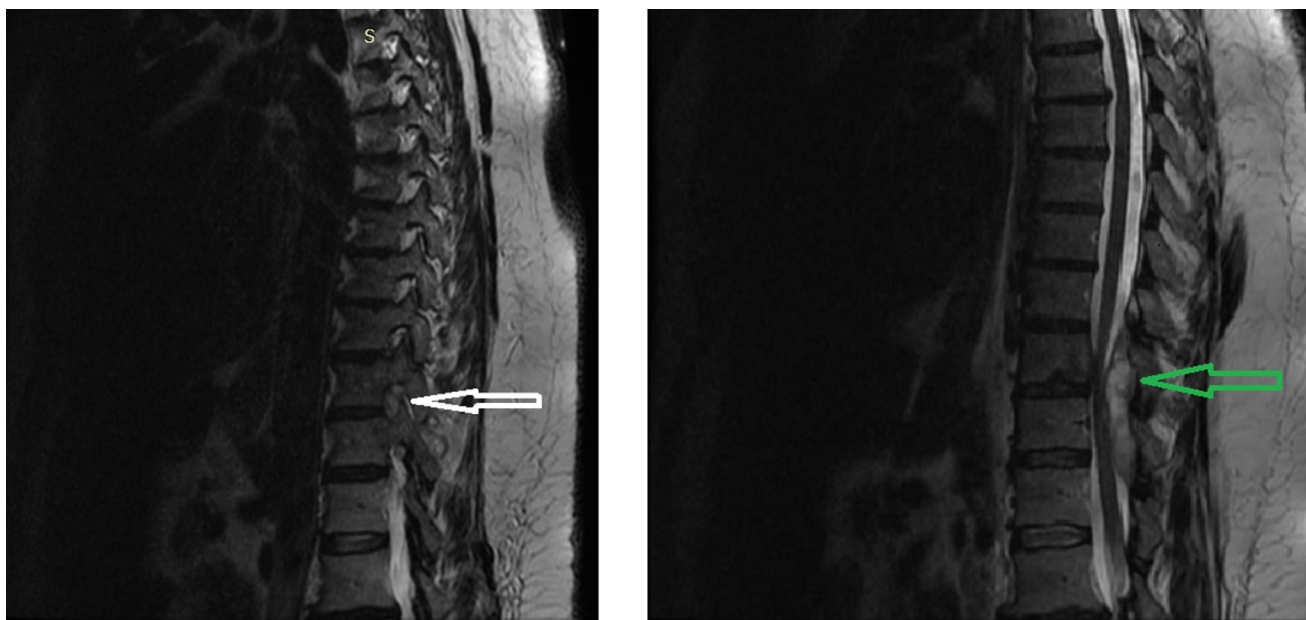We present the case of a patient diagnosed with tuberculosis of the left tenth and eleventh costotransverse joints when exploring a thoracic pain for pulmonary embolism.

<sup>☆</sup> Competing Interests: The authors declare that they have no known competing financial interests or personal relationships that could have appeared to influence the work reported in this paper.

\* Corresponding author.

E-mail addresses: [Adnene.benammou@gmail.com](mailto:Adnene.benammou@gmail.com) (A. Benammou), [docloum@hotmail.com](mailto:docloum@hotmail.com) (A. Elloumi), [chrifkamoun@ymail.com](mailto:chrifkamoun@ymail.com) (C. Kamoun), [drbellilmehdi@gmail.com](mailto:drbellilmehdi@gmail.com) (M. Bellil), [Baltiwaliid@ymail.com](mailto:Baltiwaliid@ymail.com) (W. Balti), [khaledhadhri.kh@gmail.com](mailto:khaledhadhri.kh@gmail.com) (K. Hadhri), [mondher.kooli@rns.tn](mailto:mondher.kooli@rns.tn) (M. Kooli), [mbensalah9494@gmail.com](mailto:mbensalah9494@gmail.com) (M. Ben Salah).  
<https://doi.org/10.1016/j.radcr.2022.03.016>

1930-0433/© 2022 The Authors. Published by Elsevier Inc. on behalf of University of Washington. This is an open access article under the CC BY-NC-ND license (<http://creativecommons.org/licenses/by-nc-nd/4.0/>)



**Fig. 1 – T2-weighted sagittal section of Magnetic Resonance Imaging (MRI) of the thoracic spine showing ligamentum flavum hypertrophy causing significant canal compression from posterior aspect (green arrow) with liquid in the costovertebral joint (white arrow).**

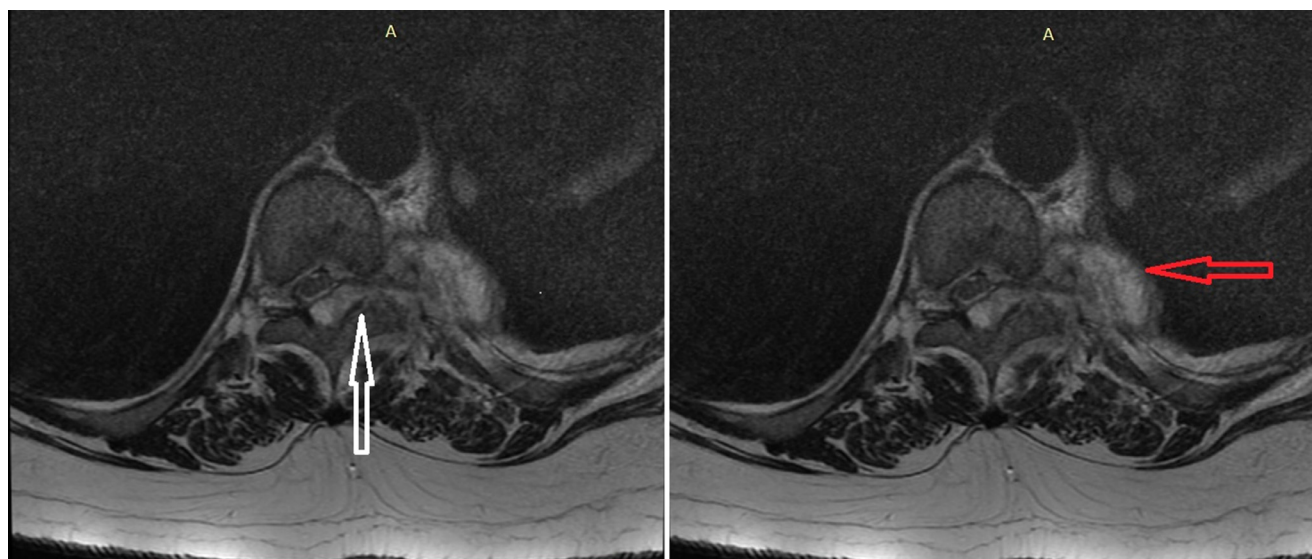
### Case report

A 56-year-old female with a history of recently diagnosed diabetes presented with acute left Basal thoracic pain, cough, and dyspnea on exertion. At the physical examination, the patient had no fever. Respiratory, cardiovascular, neurological and osteoarticular examinations were normal apart from a tachycardia at 100 beats per minute. Biochemical examination showed an elevated C-reactive protein (CRP) level with respiratory alkalosis and hypoxemia. A thoracic computed-tomography (CT) angiography was performed and showed a distal pulmonary embolism of the right pulmonary artery. It also showed evidence of an arthritis of the eleventh costo-vertebral articulation, with an abscess of the soft parts facing the costo-vertebral angle of the same level. A magnetic resonance imaging (MRI) scan was performed and showed evidence of a left costovertebral arthritis of the T10 and T11 vertebrae extending to the posterior arches associated to a posterior epidural collection communicating with a left paravertebral collection. A CT guided biopsy of the affected costovertebral articulation was performed. Histologic examination showed epithelioid and giantocellular granulomas. Tuberculosis Culture was positive. Tuberculin skin test, as well as the search of Koch bacillus in urine and expectoration, were all negative. Spinal posterior tuberculosis was diagnosed. The patient was treated with low molecular weight heparin and acenocoumarol relay for pulmonary embolism, with good evolution. Spinal tuberculosis was treated with a quadritherapy of isoniazid, rifampicin, ethambutol and pyrazinamide for 2 months, then with biotherapy of isoniazid and rifampicin. A corticosteroid therapy was associated with the presence of an epiduritis. [Figure 1](#) [Figure 2](#) [Figure 3](#)

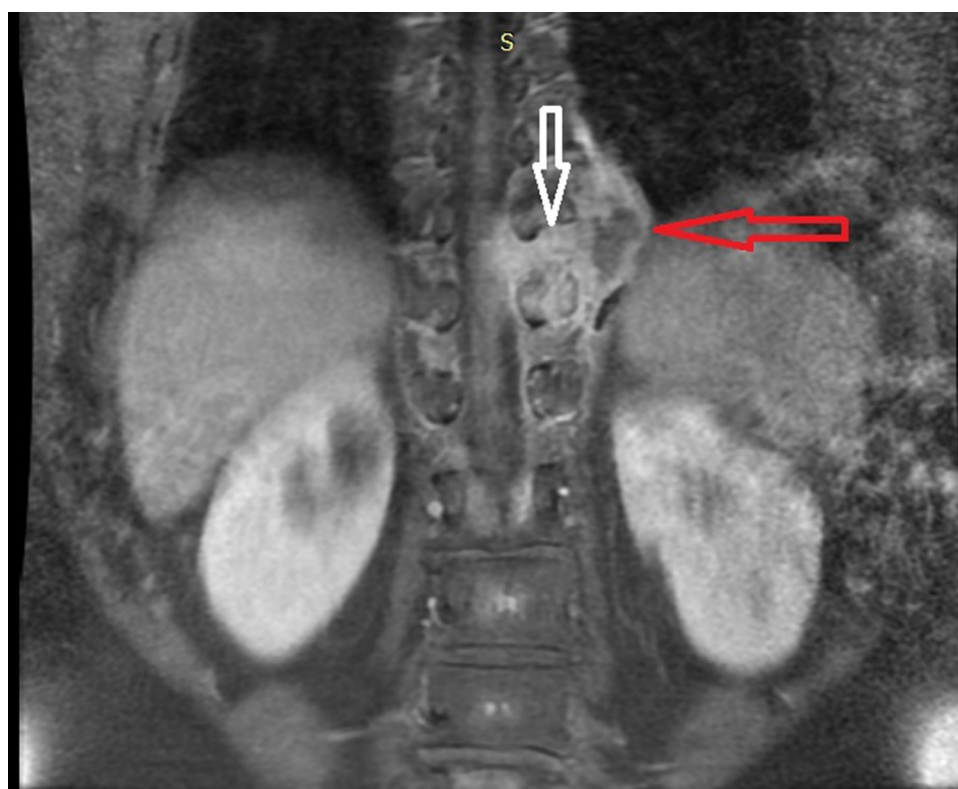### Discussion

The spine is involved in 50% of the skeletal system tuberculosis [5]. It commonly impacts the lower dorsal and dorsolumbar junction [6]. It usually involves the anterior column. The involvement of the posterior elements is rare [6]. Posterior elements are typically affected secondarily to the vertebral bodies [4]. Isolated involvement of the posterior elements is due to hematogenous spread via posterior external venous plexuses of vertebral veins [4]. Clinical features of Spinal tuberculosis involve back pain with or without constitutional symptoms with an insidious onset. Kyphotic deformity and neurological deficit may be present if it is not diagnosed and treated early [7]. Posterior spine tuberculosis presents with bony back pain associated with tenderness or swelling in the midline or paraspinal area, formation of cold abscess [2]. Radicular pain can be present in this case. Neurological deficit is common in posterior spine tuberculosis [2]. The high prevalence of neurological deficit can be explained by the predilection of this type of lesion in the thoracic spine, where the spinal cord canal ratio is critical [4].

In our case, the patient presented with none of the symptoms of the posterior spine tuberculosis, especially neurological deficit. Conventional X-rays have limited contribution in this type of affection [2]. CT scan can identify bone destruction and granulation tissue [4]. MRI is the gold standard in detecting affection of the posterior elements in early stages, showing bone marrow edema before any osseous destruction [6]. MRI can also show epidural collection [4]. The uniqueness of our case is that it was initially diagnosed with a CT scan, realized to search for a pulmonary embolism. MRI was realized



**Fig. 2 – T2-weighted axial section of the MRI of the thoracic spine, showing liquid in the costotransverse joint (white arrow) and paravertebral abscess (red arrow).**



**Fig. 3 – T1-weighted coronal section of the MRI of the thoracic spine, showing liquid in the costotransverse joint (white arrow) and paravertebral abscess (red arrow).**

secondarily for confirmation of the diagnoses and to establish the exact lesions. Histopathological confirmation can confirm the diagnosis [2]. Treatment with antitubercular drugs should be started as soon as the diagnosis is made [6]. Surgery for posterior elements' tuberculosis is indicated for neurological deficits and establishing the final diagnosis [2].

## Conclusion

Although rare, involvement of the posterior elements of the spine in spinal tuberculosis should be known by spine surgeons. Clinical presentations are multiples and neurological

deficits are common. MRI is the gold standard for imagery. Treatment associates antitubercular drugs and surgery for complicated cases.

---

## Acknowledgments

I thank Mrs Lamice Skhiri for offering help in reviewing and revising the manuscript for spelling, grammar and syntax.

---

## Patient Consent

Consent for publication: Informed consent was obtained from the patient described in this report.

---

## REFERENCES

- [1] Boruah DK, Gogoi BB, Prakash A, Lal NR, Hazarika K, Borah KK. Magnetic resonance imaging evaluation of posterior spinal tuberculosis: a cross-sectional study. *Acta Radiol* 2021;62:1035–44. doi:[10.1177/0284185120948496](https://doi.org/10.1177/0284185120948496).
- [2] Sonone S.V., Dahapute A.A., Keny S.A., Marathe N.A., Dhole K.P. Unusual presentation of koch's spine involving posterior elements of vertebra– a case report 2019;3. doi:[10.13107/jocr.2019.v09.i04.1470](https://doi.org/10.13107/jocr.2019.v09.i04.1470).
- [3] Narlawar RS, Shah JR, Pimple MK, Patkar DP, Patankar T, Castillo M. Isolated tuberculosis of posterior elements of spine: magnetic resonance imaging findings in 33 patients. *Spine* 2002;27:275–81. doi:[10.1097/00007632-200202010-00015](https://doi.org/10.1097/00007632-200202010-00015).
- [4] Arora S, Sabat D, Maini L, Sural S, Kumar V, Gautam VK, et al. Isolated involvement of the posterior elements in spinal. *Tuberculosis* 2012;94:8. doi:[10.2106/JBJS.K.01464](https://doi.org/10.2106/JBJS.K.01464).
- [5] Tuli SM. Tuberculosis of the spine: a historical review. *Clin Orthop* 2007;460:29–38. doi:[10.1097/BLO.0b013e318065b75e](https://doi.org/10.1097/BLO.0b013e318065b75e).
- [6] Gupta M, Jain VK, Naik AK, Arya RK. Tuberculosis of bilateral first costotransverse joints. *Case Rep* 2013;2013 bcr2013010490–bcr2013010490. doi:[10.1136/bcr-2013-010490](https://doi.org/10.1136/bcr-2013-010490).
- [7] Jain AK, Rajasekaran S, Jaggi KR, Myneedu VP. Tuberculosis of the spine. *J Bone Jt Surg* 2020;102:617–28. doi:[10.2106/JBJS.19.00001](https://doi.org/10.2106/JBJS.19.00001).