



High-dose glucocorticoid treatment of near-fatal bocavirus lung infection results in rapid recovery

To the Editor:

Human bocavirus (HBoV), which belongs to *Parvoviridae*, is a well-defined pathogen of respiratory infections, particularly in young children [1]. In contrast, the frequency of HBoV infections in adults with respiratory symptoms is virtually unknown and its causative role in respiratory failure is debated [1, 2]. Furthermore, the observation that dexamethasone is beneficial in COVID-19 patients with respiratory failure requiring respiratory support has gained great interest [3]. However, whether glucocorticoid treatment is useful in other severe viral respiratory diseases is a matter of controversy [4].

Here, we report on a 58-year-old, obese (body mass index $35 \text{ kg}\cdot\text{m}^{-2}$, Eastern Cooperative Oncology Group performance status 1), Caucasian male who presented at Charité University Hospital (Berlin, Germany) on 25 February 2020 with a 6-day history of fever and shortness of breath. 3 months earlier, he had received BEAM (carmustine, etoposide, cytarabine and melphalan) high-dose chemotherapy and autologous stem cell transplantation (autoSCT) for relapsed Hodgkin's lymphoma, resulting in complete remission. Relevant medical history included psoriasis, diabetes mellitus type 2, permanent atrial fibrillation and COPD of Global Initiative for Chronic Obstructive Lung Disease stage II, with no relevant previously documented pulmonary structural alterations. Concomitant medication on admission consisted of acyclovir, pantoprazole, digitoxin, bisoprolol, sitagliptin, metformin, insulin and acitretin, all not considered as causative for the clinical symptoms. On admission, peripheral oxygen saturation demonstrated hypoxaemia (S_{pO_2} 88%), C-reactive protein (CRP) level was $50.9 \text{ mg}\cdot\text{L}^{-1}$ (normal range $<5 \text{ mg}\cdot\text{L}^{-1}$), and chest radiography disclosed diffuse reticular, interstitial infiltrations of the lung. As the patient deteriorated, accompanied by further CRP increase to $92.9 \text{ mg}\cdot\text{L}^{-1}$, during a 7-day course (25 February to 3 March) of antibiotic treatment with piperacillin/tazobactam and ciprofloxacin, a subsequent lung computed tomography (CT) scan (figure 1a) revealed bilateral pulmonary infiltrates with interstitial pattern, ground-glass opacities, (pre-existing) bullae and consolidation in the upper-left lobe. Small-volume bronchoalveolar lavage (BAL) and lung biopsy were performed. On 5 March, the patient finally required mechanical ventilation due to respiratory failure without signs of overt sepsis, with an initial positive end-expiratory pressure of $5 \text{ cmH}_2\text{O}$; arterial oxygen tension/inspiratory oxygen fraction ratio was 136 mmHg, suggesting moderate acute respiratory distress syndrome (ARDS). Extended examinations of the BAL for infectious pathogens (bacterial culture and microscopy; and PCR-based respiratory panel analyses including various infectious agents (viruses (adenovirus, HBoV, cytomegalovirus, coronavirus including severe acute respiratory syndrome (SARS) coronavirus 2, Epstein-Barr virus (EBV), entero/rhinovirus, human herpesvirus 6, herpes simplex virus (HSV)-1 and HSV-2, influenza virus A/B, metapneumovirus, parainfluenzavirus 1-4, respiratory syncytial virus A/B, varicella zoster virus), bacteria (*Bordetella* spp., *Chlamydia* spp., *Legionella* spp. and *Mycoplasma* spp.) and *Pneumocystis jirovecii*) revealed positivity for HBoV (and low-level detection of EBV (2390 copies (cp) per mL) in BAL but not in blood, judged not to be clinically relevant) but no other pathogens.

We considered HBoV infection followed by excessive immune response, possibly aggravated by immune reconstitution after autoSCT, as underlying pathogenic events. A high concentration of HBoV genome



@ERSpublications

Human bocavirus (HBoV) has to be considered a life-threatening pathogen in adults with atypical pneumonia. Pulsed high-dose glucocorticoid treatment may be beneficial in patients suffering from severe pulmonary disease caused by HBoV or other viruses. <https://bit.ly/3epiMyO>

Cite this article as: Obenaus M, Schildgen O, Schürmann D, *et al.* High-dose glucocorticoid treatment of near-fatal bocavirus lung infection results in rapid recovery. *ERJ Open Res* 2021; 7: 00060-2021 [<https://doi.org/10.1183/23120541.00060-2021>].

Copyright ©The authors 2021. This version is distributed under the terms of the Creative Commons Attribution Non-Commercial Licence 4.0. For commercial reproduction rights and permissions contact permissions@ersnet.org



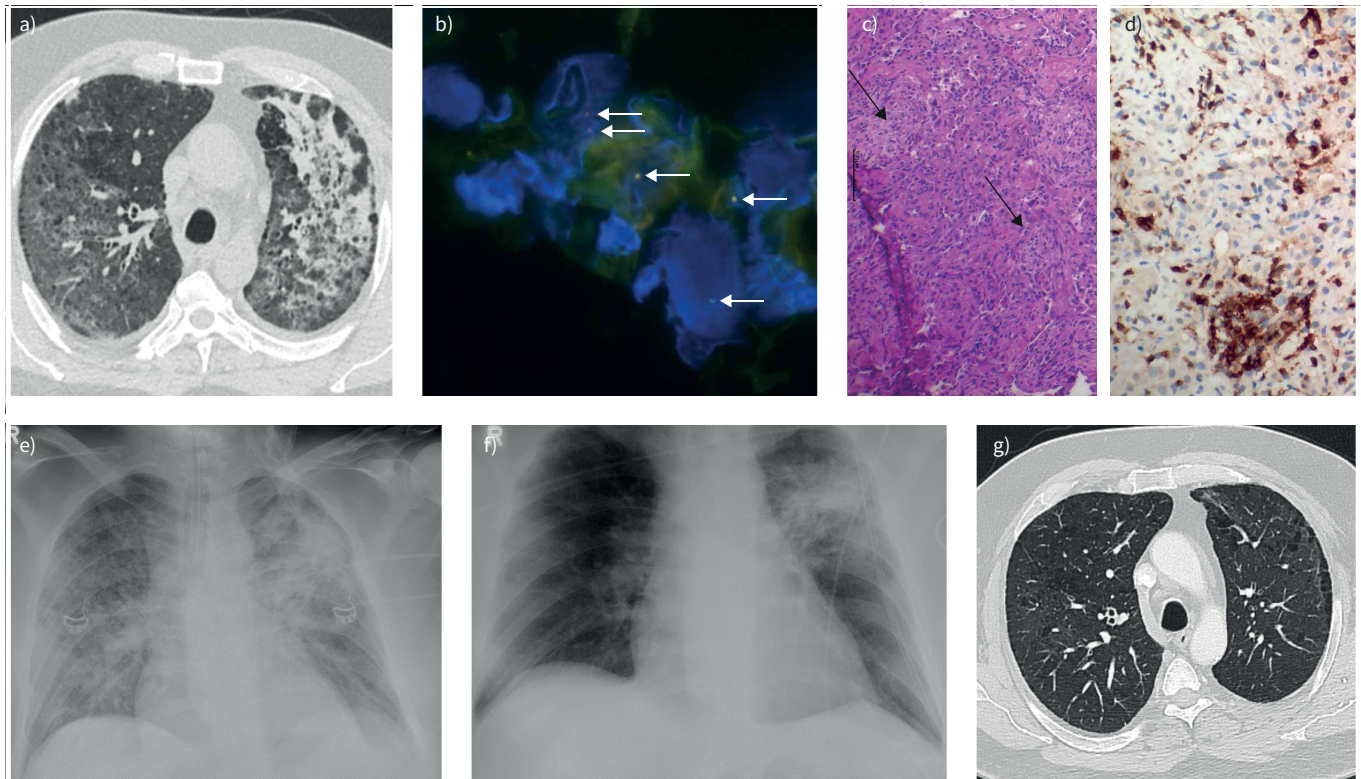


FIGURE 1 Radiomorphological and pathological-anatomical findings of a patient with near-fatal human bocavirus (HBoV) infection. a) Computed tomography (CT) image after a 7-day course of antibiotic therapy shows bilateral pulmonary infiltrates with interstitial pattern and ground-glass opacities (3 March 2020). b) HBoV-specific fluorescence *in situ* hybridisation in lung biopsy. Head and tail HBoV genome regions were detected with specific fluorescence probes and tissue was counterstained with DAPI. Yellow and orange dots (arrows) indicate codetection of the head and tail regions of HBoV-DNA. c) Lung biopsy showing fibroblast proliferation (arrows) (haematoxylin and eosin staining). d) Strong infiltration with T-lymphocytes (CD3 staining in brown) in the lung tissue reflecting excessive immune response. e) Chest radiography (anteroposterior view) at initiation of glucocorticoid treatment (day 1) showing multifocal opacities in both lungs with foci of consolidation in the upper-left lobe (5 March 2020), and f) at day 4, demonstrating resolution of the multifocal opacities with demarked consolidation in the upper left lobe (8 March 2020). g) CT image 2 months after treatment demonstrates complete resolution of infiltrates with remaining pre-existing small bullae (26 May 2020).

copies (3.2×10^8 cp·mL⁻¹ in BAL), HBoV detection by fluorescence *in situ* hybridisation (figure 1b) and pronounced T-lymphocytic infiltrates (figure 1c and d) in the lung tissue confirmed this scenario. Given the lack of HBoV-specific treatments, we aimed to mitigate the immune reaction and subsequent pulmonary damage by pulsed high-dose glucocorticoid therapy (5 March (day 1), 500 mg prednisolone; days 2 and 3, 1000 mg methylprednisolone) followed by rapid reduction to 20 mg·day⁻¹ prednisolone and tapering. Respiratory parameters and radiological findings improved rapidly (figure 1e and f), allowing termination of mechanical ventilation on day 4 (8 March) of intensive care unit treatment and discharge on 17 March. In parallel to the clinical improvement, CRP values rapidly decreased and remained normal. A CT scan 2 months after treatment confirmed complete resolution of all infiltrates (figure 1g).

Given the virtually unknown frequency of HBoV in adult patients with respiratory symptoms [1], we retrospectively analysed a total of 5328 consecutive adult respiratory samples, mainly consisting of tracheobronchial secretions and BALs, and which were all examined by PCR-based respiratory panel analyses, for HBoV. We identified 17 HBoV-positive patients, most of them heavily immunocompromised. Given the reconstitution of white blood cells (4.45 nL⁻¹, normal range 3.90 – 10.50 nL⁻¹) with normal neutrophils (3.03 nL⁻¹, normal range 1.50 – 7.70 nL⁻¹) and slightly reduced lymphocytes (0.95 nL⁻¹, normal range 1.10 – 4.50 nL⁻¹), even though platelets (30 nL⁻¹, normal range 150 – 370 nL⁻¹) and haemoglobin (8.9 mg·dL⁻¹, normal range 13.5 – 17.0 mg·dL⁻¹) were reduced on admission, as well as almost normal immunoglobulin levels (IgG 6.61 g·L⁻¹, normal range 7.00 – 16.00 g·L⁻¹; IgA 1.72 g·L⁻¹, normal range 0.7 – 4.00 g·L⁻¹; and IgM 0.30 g·L⁻¹, normal range 0.40 – 2.30 g·L⁻¹) at the time of HBoV-induced respiratory failure, we judged our patient to be largely immunocompetent. Thus, even though rare, HBoV must be considered a life-threatening pathogen in adults with atypical pneumonia and should be included in the respective diagnostic work-up, with HBoV-DNA quantification if positive.

Only recently, it has been demonstrated that dexamethasone is beneficial in COVID-19 patients with respiratory failure requiring respiratory support [3]; however, the benefit of glucocorticoid treatment in other severe viral respiratory diseases is unclear [4]. In contrast to the dexamethasone scheme used in the RECOVERY trial in COVID-19 patients (6 mg once daily for up to 10 days), we applied a pulsed high-dose glucocorticoid therapy scheme deduced from treatment of autoimmune diseases. Notably, the application of such pulsed “very high-dose” glucocorticoid therapy is supposed to extend the glucocorticoid mode of action compared to lower doses [5, 6]. We assume that this short-term high-dose glucocorticoid therapy effectively dampened the detrimental virus-induced immune response, most likely by glucocorticoid-induced cell death of immune effector cells including infiltrating T-lymphocytes, and anti-inflammatory effects by modulation of monocyte and macrophage function [7, 8]. Furthermore, glucocorticoid therapy can inhibit fibroblast proliferation and support the clearance of inflammation-induced tissue damage [7]. We are aware of glucocorticoid therapy-induced side-effects; that corticosteroid treatment of ARDS or SARS patients, or patients suffering from viral pneumonia, has generated conflicting results [4, 5, 9–11]; and that prolonged intake of corticosteroids predisposes to invasive aspergillosis in the context of severe influenza infection [12]. However, short pulsed high-dose glucocorticoid therapy has been used for decades for the treatment of various severe autoimmune diseases, with limited and well-known side-effects [13]. Therefore, we decided to use such a “very high-dose” short-term scheme and not a lower-dose, longer-lasting scheme for our patient. We believe that in selected patients, in which the virus-induced immune response is profound and likely to be more harmful to lung tissue than damage by the virus itself, and in which fatal lung damage has not yet passed the point of no return, glucocorticoid therapy may preserve lung tissue and function. Notably, most recently, it has been shown that severe COVID-19 patients benefit from pulsed methylprednisolone administration if given during the early phase of pulmonary infection [14]. Thus, high-dose glucocorticoid therapy may be beneficial in patients suffering from severe pulmonary disease caused by HBoV, as demonstrated in our case, or other viruses.

Matthias Obenaus¹, **Oliver Schildgen**², **Dirk Schürmann**³, **Ann-Christin von Brünneck**⁴, **Martin Janz**^{1,5}, **Ulrich Keller**^{1,5}, **Bernhard Gebauer**⁶, **Johannes Schilling**⁷, **Stefan Schwartz**¹, **Benedikt Weissbrich**⁸, **Thomas Schneider**⁹, **Jörg Hofmann**¹⁰ and **Stephan Mathas**^{1,5}

¹Hematology, Oncology and Tumor Immunology, Charité – Universitätsmedizin Berlin, corporate member of Freie Universität Berlin and Humboldt-Universität zu Berlin, Berlin, Germany. ²Institute of Pathology, Kliniken der Stadt Köln gGmbH, Kliniken der Privaten Universität Witten/Herdecke mit Sitz in Köln, Cologne, Germany. ³Infectious Diseases and Respiratory Medicine, Charité – Universitätsmedizin Berlin, Berlin, Germany. ⁴Pathology, Charité – Universitätsmedizin Berlin, Berlin, Germany. ⁵Experimental and Clinical Research Center, a cooperation between the Charité and the Max-Delbrück-Center for Molecular Medicine, Berlin, Germany. ⁶Radiology, Charité – Universitätsmedizin Berlin, Berlin, Germany. ⁷Nephrology and Medical Intensive Care, Charité – Universitätsmedizin Berlin, Berlin, Germany. ⁸Institute for Virology and Immunobiology, University Würzburg, Würzburg, Germany. ⁹Gastroenterology, Infectious Diseases and Rheumatology, Charité – Universitätsmedizin Berlin, Berlin, Germany. ¹⁰Institute of Virology, Charité – Universitätsmedizin Berlin, Berlin, Germany.

Correspondence: Stephan Mathas, Hematology, Oncology and Tumor Immunology and Max-Delbrück-Center for Molecular Medicine, Charité – Universitätsmedizin Berlin, Hindenburgdamm 30, D-12200 Berlin, Germany. E-mail: stephan.mathas@charite.de

Received: 12 Feb 2021 | Accepted: 27 Feb 2021

Conflict of interest: M. Obenaus reports personal fees from Novartis during the conduct of this study. O. Schildgen has nothing to disclose. D. Schürmann has nothing to disclose. A-C. von Brünneck has nothing to disclose. M. Janz has nothing to disclose. U. Keller reports personal fees from Takeda, Hexal, Abbvie, Pentizapharm and AstraZeneca, and personal fees and other support from Roche, Janssen-Cilag, Pfizer and BMS, outside the submitted work. B. Gebauer reports personal fees from Parexek/CALYX, ICON, Bayer, Siemens, Roche, Merck, IPSEN, Pfizer, Elsay, MSD, Pharmcept, Guerbet, Ewimed and Sirtex Medical outside the submitted work. J. Schilling has nothing to disclose. S. Schwartz reports personal fees from Pfizer, BTG Intl Inc., MSD and Novartis, personal fees and nonfinancial support from Gilead Sciences, AMGEN and Jazz Pharmaceuticals, and nonfinancial support from Basilea, outside the submitted work. B. Weissbrich has nothing to disclose. T. Schneider has nothing to disclose. J. Hofmann has nothing to disclose. S. Mathas has nothing to disclose.

References

- 1 Qiu J, Söderlund-Venermo M, Young NS. Human parvoviruses. *Clin Microbiol Rev* 2017; 30: 43–113.
- 2 Dieninghoff D, Karagiannidis C, Straßmann S, et al. Fatal HBoV-1 infection in adult female cystic fibrosis patient. *Hum Pathol Case Rep* 2017; 7: 51–52.

- 3 RECOVERY Collaborative Group. Dexamethasone in hospitalised patients with Covid-19. *N Engl J Med* 2021; 384: 693–704.
- 4 Ruuskanen O, Lahti E, Jennings LC, *et al.* Viral pneumonia. *Lancet* 2011; 377: 1264–1275.
- 5 Stahn C, Buttgerit F. Genomic and nongenomic effects of glucocorticoids. *Nat Clin Pract Rheumatol* 2008; 4: 525–533.
- 6 Buttgerit F, da Silva JAP, Boers M, *et al.* Standardized nomenclature for glucocorticoid dosages and glucocorticoid treatment regimens: Current questions and tentative answers in rheumatology. *Ann Rheum Dis* 2002; 61: 718–722.
- 7 Cain DW, Cidlowski JA. Immune regulation by glucocorticoids. *Nat Rev Immunol* 2017; 17: 233–247.
- 8 Ehrchen JM, Roth J, Barczyk-Kahlert K. More than suppression: glucocorticoid action on monocytes and macrophages. *Front Immunol* 2019; 10: 2028.
- 9 Steinberg KP, Hudson LD, Goodman RB, *et al.* Efficacy and safety of corticosteroids for persistent acute respiratory distress syndrome. *N Engl J Med* 2006; 354: 1671–1684.
- 10 Villar J, Ferrando C, Martínez D, *et al.* Dexamethasone treatment for the acute respiratory distress syndrome: a multicentre, randomised controlled trial. *Lancet Respir Med* 2020; 8: 267–276.
- 11 Sung JY, Wu A, Joynt GM, *et al.* Severe acute respiratory syndrome: report of treatment and outcome after a major outbreak. *Thorax* 2004; 59: 414–420.
- 12 Schauwvlieghe AFAD, Rijnders BJA, Philips N, *et al.* Invasive aspergillosis in patients admitted to the intensive care unit with severe influenza: a retrospective cohort study. *Lancet Respir Med* 2018; 6: 782–792.
- 13 Weusten BLAM, Jacobs JWG, Bijlsma JWJ. Corticosteroid pulse therapy in active rheumatoid arthritis. *Semin Arthritis Rheum* 1993; 23: 183–192.
- 14 Edalatifard M, Akhtari M, Salehi M, *et al.* Intravenous methylprednisolone pulse as a treatment for hospitalised severe COVID-19 patients: Results from a randomised controlled clinical trial. *Eur Respir J* 2020; 56: 2002808.