




Since January 2020 Elsevier has created a COVID-19 resource centre with free information in English and Mandarin on the novel coronavirus COVID-19. The COVID-19 resource centre is hosted on Elsevier Connect, the company's public news and information website.

Elsevier hereby grants permission to make all its COVID-19-related research that is available on the COVID-19 resource centre - including this research content - immediately available in PubMed Central and other publicly funded repositories, such as the WHO COVID database with rights for unrestricted research re-use and analyses in any form or by any means with acknowledgement of the original source. These permissions are granted for free by Elsevier for as long as the COVID-19 resource centre remains active.

Contents lists available at [ScienceDirect](https://www.sciencedirect.com)

# American Journal of Otolaryngology–Head and Neck Medicine and Surgery

journal homepage: [www.elsevier.com/locate/amjoto](http://www.elsevier.com/locate/amjoto)

## Adjunctive use of saturated solution of potassium iodide (SSKI) with liposomal amphotericin B (L-AMB) in mucormycosis achieves favorable response, shortened dose and duration of amphotericin: A retrospective study from a COVID-19 tertiary care center

Sumit Mrig<sup>a</sup>, Kabir Sardana<sup>b</sup>, Pooja Arora<sup>b,\*</sup>, Vineet Narula<sup>a</sup>, Sandeep Arora<sup>a</sup>, Amrit Kapoor<sup>a</sup>, Ritu Raj Baruah<sup>c</sup>, Poornima Sen<sup>d</sup>, Shweta Agarwal<sup>d</sup>, Soumya Sachdeva<sup>b</sup>, Arun Dewan<sup>e</sup>, Sanjeet Panesar<sup>f</sup>

<sup>a</sup> Department of ENT, Max Smart Superspeciality Hospital, Saket, New Delhi, India

<sup>b</sup> Dermatology, Dr RML Hospital & ABVIMS, New Delhi, India

<sup>c</sup> Ophthalmology, Max Smart Superspeciality Hospital, Saket, New Delhi, India

<sup>d</sup> Max Superspeciality Hospital, Saket, New Delhi, India

<sup>e</sup> Critical Care & Internal Medicine, Max Smart Superspeciality Hospital, Saket, New Delhi, India

<sup>f</sup> Department of Community Medicine, Dr RML Hospital & ABVIMS, New Delhi, India

### ARTICLE INFO

#### Keywords:

Mucormycosis  
COVID-19  
SARS-CoV-2  
Amphotericin  
Potassium iodide

### ABSTRACT

**Purpose:** Second wave of COVID-19 pandemic was associated with an unprecedented rise in cases of mucormycosis, treatment of which has been challenging owing to the availability and side effects associated with amphotericin.

**Methods:** All patients presenting with rhino-orbital cerebral mucormycosis (ROCM) following COVID-19 infection between April 2021 to June 2021 were included in this retrospective interventional study. Primary objective was to assess the clinical response with combination of intravenous liposomal amphotericin B (4–5 mg/kg/day) and saturated solution of potassium iodide (SSKI) given orally along with surgical debridement.

**Results:** Twenty-five patients of ROCM were treated with the regimen. Mean age and fasting blood sugar levels were 53.48 years and 239.64 mg/dL respectively. All patients had history of intake of steroids with a mean daily dose of 86.39 mg of prednisolone equivalent. 88% of patients had a “proven” diagnosis of mucormycosis. Cultures were positive in 52% of patients with *Rhizopus arrhizus* as the predominant species. The mean daily dose of amphotericin received was 268 mg/day with a mean duration of 9.52 days. Mean daily dose of SSKI was 2.57 g. 21 patients (84%) had stabilization of disease at week 8 and achieved cure at the end of treatment whereas the mortality rate was 16%. Factors that significantly affected outcome were eye and central nervous system (CNS) involvement on presentation.

**Conclusion:** SSKI, with its remarkably low cost and safety profile, makes it a potential adjuvant drug that may help achieve the twin benefits of shortened duration and dose of LAMB.

### 1. Introduction

Mucormycosis is a rare life-threatening fungal infection caused by opportunistic fungi belonging to the order *Mucorales*. Rhino-orbital cerebral mucormycosis (ROCM) is the commonest presentation that occurs due to inhalation of spores that colonize the nose and paranasal sinuses and further spread to the orbit and brain causing high morbidity and

mortality even with treatment. Angioinvasion and vascular thrombosis is the hallmark of disease that presents with tissue necrosis, black eschar, or discharge in the nasal or oral cavity.

It has long been recognized that mucormycosis affects immunocompromised patients especially those with diabetes mellitus (DM). With the advent of the COVID-19 pandemic and the second wave of infection in the year 2021, evidence has emerged that patients infected

\* Corresponding author at: 9547, Sector C 9, Vasant Kunj, New Delhi, India.

E-mail address: [academic.drpoorjamrig@gmail.com](mailto:academic.drpoorjamrig@gmail.com) (P. Arora).

<https://doi.org/10.1016/j.amjoto.2022.103465>

Received 23 March 2022;

Available online 8 April 2022

0196-0709/© 2022 Elsevier Inc. All rights reserved.

with SARS-CoV2 have increased risk of acquiring secondary fungal infections [1]. India witnessed an unprecedented rise in the number of patients infected with mucormycosis in the past few months on account of several factors like use of corticosteroids for COVID-19, increase in severe infections leading to microangiopathy and high prevalence of diabetes [2]. Management of ROCM is challenging in low- and middle-income countries especially with limited availability of amphotericin, the first line agent in treatment. In this article, we present our experience in managing 25 patients who presented with ROCM following COVID-19 infection and were treated with a novel combination of restricted dose of amphotericin B and oral potassium iodide.

## 2. Methodology

### 2.1. Study design and cohort

This was a single center retrospective interventional study done in a tertiary care COVID-19 hospital involved in the emergent treatment of mucormycosis. All patients who presented with ROCM following COVID-19 infection and were treated with a combination of amphotericin B and oral potassium iodide between April 2021 to June 2021 were included in the study.

### 2.2. Disease definitions and workflow

The diagnosis of mucormycosis was based on the guidelines proposed by the All-India Ophthalmological Society [3]. These guidelines were formulated taking into consideration the increase in cases of mucormycosis seen in India during the second wave of COVID-19 infection (Table 1). All patients diagnosed as “proven” or “probable” mucormycosis were included in the study. Patients who presented with clinical signs and symptoms suggestive of mucormycosis but who did not have any confirmatory or suggestive evidence on laboratory investigations were excluded from the study.

All patients were subjected to a detailed history with assessment of demographic profile, clinical features, predisposing factors, treatment received for COVID-19 and other co-morbidities. The current COVID-19 status was determined by SARS-CoV2 reverse transcriptase polymerase chain reaction (RT-PCR) done on nasopharyngeal swab. Computed tomography (CT) scan of paranasal sinuses was performed as the initial investigation in all patients. In cases where eye or brain involvement was suspected, a magnetic resonance imaging (MRI) with gadolinium contrast was done. This was followed by nasal endoscopic examination to look for black necrotic eschar on nasal mucosa and hard palate, discoloration of mucosa or ulceration. Opinion of ophthalmologist was sought in patients suspected of orbital disease.

Direct microscopic examination (with potassium hydroxide-KOH mount), histopathology and culture were done from material obtained by endoscopic examination. Presence of non-septate or pauci-septate irregular, ribbon like hyphae with wide angled branching was considered diagnostic. Tissue biopsy was stained with hematoxylin and eosin

**Table 1**

Guidelines for diagnosis of mucormycosis proposed by the All India Ophthalmological Society.

	Proven	Probable	Possible
Clinical Features (typical signs and symptoms in the setting of recent COVID-19 infection, diabetes mellitus, immunosuppression including use of steroids, mechanical ventilation or oxygen support)	Present	Present	Present
Supportive evidence (diagnostic nasal endoscopy and/or contrast-enhanced MRI/CT scan)	Present	Present	Absent
Confirmatory evidence (direct microscopy or culture or histopathology with special stains or molecular diagnostics)	Present	Absent	Absent

and Periodic acid Schiff (PAS) stains. Detection of characteristic hyphae with signs of angioinvasion was considered diagnostic of mucormycosis. The material obtained by endoscopy was also inoculated on Sabouraud dextrose agar (SDA) and blood agar. These were incubated at 37 °C and 25 °C for 1–2 weeks. In case of mucormycosis, there was rapid growth of gray fluffy colonies that showed characteristic hyphae on subculture. Species identification was done by colony characteristics and microscopy using lactophenol cotton blue mount.

All patients with suspected mucormycosis were subjected to functional endoscopic sinus surgery (FESS) with debridement and started on intravenous liposomal amphotericin (L-AMB) 4-5 mg per kg with concomitant administration of saturated solution of potassium iodide (SSKI). This was based on the existential evidence of the role of SSKI in the treatment of mucormycosis [4–6]. During the emergent crisis with a limited supply of amphotericin, the duration of treatment was variable depending on the availability of the drug, response of the patient and the renal status. Renal function tests were performed daily to monitor side effects of amphotericin. After a baseline thyroid function test (TFT) and serum electrolytes, SSKI was started at a dose of 10 drops three times a day and increased to 15 drops TDS over a period of 1 week. This corresponded to a dose of 2–2.7 g daily.

For assessing stabilization of disease and response to treatment, MRI was done in all patients fortnightly along with endoscopic assessment. Further surgical intervention was done depending on clinical progression of disease and/or corroboration on serial scans. After the initial intensive phase with amphotericin, patients were started on oral posaconazole (loading dose of 300 mg twice daily followed by 300 mg once daily) for a total duration of 3 months. SSKI was continued in maintenance phase with a total treatment duration of 16 weeks. Follow up was done once in 2 weeks in all patients with endoscopic examination and monthly MRI scans in the maintenance phase.

### 2.3. Study objectives and outcomes

Primary objective was to assess the clinical response with protocol of restricted dose and duration of amphotericin B with adjunctive use of oral potassium iodide in patients with ROCM post COVID-19. Secondary objectives were to assess the side effects, complications and mortality associated with treatment and factors affecting the outcome.

Response was defined as “favorable” if there were signs of resolution of infection or stabilization of disease without further progression on clinical examination or on radiological scans. Response was defined as “unfavorable” if there was progression of disease on scans or appearance of new symptoms or signs suggestive of extension of disease. The response to treatment was assessed at 8 weeks using clinical, endoscopic, and radiological findings.

Outcome at the end of treatment was defined as complete resolution of clinical symptoms and signs of disease along with stabilization on radiological scans.

### 2.4. Ethical considerations

Approval for analyzing the hospital data was taken from the Institutional Review Board (IRB).

### 2.5. Statistical analysis

The data collected was entered in MS excel and was subjected to analysis using Statistical Package for Social Sciences (SPSS) version 28.0. Descriptive tabulations and frequency tables were derived. The continuous variables were presented as mean  $\pm$  SD or median and the categorical variables were mentioned as proportions or percentages (%). The association was calculated between the qualitative variables using Chi-square test or Fisher's exact test after testing for the normality of the quantitative variables. The normally distributed quantitative data between groups were compared using one way ANOVA. A *p* value of <0.05

was considered as statistically significant.

### 3. Results

A total of 25 patients were identified who were treated with a combination of amphotericin B and oral potassium iodide along with surgical debridement.

#### 3.1. Patient characteristics and predisposing factors

The age of the patients ranged from 34 to 77 years with a mean age of 53.48 years (median: 53 years). The male to female ratio was 1.27:1. Eighteen patients (72%) were known cases of diabetes with an average disease duration of 86.95 months.

All patients had history of COVID-19 infection in the last 6 weeks. The duration between the diagnosis of COVID-19 and mucormycosis was 23.48 days (median: 22 days) with mean chest CT severity score of 12.36 (median: 12, range: 7–21). All patients had history of intake of oral steroids for COVID-19 infection. Highest mean dose of steroid used daily was 86.39 mg of prednisolone equivalent whereas the mean duration was 15.96 days. Intake of injectable steroid was reported by 14 patients

**Table 2**  
Patient characteristics and predisposing factors in the study group.

Feature	Factor	Number (percentage) n = 25
Age	Mean	53.48 years
	Range	34–77 years
Gender	Male	14 (56%)
	Female	11 (50%)
	Male:Female	1.27:1
Diabetes	<i>Diabetes</i>	
	Known case	18 (72%)
	Post COVID DM	1 (4%)
	On admission	6 (24%)
	Duration of diabetes	86.95 months
	Average blood sugar levels	239.64 mg/dL
	Range	100–485
	Controlled	8 (32%)
	Poorly controlled	17 (68%)
	<i>Treatment</i>	
	Insulin	22 (88%)
	Oral HA	1 (4%)
	None	2 (8%)
	H/O ketoacidosis	6 (24%)
History of COVID-19	Positive	25 (100%)
	Duration between COVID diagnosis & first symptom of mucormycosis	23.48 days
	CT score (Mean)	12.36
	Range	7–21
	Mild	7
	Moderate	11
	Severe	7
	Hospitalization	20 (80%)
	No of days in ward for those admitted	9.3 days
	ICU admission	3 (12%)
	Oxygen support	14 (56%)
	Mechanical ventilation	1 (4%)
	Steroid received	25 (100%)
	<i>Type of steroid</i>	
	Methylprednisolone	12 (48%)
	Prednisolone	3 (12%)
	Dexamethasone	10 (40%)
Mean of highest dose of steroid (mean) in prednisolone equivalent	83.39 mg	
Range	7.5–426.88 mg	
Total duration of steroid use (mean)	15.96 days	
Range	4–40 days	
Use of IV steroids	14 (56%)	
Current symptoms of COVID-19	4 (16%)	
COVID-19 report on presentation		
Positive	2 (8%)	
Negative	23 (92%)	

(56%). Patient characteristics and predisposing factors are depicted in [Table 2](#).

#### 3.2. Clinical, radiological, and mycological characteristics

The most common presenting symptom was facial swelling reported by nine patients. Majority of patients had more than one presenting complaint. Eye symptoms in the form of redness and swelling of eye, blurring of vision was reported by 44% of patients and were the presenting symptom in 4 patients.

Most common finding on CT scan was involvement of the maxillary sinus followed by ethmoid, frontal, and sphenoid sinuses ([Fig. 1](#)). However, in some cases, involvement of the infraorbital rim was also seen. Orbital involvement on MRI was seen in 11 patients (44%) whereas CNS involvement ([Fig. 2](#)) was seen in 6 patients (24%). One patient had disseminated mucormycosis involving the gastrointestinal tract with lesion involving the greater curvature of stomach. Cutaneous involvement was seen in one patient in the form of ulceration and necrosis over the cheek and left ala of nose ([Figs. 3, 4](#)).

Based on the diagnostic features and criteria mentioned in [Table 1](#) the diagnosis of mucormycosis was “proven” in 22 patients (88%) and “probable” in 3 patients (12%).

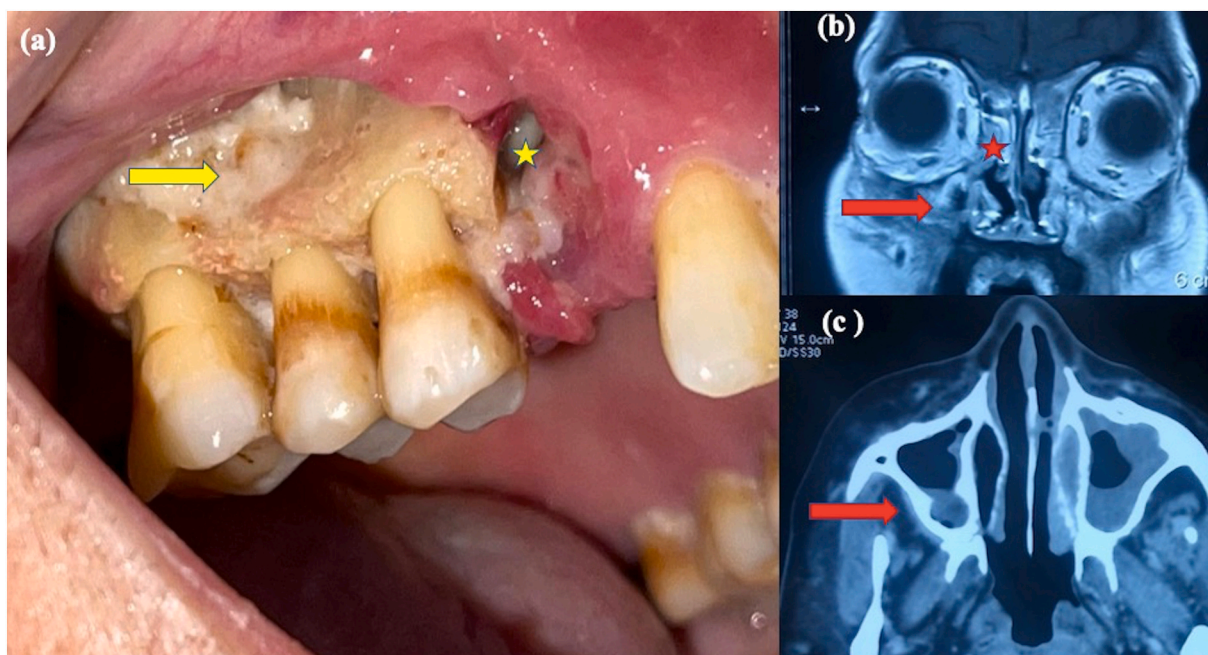
Mucosal biopsy with special stains was diagnostic in 22 patients (88%) whereas direct microscopy on KOH mount showed fungal hyphae in 17 patients (68%). Culture was positive in 13 patients (52%) with *Rhizopus arrhizus* as the predominant species isolated in 8 patients. Clinical and mycological characteristics of the patients are depicted in [Table 3](#).

Synergism between amphotericin B and potassium iodide against *Mucorales* was evaluated using checkerboard broth microdilution assay. In this two-fold concentrations of amphotericin B (0, 0.3–16 µg/mL) were put up horizontally and that of KI (0, 16–1024 µg/mL) vertically giving rise to 88 permutations of the two compounds. These combinations were evaluated against *Rhizopus arrhizus* isolates (n, 5). It was found that KI didn't exhibit inherent *in-vitro* activity against *R. arrhizus* (MIC > 1024 µg/mL), whereas the MIC of amphotericin B alone was in the range of 0.25–0.5 µg/mL. In all the 5 isolates tested, the MIC of amphotericin B was not potentiated by KI at all the seven concentrations tested and remained static at 0.25–0.5 µg/mL irrespective of the concentration of KI suggesting that there was no synergy in the *in-vitro* activity of amphotericin B and potassium iodide.

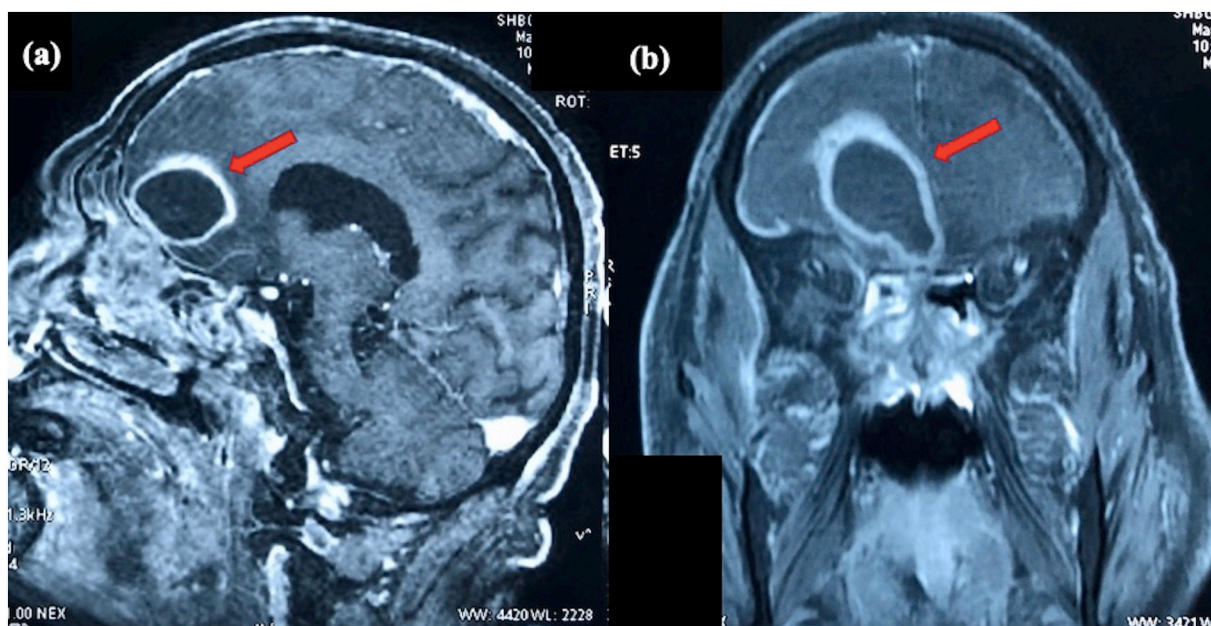
#### 3.3. Therapeutic intervention

FESS with debridement was performed in all patients. Total orbital exenteration ([Fig. 5](#)) by the oculoplastic surgeon was done in 6 patients (24%). Maxillectomy ([Figs. 6, 7](#)) was done in 6 (24%) patients. Six patients (24%) required an alveolectomy in second week of treatment after a first stage debridement. Alveolar involvement was confirmed by Cone-beam computed tomography (CBCT) prior to surgery. One patient (4%) underwent a craniotomy for frontal lobe involvement ([Fig. 2](#)). All patients were started on intravenous amphotericin B along with saturated solution of potassium iodide given orally in the form of drops. Twenty-four patients received liposomal amphotericin B whereas one patient received amphotericin B deoxycholate due to non-availability of former. Dose of amphotericin used was 4–5 mg/kg/day for rhino-orbital disease and 7 mg/kg for those with cerebral involvement. The mean daily dose used in our patients was 268 mg with a range of 250–400 mg. The mean duration of amphotericin treatment was 9.52 days. Four patients received retrobulbar injections of amphotericin B in addition to systemic therapy.

All patients were started on SSKI solution at a dose of 10 drops three times a day which was increased to 15 drops TDS over the next 5 days depending on the tolerability. Twenty-one patients (84%) received 15 drops TDS whereas 4 patients had to be continued on 10 drops TDS. SSKI had to be stopped prematurely in 2 patients (8%). The reason for



**Fig. 1.** 53-year-old female with mucormycosis (a) Clinical image showing erosion of right upper alveolus with loosening of teeth (yellow arrow) & granulation tissue with pus forming sinus (yellow star) (b) Contrast enhanced MRI scan (coronal view) showing ethmoid sinusitis (red star) with preserved periorbital fat & medial rectus muscle along with maxillary sinusitis (red arrow) (c) Axial CT scan picture showing bilateral maxillary sinusitis (red arrow). (For interpretation of the references to colour in this figure legend, the reader is referred to the web version of this article.)



**Fig. 2.** Contrast enhanced MRI scan of a patient with cerebral involvement. Sagittal (a) and coronal (b) view show extension of right fronto-ethmoid soft tissue mass eroding through the cribriform plate extending intracranially into right basi-frontal region with thick walled peripherally enhancing altered signal intensity lesion with significant perilesional edema.

discontinuation was gastrointestinal intolerance and raised TSH. These two patients received only posaconazole in maintenance phase.

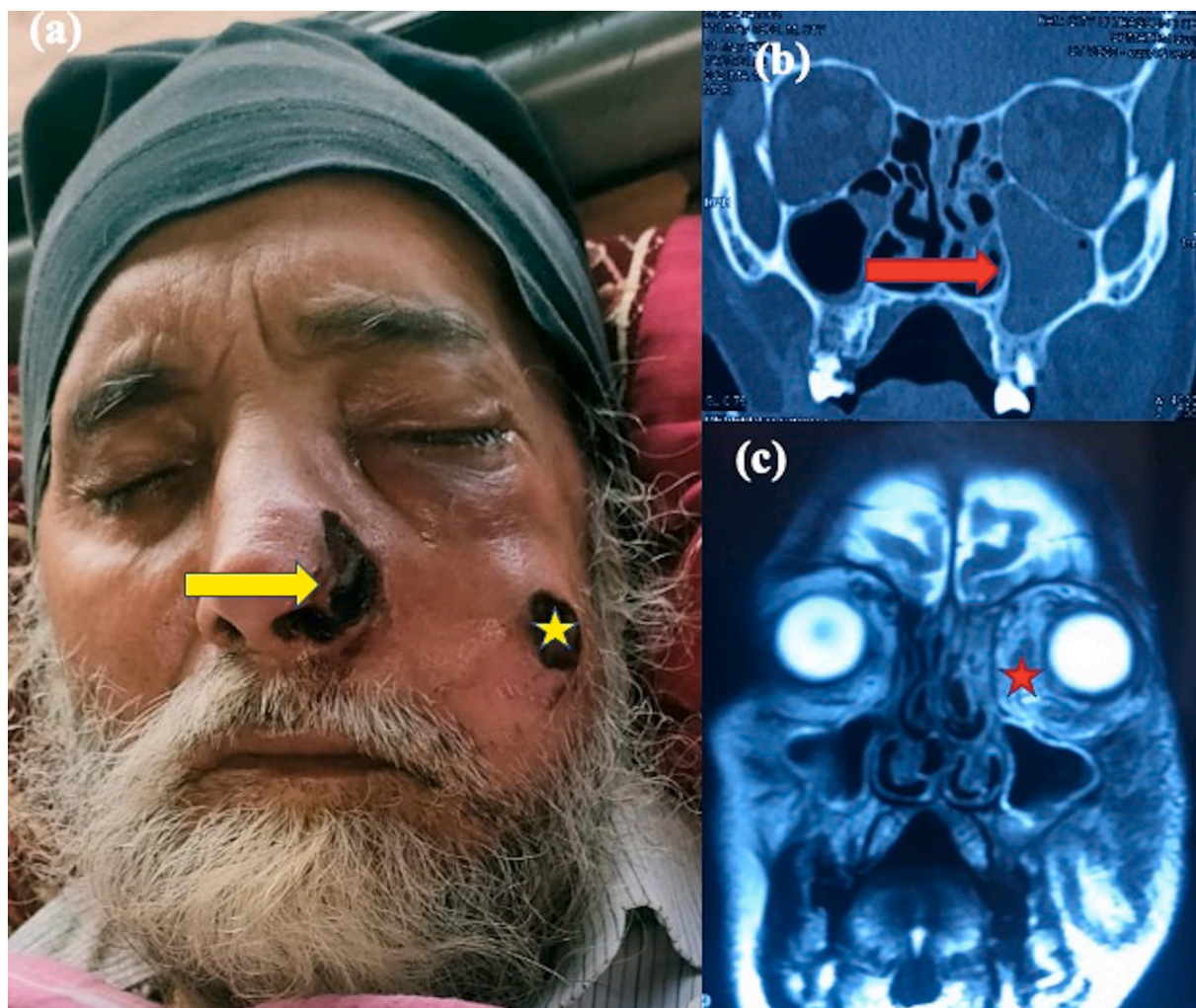
Following the intensive phase with amphotericin and KI, 24 patients were put on maintenance treatment with oral posaconazole 300 mg BD for day 1 followed by 300 mg OD for a period of 3 months. One patient died in intensive phase due to underlying lung disease. The therapeutic intervention and outcome of patients in the study group are depicted in [Table 4](#).

KI was continued at the maximum tolerated dose for a duration of 16

weeks. Posaconazole had to be discontinued in one patient due to worsening of underlying chronic liver disease (CLD). This patient was given only SSKI in the maintenance phase.

#### 3.4. Outcome and mortality, factors affecting outcome

The outcome of treatment was assessed at week 8 of treatment and at the end of treatment ([Figs. 3 & 4, 8 & 9](#)). Four patients (16%) died with an average duration of 22.2 days after diagnosis of disease. The cause of



**Fig. 3.** Clinical & radiological images of a 60-year-old male with mucormycosis and skin involvement (a) Clinical image showing black necrotic eschar formation on the lateral border of nose involving ala (yellow arrow) & cheek (yellow star) (b) CT scan of paranasal sinuses (coronal view) showing left maxillary sinusitis (red arrow) (c) Contrast enhanced MRI scan (coronal view) showing alteration of periorbital fat with edematous left medial rectus muscle (red star) depicting disease infiltration. (For interpretation of the references to colour in this figure legend, the reader is referred to the web version of this article.)

death was underlying COVID-19 pneumonia in 2 patients, renal failure with septicemia in one patient and post-surgical pulmonary embolism in another patient. However, none of the patients died due to mucormycosis.

All 21 patients who survived had stabilization of disease at week 8 of treatment. These patients were cured of disease at the end of treatment as assessed clinically, on endoscopic examination and MRI scans. The patient with disseminated mucormycosis responded well to the combination treatment with disappearance of the gastrointestinal lesion as assessed on serial upper gastrointestinal endoscopy. Few patients (33%) had insignificant post-surgical inflammatory edema on MRI scans. Patients with cosmetic defects/alveolectomies/orbital exenteration are planned for reconstruction procedures with plastic surgeons for implants and prosthodontics. Factors that significantly affected outcome were eye involvement and CNS involvement on initial presentation. The Kaplan Meier Curve for survival probability is shown in Fig. 10. The survival curves illustrate that there is no difference in overall survival rate at 16 weeks as compared to baseline based on severity of the COVID illness at the end of 16 weeks.

### 3.5. Adverse effects

Seven patients (28%) developed hypokalemia due to treatment with

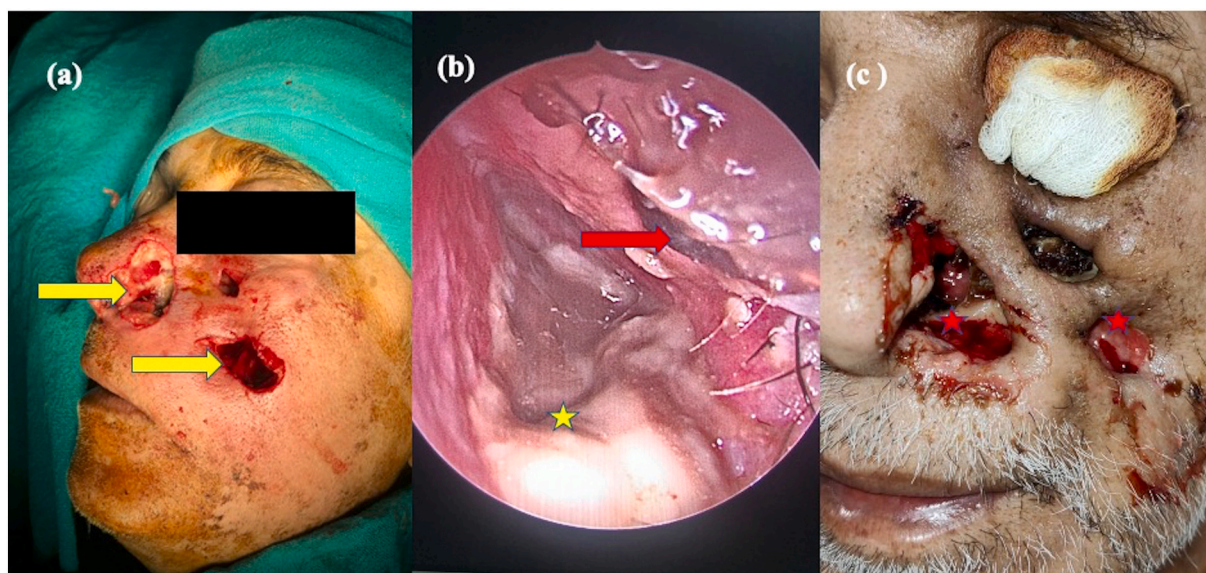
amphotericin which was managed with potassium supplementation whereas 1 developed nephrotoxicity manifested as raised serum creatinine.

Three patients developed gastric side effects due to SSKI manifested as diarrhea. Out of these three patients, 2 were continued with reduced dose and managed symptomatically whereas 1 patient developed severe symptoms due to which KI had to be discontinued. One patient developed watering of eye that subsided with continued treatment.

## 4. Discussion

The precipitous situation of paucity of L-AMB and the spike in cases of mucormycosis was the primary reason for using the adjunctive therapy with SSKI. Being a retrospective data, we can compare this with the existent data of the dose and duration of L-AMB. The combination therapy along with surgical debridement led to a favorable outcome in 84% of our patients. While mortality was seen in 16% patients, the main cause of death was underlying COVID-19 pneumonia (2 patients), septicemia due to hospital acquired infection (1 patient) and pulmonary embolism (1 patient). Unexpectedly, none of our patients died due to mucormycosis. Factors that significantly affected outcome were eye and CNS involvement on initial presentation.

The demographic profile of our patients was consistent with other



**Fig. 4.** Post debridement, endoscopic picture & healed facial sinuses of patient depicted in Fig. 3(a) Intraoperative image after extensive debridement from nose & cheek (yellow arrow) showing loss of skin (post necrosis) (b) endoscopic picture of left nasal cavity showing necrotic tissue on the lateral nasal wall (red arrow) with slough present on the nasal cavity floor (yellow star) (c) Clinical image after 4 weeks of debridement and medical treatment with amphotericin and SSKI showing healthy granulation tissue (red star). (For interpretation of the references to colour in this figure legend, the reader is referred to the web version of this article.)

**Table 3**

Clinical and mycological characteristics of patients with ROCM.

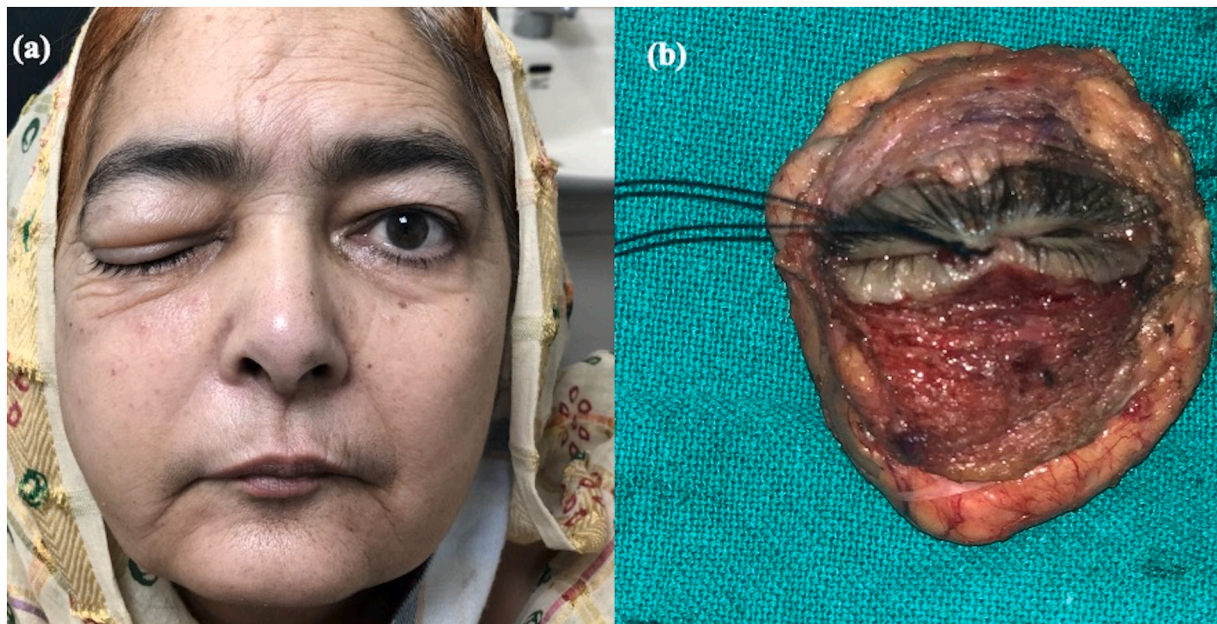Feature	Characteristics	Number (%)
Presenting symptoms	Facial swelling	9 (36%)
	Headache	9 (36%)
	Nasal blockage/discharge/epistaxis	5 (20%)
	Dental pain/pain in jaw	8 (32%)
	Facial pain/stiffness/numbness	4 (16%)
	Eye symptom	4 (16%)
	Discoloration in nose/mouth	2 (8%)
Eye symptoms	Present	11 (44%)
	Absent	14 (56%)
Biopsy	Diagnostic (hyphae)	22 (88%)
KOH	Positive	17 (68%)
	• Aseptate hyphae	14
	• Septate hyphae	1
Culture	• Both aseptate and septate	2
	Negative	8 (32%)
	Positive	13 (52%)
	• <i>Rhizopus arrhizus</i>	8
	• <i>Rhizopus homothallicus</i>	2
Orbital involvement	• <i>Rhizopus arrhizus</i> + <i>Aspergillus flavus</i>	3
	Negative	12 (48%)
	Present	11 (44%)
CNS involvement	Absent	14 (56%)
	Present	6 (24%)
Diagnosis	Absent	19 (76%)
	Possible	0
	Proven	22 (88%)
	Probable	3 (12%)

studies that have also reported a male predominance. The mean age was 53.48 years emphasizing the fact that ROCM occurs in old age. 72% of our patients had prior history of diabetes with an average duration of around 7.1 years whereas 6 patients were diagnosed with diabetes after admission for mucormycosis. Majority of our patients had poorly controlled blood sugar levels warranting use of insulin. DM is the single most common risk factor in patients with mucormycosis, especially ROCM. Hyperglycemia causes inhibition of neutrophil chemotaxis, phagocytosis and impairs intracellular killing of pathogen. It also causes upregulation of GRP78 (glucose regulated protein) receptors in cells that are responsible for entry of *Mucorales* in endothelial cells [7]. In the

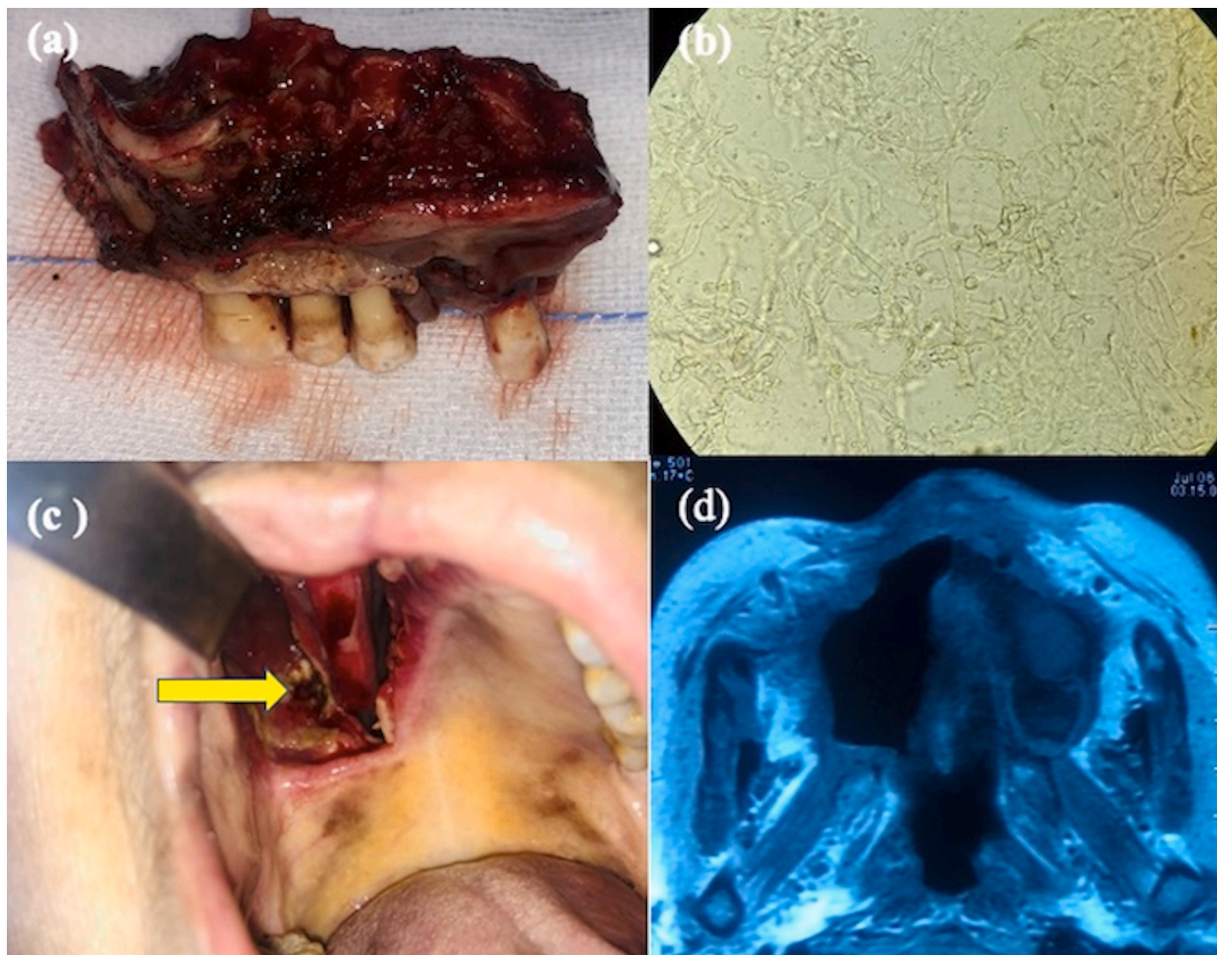
largest Indian study done to assess the risk factors for mucormycosis in India, it was found that diabetes was seen in 82.5% patients with ROCM [8]. Additionally, India has 77 million people with diabetes, making the prevalence of mucormycosis 80 times higher than in other parts of the world [9]. Also, patients with COVID-19 are predisposed to acute diabetes and DKA due to viral induced damage of pancreatic islets as the latter has high expression of angiotensin-converting enzyme 2 receptors [10]. Besides, the cytokine storm associated with COVID-19 leads to increased insulin resistance. The use of corticosteroids worsens the glucose homeostasis in COVID-19. All our patients reported use of oral or intravenous steroids for COVID-19 with a mean dose of 83.39 mg of prednisolone equivalent and a mean duration of 15.96 days. Though guidelines mention use of methylprednisolone and dexamethasone in selected cases of moderate to severe infection, these have been used rampantly in India not only by the physicians as a blanket protocol to reduce hospital stay and mortality but also self-used by the patients without prescription. A study showed that a cumulative prednisolone dose of greater than 600 mg (or 2–7 g of methylprednisolone) given a month before onset of infection predisposes cancer patients to infection by *Zygomycetes* [11]. Corticosteroids have pleiotropic effects on immunity and impair the body's defense (macrophages and neutrophils) against invasive fungal infection [12]. Apart from steroid use, there are other factors that make COVID-19 patients more susceptible to mucormycosis. There is immune dysregulation in COVID-19 with reduced number of T cells. Further, there is alteration of iron metabolism in severe infection leading to a hyper-ferritinemic state [13]. This intracellular iron causes tissue damage by generating reactive oxygen species. Iron is an essential element for growth of the fungus and studies have found that increased serum levels of unbound iron predispose patients to mucormycosis [14,15].

It has also been postulated that endothelial injury seen in severe COVID-19 infections predisposes patients to mucormycosis as endothelial adhesion and penetration are critical steps in entry of infection [16]. Angioinvasion results in ischaemic necrosis of tissue and prevents delivery of antifungal agents to the site of infection. Hence, debridement forms an essential part of management.

80% of our patients reported hospitalization due to COVID-19. Use of non-sterile products and various medical devices and procedures can lead to health care associated mucormycosis though the exact

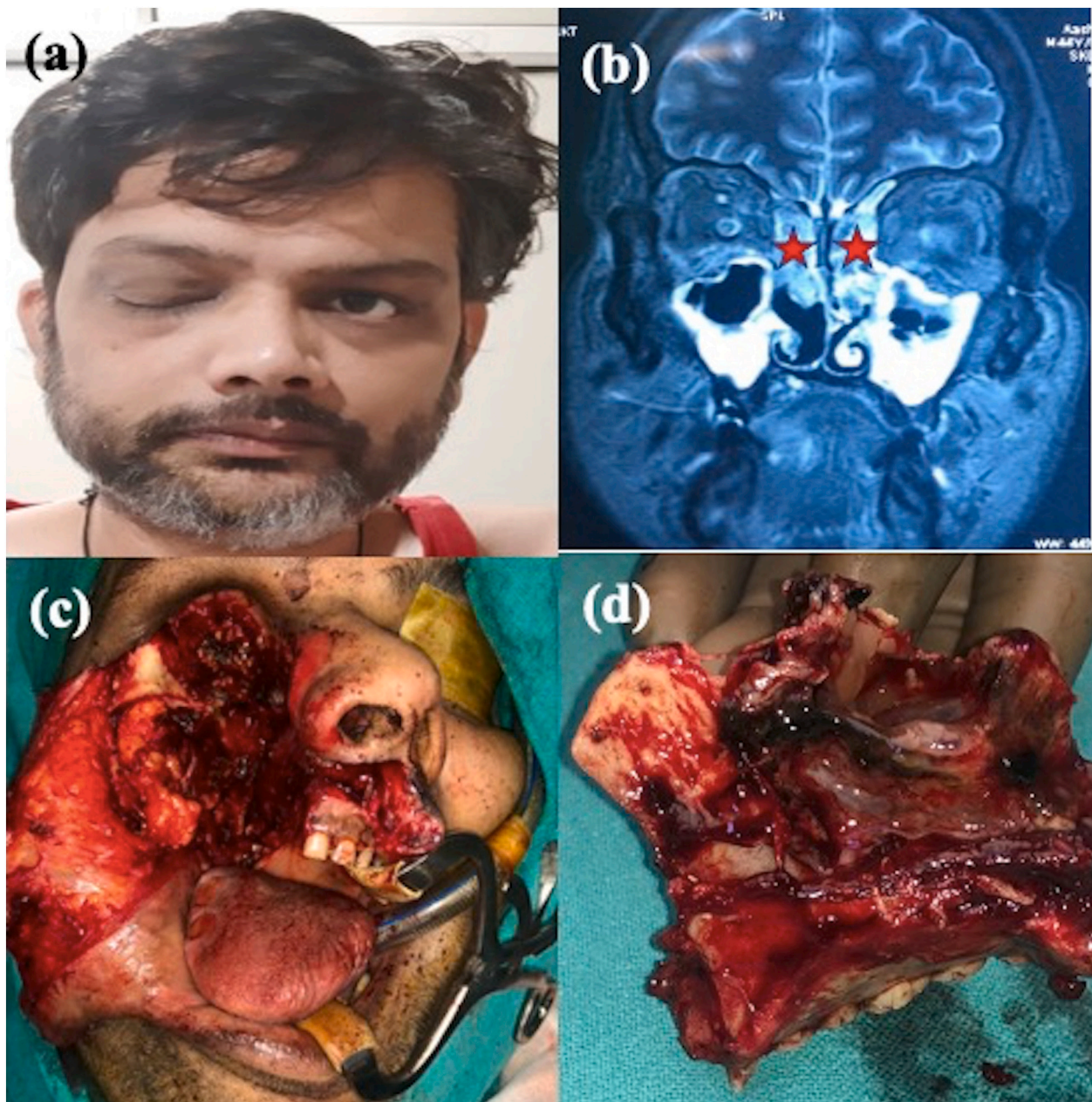


**Fig. 5.** A 62-year-old female with mucormycosis (a) Clinical image showing complete ptosis of right eye & swelling of the eyelid (b) Complete enucleated specimen of left eye with periorbital fat.



**Fig. 6.** Clinical, radiological & microscopic images of patient with ROCM (a) Post-operative inferior maxillectomy specimen showing black necrotic tissue with eroded upper alveolus and loosely attached teeth (b) Microscopic image showing aseptate hyphae of *Rhizopus* with 90 degree angle branching (40×) (c) 10 days post-operative clinical image showing well healed margins (yellow arrow) (d) Post-operative contrast enhanced MRI scan showing absence of disease on right side of maxilla. (For interpretation of the references to colour in this figure legend, the reader is referred to the web version of this article.)





**Fig. 7.** A 43-year-old male with mucormycosis (a) Clinical image showing complete ptosis of right eye with swelling (b) Contrast enhanced T2 weighted coronal MRI scan showing involvement of bilateral ethmoid sinuses (red star) with abutment of right medial rectus muscle depicting disease infiltration (c) Intraoperative image of patient showing right total maxillectomy with orbital exenteration via Weber Ferguson incision (d) Post-operative sagittal view of maxilla showing necrotic black mucosa. (For interpretation of the references to colour in this figure legend, the reader is referred to the web version of this article.)

correlation is difficult to establish [17].

Two of our patients had concurrent COVID-19 and ROCM. One of these patients developed septicemia with *Klebsiella sp* isolated on blood culture and succumbed to the illness. He received KI for only 10 days. The other patient was a 44-year-old male with cerebral involvement who developed cerebrovascular accident and needed ICU admission with mechanical ventilation. KI had to be discontinued in this patient.

The above findings reiterate that the unprecedented rise in cases of mucormycosis seen in India was subsequent to the second wave of pandemic caused by B.1.617 variant (delta variant) of SARS-CoV-2. This variant was more infectious and virulent warranting use of systemic steroids which in turn led to uncontrolled sugar levels. Panic and injudicious use of steroids was compounded by the deficient medical care due to surge of patients in hospitals and nationwide lockdown.

Facial swelling was the most common presenting complaint in our cohort of patients and involvement of the maxillary sinus was the most common finding on CT scans.

Thickening of the mucosa of nasal and paranasal sinuses with irregular patchy enhancement is an early sign of ROCM on CT scans. The absence of these findings has a strong negative predictive value for ROCM [3]. MRI should be done in cases where brain or eye involvement is suspected as it has greater sensitivity for determining extent of disease, soft tissue involvement and intracranial spread. Imaging can also be used to monitor treatment response. We performed MRI scans at 2-week interval in our patients. However, resolution on imaging lags clinical resolution. Hence, clinical improvement is a better indicator of treatment response or failure.

One of our patients had cutaneous involvement due to mucormycosis

**Table 4**  
Therapeutic intervention and outcome in patients.

Feature	Characteristics	No (%)
Surgery	FESS with debridement	25 (100%)
	Maxillectomy	6 (24%)
	Alveolectomy	6 (24%)
	Craniotomy	1 (4%)
	Orbital exenteration	6 (24%)
Medical treatment amphotericin	Mean daily dose	268 mg
	Range	250–400 mg
Potassium iodide	Dose in mg/kg	4.12 mg/kg
	Duration	9.52 days
	Mean dose	2.57 g/day
	Duration	4 months
	15 drops TDS	21 (84%)
Side effects of amphotericin	10 drops TDS	4 (16%)
	Prematurely stopped in 2 patients (GI side effect: 1, raised TSH with cerebral mucormycosis requiring mechanical ventilation:1)	2 (8%)
	Hypokalemia	7 (28%)
Side effects of KI	Nephrotoxicity	1 (4%)
	GI side effects	3 (12%)
Maintenance treatment*	Watering of eyes	1 (4%)
	Raised TSH	1 (4%)
	Posaconazole + KI	21
Response at 8 weeks	Posaconazole alone	2
	KI alone	1
	Favorable	21 (84%)
Outcome/end of treatment	Unfavorable (mortality)	4 (16%)
	Cause of death#	
	Days after diagnosis	22.2 days
Outcome/end of treatment	Cured	21(84%)
	Death	4 (16%)

\* One patient died in the intensive phase of disease.

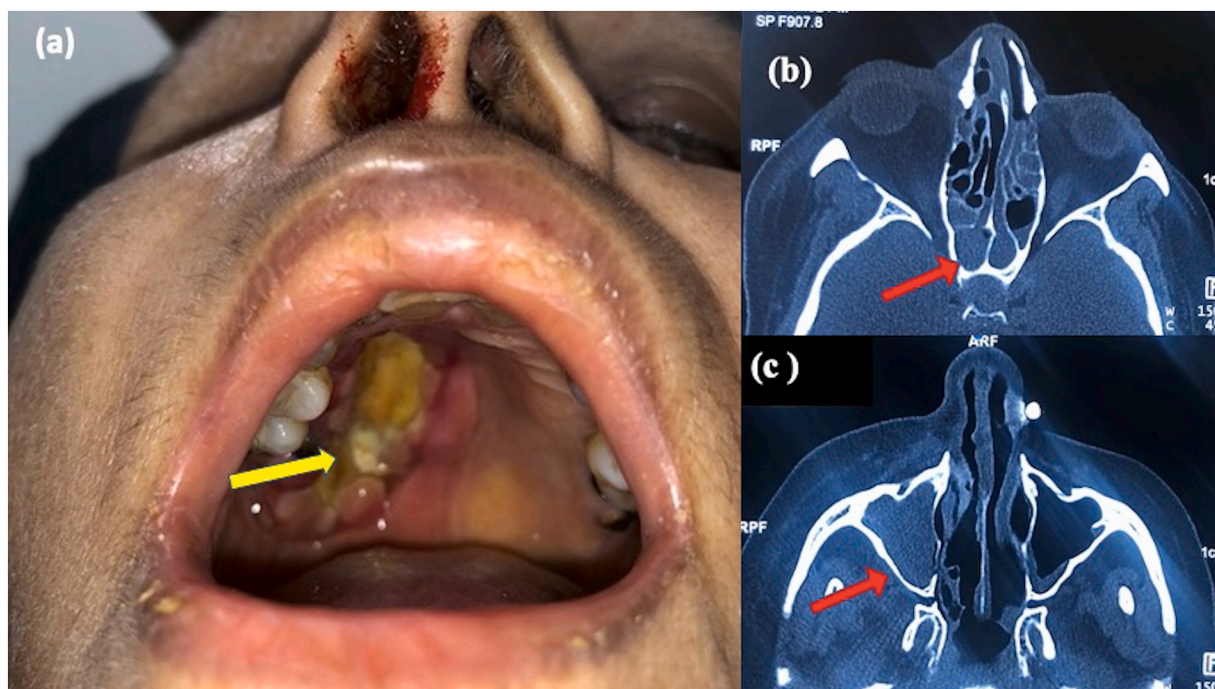
# COVID-19 pneumonia (2 patients), renal failure and septicemia (1 patient), pulmonary embolism (1 patient).

and responded favourably to therapy. One patient had disseminated disease with involvement of gastrointestinal tract and responded well. *Rhizopus arrhizus* was the predominant species in our study which is in concordance with other studies [18]. We also found co-infection with *Aspergillus flavus* in 3 patients.

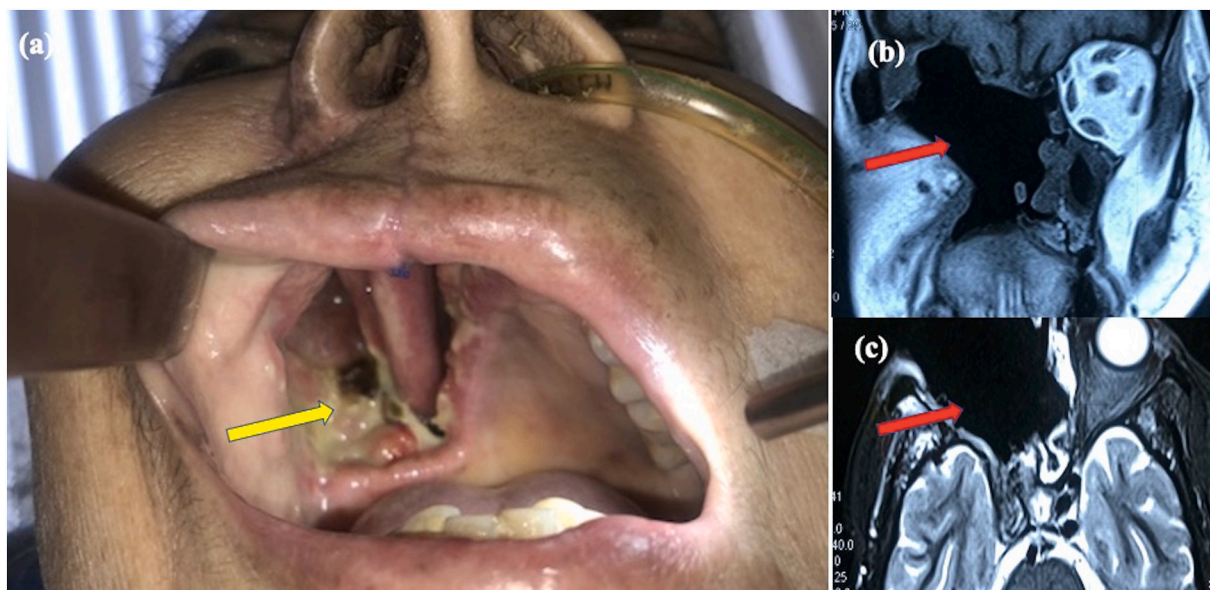
FESS with debridement was done in all our patients along with medical treatment. The ECMM guidelines recommend early surgical treatment in all cases of mucormycosis. Debridement of infected tissues results in higher survival rates and should be repeated as required depending on clinical signs and response to treatment. Orbital exenteration was performed in 5 patients based on indications. Maxillectomy was performed in 6 patients due to involvement of maxilla diagnosed on CT scans. Four patients needed an alveolectomy in second week of disease.

We chose to treat our patients with amphotericin B as per the ECMM guidelines that recommend use of liposomal amphotericin B in a dose of 5–10 mg/kg/day in all patterns of organ involvement. However, the mean dose in our patients was less than 5 mg/kg due to limited supply of the drug. Here it is important to emphasize that while polyenes are the preferred backbone agent there are wide variations in the dose and duration of therapy. Preclinical pharmacokinetics/pharmacodynamics studies in murine models of pulmonary mucormycosis that simulated human dosing have suggested that ABLC at 5 mg/kg/day or L-AMB at 10 mg/kg/day results in rapid antifungal accumulation in the lung, reduced fungal burden, and improved survival [19]. But these models do not routinely assess nephrotoxicity of higher-dose L-AMB regimens. Both clinical and observational studies have suggested an early “window” of 10 to 14 days when nephrotoxicity risk is lowest with L-AMB, which may be shortened in patients receiving concomitant nephrotoxic agents or aggressive diuresis [20–22].

In one of the few randomized trials that compared standard doses of L-AMB (3 mg/kg/day) to a higher dose-regimen (10 mg/kg/day for 14 days, then 3 mg/kg/day) for invasive aspergillosis, patients randomized to the higher-dosed L-AMB regimen failed to achieve higher response rates but experienced significantly higher rates of nephrotoxicity and severe hypokalemia [23]. This has been reiterated by another study



**Fig. 8.** Clinical & radiological images of a 53-year-old female with ROCM (a) Clinical picture of palate showing necrosis & eschar formation on the right side of hard palate reaching till midline (yellow arrow) (b) Axial CT scan of paranasal sinuses demonstrating ethmoid & sphenoid sinusitis (red arrow) (c) Axial CT scan showing right maxillary sinusitis (red arrow). (For interpretation of the references to colour in this figure legend, the reader is referred to the web version of this article.)



**Fig. 9.** Post-operative clinical images of patient shown in Fig. 1 showing disease clearance (a) Clinical image taken 1 week after inferior maxillectomy showing granulating margins (yellow arrow) (b) Contrast enhanced MRI scan (coronal view) showing clearance of disease with orbital exenteration & right maxillectomy (red arrow) (c) Contrast enhance MRI scan (axial view) showing absence of any disease post-surgery. (For interpretation of the references to colour in this figure legend, the reader is referred to the web version of this article.)

where the authors used high dose L-AMB (10 mg/kg/day) in 40 patients with mucormycosis along with surgical debridement in 71% patients [24]. While the response rate at 4 weeks was 36%, there was doubling of serum creatinine in 40% of patients leading to dose reduction in seven patients. Thus the key principle is not to use L-AMB higher than 5 mg/kg/day and switch therapy to a triazole therapy after the first 1 to 2 weeks of therapy.

Notably data from the working group in zygomycosis of the European confederation of medical mycology (ECMM) of 230 patients found that in those who received it as the only antifungal medication, the survival rate was 68% [25]. In patients who were cured, the median duration of treatment was 55 days (range 14–169 days). Compared to this, the mean dose and duration of amphotericin B in our study were 4.12 mg/kg and 9.52 days respectively, which is less than the ECMM guidelines that recommend use of amphotericin B at a dose of 5 mg/kg/day for 3–6 weeks in the intensive phase [26]. The use of SSKI is the most likely reason for this efficacy profile of L-AMB and a survival rate of 84% seen in our work.

In recent years, promising combination-therapy strategies have been described in preclinical models and in retrospective and open label case series to obviate long term use of LAMB. Despite being one of the largest pharmaceutical hubs in the world, India faced an acute shortage of amphotericin due to the exponential demands leading to delay in treatment. A delay of more than 6 days is associated with twofold increase in mortality at 12 weeks [27]. This prompted us to use potassium iodide. ECMM/ISHAM recommendations for management of COVID-19 associated mucormycosis in low- and middle-income countries specifies use of posaconazole and isavuconazole in cases of non-availability of amphotericin [28]. However, the MIC values of isavuconazole for *Mucorales* species are higher compared to amphotericin and data on CNS penetration are limited [29]. Moreover, the cost of these azole drugs is a major deterrent in our country.

KI has been used in various fungal infections including sporotrichosis, conidiobolomycosis and subcutaneous zygomycosis but its use in mucormycosis is limited to few case reports [5,6,30,31]. The direct antifungal effect has not been proven yet. Our own data found that there was no synergism between amphotericin B and KI against *Mucorales* and KI did not exhibit inherent *in-vitro* activity against *R. arrhizus* in checkerboard broth microdilution assay. The MIC of amphotericin was

not potentiated by KI at seven concentrations tested thus suggesting interaction with the immune system as the possible mechanism for fungal clearance. A plausible explanation is that KI enhances the phagocytosis potential of the host cells and modulates the neutrophilic activity [32]. Also, the drug has a profound activity in certain disorders with chronic inflammation like erythema nodosum where it interacts with the host immune response and exerts an anti-inflammatory effect [33].

Here it must be pointed out that while an ideal situation would have been an RCT, neither AmB nor lipid amphotericin B derivatives have ever been, or will ever be, tested against placebo in a monotherapy randomized trial of mucormycosis. Also, the greatest barriers to conducting a phase III, randomized, double-blinded, placebo-controlled, combination-therapy study for mucormycosis are financial and logistical, owing to the relative rarity of the disease.

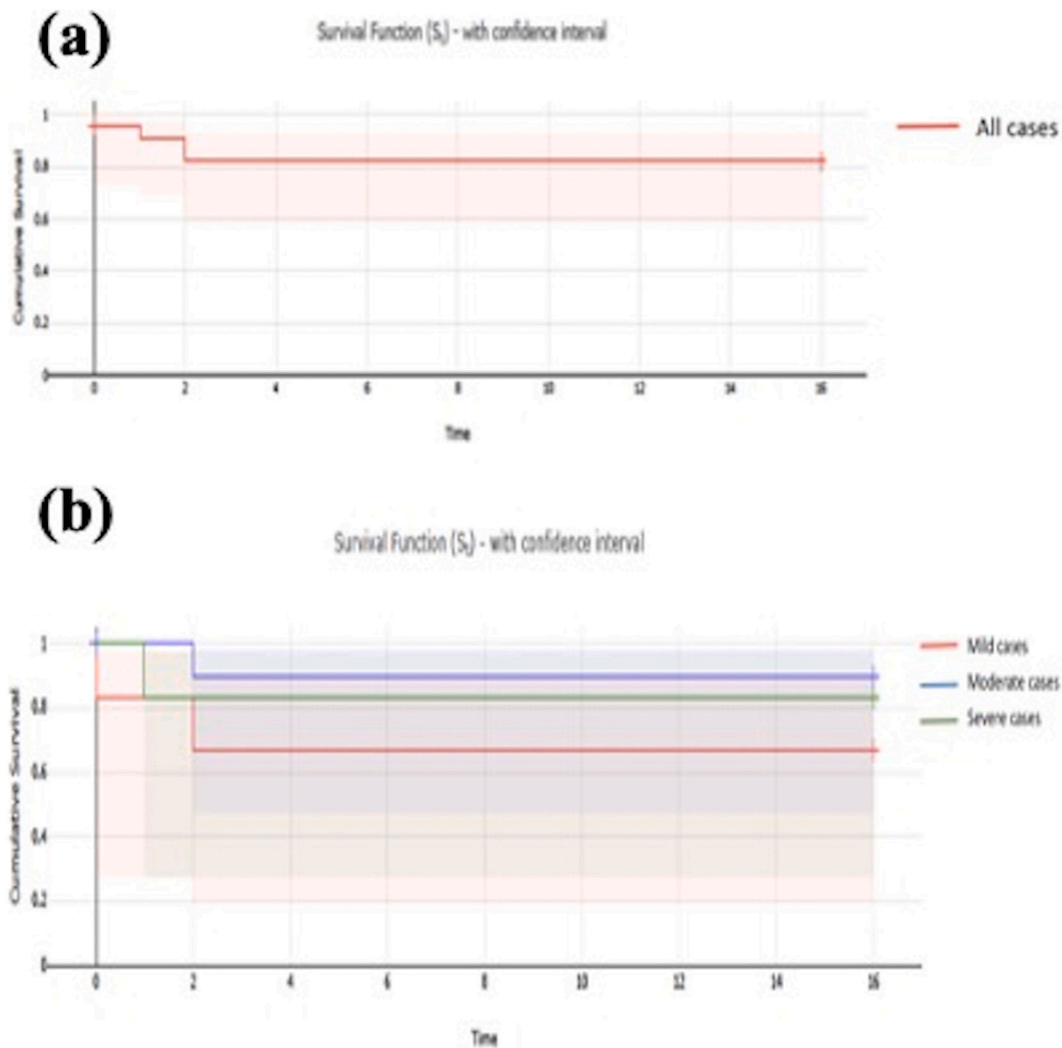
While a plethora of drugs have been tried in combination (Echinocandins, deferasirox, posaconazole, isavuconazole, granulocyte transfer, hyperbaric oxygen, and interferon) we observe that potassium iodide, with its remarkably low cost and safety profile, makes it a potential adjuvant drug that may help achieve the twin benefits of shortened duration and dose of LAMB.

## 5. Limitations

Our data is limited to a single centre and may not be representative of entire population. We could not assess the strength of association of risk factors involved in ROCM due to absence of a control group of patients with mucormycosis and without COVID-19 infection. Given the morbidity and mortality of disease, such a plan will be impractical and unethical.

## 6. Conclusion

SSKI, with its remarkably low cost and safety profile, makes it a potential adjuvant drug that may help achieve the twin benefits of shortened duration and dose of LAMB.



**Fig. 10.** Figure shows the bivariate survival analysis by the Kaplan-Meier method to study the effect of COVID-19 severity on favorable outcome of patients with mucormycosis treated with the combination treatment for 16 weeks. The overall favorable outcome rate was 82.2%; in the cases, and there were 4 events as death (within 1 week, at 1 week and at 2 weeks) and 1 censored case (within 1 week of the study duration). The survival curves illustrate that there is no difference in overall survival rate at 16 weeks as compared to baseline based on severity of the COVID illness post mucormycosis at the end of 16 weeks.

#### CRediT authorship contribution statement

DR SUMIT MRIG - Conceptualization, Data curation, Investigation, Methodology, Writing - original draft

DR KABIR SARDANA - Conceptualization, writing - reviewing and editing

DR POOJA ARORA - Conceptualization, Data curation, Writing - original draft, Writing - review & editing

DR VINEET NARULA - Data curation, Investigation.

DR SANDEEP ARORA - Data curation, Investigation.

DR AMRIT KAPOOR - Data curation, Investigation.

DR RITU RAJ BARUAH - Investigation, Resources.

DR POORNIMA SEN - Investigation, Resources.

DR SHWETA AGARWAL - Investigations, Resources.

DR SOUMYA SACHDEV - Data curation, Writing - review & editing

DR ARUN DEWAN - Data curation, Investigation.

DR SANJEET PANESAR - Data curation, Writing - review & editing

Adjunctive use of saturated solution of potassium iodide (SSKI) with liposomal amphotericin B (L-AMB) in mucormycosis achieves favorable response, shortened dose and duration of amphotericin: A retrospective study from a COVID-19 tertiary care center.

#### Funding

No sources of funding.

#### Declaration of competing interest

No conflict of interest.

#### Acknowledgment

We acknowledge Dr. S Rudramurthy, Department of Microbiology, Postgraduate Institute of Medical Education and Research, Chandigarh, India.

#### References

- [1] White PL, Dhillon R, Hughes H, Wise MP, Backx M. COVID-19 and fungal infection: the need for a strategic approach. *Lancet Microbe* 2020;1(5):e196.
- [2] Al-Tawfiq JA, Alhumaid S, Alshukairi AN, et al. COVID-19 and mucormycosis superinfection: the perfect storm. *Infection* 2021;49:833–53.
- [3] Honavar SG. Code mucor: guidelines for the diagnosis, staging and Management of Rhino-Orbito-Cerebral Mucormycosis in the setting of COVID-19. *Indian J Ophthalmol* 2021;69:1361–5.

- [4] Sardana K, Arora P, Goel S, et al. Repurposing super saturated potassium iodide as an adjunctive treatment in mucormycosis: an exposition in a diabetic patient with rhino-orbital disease with cutaneous extension. *Dermatol Ther* 2021;27:e15181.
- [5] Grewal RK, Grewal SS, Zachariah RM. Orbital mucormycosis (phycomycosis) (a survival with amphotericin-B and potassium iodide). *Indian J Ophthalmol* 1985; 33:239–41.
- [6] Nucci M, Engelhardt M, Hamed K. Mucormycosis in South America: a review of 143 reported cases. *Mycoses* 2019;62:730–8.
- [7] Liu M, Spellberg B, Phan QT, et al. The endothelial cell receptor GRP78 is required for mucormycosis pathogenesis in diabetic mice. *J Clin Invest* 2010;120:1914–24.
- [8] Patel A, Kaur H, Xess I, et al. A multicentre observational study on the epidemiology, risk factors, management and outcomes of mucormycosis in India. *Clin Microbiol Infect* 2020;26:944.e9–944.e15.
- [9] Skiada A, Pavleas I, Drogari-Apiranthitou M. Epidemiology and diagnosis of mucormycosis: an update. *J Fungi (Basel)* 2020;6:265.
- [10] Yang JK, Lin SS, Ji XJ, Guo LM. Binding of SARS coronavirus to its receptor damages islets and causes acute diabetes. *Acta Diabetol* 2010;47:193–9.
- [11] Kontoyiannis DP, Wessel VC, Bodey GP, Rolston KV. Zygomycosis in the 1990s in a tertiary-care cancer center. *Clin Infect Dis* 2000;30:851–6.
- [12] Lionakis MS, Kontoyiannis DP. Glucocorticoids and invasive fungal infections. *Lancet* 2003;29:1828–38.
- [13] Perricone C, Bartoloni E, Bursi R, et al. COVID-19 as part of the hyperferritinemic syndromes: the role of iron depletion therapy. *Immunol Res* 2020;68:213–24.
- [14] Ibrahim AS, Spellberg B, Walsh TJ, Kontoyiannis DP. Pathogenesis of mucormycosis. *Clin Infect Dis* 2012;54(Suppl 1):S16–22.
- [15] Boelaert JR, de Locht M, Van Cutsem J, et al. Mucormycosis during deferoxamine therapy is a siderophore-mediated infection: in vitro and in vivo animal studies. *J Clin Invest* 1993;91:1979–86.
- [16] Ibrahim AS, Spellberg B, Walsh TJ, Kontoyiannis DP. Pathogenesis of mucormycosis. *Clin Infect Dis* 2012;54(Suppl 1):S16–22. Suppl 1.
- [17] Rammaert B, Lanternier F, Zahar JR, et al. Healthcare-associated mucormycosis. *Clin Infect Dis* 2012;2012(54 Suppl 1):S44–54.
- [18] Prakash H, Chakrabarti A. Epidemiology of mucormycosis in India. *Microorganisms* 2021;9:1–12.
- [19] RE Lewis ND, Albert G, Liao J, Hou RA, Prince DP, Kontoyiannis D. Comparative pharmacodynamics of amphotericin B lipid complex and liposomal amphotericin B in a murine model of pulmonary mucormycosis. *Antimicrob Agents Chemother* 54: 1298–1304.
- [20] Stanzani M, Vianelli N, Cavo M, Maritati A, Morotti M, Lewis RE. Retrospective cohort analysis of liposomal amphotericin B nephrotoxicity in patients with hematological malignancies. *Antimicrob Agents Chemother* 2017;61. e02651-16.
- [21] Prentice HG, Hann IM, Herbrecht R, et al. A randomized comparison of liposomal versus conventional amphotericin B for the treatment of pyrexia of unknown origin in neutropenic patients. *Br J Haematol* 1997;98:711–8.
- [22] Safdar A, Ma J, Saliba F, et al. Drug-induced nephrotoxicity caused by amphotericin B lipid complex and liposomal amphotericin B: a review and meta-analysis. *Medicine (Baltimore)* 2010;89:236–44.
- [23] Cornely OA, Maertens J, Bresnik M, et al. Liposomal amphotericin B as initial therapy for invasive mold infection: a randomized trial comparing a high-loading dose regimen with standard dosing (AmBiLoad trial). *Clin Infect Dis* 2007;44: 1289–97.
- [24] Lanternier F, Poiree S, Elie C, et al. French mycosis study group. Prospective pilot study of high-dose (10 mg/kg/day) liposomal amphotericin B (L-AMB) for the initial treatment of mucormycosis. *J Antimicrob Chemother* 2015;70:3116–23.
- [25] Skiada A, Pagano L, Groll A, et al. European Confederation of Medical Mycology Working Group on Zygomycosis. Zygomycosis in Europe: analysis of 230 cases accrued by the registry of the European Confederation of Medical Mycology (ECMM) Working Group on Zygomycosis between 2005 and 2007. *Clin Microbiol Infect* 2011;17:1859–67.
- [26] Cornely OA, Alastruey-Izquierdo A, Arenz D, et al. Mucormycosis ECMM MSG global guideline writing group. Global guideline for the diagnosis and management of mucormycosis: an initiative of the European Confederation of Medical Mycology in cooperation with the mycoses study group education and research consortium. *Lancet Infect Dis* 2019;19:e405–21.
- [27] Chamilos G, Lewis RE, Kontoyiannis DP. Delaying amphotericin B-based frontline therapy significantly increases mortality among patients with hematologic malignancy who have zygomycosis. *Clin Infect Dis* 2008;47:503–9.
- [28] Rudramurthy SM, Hoenigl M, Meis JF, et al. ECMM and ISHAM. ECMM/ISHAM recommendations for clinical management of COVID-19 associated mucormycosis in low- and middle-income countries. *Mycoses* 2021;64:1028–37.
- [29] Chowdhary A, Kathuria S, Singh PK, et al. Molecular characterization and in vitro antifungal susceptibility of 80 clinical isolates of mucormycetes in Delhi, India. *Mycoses* 2014;57(Suppl 3):97–107.
- [30] Arora P, Raihan M, Kubba A, Gautam RK. Lymphocutaneous sporotrichosis treated with potassium iodide with development of subclinical hypothyroidism: wolff-chaikoff Effect? *Indian Dermatol Online J* 2017;8:475–7.
- [31] Arora P, Sardana K, Bansal S, Garg VK, Rao S. Entomophthoromycosis (basidiobolomycosis) presenting with "saxophone" penis and responding to potassium iodide. *Indian J Dermatol Venereol Leprol* 2015;81:616–8.
- [32] Shimizu T, Hiruma M, Akiyama M, Kukita A, Tsuru S. Effect of immunization and potassium iodide on polymorphonuclear leukocyte chemiluminescence in experimental murine sporotrichosis. *Mycoses* 1989;32:443–7.
- [33] Sehrawat M, Dixit N, Sardana K, Malhotra P. Exploring the combination of SSKI and topical heparin in a case of erythema nodosum migrans. *Dermatol Ther* 2018; 31:e12610.