

The Use of a Plastic Guide Improves the Safety and Reduces the Duration of Endotracheal Intubation in the Pig

Adrian JANISZEWSKI^{1,4}*, Robert PASŁAWSKI^{1,2}, Piotr SKRZYPCZAK³, Urszula PASŁAWSKA^{1,4}, Andrzej SZUBA^{1,2} and Józef NICPON^{1,4}

¹Regional Specialist Hospital in Wrocław, Research and Development Centre, 51–124 Wrocław, Poland

²Department and Clinic of Internal and Occupational Diseases and Hypertension Medical University, 50–556 Wrocław, Poland

³Department of Surgery, Faculty of Veterinary Medicine, Wrocław University of Environmental and Life Sciences, 50–366 Wrocław, Poland

⁴Department of Internal Diseases with Clinic for Horses, Dogs, and Cats, Faculty of Veterinary Medicine, Wrocław University of Environmental and Life Sciences, 50–366 Wrocław, Poland

(Received 1 August 2013/Accepted 27 May 2014/Published online in J-STAGE 16 June 2014)

ABSTRACT. The successful endotracheal intubation of pigs using the standard orotracheal method is challenging and technically difficult, because of the pig's oral anatomy and the presence of excess tissue in the oropharyngeal region. Hence, the operator, who is usually an anesthetist, requires extensive training in order to successfully perform the procedure in pigs. In this report, we describe a safe and quick method of successful endotracheal intubation in the pig using an 80-cm blunt-tipped plastic vascular catheter, when the pig is placed in ventral recumbency. Specifically, the use of this plastic guide wire shortened the duration of the procedure and reduced the risks of the procedure. Since the use of the guide wire also improves the ease of the procedure, its use will also enable inexperienced operators to perform successful first-time endotracheal intubation of pigs without causing injury.

KEY WORDS: anesthesia, endotracheal intubation, laryngoscopy, swine

doi: 10.1292/jvms.13-0393; *J. Vet. Med. Sci.* 76(10): 1317–1320, 2014

The successful endotracheal intubation of pigs using the standard orotracheal method is challenging and technically difficult in comparison to human and other experimental animals [1, 4], because of the pig's oral anatomy and the presence of excess tissue in the oropharyngeal region. Specifically, visibility of the laryngeal opening is impeded, because of its long snout, the thick fleshy base of its tongue, the angle of the elevation of the soft palate and the descent of the epiglottis [9]. Hence, the operator, who is usually an anesthetist, requires extensive training in order to successfully perform the procedure in pigs. The standard method of orotracheal intubation in pigs requires advancing the tip of the endotracheal tube while visualizing vocal cords using the blade of a laryngoscope. In order to advance the tube, the tube is twisted using a corkscrew action. After passing the tube through the cricoid cartilage, the tube is rotated through an angle of 180 degree and this rotation advances the tube beyond the ventral floor of the larynx and into the trachea [10]. If the pig is not intubated at first attempt, repeated attempts to endotracheally intubate become more difficult, because pigs are very susceptible to laryngospasm and edema of larynx mucosa [5], and moreover, laryngeal perforation during the standard intubation can occur [9].

Another obstacle for successful endotracheal intubation of mature pigs, except for minipigs, is the length of the blade of commercially available laryngoscopes: the blades, even with an attached light source, were not long enough to visualize the epiglottis and the laryngeal opening in order to enable safe and successful insertion of endotracheal tube. These anatomical obstacles and technical difficulties have led to the abandonment of the standard orotracheal method of endotracheal intubation method and the use of tracheotomy to endotracheally intubate pigs [2]. In this report, we describe the use of plastic vascular catheter for the safe and successful first-time endotracheal intubation of pigs.

MATERIALS AND METHODS

The maintenance and welfare of the pigs complied with the guidelines for experimentation on animals of the Animal Care and Use Committee of the Wrocław University of Environmental and Life Sciences, which are in accordance with Polish national legislation on the use of animals for experimental and other scientific purposes (Act of 21 January 2005, of Experiments on Animals, Journal of Laws of the Republic of Poland nr 33 poz.289). The study and all its procedures were reviewed and approved by the Animal Care and Use Committee of the Wrocław University of Environmental and Life Sciences.

Eighty (40 boars and 40 sows) Polish white-skinned domestic pigs, 40–200 kg body weight, were used in the study, whose aim was to develop a safe method for endotracheally intubating pigs using a plastic catheter. The pigs were divided into four equal groups based on their body mass and

*CORRESPONDENCE TO: JANISZEWSKI, A., Department of Internal Diseases with Clinic for Horses, Dogs, and Cats. Pl. Grunwaldzki 47, 50–366 Wrocław, Poland. e-mail: ajanisz@gmail.com

©2014 The Japanese Society of Veterinary Science

This is an open-access article distributed under the terms of the Creative Commons Attribution Non-Commercial No Derivatives (by-nc-nd) License <<http://creativecommons.org/licenses/by-nc-nd/3.0/>>.

Table 1. Intubation times in different body position, body weight and methods of intubation

Body Position	Body Weight (kg)	Age (months)	Authors' Method			Standard Orotracheal Method		
			Number of Intubations	Intubation Time (s)	Mean \pm SD Intubation Time (s)	Number of Intubations	Intubation Time (s)	Mean \pm SD Intubation Time (s)
Ventral Recumbency	40–79	12–20	7	16	22 \pm 4 s	4	30	55 \pm 34 s
	80–119	20–28	6	21		4	36	
	120–159	28–36	6	24		3	48	
	160–200	36–44	6	25		4	105	
Dorsal Recumbency	40–79	12–20	6	17	31 \pm 11 s	4	66	92 \pm 23 s
	80–119	20–28	7	29		4	82	
	120–159	28–36	6	35		4	102	
	160–200	36–44	6	43		3	119	
Lateral Recumbency	40–79	12–20	6	20	39 \pm 17 s	3	72	124 \pm 41s
	80–119	20–28	6	31		4	113	
	120–159	28–36	7	45		4	142	
	160–200	36–44	6	60		4	167	

age (Table 1). The pigs were premedicated by intramuscular injection of a mixture of 0.1 mg/kg midazolam (Midanium 5 mg/ml, Warszawskie Zakłady Farmaceutyczne Polfa S.A., Warsaw, Poland), 0.02 mg/kg medetomidine (Cepetor 1 mg/ml, CP-Pharma Handelsges, Burgdorf, Germany) and 8 mg/kg ketamine (Bioketan 100 mg/ml Vetoquinol Biowet sp.z o.o., Gorzów Wlkp., Poland) in the biceps femoris muscle. After catheterization of the auricular vein using a 22 G cannula (Vasofix Certo, B.Braun, Melsungen, Germany), anesthesia was induced by an intravenous bolus injection of either sodium thiopental 2–4 mg/kg (Thiopental 1,000 mg, Sandoz, International GmbH, Holzkirchen, Germany) or propofol 1–2 mg/kg (Propofol 1% MTC/LCT Fresenius Kabi AG, Bad Homburg, Germany). Thirty pigs were endotracheally intubated by the standard oro-tracheal method [8, 10] using a laryngoscope whose blade length was 195 mm. The dimensions of the endotracheal tube (Sumi, Sulejowek, Poland) were 5.0–8.5 mm (internal diameter) and 26–28 cm (length), and the size of endotracheal tube that was used to intubate each pig was selected according to the body weight of the animal.

Fifty pigs were endotracheally intubated according to the authors' method using a self-made stainless steel throat spatula (40 cm long and 2 cm wide), a forehead lamp (Spot Headlamp, Black Diamond Equipment, Reinach, Switzerland), an approximately 80 cm blunt-tipped plastic catheter (7 Fr Embolectomy Catheter, Biosensors International, Singapore) which was used as a guide wire, and an endotracheal tube whose dimensions were the same as those previously described. A metal wire was inserted into the catheter, which was used as the guide wire, in order to maneuver it well and determine the catheter's shape. The plastic catheter had to have be of such dimensions, because it had to take into consideration the length of insertion into the trachea (around 20 cm), the length of the endotracheal tube (26–28 cm) and the length of the oral cavity. The method of endotracheal intubation comprises four steps: visualization of the vocal cords using the light of the forehead lamp and the throat spatula in

order to depress the tongue and epiglottis; placing the plastic guide wire on the surface of the depressed epiglottis in the laryngeal cleft (Fig. 1a) without rotating the guide wire and simultaneous compression of the epiglottis; and endotracheal intubation by sliding the endotracheal tube over the plastic guide wire (Fig. 1b); and then removal of the guide wire. The pigs were intubated by both methods when placed in different body positions, namely dorsal recumbency, lateral recumbency and ventral recumbency. Each pig was intubated thrice in different body positions at intervals of 30 days. Three persons attempted to intubate the pigs; one of them is an experienced anesthesiologist with prior experience in swine intubation, and the remaining two only had experienced in the intubation of dogs and cats. Forty pigs (50%) were intubated by an experienced anesthesiologist and an unexperienced anesthesiologist intubated the remaining 40 pigs. The intubation time measure was initiated when the assistant opened the oral cavity of the animal and ended when the tube was inserted and the guide wire was removed. Intubation was visually monitored by an anesthesiologist for signs of edema or bleeding. End-tidal carbon dioxide (ETCO₂), respiratory rate and isoflurane level were monitored immediately after connected semi-closed anesthesia circuit. Anesthesia was maintained with oxygen-isoflurane for a minimum of one hour. It confirmed with ETCO₂ that endotracheal tube was not inserted into the esophagus, because no CO₂ is present in gases exiting from an esophagus. In case of faulty intubation, the pigs would not have been anesthetized properly, and this would have been picked up by the anesthesiologist. To confirm the complication after extubation, all animals were sedated intravenously using propofol 1–2 mg/kg, and the larynx was observed using the self-made spatula and mentioned head lamp approximately 1 hr after extubation.

The data were presented as means and standard deviation (SD). The Spearman's rank correlation coefficient (a computerized software package Statistica for Windows, version 8.0, StatSoft, Krakow, Poland) was used statistically for assessing the relationship between variables.

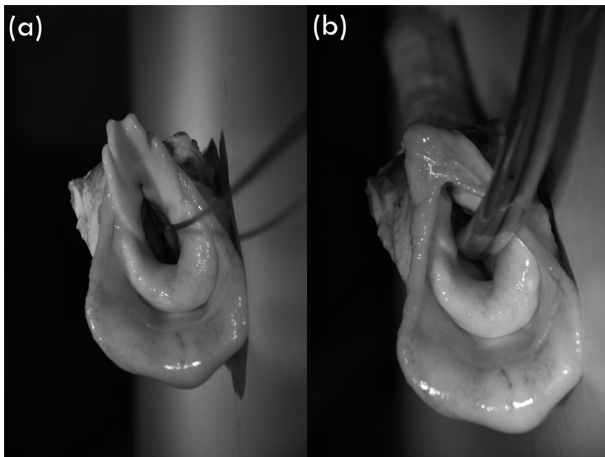


Fig. 1. (a) Introduction of the 80-cm blunt-tipped plastic guide wire into the trachea by passing it over the vocal cords, (b) Insertion of the endotracheal tube into the trachea by sliding it over the guide wire after its insertion into the trachea. To perform the pictures, the cadaver model not associated with this study was used.

RESULTS

In pigs, intubation time was measured only for experienced anesthesiologist. Using the standard orotracheal method, we noted the following times of intubation; 92 ± 23 sec in dorsal recumbency, 124 ± 41 sec in lateral recumbency and 55 ± 34 sec in ventral recumbency. Using the plastic guide wire, these times were: 31 ± 11 sec in dorsal recumbency, 39 ± 17 sec in lateral recumbency and 22 ± 4 sec in ventral recumbency. Both the experienced and inexperienced staffs were able to intubate each pig on the first attempt using the plastic guide wire without any complications. It was found that endotracheal intubations using the plastic guide wire were most efficient when the pigs were placed in ventral recumbency with the head elevated in order to straighten the upper respiratory tract. We also found that visualization of the oropharynx was best when the pig's mouth was at the same level of the operator's or anesthetist's eye.

In the standard orotracheal method, the experienced staff took an average of 1.2 attempts, and the inexperienced staff took an average of 2.0 attempts to correctly intubate the pigs. Laryngospasm and edema of the larynx mucosa with mild bleeding (which stopped spontaneously after few min) were observed when using standard orotracheal intubation, which prevented further probe intubation using this method five times. After five unsuccessful attempts at intubation using the standard endotracheal method, the authors' method was used. In each of these cases, the pigs could be intubated using the guide wire. Using the plastic guide wire, every pig was successfully intubated at the first attempt, whereas 1.6 attempts (average) were required to intubate the pigs using the standard orotracheal method. The mean time to successfully intubate the pigs using the plastic guide wire was considerably two times shorter than that required using the standard orotracheal method (22 ± 4 sec vs. 55 ± 34 sec) (Table 1).

The difficulty in intubation using the standard orotracheal method is positively correlated with body weight ($r=0.66$), in contrast to author's method, where body weight had no influence on the difficulty in intubation ($r=0.19$).

When the larynx was observed under sedation approximately 1 hr after extubation, any pigs were not shown the bleeding or the laryngeal stridor. And, no adverse effects, such as post-procedural vomiting, respiratory distress or porcine stress syndrome after extubation, were seen in those pigs that were endotracheally intubated using standard orotracheal and author's method.

DISCUSSION

The average intubation time obtained (22 ± 4 sec) was similar to the 20 sec achieved by Theisen *et al.* [10] in pigs intubated in ventral recumbency. However, their experiments were performed on relatively small pigs (32.9 ± 4.8 kg). In this study, intubation was performed on pigs whose long snout made intubation difficult and time-consuming even for an experienced anesthetist. From these results, we concluded that the use of the plastic guide wire endotracheal intubation in pigs reduces the time and improves the safety of the procedure.

Although endotracheal intubation using a plastic guide wire seems to be time-consuming, it was found that its use shortened the duration of the procedure, improved the ease of the procedure and reduced the risks of the procedure. Metal guide wires have been reported to be useful for the endotracheal intubation of pigs [4, 7]. However, their use increases the risk of damage to the oropharynx, larynx and respiratory tract mucosa. The plastic guide wire used in this study seems to be safer than a bare metal wire, because of its blunt tip, smooth surface and possibility of shape adjustment.

Successful endotracheal intubation at the first attempt is very important, because it reduces the risk of injury to the laryngeal mucosa [4]. Even when the intubation is properly performed and successful at the first attempt using the standard orotracheal method, it has been reported that laryngotracheal damage, such as ulceration of the respiratory mucosa that is in contact with the tube, perichondritis, proliferation of granulation tissue and, eventually, formation of scar tissue and stenosis may still occur [3, 6].

To summarize, we found that the use of an 80 cm blunt-tip plastic vascular catheter as a guide wire improves the safety of endotracheal intubation and reduces the duration of the procedure in the pig when placed in ventral recumbency. Since the use of the plastic guide wire also improves the ease of the procedure, its use will also enable inexperienced operators to perform successful first-time endotracheal intubation of pigs without causing injury.

ACKNOWLEDGMENTS. This publication is part of the "Wrovasc-Integrated Cardiovascular Centre"-project, which is co-financed by the European Regional Development Fund, within Innovative Economy Operational Program, 2007-2013. "European Funds-for the development

of innovative economy". The authors also wish to thank Dr. Arieh Bomzon, ConsulWrite (www.consulwrite.com) for his editorial assistance in preparing the manuscript.

REFERENCES

1. Forbes, R. B., Murray, D. J. and Albanese, M. A. 1989. Evaluation of an animal model for teaching fibreoptic tracheal intubation. *Can. J. Anaesth.* **36**: 141–144. [Medline] [CrossRef]
2. Geovanini, G. R., Pinna, F. R., Prado, F. A. P., Tamaki, W. T. and Marques, E. 2008. Standardization of anesthesia in swine for experimental cardiovascular surgeries. *Rev. Bras. Anesthesiol.* **58**: 363–370. [Medline]
3. Gordin, A., Chadha, N. K., Campisi, P., Luginbuehl, I., Taylor, G. and Forte, V. 2010. Effect of a novel anatomically shaped endotracheal tube on intubation-related injury. *Arch. Otolaryngol. Head Neck Surg.* **136**: 54–59. [Medline] [CrossRef]
4. Hartmann, H., Buhholz, W. and Mugge, L. 1971. Instrumentarium zur endotrachealen intubation und technik der intratrachealnarkose beim schwein. *Naunyn Schmiedebergs Arch. Pharmakol.* **268**: 96–101 (in German). [Medline] [CrossRef]
5. Oshodi, A., Dysart, K., Cook, A., Rodriguez, E., Zhu, Y., Shaffer, T. H. and Miller, T. L. 2011. Airway injury resulting from repeated endotracheal intubation: Possible prevention strategies. *Pediatr. Crit. Care Med.* **12**: e34–e39. [Medline] [CrossRef]
6. Puyo, C. A., Tricomi, S. and Dahms, T. E. 2008. Early biochemical markers of inflammation in a swine model of endotracheal intubation. *Anesthesiology* **109**: 88–94. [Medline] [CrossRef]
7. Schmitz, T., Konrad, R. M. and Tarbiat, S. 1964. Zur Technik der Intubationsnarkose bei Läufer Schwein. *Z. Gesamte Exp. Med.* **138**: 299–305 (in German). [Medline] [CrossRef]
8. Smith, A. C. and Swindle, M. M. 2008. Anesthesia and Analgesia in Swine. pp. 413–440. *In: Anesthesia and Analgesia in Laboratory Animals*, 2nd ed. (Fish, R.E., Brown, M.J., Danneman, P.J. and Karas, A.Z. eds.), Academic Press, New York.
9. Steinbacher, R., von Ritgen, S. and Moens, Y. P. 2012. Laryngeal perforation during a standard intubation procedure in a pig. *Lab. Anim.* **46**: 261–263. [Medline] [CrossRef]
10. Theisen, M. M., Maas, M., Hartlage, M. A., Ploner, F., Niehues, S. M., Van Aken, H. K., Weber, T. P. and Unger, J. K. 2009. Ventral recumbency is crucial for fast and safe orotracheal intubation in laboratory swine. *Lab. Anim.* **43**: 96–101. [Medline] [CrossRef]