

## Inflammation and Infection

# Communicating Fistula Between Colocutan and Nephrocutan With Renal Stones and Renal Replacement Lipomatosis. A Case Report



Bambang Soeprijanto <sup>a,\*</sup>, Wahjoe Djatisoesanto <sup>b</sup>, Willy Sandhika <sup>c</sup>

<sup>a</sup> Radiology Department, Medical Faculty, Universitas Airlangga, Surabaya, Indonesia

<sup>b</sup> Urology Department, Medical Faculty, Universitas Airlangga, Surabaya, Indonesia

<sup>c</sup> Pathology Department, Medical Faculty, Universitas Airlangga, Surabaya, Indonesia

## ARTICLE INFO

## Article history:

Received 20 September 2016

Accepted 19 October 2016

## Keywords:

Colocutaneous fistula

Nephrocutaneous fistula

Renal stone

Renal replacement lipomatosis

## ABSTRACT

Colocutaneous fistula with nephrocutaneous fistula is a rare condition. Renal replacement lipomatosis is the result of the atrophy and destruction of renal parenchyma. We report a 60-year-old male with intermittent drainage mucus and fluid from ulcer of his right lumbar region. Renal ultrasound and plain abdominal X-ray revealed a chronic parenchymal disease with stone of the right kidney. Fistulography showed a fistula tract connecting the skin and the right pelvicalyceal system and the colon. Computerized tomography demonstrated a renal calculus with a massive fatty proliferation. The patient was planned for right nephrectomy and excision of the sinus tract.

© 2016 The Authors. Published by Elsevier Inc. This is an open access article under the CC BY-NC-ND license (<http://creativecommons.org/licenses/by-nc-nd/4.0/>).

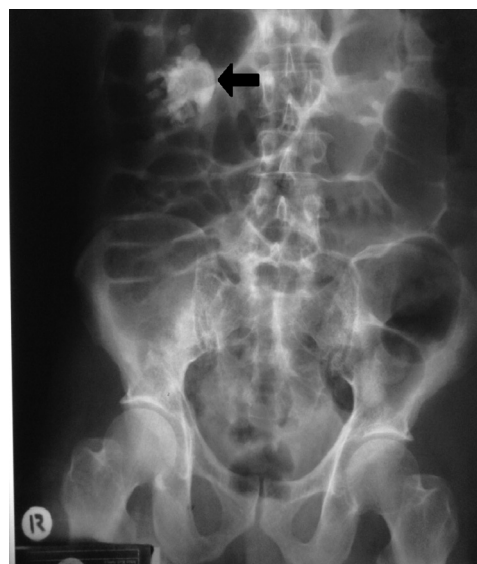## Introduction

Enterocutaneous fistula (ECF) occurs simultaneously with the nephrocutaneous fistula (NCF) is a rare clinical condition. Infection associated with the kidney stones are the most common cause.<sup>1–4</sup> Renal replacement lipomatosis (RRL) is the result of the atrophy and destruction of renal parenchyma.<sup>5</sup> We report a case of NCF and CCF with renal calculus and RLL. The aim of this report was to add references to the data about this complex clinical condition.

## Case report

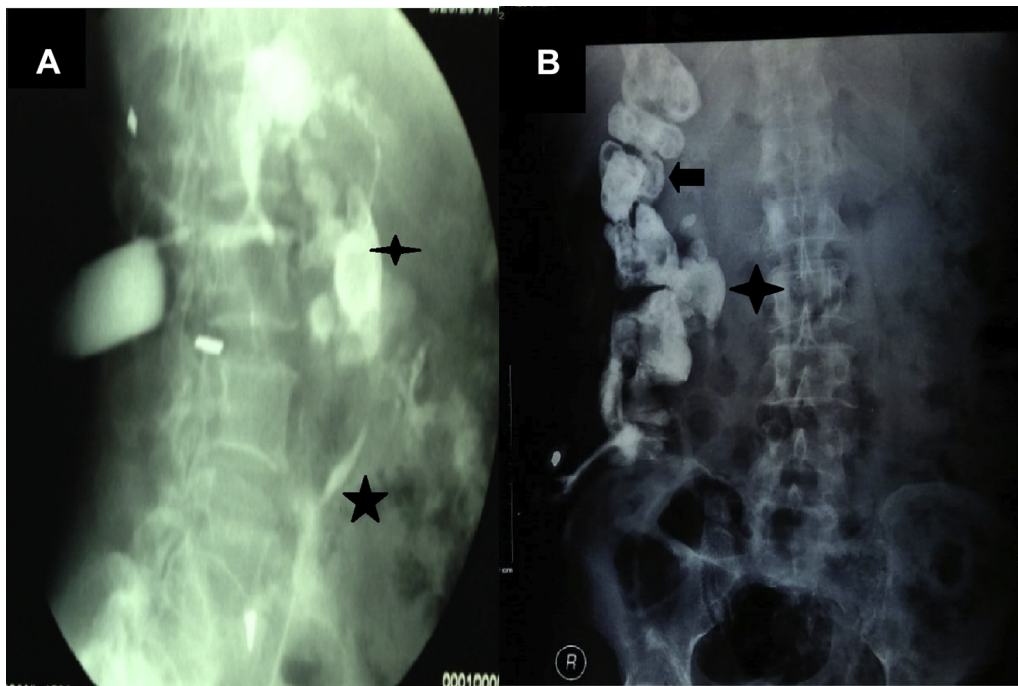
A 60-year-old man came with a history of intermittent discharge from an ulcer over the right side of back, associated with foul smelling discharge for the past 4 years. Abdominal examination revealed multiple ulcers on the right lumbar region. It was pale black-red in color and did not bleed if touched. The size of largest ulcer was 2 cm × 3 cm. The ulcer margins were inverted and occasionally discharge fluid and mucus. The discharge reduced when the patient took the medication but increased again after stopping therapy. Laboratory investigation revealed a normal leukocyte count ( $8 \times 10^9/L$ ). Urinalysis showed the presence of more than 10 leukocytes per high-power microscopic field. Urine culture showed *Proteus Mirabilis*. Renal ultrasound (US) revealed a

chronic parenchymal disease of the right kidney with calculi of size 2 cm x 2.5 cm. Abdominal X-ray (AXR) supported the suspicion of an opaque renal stone (Fig. 1). A fistulography was performed using 60% urografin, which revealed a communicating fistula with the



**Figure 1.** An abdominal X-rays (AXR) revealed a stone in the right upper quadrant (←).

\* Corresponding author. Jl. Manyar Tistoasri 5/18, Surabaya, 60116, Indonesia.  
E-mail address: [bambangsoeprijanto@yahoo.com](mailto:bambangsoeprijanto@yahoo.com) (B. Soeprijanto).



**Figure 2.** A and B. A fistulography showed a fistula tract connecting the skin, right pelvicalyceal system (★), right ureter (★) and proximal colon (◄).

right pelvicalyceal system and proximal colon (Fig. 2). Unenhanced computed tomography (CT) scans of the abdomen showed atrophy of the right renal parenchyma with renal calculus. Additionally, there was a massive fatty proliferation within the renal sinus, hilus, and perinephric space of the right kidney (Fig. 3). The result of histopathological examination of the skin biopsy was hyperkeratosis of the epidermis with spores (fungus) and many inflammatory cells. No signs of malignancy. The patient was planned for right nephrectomy and excision of the sinus tract.

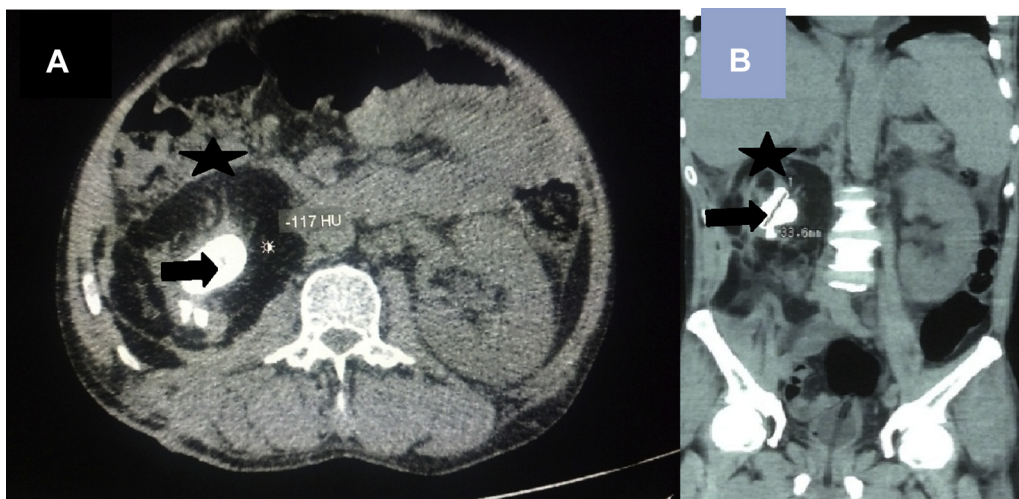
### Discussion

An abnormal communication between the skin and the small or large bowel can arise from the duodenum, jejunum, ileum, colon, or rectum. The etiology of ECF can be characterized as a result from

infective condition, postoperative, traumatic, and spontaneous. Spontaneous ECF is seen in about 15–25% of cases. Sepsis and malnutrition are predisposing factors. Less commonly, ECF develop spontaneously as part of the disease process in Crohn's disease or diverticulitis.<sup>2,3</sup>

ECF are classified as high output, moderate output and low output. High output fistulas are more prone to electrolyte imbalance and malnutrition. Moderate fistulas and high output fistulas are usually related to the small bowel.<sup>2</sup> In a series of patients with ECF is colocutaneous fistula (CCF). Some cases of CCF is caused by appendicular abscess drainage. In a rare case, a spontaneous CCF is caused from colonic cancer.<sup>3</sup> In this present case, is likely classified as low-output fistula.

NCF is an inflammatory process of the kidney, and extend to adjacent urinary organs. Fistulae to the skin represent a late stage of



**Figure 3.** A and B. An unenhanced computed tomography (CT) scan of the abdomen showed a renal calculus (◄) and massive fatty proliferation (-117HU) (★) of the right kidney.

the chronic renal infection. Gastrointestinal system and skin are the most commonly involved structures that may cause NCF communicate with CCF.<sup>4</sup> NCF spontaneously associated with CCF as in this case is a rare and complex clinical condition.

Renal calculi and infection of the genitourinary system is the two most common predisposing factors of NCF. Some cases of urolithiasis may remain asymptomatic for a prolonged period and present later as an advanced or complicated disease. Nephrolithiasis and chronic urinary tract infection, is capable to damaging the entire kidney.<sup>4</sup> Renal Replacement Lipomatosis (RRL) is the result of the atrophy and destruction of renal parenchyma with massive increases of the amount of fat in the sinus and peri renal space.<sup>5</sup>

In some cases, NCF have not shown pyuria and bacterial growth in their urine, because renal stone obstruct the contaminated urine to reach the bladder. RRL and *Proteus Mirabilis* were found in a urine culture, therefore Xanthogranulomatous pyelonephritis can be suspected in these patient.<sup>4</sup>

Abdominal AXR and US usually is as the first imaging modalities during evaluation of such cases and then followed by fistulography. CT not only supports the diagnosis but also detects any changes in renal parenchyma and the extension of the disease to the extra renal region. CT scan enables an accurate diagnosis of RRL and aids in the differential diagnosis of fat-contained masses, such as retroperitoneal liposarcoma, renal lipoma, and angiomyolipoma. MRI provides further confirmation of RRL.<sup>5</sup>

## Conclusions

Communication between a colcutaneous fistula and a nephrocutaneous fistula with renal stones and renal replacement lipomatosis is a rare and complex clinical condition. AXR and US are

typically the first imaging studies conducted for evaluation of such cases and are then followed by fistulography. CT cannot only confirm the diagnosis but also detect any changes in the renal parenchyma and extension of the disease to extra renal regions.

## Informed consent

Permission for publication and informed consent from the patients has been documented in the paper.

## Conflict of interest

None.

## Acknowledgement

Any institution has not financed this case report.

## References

1. Kate V. Enterocutaneous Fistula. Medscape. Updated: Jan 25, 2016. (Cited 2016 March 25). Available from: <http://emedicine.medscape.com/article/1372132-overview>.
2. SurgWiki. Enterocutaneous fistula. Blackwell Publishing Asia Pty Ltd.155 Cremorne Street, Richmond Victoria, 3121, Australia. Dated modified on 10 January 2012; (cited 2016 March 28). Available from: [http://www.surgwiki.com/wiki/About\\_SurgWiki](http://www.surgwiki.com/wiki/About_SurgWiki).
3. Nagaraja R, Kudva A, Prasad, Nagpal N. Spontaneous colcutaneous fistula: A rare presentation of colon carcinoma. *Internet J Surg.* 2007;15(1). Available from <http://ispub.com/IJS/15/1/6898>.
4. Tanwar R, Rathore KV, Rohilla MK. Nephrocutaneous fistula as the initial manifestation of asymptomatic nephrolithiasis: A call for radical management. *Urol Ann.* 2015;7(1):94–96. <http://dx.doi.org/10.4103/0974-7796.148632>.
5. Khallouk A, Tazi MF, Elfassi MJ, Farih MH. Chronic spontaneous nephrocutaneous fistula associated with renal replacement lipomatosis. *Rev Urol.* 2010;12(4):190–192. [PMC3020281](https://pubmed.ncbi.nlm.nih.gov/2020281/).