

Meniscal Ramp Lesion Repair by a Trans-septal Portal Technique



Kadir Buyukdogan, M.D., Michael S. Laidlaw, M.D., and Mark D. Miller, M.D.

Abstract: The identification of meniscal ramp lesions can be quite difficult or even impossible with conventional anterior arthroscopic viewing and working portals. Although even the use of transnotch viewing maneuvers into the posteromedial compartment increases the likelihood of diagnosis, it is the posteromedial and trans-septal portals that provide the best direct visualization of these many times “hidden lesions.” In this surgical technique description, we describe a method to not only adequately visualize the ramp lesion, but also provide subtle variations to existing surgical techniques that can help limit injury to neurovascular structures as well as gain satisfactory vertical suture repair of this posteromedial meniscocapsular injury.

In the setting of acute or chronic anterior cruciate ligament (ACL) deficiency, concomitant meniscal lesions, particularly tears involving the posterior horn of the medial meniscus (PHMM), are commonly encountered.¹ A specific type of injury involving the peripheral capsular attachment of the PHMM has been referred to as a ramp lesion, and these lesions have been increasingly recognized over the past several years.² Recent studies showed a high prevalence of ramp lesions (16%-17%) in ACL-deficient knee patients.^{3,4}

Biomechanical consequences of meniscus injuries or deficiencies on tibiofemoral joint contact pressure and knee kinematics are well known. Recent reports have also highlighted the role that ramp lesions play in knee stability. In a cadaveric study by Peltier et al.,⁵ authors found that ramp lesions increased the forces in the ACL given that the PHMM acts as secondary restraint to knee stability. Data from a recent cadaveric study by

Stephen et al.⁶ validated the findings of this previous study. Moreover, they have reported that anterior and external rotational laxities were not restored after an isolated ACL reconstruction but were restored with ACL reconstruction combined with posterior meniscocapsular injury repair. According to these biomechanical studies, the diagnosis and treatment of ramp lesions is vital to protect an ACL graft from excessive forces and to restore the stability of the knee.

Ramp lesions remained unrecognized given the inadequate visualization of these lesions through standard anterior arthroscopic portals. Moreover, many times imaging modalities fail to detect these posterior horn lesions. Bollen⁷ presumed that near full extension of the knee during magnetic resonance imaging (MRI) investigation may reduce meniscocapsular separation, similar to the failure of MRI to identify a reduced bucket-handle meniscal tear. Thus, the arthroscopic evaluation of the posterior compartments of the knee through the intercondylar notch and with accessory posterior portals is crucial so as not to overlook these injuries. In this surgical technique description, we describe our method for the repair of ramps lesions using a posterior trans-septal portal.

Technique

Standard anteromedial and anterolateral arthroscopic portals are made for a diagnostic arthroscopy. Close attention not only is paid to whether the probe can be introduced into the PHMM but also if there is any aberrant meniscal excursion into the joint. The latter many times can help discern the stability status of a posterior horn meniscocapsular separation. Should the

From the Department of Orthopaedic Surgery, University of Virginia, Charlottesville, Virginia, U.S.A.

The author reports the following potential conflicts of interest or sources of funding: M.D.M. receives royalties from Arthrex; however, for the purposes of this described surgical technique, there is no gross conflict of interest. Full ICMJE author disclosure forms are available for this article online, as supplementary material.

Received March 13, 2017; accepted May 21, 2017.

Address correspondence to Mark D. Miller, M.D., Department of Orthopaedic Surgery, University of Virginia, 400 Ray C. Hunt Drive, Suite 300, Charlottesville, VA 22903, U.S.A. E-mail: MDM3P@hscmail.mcc.virginia.edu

© 2017 by the Arthroscopy Association of North America

2212-6287/17333/\$36.00

<http://dx.doi.org/10.1016/j.eats.2017.05.029>

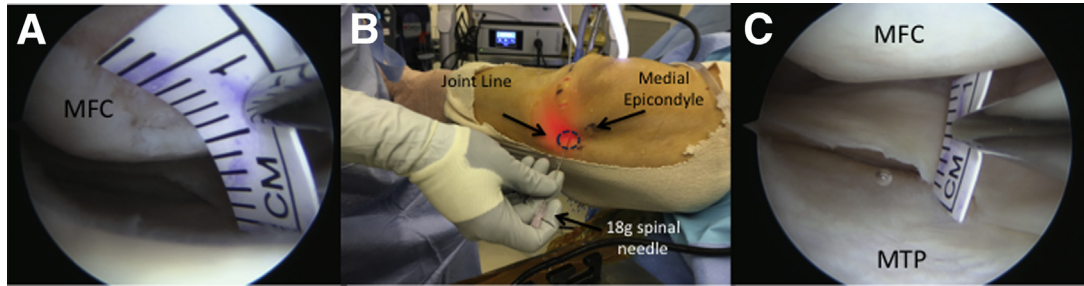


Fig 1. (A) Arthroscopic image of right knee viewing through the anterolateral portal. Tight medial compartment, measured as 4 mm, results in difficult arthroscopic probe examination of the PHMM. (B) Fenestration of the medial collateral ligament, proximal to the meniscus and directly on the femur, is performed by an 18-g spinal needle. (C) This provides an increased medial joint space, measured as 11 mm, and adequate visualization of the meniscus without damaging the cartilage. (MFC, medial femoral condyle; MTP, medial tibial plateau; PHMM, posterior horn of the medial meniscus.)

medial compartment be “tight” resulting in a difficult arthroscopic probe examination of the PHMM, then a fenestration of the medial collateral ligament, proximal to the meniscus and directly on the femur, is performed by an 18-g spinal needle. This provides adequate visualization to complete the arthroscopic examination of the meniscus without damaging the cartilage⁸ (Fig 1). It is in our experience that there is very limited morbidity associated with the fenestration procedure during the recovery period or long term. With the knee in 90° of flexion, a Gillquist maneuver (transpatellar tendon) or a preferred modified Gillquist maneuver (anterolateral portal) is performed while using a 30° or 70° arthroscope.⁹ We routinely use a 30° arthroscope, which adequately visualizes the posteromedial compartment and meniscocapsular junction. Should a lesion be identified or if further evaluation is needed, then a posteromedial portal is safely made in a standard fashion. As previously described, this is routinely made by spinal needle localization at 2.5 cm distal and 2.5 cm posterior to the palpated medial epicondyle with the

knee in 90° of flexion (Fig 2A).¹⁰ The portal is developed by a “nick and spread” technique to limit injury to branches of the saphenous nerve. After spreading the tissues with a straight hemostat, a cannula is placed to help with further evaluation and to shuttle sutures. We prefer a double dam flexible flanged cannula (Arthrex, Naples, FL), as its wide diameter nicely retracts the synovium/capsule medially (Fig 3). Further probe evaluation of the posteromedial meniscocapsular junction is performed. The arthroscopic shaver is placed through the posteromedial portal and debridement performed as needed to uncover any potential hidden lesions, whereas the arthroscope is inserted through intercondylar notch. The tear is then measured by an arthroscopic ruler to help guide the decision-making process. The arthroscope can be moved into the posteromedial portal to directly visualize any gross lesion as well. If it is less than 1.5 cm in measurable length, without gross excursion and deemed stable, then it is trephined/debrided by the shaver alone.¹¹ However, if it meets criteria for repair, greater than 1.5 cm in

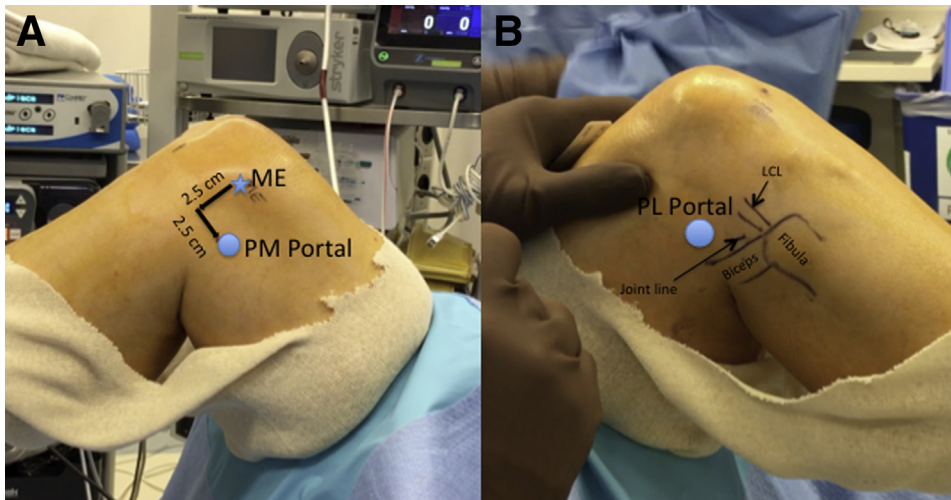
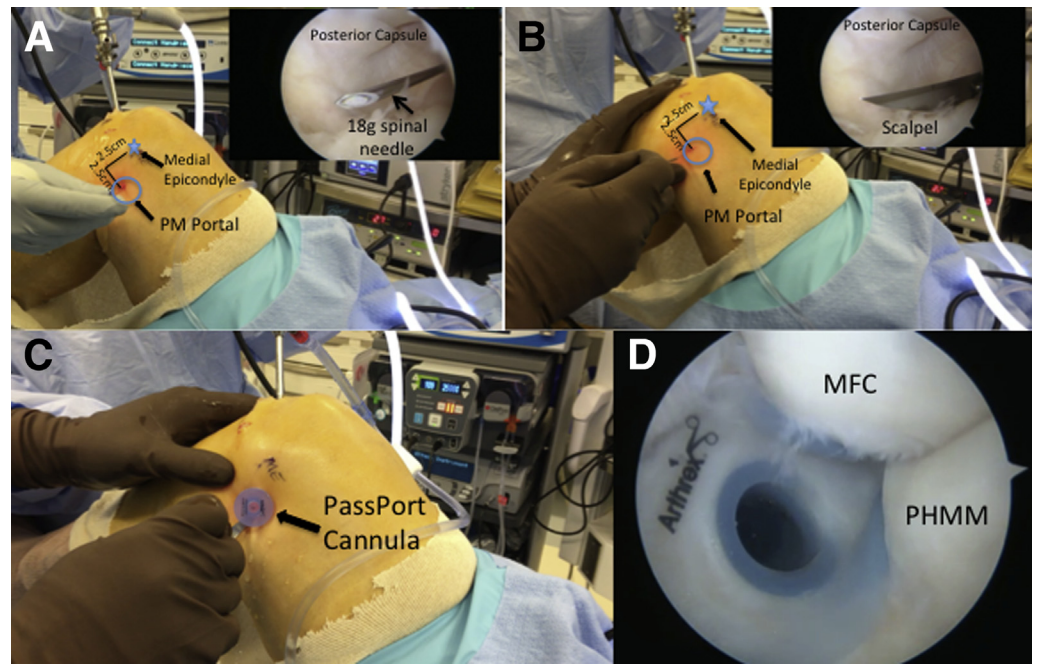


Fig 2. (A) Right knee: a posteromedial portal is established 2.5 cm distal from the bony prominence of medial epicondyle and 2.5 cm posterior from this measured point with the knee in 90° of flexion. (B) Right knee: the posterolateral portal is located anterior to the long head of the biceps and proximal and posterior to the LCL. (LCL, lateral collateral ligament; ME, medial epicondyle; PL, posterolateral portal; PM, posteromedial portal.)

Fig 3. Posteromedial portal establishment on the right knee with the “nick and spread” technique. With the knee in 90° of flexion, modified Gillquist maneuver is performed into the posteromedial compartment. This helps to visualize portal establishment with a needle (A) and the portal is enlarged with a scalpel (B). A double dam flexible flanged cannula (Arthrex) is placed into the portal (C). Adequate visualization of the PHMM is obtained with the cannula nicely retracting the capsule medially (D). (MFC, medial femoral condyle; PHMM, posterior horn of medial meniscus; PM, posteromedial portal.)



length or is deemed unstable by gross meniscal excursion into the joint, then a trans-septal portal is created and the tear is repaired per the below listed technique.

With the knee still in 90° of flexion, a Gillquist maneuver or a preferred modified Gillquist maneuver (anteromedial portal) is performed into the

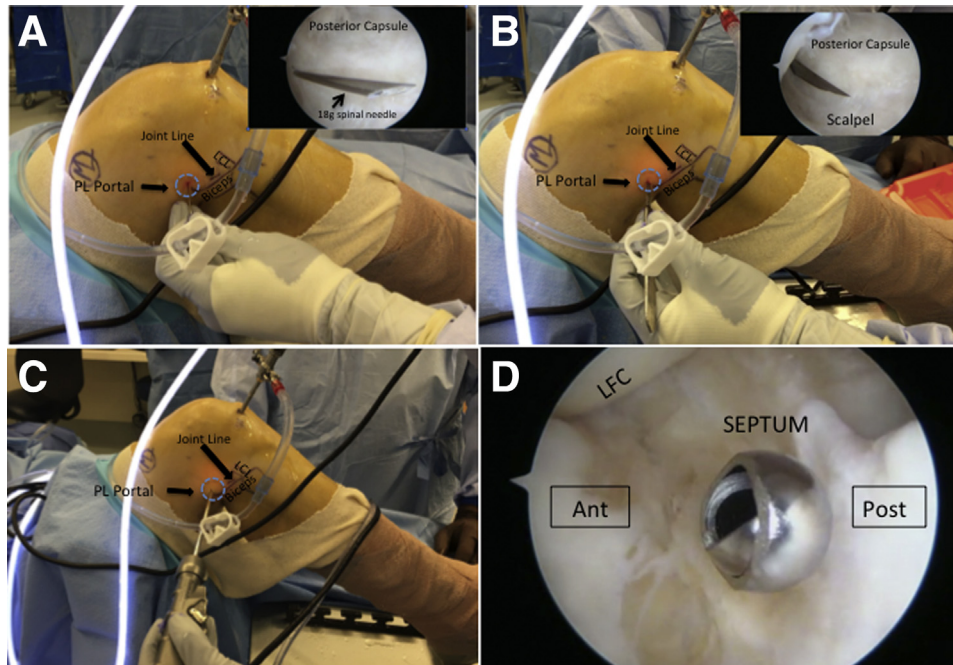


Fig 4. Posterolateral portal establishment on the right knee. With the knee still in 90° of flexion, modified Gillquist maneuver is performed into the posterolateral compartment. Portal location is planned anterior to the long head of the biceps and proximal and posterior to the LCL. With the help of transillumination, a spinal needle is used to localize the portal (A) and then the portal is enlarged with a scalpel (B). An arthroscopic shaver is introduced through the posterolateral portal and placed directly against the septum without penetrating it yet (C). Arthroscopic image of the shaver through the posteromedial portal with direct visualization during trans-septal portal/window creation. Note that the opening of the shaver is oriented anterior to avoid popliteal artery injury (D). (LCL, lateral collateral ligament; LFC, lateral femoral condyle; PL, posterolateral portal.)

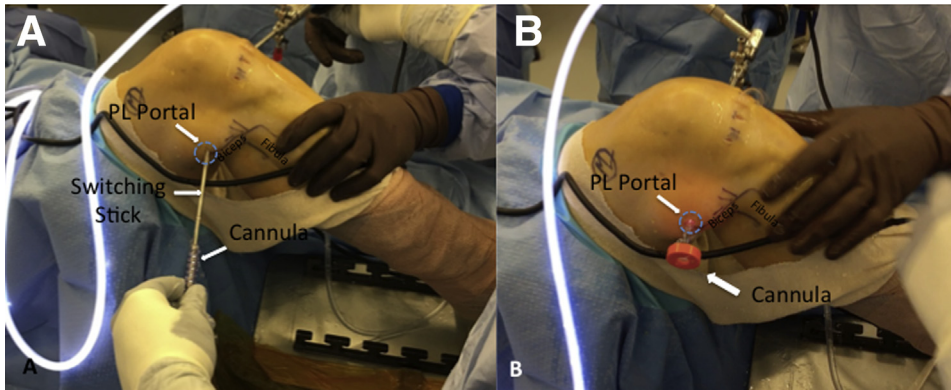


Fig 5. With the help of a switching stick (A), a standard long arthroscopic cannula (Depuy) is placed into the posterolateral portal to facilitate instrument use through this portal (B). (PL, posterolateral portal.)

posterolateral compartment. With the knee in 90° of flexion or temporarily in a figure-four position, the lateral collateral ligament and long head of the biceps femoris are palpated and drawn out. Transillumination with the knee arthroscope, in conjunction with the drawn-out anatomic landmarks, also helps to confirm where a satisfactory and safe portal can be placed (Fig 2B). Again, under direct arthroscopic visualization, a spinal needle is used to localize the portal placement. Great care is taken to remain well anterior to the long head of the biceps femoris, which can be easily palpated, to help limit injury to the common peroneal nerve (Fig 4). A standard long arthroscopic cannula (Depuy, Raynham, MA) can be placed over a switching stick into this portal and the arthroscopic shaver placed so that it rests directly against the posterior septum of the knee, which separates the posterolateral and posteromedial compartments of the knee (Fig 5).

With the knee in 90° of flexion, the 30° arthroscope is then placed through the posteromedial portal to view laterally, and the arthroscopic shaver is gently advanced from the posterolateral portal so that it penetrates through the septum (Fig 6A). When establishing the trans-septal portal from lateral to medial, it is important

to be careful by aiming the instrument and blades anteriorly to help avoid popliteal artery injury. An arthroscopic shaver is used to resect the septum, taking great care to only resect the septum and not damage the posterior cruciate ligament while keeping the shaver opening oriented anteriorly. We have found that extending the hole in the septum by a shaver may facilitate the passage of the arthroscope or instrument insertion and manipulation. This step is completed so that the arthroscope can easily be advanced from the posteromedial recess into the posterolateral recess of the knee, with an unobstructed view as it takes a “trip across the septum” (Fig 6B).

Next, the 30° arthroscope is placed through the posterolateral portal. It is advanced through the trans-septal portal so that it has a very clear, direct visualization of the posteromedial ramp lesion. At this point, the lesion is freshened by an arthroscopic rasp and shaver from the posteromedial portal (Fig 7). We have found that many times shoulder labral repair suture passers, such as a 45° to the left and right suture passer (Depuy), can be beneficial so that adequate bites/purchase of tissue can be obtained. It has not been our experience that this often requires separate passes

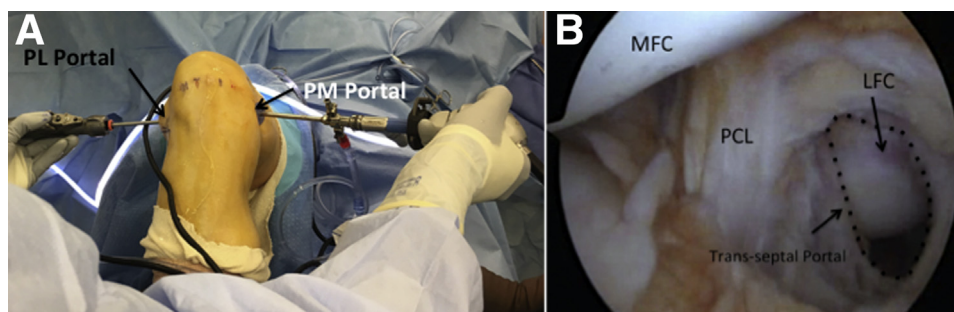


Fig 6. (A) Right knee: with the knee in 90° of flexion, the arthroscope is then placed through the posteromedial portal to view laterally, and the arthroscopic shaver is gently advanced from the posterolateral portal to extend the hole in the septum for facilitating the passage of the arthroscope or instrument insertion and manipulation. (B) Arthroscopic image viewing from the PM portal: the trans-septal portal (dashed borders) has been established without damaging the PCL. (LFC, lateral femoral condyle; MFC, medial femoral condyle; PCL, posterior cruciate ligament; PL, posterolateral portal; PM, posteromedial portal.)

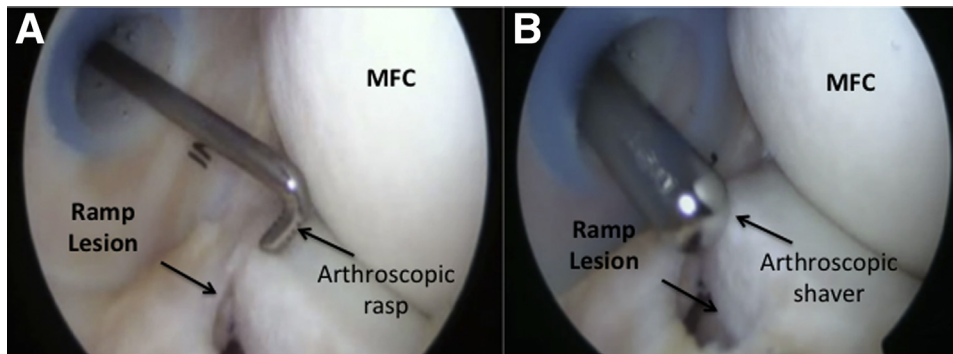


Fig 7. (A) Right knee arthroscopic image: the arthroscope is placed through the PL portal and advanced through the trans-septal portal to directly visualize the ramp lesion. An arthroscopic rasp determines the margins of the lesion after removing overlying fibrotic tissue. (B) Right knee arthroscopic image: the edges of the lesion are freshened by an arthroscopic shaver. (MFC, medial femoral condyle; PL, posterolateral.)

through the meniscus and capsule given the density and size of the PHMM. We have found that a single posteromedial portal is adequate for suture shuttling for lesions less than 2 cm in length. This can help limit any additional potential injury to the saphenous nerve; however, larger tears can be managed with 2 posteromedial portals if needed. If a second portal is needed, it is made just proximal to the standard posteromedial portal, with or without a cannula. Working the tear from medial to lateral, a 45° passer is first placed through the capsular tissue from superior to inferior with the eyelet suture shuttle exiting actually through the tear (Fig 8). This ensures an adequate bite of capsular tissue, which many times can be quite diminutive in quality. The shuttle suture is advanced as far as possible into the joint and then the suture passer is removed through the single cannula as the suture shuttle is advanced further. An arthroscopic atraumatic grasper then retrieves the suture shuttle through the same posteromedial portal if a single portal is desired, or

it can be inserted through a second posteromedial portal if deemed necessary given the tear length. A No. 2 ultrahigh-molecular-weight polyethylene fiber suture is shuttled through the capsular tissue out through the posteromedial portal. Next a 45° passer, pointed the opposite direction, is delivered through the posteromedial portal and placed through the meniscal tissue from superior to inferior, again exiting into the tear, and the eyelet suture shuttle advanced into the joint. This is once again retrieved with an atraumatic grasper through the cannula. The corresponding end of the No. 2 ultrahigh-molecular-weight polyethylene fiber suture that has not passed through any repair tissue yet is then shuttled back through the meniscal tissue. This completes a simple suture vertical mattress repair across the tear, which we have found is the most reliable way to get adequate tissue bites/purchase (Fig 9). This process is then repeated for as many sutures as required to adequately repair the tear. We routinely place a suture every 5 to 7 mm as needed. Sutures either can be tied as

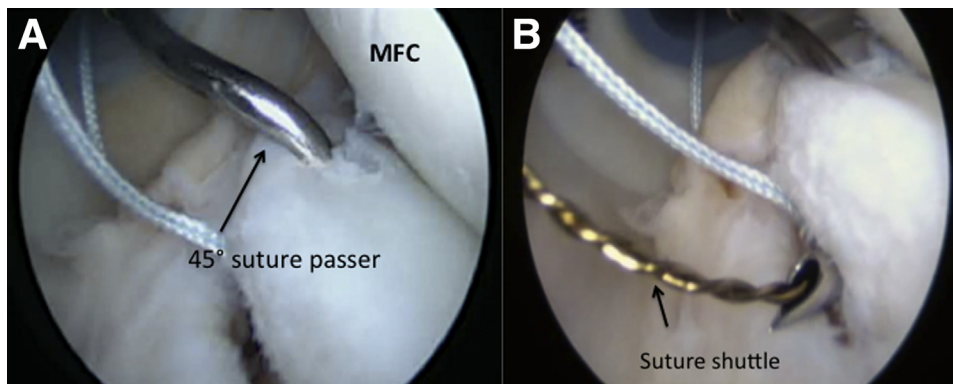


Fig 8. (A) Right knee arthroscopic image from the trans-septal portal: a 45° right suture passer (Depuy) is penetrating the right PMMH through the posteromedial portal, after already shuttling a single limb of a UHMPE suture through the capsular component. (B) Eyelet suture shuttle advanced into the joint to be retrieved by an atraumatic grasper through the posteromedial portal. (MFC, medial femoral condyle; PMMH, posterior horn of medial meniscus; UHMPE, ultra-high molecular weight polyethylene fiber.)

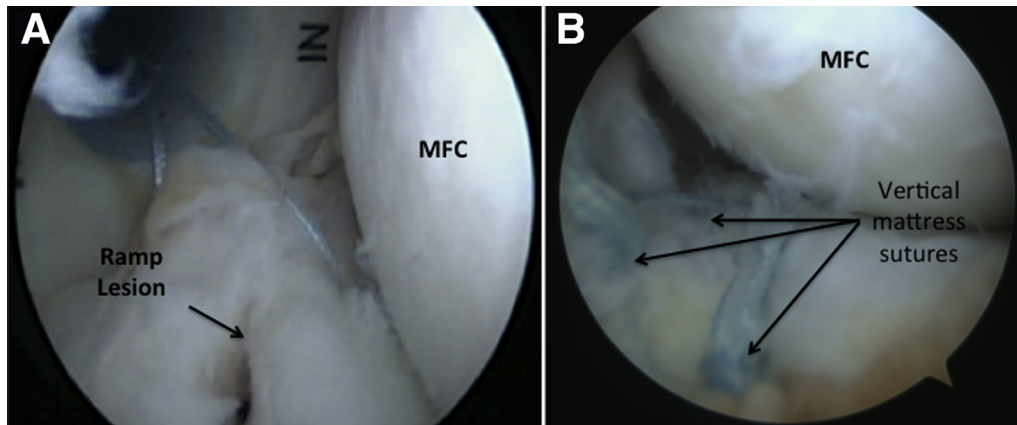


Fig 9. (A) Right knee arthroscopic image: the sutures are passed in a vertical mattress fashion, adequately reducing the torn tissue and reconstituting the ramp of the PHMM. (B) Right knee arthroscopic image through a trans-septal portal: sutures are placed in 5-7 mm intervals and knots are kept on the capsular side when tying arthroscopically to limit abrasion to the medial femoral condyle. (MFC, medial femoral condyle; PHMM, posterior horn of medial meniscus.)

they are placed or all at once at the end of the procedure; however, it is recommended to tie the sutures in mid flexion, so as not to overtension the repair, and to keep the knot on the capsular side when tying arthroscopically to limit abrasion to the posterior femoral condyle (Video 1). The cannulas are removed, sites are thoroughly irrigated, and the percutaneous skin incisions closed in a standard fashion with 3-0 nylon.

A meniscal repair protocol is employed post-operatively, which is in addition to any other ancillary procedures performed at the time of the ramp lesion repair/treatment. Routinely we place the patient in a knee brace, limit the patient's weightbearing status to 50% and range of motion is allowed from 0° to 90° during the first 6 weeks. Thereafter, full range of motion and progressive weightbearing as tolerated are implemented with a goal of return to sports by 4 to 6 months, depending on other concomitant pathology treated surgically at the time of the meniscal ramp lesion repair.

Table 1. Pearls and Pitfalls

Pearls

- Establishing the trans-septal portal from lateral to medial is important to help avoid popliteal artery injury
- Placing a double dam flexible flanged cannula in the PM portal helps to retract the synovium/capsule medially
- The use of 45° to the left/right suture passers may be beneficial to obtain adequate bites/purchase of torn tissue
- Extending the hole in the septum by a shaver may facilitate arthroscope or instrument insertion and manipulation

Pitfalls

- Keeping the shaver opening oriented anteriorly during trans-septal portal establishment is important to help avoid popliteal artery injury
- Using bony landmarks to create posteromedial and posterolateral portals in the case of transillumination fails to visualize portal locations

PM, posteromedial portal.

Discussion

The preoperative diagnosis of meniscal ramp lesions can be problematic due to low sensitivity of MRI to detect these lesions.^{4,7} It is well established that standard arthroscopic assessment may fail to visualize the posterior part of the medial meniscus and may miss tears in this region. Furthermore, some of these lesions are reported to be hidden under a layer of synovial or scar tissue, thus making them difficult to visualize without probing or minimal debridement.³ Although the importance of these lesions has been recognized more recently and the frequency of their diagnosis has increased as well, several authors have proposed different techniques to repair meniscal ramp lesions.

Sonnery-Cottet et al.³ described an all-inside technique using a 25° suture hook through a posteromedial portal to pass in from superior to inferior in the posterior meniscocapsular fragment and then from inferior to superior in the anterior meniscal fragment to lift the posterior sagging part. Although this technique allows placing vertical sutures on the lesion side, viewing from only transcondylar notch may not be sufficient to visualize the true extent of ramp lesions and using a hooked suture shuttle device from inferior to superior exiting against the femoral chondral surface could cause an iatrogenic injury to the cartilage.

In a recently reported technique by Li et al.,¹² authors used FasT-Fix meniscal repair devices to repair ramp lesions through standard anterior portals. Although this technique seems technically less challenging for most surgeons, the authors used only anterolateral portals to explore the meniscal ramp lesion, which may miss the lesion. Furthermore, with the knee in near full extension, as is routinely performed when evaluating the medial compartment arthroscopically, a complete closure of the torn meniscocapsular tissue can occur, which can also limit the adequate diagnosis of this lesion.

Table 2. Advantages and Disadvantages

Advantages	Disadvantages
<ul style="list-style-type: none"> • The trans-septal portal allows exploring the entire periphery of the PHMM to define the exact borders of the ramp lesion • Working on the posteromedial portal with 45 to the left/right suture passers allows vertical mattress suture placement 	<ul style="list-style-type: none"> • Risks of neurovascular injury during posterior portal placements and trans-septal portal establishment

PHMM, posterior horn medial meniscus.

Other potential drawbacks to this reported technique, as with any all-inside meniscal repair device, is the possibility of cartilage injury during implant placement, weak pull-out strength, migration, and breakage of implants with retained loose implant segments.

Ahn and Ha¹³ described a safe arthroscopic technique creating a portal, which is designated as the posterior trans-septal portal, through the posterior septum from the posterolateral compartment to the posteromedial compartment. This technique allows exploring areas such as the entire periphery of the posterior horns of the menisci and posterior capsule, in which visualization is often limited even using the combination of conventional anterior and posterior portals with transnotch views. Kongmalai and Chernchujit¹⁴ proposed a technique for ramp lesion repairs using a posterior trans-septal portal to improve the assessment of the lesion. We are in agreement with these authors, because complete arthroscopic visualization of the posterior part of the medial meniscus is only achievable through viewing from the creation of a posterior trans-septal portal. However, they have used 2 separate posteromedial portals to repair a ramp lesion as described earlier by Ahn et al.,¹⁵ one for inserting a hook device and other for retrieving the suture and tying the knot. Although a cadaveric study by McGinnis et al.¹⁶ reported that at least 2 posteromedial portals could be placed safely in the knee, the safety of 2 separate portals has not been validated with a large clinical series and should be undertaken with caution. As posterior compartment arthroscopic procedures have become more common, injury to neurovascular structures during the establishment of portals and neurologic complications after arthroscopic procedures is likely to increase as well.

The technique reported herein might have several advantages. First, the placement of vertical mattress sutures through an anatomically measured posteromedial portal while using a posterior trans-septal portal may in fact help limit an injury to the saphenous nerve and vein. In accordance with previously published reports, we consider visualization from the posterior trans-septal portal paramount to evaluate the extent of the lesion and ensure the adequate repair of the injury site. Second, we propose minimally resecting the septum anteriorly to create a keyhole to facilitate the passage and manipulation of instruments. By not placing a cannula completely across the septum, we limit the potential stretching of posterior located anatomic structures, such as the

popliteal neurovascular bundle. Furthermore, this technique used both right and left suture passers to gain adequate tissue purchase during advancement. Also, with the suture passer entering the meniscal tissue from superior to inferior and exiting through the tear site, this limits the potential damage to the cartilage by picking the start site on the meniscus and exiting away from the articular cartilage during passage. Finally, we have noticed that, particularly in obese patients, a transillumination method fails to visualize the best location for posteromedial and posterolateral portals. In these circumstances, we prefer to use bony prominence of the fibular head and palpable long head of the biceps femoris as landmarks in establishing a posterolateral portal as described previously.¹⁷ On the medial side, we prefer to establish a posteromedial portal that is 2.5 cm distal from the bony prominence of the medial epicondyle and 2.5 cm posterior from this measured point with the knee in 90° of flexion¹⁰ (Table 1).

This technique shares the same concerns regarding risks of neurovascular injury during portal placements. The safety of the trans-septal portal has been criticized for some time. Several cadaveric and MRI studies show that the distance between the posterior cruciate ligament and the popliteal artery ensures a safe margin of 19.3 to 27.1 mm to establish this trans-septal portal.^{18,19} When possible, we recommend the transillumination of the posterior compartment of knee before establishing portals, or using bony landmarks such as fibular head and medial epicondyle with further localization by soft tissue anatomic landmarks as well. Although there is a cost to the single use suture passers, at our institution, this is far less than the all-inside meniscal repair devices. The increased learning curve for arthroscopic visualization and suture tying can also be considered a drawback of this technique (Table 2).

References

1. Smith JP III, Barrett GR. Medial and lateral meniscal tear patterns in anterior cruciate ligament-deficient knees. A prospective analysis of 575 tears. *Am J Sports Med* 2001;29: 415-419.
2. Strobel MJ. *Manual of Arthroscopic Surgery*. New York: Springer, 1998.
3. Sonnery-Cottet B, Conteduca J, Thauinat M, Gunepin FX, Seil R. Hidden lesions of the posterior horn of the medial meniscus: A systematic arthroscopic

- exploration of the concealed portion of the knee. *Am J Sports Med* 2014;42:921-926.
4. Liu X, Feng H, Zhang H, Hong L, Wang XS, Zhang J. Arthroscopic prevalence of ramp lesion in 868 patients with anterior cruciate ligament injury. *Am J Sports Med* 2011;39:832-837.
 5. Peltier A, Lording T, Maubisson L, Ballis R, Neyret P, Lustig S. The role of the meniscotibial ligament in posteromedial rotational knee stability. *Knee Surg Sports Traumatol Arthrosc* 2015;23:2967-2973.
 6. Stephen JM, Halewood C, Kitl C, Bollen SR, Williams A, Amis AA. Posteromedial meniscocapsular lesions increase tibiofemoral joint laxity with anterior cruciate ligament deficiency, and their repair reduces laxity. *Am J Sports Med* 2016;44:400-408.
 7. Bollen SR. Posteromedial meniscocapsular injury associated with rupture of the anterior cruciate ligament: A previously unrecognized association. *J Bone Joint Surg Br* 2010;92:222-223.
 8. Claret G, Montanana J, Rios J, et al. The effect of percutaneous release of the medial collateral ligament in arthroscopic medial meniscectomy on functional outcome. *Knee* 2016;23:251-255.
 9. Gillquist J, Hagberg G. A new modification of the technique of arthroscopy of the knee joint. *Acta Chir Scand* 1976;142:123-130.
 10. Lanham NS, Tompkins M, Milewiski M, Hart J, Miller M. Knee arthroscopic posteromedial portal placement using the medial epicondyle. *Orthopedics* 2015;38:366-368.
 11. Liu X, Zhang H, Feng H, Hong L, Wang XS, Song GY. Is it necessary to repair stable ramp lesions of the medial meniscus during anterior cruciate ligament reconstruction? *Am J Sports Med* 2017;45:1004-1011.
 12. Li WP, Chen Z, Song B, Yang R, Tan W. The Fast-Fix repair technique for ramp lesion of the medial meniscus. *Knee Surg Relat Res* 2015;27:56-60.
 13. Ahn JH, Ha CW. Posterior trans-septal portal for arthroscopic surgery of the knee joint. *Arthroscopy* 2000;16:774-779.
 14. Kongmalai P, Chernchujit B. Posterior horn of medial meniscal peripheral capsular lesion: The arthroscopic repair technique working in the posterior compartment. *Arthrosc Tech* 2016;5:e763-e767.
 15. Ahn JH, Kim SH, Yoo JC, Wang JH. All-inside suture technique using two posteromedial portals in a medial meniscus posterior horn tear. *Arthroscopy* 2004;20:101-108.
 16. McGinnis MD IV, Gonzalez R, Nyland J, Caborn DN. The posteromedial knee arthroscopy portal: A cadaveric study defining a safety zone for portal placement. *Arthroscopy* 2011;27:1090-1095.
 17. Ahn JH, Lee SH, Jung HJ, Koo KH, Kim SH. The relationship of neural structures to arthroscopic posterior portals according to knee positioning. *Knee Surg Sports Traumatol Arthrosc* 2011;19:646-652.
 18. Pace JL, Wahl CJ. Arthroscopy of the posterior knee compartments: Neurovascular anatomic relationships during arthroscopic transverse capsulotomy. *Arthroscopy* 2010;26:637-642.
 19. Kim SJ, Song HT, Moon HK, Chun YM, Chang WH. The safe establishment of a transeptal portal in the posterior knee. *Knee Surg Sports Traumatol Arthrosc* 2011;19:1320-1325.