

Received: 2019.06.24

Accepted: 2019.10.04

Published: 2019.12.28

# The Prognostic Role of Expression of Nectin-4 in Esophageal Cancer

**Authors' Contribution:**

Study Design A  
Data Collection B  
Statistical Analysis C  
Data Interpretation D  
Manuscript Preparation E  
Literature Search F  
Funds Collection G

**ABCE 1 Xiaolong Lin**  
**DFG 1 Huijun Hu**  
**BCD 1 Yongquan Pan**  
**BCD 1 Yuping Pan**  
**ABF 2 Shuangquan Gao**

1 Department of Pathology, Huizhou Third People's Hospital, Guangzhou Medical University, Huizhou, Guangdong, P.R. China

2 Department of Pathology, Yuebei People's Hospital, Shaoguan, Guangdong, P.R. China

**Corresponding Authors:**

Xiaolong Lin, e-mail: [493814078@qq.com](mailto:493814078@qq.com), Shuangquan Gao, e-mail: [1530094537@qq.com](mailto:1530094537@qq.com)

**Source of support:**

Funding was provided by the Medical Foundation of Hui Zhou (No. 2019Y134) and the Medical Research Foundation of Guangdong Province (No. A2018099)

**Background:**

Nectin-4 is overexpressed in several human malignant tumors. This study aimed to investigate the expression of Nectin-4 in esophageal cancer tissues compared with adjacent normal esophageal tissue and its association with clinicopathological parameters and prognosis.

**Material/Methods:**

Nectin-4 expression in esophageal cancer tissues was compared with adjacent normal esophageal tissue from 94 patients using immunohistochemistry, Western blot, and quantitative reverse transcription-polymerase chain reaction (RT-qPCR). The chi-squared ( $\chi^2$ ) test and Fisher's exact test compared categorical variables. The log-rank test and Kaplan-Meier survival analysis assessed the relationship between Nectin-4 expression and overall survival (OS). Univariate and multivariate Cox proportional risk models compared Nectin-4 expression, patient prognosis, and clinicopathological parameters.

**Results:**

Nectin-4 expression was significantly increased in esophageal cancer tissue compared with normal tissue ( $P < 0.001$ ), tumor size  $\geq 4.5$  cm, and tumor invasion in T3/T4 compared with T1/T2 stage. Kaplan-Meier survival analysis showed that the OS of patients with increased Nectin-4 expression was significantly reduced compared with patients with low levels of Nectin-4 expression. Patient prognosis in men was less than women, tumor diameter  $\geq 4.5$  cm, lymph node involvement, and depth of invasion were associated with poor prognosis. Independent prognostic factors were Nectin-4 expression, lymph node involvement, and depth of invasion.

**Conclusions:**

In patients with esophageal cancer, the expression levels of Nectin-4, lymph node involvement, and depth of tumor invasion were independent prognostic factors. Further studies should be performed to evaluate the diagnostic and prognostic roles of Nectin-4 and its potential role as a therapeutic target.

**MeSH Keywords:**

**Carcinoma • Esophageal Neoplasms • Tumor Markers, Biological**

**Full-text PDF:**

<https://www.medscimonit.com/abstract/index/idArt/918288>

 1640

 3

 2

 22



## Background

Nectins are recently described cell junction molecules that belong to the immunoglobulin superfamily and participate in intercellular junction connections without the need for  $Ca^{2+}$  [1]. Members of the Nectin family are homophilic cell junction molecules that bind to a filamentous agonist binding protein, the multidomain F-actin-binding protein (afadin), through the cytoplasmic tail region, which connects to the actin cytoskeleton [2,3]. Nectins act synergistically or independently of cadherins and contribute to the formation of intercellular junctions [4]. Nectins also interact heterophilically with Nectin-like molecules (Necl), participate in cell junction formation, cell migration, and cell proliferation [4].

Nectin-4 is also known as poliovirus-receptor-like 4 (PVRL4), which has recently been shown to be expressed in some human malignancies. Several studies have shown that Nectin-4 may be a potential therapeutic target in human cancer [5–8]. Currently, studies have identified an association between the overexpression of Nectin-4 in breast cancer [5], lung cancer [6], and ovarian cancer [7], and has been associated with reduced prognosis. Previously reported studies have also shown increased expression of Nectin-4 in hepatocellular carcinoma (HCC) [8], cancer of the pancreas [9], stomach [10], and gallbladder [11]. The role of Nectin-4 in non-small cell lung cancer (NSCLC) cells was studied by Takano et al., who showed that overexpression of Nectin-4 induced by the activation of RAC1 could promote tumor cell growth and migration [12]. Nishiwada et al. [9] found that the levels of Nectin-4 in pancreatic cancer was significantly associated with increased expression of vascular endothelial growth factor (VEGF) and increased microvessel density, indicating that Nectin-4 expression promoted angiogenesis in tumor tissue. These findings also showed that Nectin-4 enhanced cell activity, including survival, migration, and proliferation, which may be associated with tumor metastasis and reduced survival rates. However, the role of Nectin-4 in tumor progression and prognosis in patients with esophageal cancer remains unknown. Therefore, this study aimed to investigate the expression of Nectin-4 in esophageal cancer tissue compared with adjacent normal esophageal tissue and its association with clinicopathological parameters and prognosis.

## Material and Methods

### Patients

The study cohort included 94 patients who underwent surgery for esophageal cancer between January 2006 to December 2010. Resected tumor tissue samples and adjacent normal esophageal tissues were collected and compared, where possible in 78/94 cases. In all cases, the diagnosis of primary esophageal cancer was confirmed histologically using hematoxylin and eosin (H&E) staining. Following histology, 82 samples of normal tissue were included. The clinical parameters of the patients included in the study are shown in Table 1. All patients who participated in the study provided informed consent. The study protocol was approved by the Ethics Committee of Huizhou Third Peoples' Hospital of Guangzhou Medical University and was in accordance with the requirements of the Helsinki declaration.

### Immunohistochemistry

Samples of tumor tissue and normal adjacent esophageal tissue were fixed in formalin and embedded in paraffin wax. Tissue sections were cut onto glass slides at a thickness of 4  $\mu$ m, dewaxed with xylene, and hydrated with graded alcohols. Immunohistochemical staining was performed using a Histostain-SP kit (CW Biotech Co. Ltd., Beijing, China), according to the manufacturer's instructions. Samples were finally stained with the brown chromogen, 3,3'-diaminobenzidine (DAB) and counterstained with hematoxylin, mounted, and coverslipped.

Nectin-4 immunostaining was localized to the cytoplasm and cell surface of the tumor cells. The immunostaining was assessed by light microscopy using a scoring system that included, lack of immunostaining (0 points), light yellow immunostaining (1 points), brown yellow immunostaining (2 points), and brown immunostaining (3 points). Immunostained areas were scored to include lack of immunostaining (0 points), immunostained area  $<1/3$  (1 point), immunostained area  $1/3$ – $2/3$  (2 points), and immunostained area  $>2/3$  (3 points). The sum of the two scores (degree and area of immunostaining) were used for analysis and included negative ( $<3$  points), and positive ( $\geq 3$  points). Two professional pathologists interpreted the immunohistochemical scores by light microscopy. If there was disagreement in the results of two independent pathologists, a consensus was achieved with

**Table 1.** Nectin-4 positivity in esophageal cancer tissue and adjacent normal esophageal tissue.

Tissue	Cases (n)	Nectin-4 expression		$\chi^2$	P-value
		Negative	Positive		
Esophageal cancer tissue	82	12	70	55.12	0.000
Adjacent normal tissue	70	52	18		

a third pathologist. All pathologists were unaware of the clinical data of the patients in the study.

### Quantitative reverse transcription-polymerase chain reaction (RT-qPCR)

Nectin-4 mRNA expression in esophageal cancer tissues and adjacent normal esophageal tissue was investigated by qRT-PCR, as previously described [13]. Values were normalized to GAPDH. Relative mRNA expression was assessed using the  $2^{-\Delta\Delta CT}$  method. The primers used in the study included: GAPDH, forward: 5'-AGGTCGGGTGTAACGGATTG-3'; GAPDH, reverse: 5'-GGGGTCGTTGATGGCAACA-3'; Nectin-4, forward: 5'-CTGAGCAGGTTCCAGGTTT-3'; Nectin-4, reverse: 5'-AGAGTCTTGCCTCTCGCAC-3'.

### Western blot

Tissues were lysed in RIPA lysis buffer (cat. no. P0013B) (Beyotime, Shanghai, China) and separated using 10% sodium dodecyl sulfate-polyacrylamide gel electrophoresis (SDS-PAGE). Samples were transferred to nitrocellulose membranes and blocked in 5% dried skimmed milk powder for 1 h. Membranes were probed overnight at 4°C, with primary antibodies, including a rabbit anti-human antibody to Nectin-4 (dilution, 1: 1000) (cat. no. ab155692) (Abcam, Inc., San Diego, CA, USA), and  $\beta$ -actin (dilution, 1: 2000) (cat. no. AF0003) (Beyotime, Shanghai, China). Membranes were washed in Tris-buffered saline, 0.1% Tween 20 (TBST) buffer and labeled with the corresponding horseradish peroxidase (HRP)-conjugated secondary antibodies (dilution, 1: 2000) (cat. no. A0216) (Beyotime, Shanghai, China) at room temperature for 1 h. Blots were visualized using a Tannon 5500 electrochemiluminescence (ECL) microplate reader (Tannon, Beijing, China), as previously described [14].

### Statistical analysis

Data were analyzed using SPSS software (IBM, Chicago, IL, USA) and GraphPad Prism version 6.01 software (GraphPad Software, La Jolla, CA, USA). Normally distributed data were compared with Student's t-test. The chi-squared ( $\chi^2$ ) test or Fisher's exact test were used to compare categorical variables, which were expressed as a percentage. Kaplan-Meier and log-rank tests were used for comparison of the prognostic differences in patients according to Nectin-4 expression for univariate and multivariate Cox hazard ratio (HR) models. A P-value <0.05 was considered to be statistically significant.

## Results

### Nectin-4 expression in esophageal cancer tissue and adjacent normal esophageal tissue

During the interpretation of Nectin-4 staining, seven pairs of esophageal cancer tissue and adjacent normal esophageal tissue, and four cases of core tissue samples were not included, due to missing clinical data or lack of survival data. A single pair of cancer and adjacent tissues were excluded due to lack of information. The remaining 70 patient samples of esophageal cancer and 12 samples of normal adjacent esophageal tissue were included for immunohistochemistry analysis (Figure 1). Figure 1 shows that Nectin-4 immunostaining (brown) was localized to the cytoplasm of the tumor cells. Compared with normal adjacent esophageal tissue, the Nectin-4 expression rates were significantly increased in cancer tissue at the mRNA and protein level (Figures 1, 2) (Table 1) ( $P<0.001$ ).

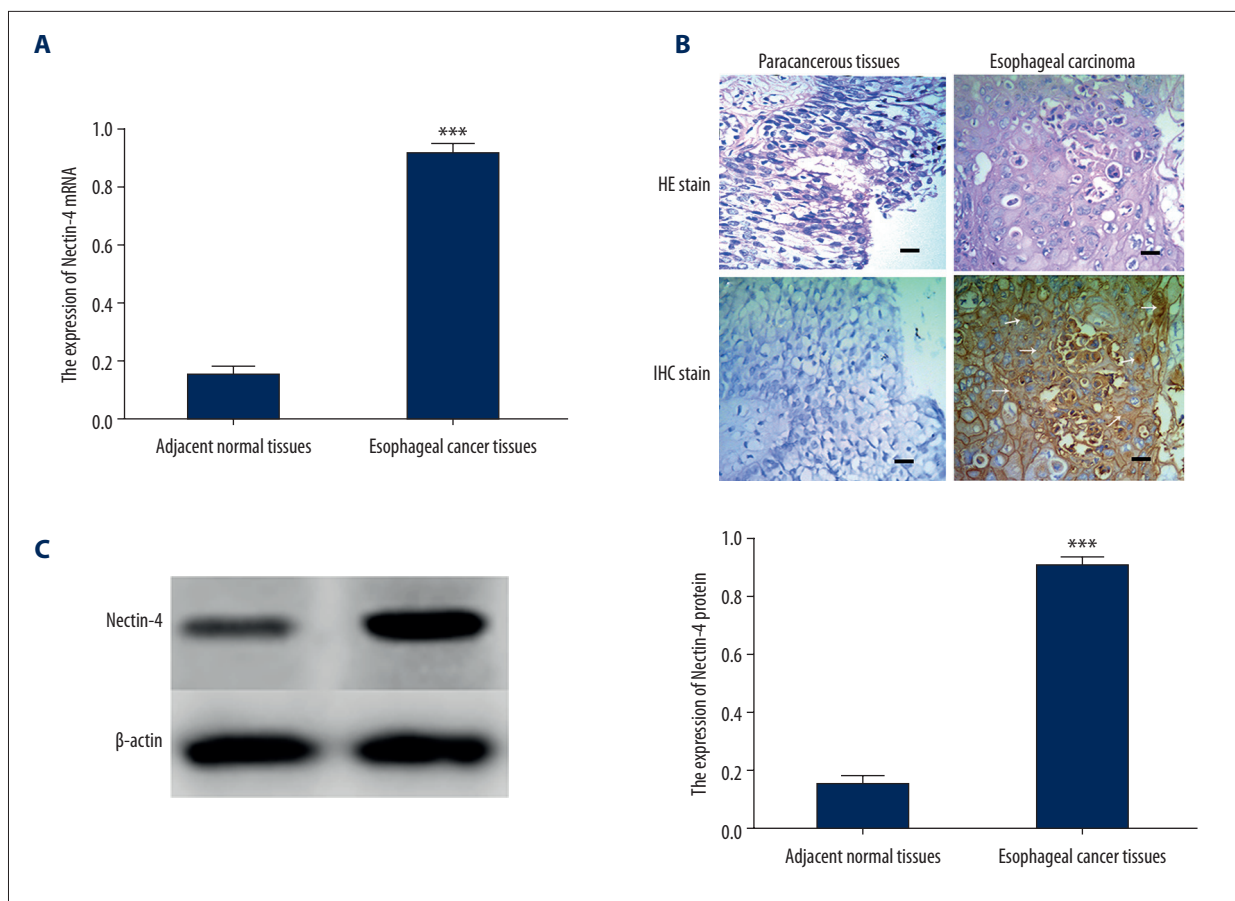
### Nectin-4 expression in esophageal cancer and patient characteristics

Nectin-4 expression was positive in 37.8% (31/82) of esophageal cancer tissues. The chi-squared ( $\chi^2$ ) test and Fisher exact test showed that Nectin-4 positivity was significantly associated with tumor size ( $\chi^2=6.385$ ;  $P=0.012$ ) and depth of tumor invasion ( $\chi^2=7.081$ ;  $P=0.008$ ). The chi-squared ( $\chi^2$ ) test showed no significant differences in Nectin-4 expression according to gender, age, the American Joint Committee on Cancer (AJCC) stage, lymph node invasion, or other clinicopathological characteristics (Table 2).

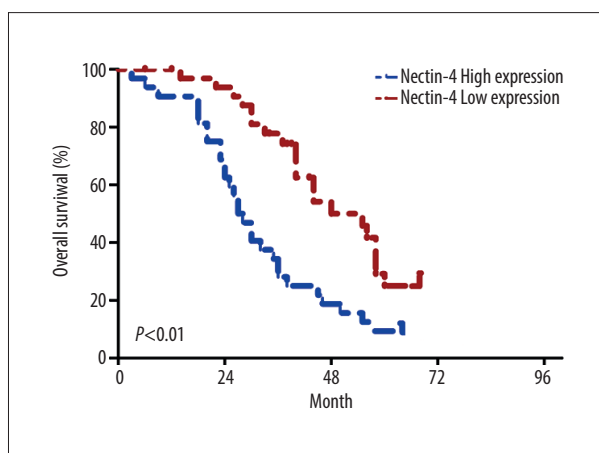
### Nectin-4 expression and prognosis in esophageal cancer

The follow-up period of the study was up to May 2019. The median survival time was 25.0 months. Kaplan-Meier analysis, univariate and multivariate Cox hazard ratio (HR) models were used to measure the hazard ratio (HR) for patient prognosis using multiple parameters to determine the effect of Nectin-4 expression and other clinical characteristics on patient prognosis in esophageal cancer.

Patients with positive Nectin-4 expression, determined by Kaplan-Meier and log-rank survival analysis, had significantly lower odds ratios (ORs) compared with patients with negative Nectin-4 expression (Figure 2) (HR=1.747; 95% CI, 1.003–3.044;  $P<0.05$ ). As shown in Table 3, the univariate Cox HR model showed that tumor diameter  $\geq 4.5$  cm (HR=1.674;  $P=0.044$ ), the depth of invasion (HR=2.950;  $P=0.008$ ), lymph node involvement (HR=2.518;  $P=0.003$ ) and Nectin-4 positivity (HR=1.704;  $P=0.039$ ) were associated with reduced patient prognosis. Prognosis in patients with esophageal cancer was significantly worse in men than women (HR=2.618;  $P=0.008$ ).



**Figure 1.** Nectin-4 expression in esophageal cancer and adjacent normal esophageal tissue. **(A)** Quantitative reverse transcription-polymerase chain reaction (RT-qPCR) analysis (\*\*\*)  $P < 0.001$  for esophageal cancer tissue vs. normal esophageal tissue). **(B)** Photomicrographs of the histology and immunohistochemistry. In esophageal cancer tissue, Nectin-4 immunostaining was localized to the cytoplasm and cell surface of esophageal cancer cells but was weakly expressed in adjacent normal tissue (scale bar=50 μm; magnification ×c400). The white arrows show areas of Nectin-4 expression. **(C)** Western blot analysis (\*\*\*)  $P < 0.001$  for esophageal cancer tissue vs. normal esophageal tissue).



**Figure 2.** Nectin-4 was negatively correlated with the overall survival (OS) of patients with esophageal cancer. Survival analysis in patients with esophageal cancer with high vs. low Nectin-4 expression.

The multivariate Cox HR model for Nectin-4 expression (HR=1.795;  $P=0.035$ ), the depth of invasion (HR=2.121;  $P=0.087$ ), lymph node involvement (HR=1.689;  $P=0.086$ ) were independent prognostic factors for esophageal cancer.

### Discussion

Esophageal cancer is a common malignant tumor that is often diagnosed at a late stage when it is associated with lymph node metastases, as early-stage esophageal cancer can be asymptomatic. To optimize the diagnosis and treatment of esophageal cancer, a more detailed understanding of the pathogenesis of this malignancy is required [15]. The findings from the present study showed that Nectin-4 expression was significantly increased in esophageal cancer and was significantly correlated with tumor size, stage, and prognosis. These findings were consistent with those from a previous study [14].

**Table 2.** Distribution of Nectin-4 in esophageal cancer and patient clinicopathological characteristics.

Characteristic	Number of patients	Nectin-4 expression		$\chi^2$	P-value
		Nectin-4 negative	Nectin-4 positive		
Age (years)					
<60	23	6	17	0.004	0.951
≥60	59	15	44		
Gender					
Male	62	17	45	0.437	0.509#
Female	20	4	16		
Tumor size (cm)					
<4.5	43	16	27	6.385	0.012*
≥4.5	39	5	34		
AJCC stage					
I–II	45	11	32	0.021	0.884
III–IV	37	10	27		
Tumor invasion (T stage)					
T1/T2	19	9	10	7.081	0.008*
T3/T4	63	11	52		
Lymph node metastasis					
Absent	44	12	32	0.095	0.922
Present	38	10	28		

AJCC – American Joint Committee on Cancer. Values were analyzed using the chi-squared ( $\chi^2$ ) test or Fisher's exact test. # Incomplete data were removed. \*  $P < 0.05$ .

**Table 3.** Factors that influenced the overall survival (OS) of patients with esophageal cancer assessed by Cox regression analysis.

Characteristics	Univariate analysis		Multivariate analysis	
	HR (95% CI)	P-value	HR (95% CI)	P-value
Gender: (Male: Female)	2.618 (1.285–5.337)	0.008*	1.827 (0.765–4.364)	0.175
Age (years): (<60: ≥60)	1.093 (0.630–1.894)	0.752	1.543 (0.828–2.878)	0.172
Tumor size: (≥4.5 cm: <4.5 cm)	1.674 (1.014–2.763)	0.044*	1.363 (0.792–2.346)	0.264
Stage: (III–IV: I–II)	0.805 (0.436–1.485)	0.487	0.723 (0.377–1.385)	0.328
Tumor invasion: (T3/T4: T1/T2)	2.950 (0.923–7.127)	0.008*	1.613 (0.898–5.021)	0.087
Lymph node metastasis: (present: absent)	2.518 (1.290–3.609)	0.003*	1.689 (0.928–3.074)	0.086
Nectin-4 expression: (high: low)	1.704 (1.027–2.825)	0.039*	1.795 (1.042–3.092)	0.035*

HR – hazard ratio; CI – confidence interval. Univariate and multivariate Cox regression analysis. The clinical data is incomplete sample have been removed. \*  $P < 0.05$  was considered as statistically significant.

Nectin-4 has been proposed as a diagnostic biomarker for several cancers [6–11], including gastric cancer, where it has been shown to promote cancer cell differentiation, lymph node metastasis and is associated with advanced TNM stage [16,17]. Dysregulated expression of Nectin-4 have been shown in human breast cancer [18–20], and pancreatic carcinoma [9]. The molecular mechanisms underlying the oncogenic effects of Nectin-4 are poorly understood, but overexpression has been shown to promote tumor angiogenesis [21], activate PI3K/AKT signaling [10,11,22] and enhance tumor growth *in vivo* [14]. Further studies are required to fully understand these oncogenic effects of Nectin-4. The findings from the present study highlighted the association between Nectin-4 expression and reduced patient prognosis in esophageal cancer. Therefore, Nectin-4 may be a promising prognostic biomarker in esophageal cancer.

## References:

- Mizutani K, Takai Y: Nectin spot: A novel type of nectin-mediated cell adhesion apparatus. *Biochem J*, 2016; 473: 2691–715
- Takekuni K, Ikeda W, Fujito T et al: Direct binding of cell polarity protein PAR-3 to cell-cell adhesion molecule nectin at neuroepithelial cells of developing mouse. *J Biol Chem*, 2003; 278: 5497–500
- Li M, Qiao D, Pu J et al: Elevated Nectin-2 expression is involved in esophageal squamous cell carcinoma by promoting cell migration and invasion. *Oncol Lett*, 2018; 15: 4731–36
- Sakisaka T, Takai Y: Biology and pathology of nectins and nectin-like molecules. *Curr Opin Cell Biol*, 2004; 16: 513–21
- Siddharth S, Goutam K, Das S et al: Nectin-4 is a breast cancer stem cell marker that induces WNT/beta-catenin signaling via Pi3k/Akt axis. *Int J Biochem Cell Biol*, 2017; 89: 85–94
- Takano A, Ishikawa N, Nishino R et al: Identification of nectin-4 oncoprotein as a diagnostic and therapeutic target for lung cancer. *Cancer Res*, 2009; 69: 6694–703
- Derycke MS, Pambuccian SE, Gilks CB et al: Nectin 4 overexpression in ovarian cancer tissues and serum: Potential role as a serum biomarker. *Am J Clin Pathol*, 2010; 134: 835–45
- Guangzheng S, Yilei W, Haifeng Z et al: [Expression of nectin-4 in hepatocellular carcinoma and its clinical significance.] *Journal of Wezhou Medical University*, 2015; 45: 887–89 [in Chinese]
- Nishiwada S, Sho M, Yasuda S et al: Nectin-4 expression contributes to tumor proliferation, angiogenesis and patient prognosis in human pancreatic cancer. *J Exp Clin Cancer Res*, 2015; 34: 30
- Zhang Y, Chen P, Yin W et al: Nectin-4 promotes gastric cancer progression via the PI3K/AKT signaling pathway. *Hum Pathol*, 2018; 72: 107–16
- Zhang Y, Liu S, Wang L et al: A novel PI3K/AKT signaling axis mediates Nectin-4-induced gallbladder cancer cell proliferation, metastasis and tumor growth. *Cancer Lett*, 2016; 375: 179–89
- Takano A, Ishikawa N, Nishino R et al: Identification of nectin-4 oncoprotein as a diagnostic and therapeutic target for lung cancer. *Cancer Res*, 2009; 69: 6694–703
- Chen L, Xiong Y, Li J et al: PD-L1 expression promotes epithelial to mesenchymal transition in human esophageal cancer. *Cell Physiol Biochem*, 2017; 42: 2267–80
- Deng H, Shi H, Chen L et al: Over-expression of Nectin-4 promotes progression of esophageal cancer and correlates with poor prognosis of the patients. *Cancer Cell Int*, 2019; 19: 106
- Liu X, An T, Li D et al: Structure of the heterophilic interaction between the nectin-like and nectin-like 1 molecules. *Proc Natl Acad Sci USA*, 2019; 116: 2068–77
- Zhang Y, Zhang J, Shen Q et al: High expression of Nectin-4 is associated with unfavorable prognosis in gastric cancer. *Oncol Lett*, 2018; 15(6): 8789–95
- Zhang Y, Chen P, Yin W et al: Nectin-4 promotes gastric cancer progression via the PI3K/AKT signaling pathway. *Hum Pathol*, 2018; 72: 107–16
- M-Rabet M, Cabaud O, Josselin E et al: Nectin-4: A new prognostic biomarker for efficient therapeutic targeting of primary and metastatic triple-negative breast cancer. *Ann Oncol*, 2017; 28: 769–76
- Rajc J, Gugic D, Frohlich I et al: Prognostic role of Nectin-4 expression in luminal B (HER2 negative) breast cancer. *Pathol Res Pract*, 2017; 213: 1102–8
- Athanassiadou AM, Patsouris E, Tshipis A et al: The significance of Survivin and Nectin-4 expression in the prognosis of breast carcinoma. *Folia Histochem Cytobiol*, 2011; 49: 26–33
- Siddharth S, Nayak A, Das S et al: The soluble nectin-4 ecto-domain promotes breast cancer induced angiogenesis via endothelial integrin-beta4. *Int J Biochem Cell Biol*, 2018; 102: 151–60
- Siddharth S, Goutam K, Das S et al: Nectin-4 is a breast cancer stem cell marker that induces WNT/beta-catenin signaling via Pi3k/Akt axis. *Int J Biochem Cell Biol*, 2017; 89: 85–94

## Conclusions

This study aimed to investigate the expression of Nectin-4 in esophageal cancer tissue compared with adjacent normal esophageal tissue and its association with clinicopathological parameters and prognosis. In patients with esophageal cancer, the expression levels of Nectin-4, lymph node involvement, and depth of tumor invasion were independent prognostic factors. Further studies should be performed to evaluate the diagnostic and prognostic role of Nectin-4 and its potential role as a therapeutic target.

## Conflict of interest

None.