



Case Report

A rare case of neurosarcoidosis occurred only in the medulla oblongata mimicking malignant brain tumor

Kentaro Murayama¹, Akihiro Inoue¹, Yawara Nakamura¹, Masayuki Ochi², Seiji Shigekawa¹, Hideaki Watanabe¹, Riko Kitazawa³, Takeharu Kunieda¹

Departments of ¹Neurosurgery, ²Neurology and Geriatric Medicine, Ehime University School of Medicine, ³Department of Diagnostic Pathology, Ehime University Hospital, Toon, Ehime, Japan.

E-mail: Kentaro Murayama - nanagon19940820@gmail.com; *Akihiro Inoue - iakihiro3@gmail.com; Yawara Nakamura - y.nkmr6084@gmail.com; Masayuki Ochi - ochimasa@m.ehime-u.ac.jp; Seiji Shigekawa - shigekawa.seiji@gmail.com; Hideaki Watanabe - whideaki@m.ehime-u.ac.jp; Riko Kitazawa - riko@m.ehime-u.ac.jp; Takeharu Kunieda - kuny@m.ehime-u.ac.jp



*Corresponding author:

Akihiro Inoue,
Department of Neurosurgery,
Ehime University School of
Medicine, Toon, Ehime, Japan.
iakihiro3@gmail.com

Received : 25 February 2021

Accepted : 20 April 2021

Published : 31 May 2021

DOI

10.25259/SNI_195_2021

Quick Response Code:



ABSTRACT

Background: Sarcoidosis is a multisystem disorder characterized by noncaseating epithelioid granulomas. However, neurosarcoidosis occurring only in the medulla oblongata is very rare and lacks specific imaging and clinical features. We report a rare case of neurosarcoidosis arising from the medulla oblongata alone, suggesting the significance of pathological findings for accurate diagnosis.

Case Description: A 78-year-old woman with a history of rheumatoid arthritis was admitted to our hospital with a 3-month history of progressive numbness in bilateral lower extremities and gait disturbance. Neurological examination on admission showed mild bilateral paired paralysis of the lower limbs (manual muscle test: right 2/V; left 4/V) and marked numbness in the right lower limb. Neuroimaging revealed a solid mass with clear boundaries in the dorsal medulla oblongata appearing hypointense on T1-weighted imaging (WI), hyperintense on T2-WI, and hypointense on diffusion WI (DWI), with strong enhancement on gadolinium-enhanced T1-WI. Cerebrospinal fluid analysis showed moderately elevated levels of protein and lymphocytic cells. Biopsy to determine the exact diagnosis revealed histological findings of noncaseating epithelioid granulomas and inflammatory infiltration, consistent with sarcoidosis. Postoperatively, corticosteroid therapy with prednisolone was initiated as soon as possible, resulting in marked reductions in lesion size. Follow-up neuroimaging after 12 months showed no signs of recurrence.

Conclusion: Neurosarcoidosis is difficult to diagnose from routine neuroimaging and laboratory findings. Accurate diagnosis requires careful identification of clinical signs, hypointensity on DWI, and morphological findings from surgical biopsy.

Keywords: Medulla oblongata, Neurosarcoidosis, Noncaseating epithelioid granuloma, Pathological finding

INTRODUCTION

Sarcoidosis is a multisystemic disorder of unknown etiology.^[2] Clinically, sarcoidosis causes damage in practically all organs, including the lungs, eyes, lymph nodes, heart, and nerves.^[2] Previous reports have described the involvement of the nervous system, as so-called “neurosarcoidosis,” in 5.0–27% of cases of systemic sarcoidosis. However, isolated neurosarcoidosis is extremely rare, occurring in only 1.0% of patients of neurosarcoidosis.^[1,2,7]

This is an open-access article distributed under the terms of the Creative Commons Attribution-Non Commercial-Share Alike 4.0 License, which allows others to remix, tweak, and build upon the work non-commercially, as long as the author is credited and the new creations are licensed under the identical terms.

©2021 Published by Scientific Scholar on behalf of Surgical Neurology International

Neurosarcoidosis in the medulla oblongata is particularly rare, with only four cases reported previously [Table 1].^[2,6-8] Therefore, it may be assumed to discriminate intracranial neurosarcoidosis from other neurological disorders, especially in the absence of extracranial disease.^[8,12] In addition, since neurosarcoidosis can mimic brain tumors in radiographical features and clinical course, we should be careful to differentiate from primary brain tumors such as astrocytoma, ependymoma, meningioma, intrathecal masses, or infectious diseases of the central nervous system (CNS).^[3,5,13] Here, we report a rare case of neurosarcoidosis identified only in the medulla oblongata, suggesting the significance of pathological findings in achieving definite diagnosis.

CASE DESCRIPTION

A 78-year-old woman with a history of rheumatoid arthritis was admitted to our hospital with a 3-month history of progressive numbness in both lower extremities and gait disturbance. Neurological examination on admission showed mild paralysis of both lower limbs (manual muscle test: right 2/V; left 4/V) and pronounced numbness in the right lower limb. Magnetic resonance imaging (MRI) revealed a solid mass with clear borders in the dorsal medulla oblongata, appearing hypointense on diffusion-weighted imaging (DWI), fluid-attenuated inversion recovery, and T1-WI (WI), and hyperintense on T2-WI, with strong enhancement on gadolinium (Gd)-enhanced T1-WI [Figure 1]. Computed tomography (CT) of the head showed a low-attenuating lesion in the same region. Cerebral angiography did not show any vascular abnormalities. Neither whole-body CT nor chest X-ray revealed any obvious abnormalities, including bilateral hilar lymphadenopathy [Figure 2a]. No dissemination was evident on MRI of the whole spinal cord [Figure 2b]. Cerebrospinal fluid (CSF) analysis showed

moderately elevated levels of both protein (227 mg/dL) and lymphocytic cells (52/ μ L), while concentrations of various markers including angiotensin-converting enzyme (ACE) and soluble interleukin-2 receptor (sIL2-R) remained within normal limits. However, β 2-microglobulin (β 2-MG) was slightly elevated. Preoperative differential diagnoses included malignant glioma, malignant lymphoma, metastatic tumor, and infectious or inflammatory diseases. To confirm the histological diagnosis and plan effective treatment for the primary disease, we performed surgical biopsy of the enhanced lesion under a midline suboccipital approach with image-guided navigation [Figure 3a]. Intraoperative findings demonstrated that this lesion was gray to yellowish in color and extremely firm without bleeding [Figures 3b and c]. Histopathological examination with hematoxylin and eosin staining demonstrated noncaseating granuloma consisting of epithelioid cells [Figure 4a] with infiltration of macrophages, multinucleated giant cells, and lymphocytes [Figure 4b-d]. Taken all these results into account, the final diagnosis was sarcoidosis limited to the medulla oblongata. Corticosteroid therapy was started with prednisolone as a therapeutic maneuver at the same time for diagnostic purpose. Three months after starting that treatment, MRI showed a marked reduction in the size of the Gd-enhanced lesion on T1-WI [Figures 5a-c]. The perioperative course was uneventful, and numbness in both lower extremities and gait disturbance resolved gradually. The patient remained clinically stable, and all residual lesions had completely disappeared in MRI by the 1-year follow-up [Figures 5d-f].

DISCUSSION

Sarcoidosis is a granulomatous disease that is usually systemic and may include the CNS, as so-called neurosarcoidosis.^[2-5,8,13] Neurosarcoidosis is rare, occurring in about 5.0% of sarcoidosis (range, 1.0–27.0%); this pathology primarily

Table 1: Clinical features of five cases with neurosarcoidosis in the medulla oblongata.

No.	Author (year)	Age (y), sex	Signs and symptoms	Lymphadenopathy	Surgery	Medication (period)	Evaluation (follow-up period)
1	Mahadewa et al. (2004)	59 M	Numbness/deep sensory dis. (bil. lower limbs)	None	Biopsy	Predonin (4.5 m)	CR (1.3 m)
2	John et al. (2012)	45 M	Rt. Horner's S, diffuse hyperreflexia, Rt. vocal cord paralysis	Mediastinal and hilar	None	Steroids, MTX (NS)	PR (5.0 m)
3	Lee et al. (2013)	61 F	Diplopia, nystagmus, dysarthria, dysphasia, numbness (bil. upper and lower limbs)	None	Biopsy	Steroid pulse therapy (NS)	PR (9.0 m)
4	Chen et al. (2018)	55 F	Numbness/deep sensory dis. (bil. upper and lower limbs)	Supraclavicular, hilar, mediastinal	None	Prednisone (7.0 m)	CR (7.0 m)
5	Present case	78 F	Numbness/paired paralysis (bil. lower limbs)	None	Biopsy	Prednisolone (>12.0 m)	CR (12.0 m)

No.: Number, y: Years, M: Male, F: Female, dis.: Disturbance, bil.: Bilateral, Rt.: Right, S: Syndrome, STR: Subtotal resection, MTX: Methotrexate, NS: Not stated, CR: Complete response, PR: Partial response

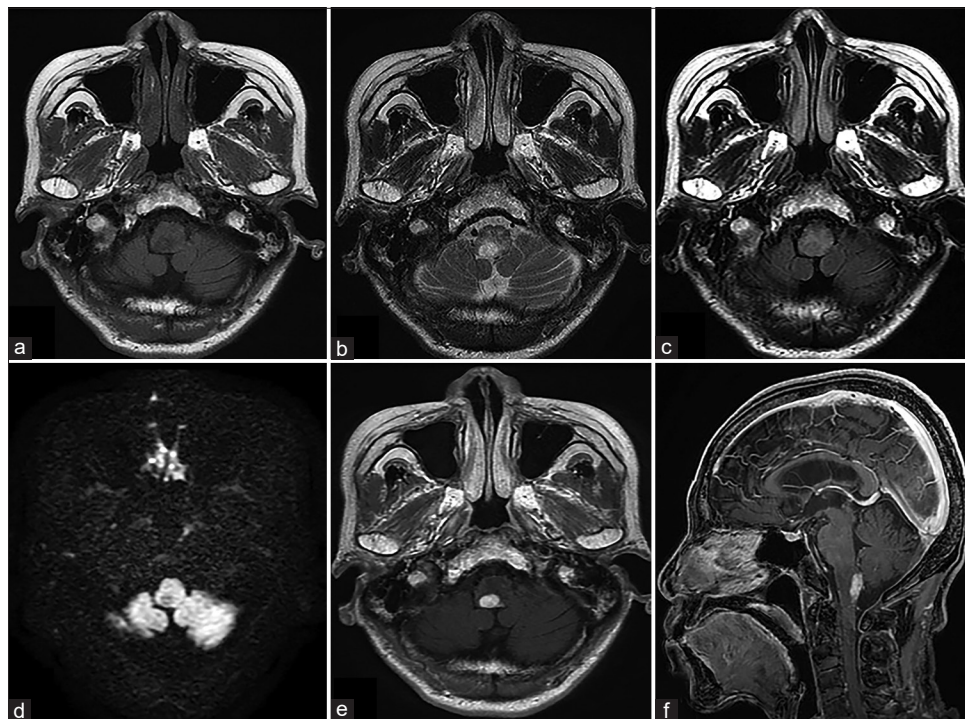


Figure 1: Preoperative axial T1-weighted (a), T2-weighted (b), fluid-attenuated inversion recovery (c), diffusion-weighted (d) and gadolinium-enhanced T1-weighted (e) magnetic resonance imaging shows a solid mass at the dorsal medulla oblongata (f). The tumor shows prominent homogeneous enhancement with gadolinium.

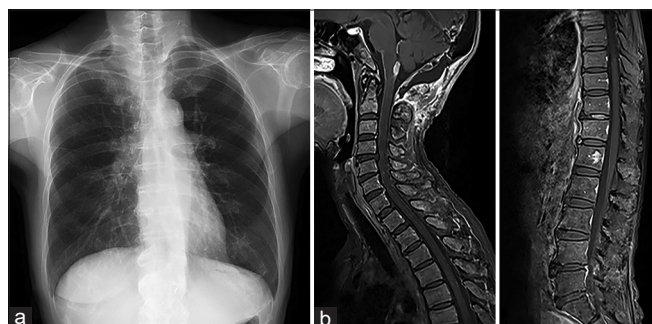


Figure 2: Preoperative chest X-ray and magnetic resonance imaging. (a) Chest X-ray does not show any obvious abnormalities, including bilateral hilar lymphadenopathy. (b) No dissemination is evident on magnetic resonance imaging of the whole spinal cord.

involves the leptomeninges, although parenchymal invasion is common.^[2,4,5,7,8,13] However, isolated neurosarcoidosis is even rarer and occurs in only 1.0% of patients with neurosarcoidosis.^[2,7] The present case was thus extremely rare and patients with isolated neurosarcoidosis in the medulla oblongata should be treated with extremely caution.

Clinically, neurosarcoidosis tends to be more common than ordinary sarcoidosis in older women.^[10] Importantly, neurological abnormalities represent the first clinical manifestation in 70–80% of patients with neurosarcoidosis and can include multiple cranial nerve palsies, peripheral

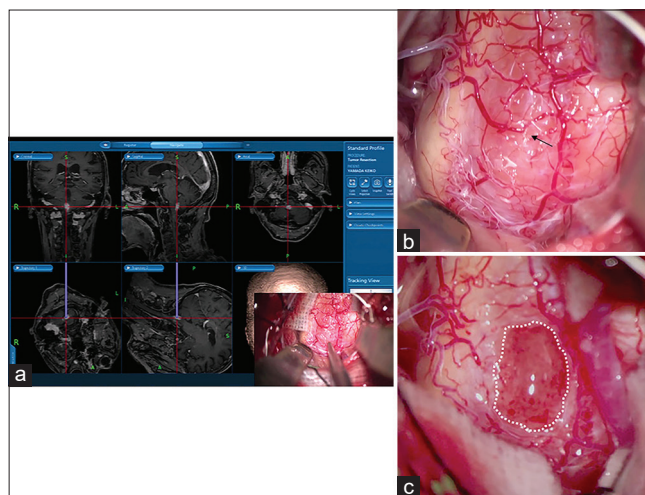


Figure 3: Intraoperative microscopic findings from craniotomy using a midline suboccipital approach. (a) The neuronavigation system demonstrates locations of the lesion in the microscopic view. (b) Microscopic examination of this lesion shows a solid, rubbery firm mass (black arrow). (c) The cut surface (white dashed circle) is gray to yellowish in color.

neuropathy, myopathy, and hydrocephalus.^[8] Laboratory findings can include mild leukocytosis, eosinophilia, and an increased erythrocyte sedimentation rate.^[8,10,12] ACE is abnormally elevated in 50–83% of sarcoidosis patients.^[2,5,8]

CSF examination yields results similar to common subacute meningitis.^[5,8] In addition, sIL2-R and β 2-MG in the CSF may be elevated.^[2,8,10] Preoperative CT and MRI show solid masses with clear boundaries.^[2,7,8,12] The solid masses almost always show relatively low attenuation on CT, and calcification is extremely rare. MRI generally depicts this

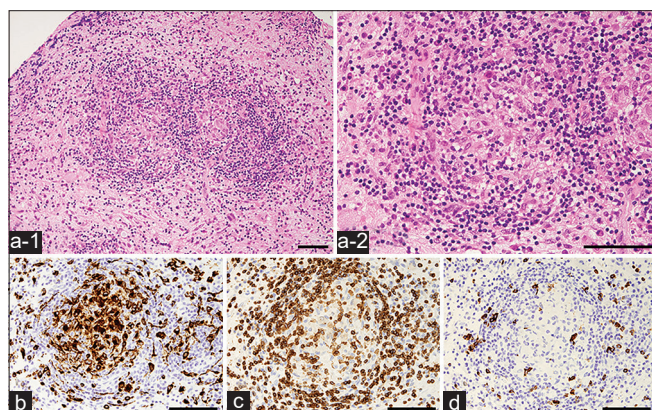


Figure 4: (a) Histopathology of the resected lesion shows a noncaseating granuloma comprising epithelioid cells without evidence of cellular atypia or mitotic figures (hematoxylin and eosin staining). Staining shows infiltration of lymphocytes and macrophages. (b-d) Immune cells show positive staining for CD68 (b) and CD3 (c), but very slight staining for CD20 (d). Magnification: (a-1) x200; a-2, (b-d) x400. Scale bars, 100 μ m.

mass as iso- to hypointense on T1-WI and hyperintense on T2-WI, and homogeneous enhancement has been seen after administration of contrast agents.^[2,8,10] In the present case, the lesion was seen as a hypointense mass on DWI, with strong contrast enhancement by Gd. This hypointensity on DWI was extremely interesting and seems to represent a key finding for making preoperative differentiation of neurosarcoidosis from other pathologies. However, since neurosarcoidosis lacks specific clinical, experimental, and radiological features, the diagnosis of neurosarcoidosis is challenging and misdiagnosis of primary brain tumors or infectious disorders of the CNS may result. Therefore, surgical biopsy appears essential to make an exact diagnosis of neurosarcoidosis.^[2,8,11]

Microscopically, the histopathological characteristics of sarcoidosis are demonstrated by noncaseating epithelioid granuloma formation.^[2,7,8,10] Granulomas in sarcoidosis generally comprise mature epithelial cells approximately 200–300 μ m in diameter.^[5,9] These lesions often appear fused in a bead-like structure and the granulomas display well-defined borders with the surrounding parenchyma. However, epithelioid cell granulomas are often associated with lymphoproliferative diseases. Particularly in T-lymphocytic lymphoma, epithelioid cells appear more frequently, and lymphoepithelioid variant lesions are observed.^[5,9] Therefore, it is important for diagnosis to confirm that the granuloma infiltrated by lymphocytes is not

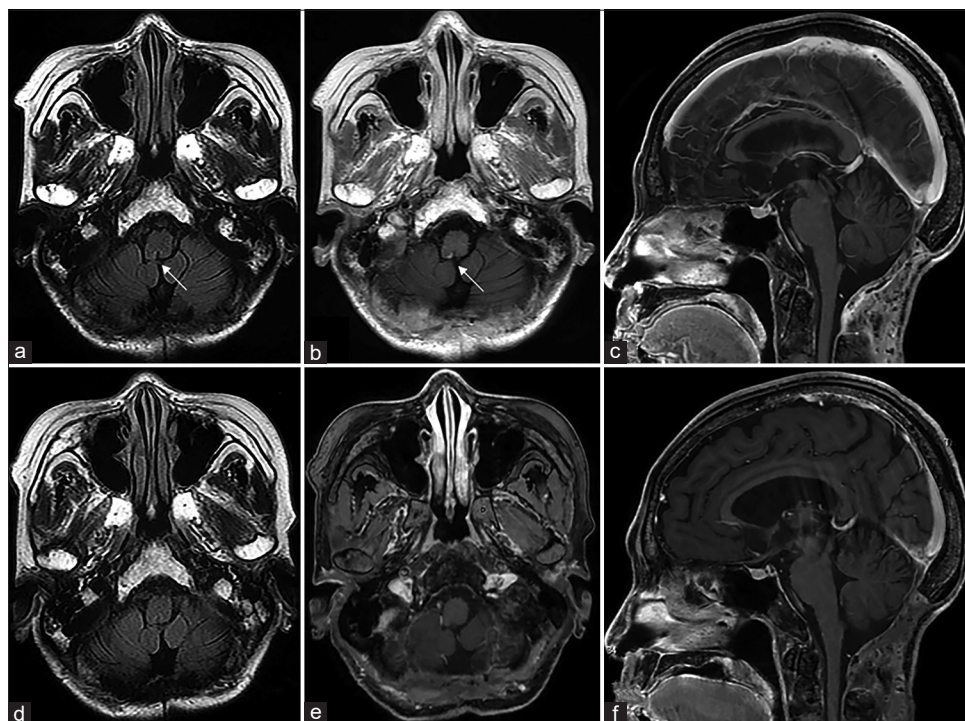


Figure 5: (a-c) Three months after starting treatment, magnetic resonance imaging shows marked reductions in mass size on fluid-attenuated inversion recovery imaging and gadolinium-enhanced T1-weighted imaging (white arrows). (d-f) All residual lesions have disappeared by the 1-year follow-up.

neoplastic.^[5,9] For neurosarcoidosis in the medulla oblongata without evidence of systemic sarcoidosis, biopsy should be considered whenever possible, as differential diagnosis based on the clinical presentation and radiological findings cannot exclude the possibility of tumors such as malignant glioma or malignant lymphoma. In the present case, clinical and imaging findings did not lead to a definitive diagnosis, but surgical biopsy confirmed the presence of noncaseating epithelioid granuloma as a pathological finding, leading to the definitive diagnosis of neurosarcoidosis.

Finally, regarding the treatment of neurosarcoidosis, the optimal treatment remains to be determined.^[2,8,10] Several published cases and case series have described immunosuppressive treatments, including administration of corticosteroids with or without additional immunosuppressive therapy.^[2,7,8,10] However, the optimal duration of treatment also remains unclear, and relapse on withdrawal of immunosuppressants has been reported.^[2,7,8,12] In the present case, administration of prednisolone alone proved sufficient to elicit rapid and persistent clinical and radiological improvements throughout 12 months of follow-up. Accumulation of the cases and longer patient follow-up are both required.

CONCLUSION

We suggest that neurosarcoidosis should be included as an important differential diagnosis for intramedullary malignant brain tumor. Even if the patient shows no evidence of systemic sarcoidosis, consideration of neurosarcoidosis is very important. Careful identification of clinical signs, MRI findings including hypointensity on DWI and detailed histopathological evaluation of specimens from surgical biopsy are necessary for accurate diagnosis of neurosarcoidosis. In addition, accurate recognition of these pathological findings may expedite appropriate treatment with steroids while avoiding unnecessary extensive surgery.

Declaration of patient consent

The authors certify that they have obtained all appropriate patient consent.

Financial support and sponsorship

Nil.

Conflicts of interest

There are no conflicts of interest.

REFERENCES

1. Caneparo D, Lucetti C, Nuti A, Cipriani G, Tessa C, Fazzi P, *et al.* A case of sarcoidosis presenting as a non-specific intramedullary lesion. *Eur J Neurol* 2007;14:346-9.
2. Chen XY, Ren ZC, Huang XJ. Sarcoidosis of the medulla oblongata causing intractable hiccoughs and numbness of extremities: A case report. *Medicine (Baltimore)* 2018;97:e13667.
3. Dennis AN, Darius CW. Neurosarcoidosis: A review of its intracranial manifestation. *J Neurol* 2001;248:363-72.
4. Ferriby D, Seze JD, Stojkovic T, Hachulla E, Wallaert B, Destee A, *et al.* Long-term follow-up of neurosarcoidosis. *Neurology* 2001;57:927-9.
5. Jarnier D, Series C. Neurosarcoidosis: Review of the literature. *Neurochirurgie* 1999;45:214-8.
6. John S, Parambil J, Culver D, Tavee J. Medullary neurosarcoidosis presenting with intractable hiccoughs. *J Clin Neurosci* 2012;19:1193-5.
7. Lee JH, Takai K, Ota M, Shimizu T, Komori T, Taniguchi M. Isolated neurosarcoidosis in the medulla oblongata involving the fourth ventricle: A case report. *Br J Neurosurg* 2013;27:393-5.
8. Mahadewa TG, Nakagawa H, Watabe T, Inoue T. Intramedullary neurosarcoidosis in the medulla oblongata: A case report. *Surg Neurol* 2004;61:283-7.
9. Negi M, Takemura T, Guzman J, Uchida K, Furukawa A, Suzuki Y, *et al.* Localization of propionibacterium acnes in granulomas supports a possible etiologic link between sarcoidosis and the bacterium. *Mod Pathol* 2012;25:1284-97.
10. Okamura M, Hamaguchi M, Suzuki K, Nakamura T, Fujita H, Hirata K. A patient with neurosarcoidosis presenting with easy falling and dysphagia. *Rinsho Shinkeigaku* 2020;60:346-50.
11. Pawate S, Moses H, Sriram S. Presentations and outcomes of neurosarcoidosis: A study of 54 cases. *QJM* 2009;102:449-60.
12. Uchino M, Nagao T, Harada N, Shibata I, Hamatani S, Mutou H. Neurosarcoidosis without systemic sarcoidosis-case report. *Neurol Med Chir (Tokyo)* 2001;41:48-51.
13. Vinas FC, Rengachary S. Diagnosis and management of neurosarcoidosis. *J Clin Neurosci* 2001;8:505-13.

How to cite this article: Murayama K, Inoue A, Nakamura Y, Ochi M, Shigekawa S, Watanabe H, *et al.* A rare case of neurosarcoidosis occurred only in the medulla oblongata mimicking malignant brain tumor. *Surg Neurol Int* 2021;12:243.