



Neuromelanin Magnetic Resonance Imaging Reveals Increased Dopaminergic Neuron Activity in the Substantia Nigra of Patients with Schizophrenia

Yoshiyuki Watanabe^{1*}, Hisashi Tanaka¹, Akio Tsukabe¹, Yuki Kunitomi¹, Mitsuo Nishizawa¹, Ryota Hashimoto^{2,4}, Hidenaga Yamamori⁴, Michiko Fujimoto⁴, Masaki Fukunaga³, Noriyuki Tomiyama¹

1 Diagnostic and Interventional Radiology, Osaka University Graduate School of Medicine, Suita, Japan, **2** Research Center for Children's Mental Development, United Graduate School of Child Development, Osaka University, Suita, Japan, **3** Departments of Biofunctional Imaging and Immunology, Frontier Research Center, Osaka University, Suita, Japan, **4** Department of Psychiatry, Osaka University Graduate School of Medicine, Suita, Japan

Abstract

Purpose: The dopamine hypothesis suggests that excessive dopamine release results in the symptoms of schizophrenia. The purpose of this study was to elucidate the dopaminergic and noradrenergic neurons using 3-T neuromelanin magnetic resonance imaging (MRI) in patients with schizophrenia and healthy control subjects.

Methods: We prospectively examined 52 patients with schizophrenia (M: F = 27:25, mean age, 35 years) and age- and sex-matched healthy controls. Using a 3T MRI unit, we obtained oblique T1-weighted axial images perpendicular to the brainstem. We measured the signal intensity and area for the substantia nigra (SNc), midbrain tegmentum, locus ceruleus (LC), and pons. We then calculated the contrast ratios (CR) for the SNc (CR_{SN}) and LC (CR_{LC}), which were compared between patients and healthy controls using unpaired *t*-tests.

Results: The SNc and LC were readily identified in both patients and healthy controls as areas with high signal intensities in the posterior part of the cerebral peduncle and in the upper pontine tegmentum. The CR_{SN} values in patients were significantly higher than those in healthy controls (10.89 ± 2.37 vs. 9.6 ± 2.36, *p* < 0.01). We observed no difference in the CR_{LC} values between the patients and healthy controls (14.21 ± 3.5 vs. 13.44 ± 3.37, *p* = 0.25). Furthermore, there was no difference in area of the SNc and LC between schizophrenia patients and controls.

Conclusions: Neuromelanin MRI might reveal increased signal intensity in the SNc of patients with schizophrenia. Our results indicate the presence of excessive dopamine products in the SNc of these patients.

Citation: Watanabe Y, Tanaka H, Tsukabe A, Kunitomi Y, Nishizawa M, et al. (2014) Neuromelanin Magnetic Resonance Imaging Reveals Increased Dopaminergic Neuron Activity in the Substantia Nigra of Patients with Schizophrenia. PLoS ONE 9(8): e104619. doi:10.1371/journal.pone.0104619

Editor: Juan Zhou, Duke-NUS Graduate Medical School, Singapore

Received: February 14, 2014; **Accepted:** July 15, 2014; **Published:** August 11, 2014

Copyright: © 2014 Watanabe et al. This is an open-access article distributed under the terms of the Creative Commons Attribution License, which permits unrestricted use, distribution, and reproduction in any medium, provided the original author and source are credited.

Funding: This work was supported by research grants from KAKENHI, 22390225-Grant-in-Aid for Scientific Research (B), 23659565-Grant-in-Aid for Challenging Exploratory Research and Grant-in-Aid for Scientific Research on Innovative Areas (Comprehensive Brain Science Network) from the Japanese Ministry of Education, Culture, Sports, Science and Technology (MEXT), and the Japan Foundation for Neuroscience and Mental Health. The funders had no role in study design, data collection and analysis, decision to publish, or preparation of the manuscript.

Competing Interests: One of the co-authors, Ryota Hashimoto, United Graduate School of Child Development, Osaka University, is an editor of PLOS ONE. This does not alter the authors' adherence to PLOS ONE policies on sharing data and materials.

* Email: watanabe@radiol.med.osaka-u.ac.jp

Introduction

Dopamine dysfunction plays an important role in the pathogenesis of schizophrenia [1]. The dopamine hypothesis suggests that excessive dopamine release results in symptoms of schizophrenia. *In vivo* positron emission tomography (PET) studies in patients with schizophrenia have indicated an increased baseline occupancy of D2 receptors by dopamine [2] and an increased capacity for striatal dopamine synthesis [3]. However, PET is not widely available, and its use in research is limited because of its high production costs. Further, the short half-life of ¹¹C radiopharmaceuticals restricts their use to only institutions having a cyclotron on-site.

Neuromelanin is a byproduct of the synthesis of monoamine neurotransmitters, such as noradrenalin and dopamine, and is

mainly distributed within neurons of the substantia nigra (SNc) or locus ceruleus (LC) [4]. Neuromelanin has a T1-shortening effect, which was a similar characteristic of the cutaneous melanin. High-field magnetic resonance imaging (MRI), such as 3 T, is very sensitive to tissue T1 relaxation and are able to depict tissue containing neuromelanin in (SNc) or (LC) [5]. There are many previous reports which showed the signal decrease in Parkinson's disease using neuromelanin MRI [4,6–10], but there are only two reports using this technique for schizophrenia [11,12].

The purpose of this study was to use 3T neuromelanin MRI for examining dopaminergic and noradrenergic nuclei in patients with schizophrenia and healthy controls.

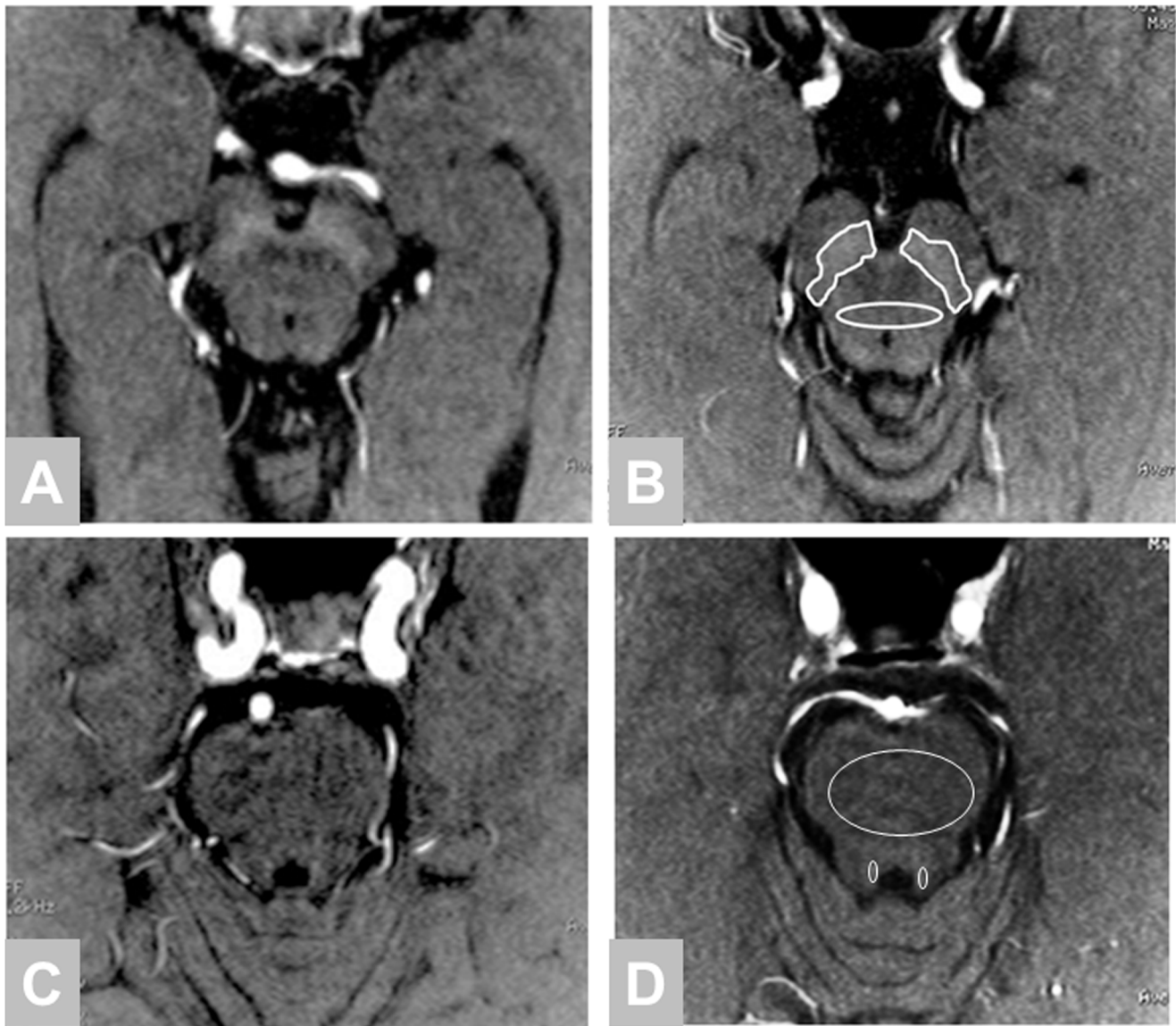

Figure 1. Neuromelanin imaging in the midbrain. A, C: 30-year-old male with schizophrenia, $CR_{SN} = 12.9$, $CR_{LC} = 10.7$; B, D: 26-year-old female healthy control, $CR_{SN} = 6.2$, $CR_{LC} = 7.6$ Demonstrating a region of interest drawn around the substantia nigra and midbrain tegmentum side on Figure 1B and locus ceruleus on Figure 1D. doi:10.1371/journal.pone.0104619.g001

Materials and Methods

Subjects

From April to November 2012, we prospectively examined 63 consecutive patients with schizophrenia who met the *Diagnostic and Statistical Manual of Mental Disorders, 4th Edition*, (DSM-IV) diagnostic criteria using 3T-MRI. Eleven patients were excluded because of motion artifacts (6 patients) and equipment failure (5 patients). Therefore, 52 patients (M: F = 27:25; mean age = 35 years; range = 17–69 years) were included in the analysis. In addition, we obtained MRI data from age- and sex-matched healthy controls. Controls were recruited from the community through local advertisements at Osaka University. An institutional review board approved this study, and written informed consent was obtained from all subjects before their participation. We used the Japanese version of the Positive and Negative Symptom Scale (PANSS) [13] to assess patient symptoms and their severity scores.

We administered the Japanese version of Wechsler Adult Intelligence Scale III [14] to determine the full scale intelligence quotient (IQ). Premorbid IQ was estimated using the Japanese Adult Reading Test [15,16].

This study was performed in accordance with the World Medical Association's Declaration of Helsinki and approved by the local institutional review board (2013-423, Osaka University Ethics Committee). Written informed consent was obtained by all subjects. If the subjects were under 20 years old, written informed consent was obtained from both minors and guardians. If the patients with schizophrenia were difficult condition to accept consent by themselves, these patients were not included in this study.

Imaging protocol

Using a 3T MRI unit (Signa Excite HDxt, GE healthcare, Milwaukee, Wisconsin), we obtained oblique T1-weighted oblique axial images perpendicular to the brainstem. The T1-weighted

Table 1. Clinical characteristics of patients with schizophrenia and healthy controls.

	Schizophrenia	Control		Schizophrenia	Control	
	all n = 52	all n = 52	p value	<30 year n = 24	<30 year n = 29	p value
Age	35.1 (13.3)	34.6 (13.7)	0.89	23.8 (4.1)	23.0 (2.3)	0.34
Sex (male:female)	27:25	27:25		11:13	16:13	
Year of education	13.4 (2.5)	15.4 (2.1)	<.001	13.0 (2.7)	15.6 (1.6)	<.001
Smoking (%)	16 (31%)	4 (7.7%)	<.001	6 (25%)	1 (3.4%)	<.001
Estimated premorbid IQ	102.0 (10.9)	109.7 (7.3)	<.001	102.0 (11.2)	111.3 (5.0)	<.001
Full scale IQ	87.0 (20.9)	113.8 (14.1)	<.001	87.8 (20.4)	118.4 (11.4)	<.001
Age of onset	22.9 (10.1)			18.2 (3.3)		
Duration (years)	10.4 (10.9)			4.9 (4.6)		
CPZeq (mg/day)	596.2 (556.2)			495.8 (541.6)		
PANSS positive	21.0 (6.3)			18.3 (6.3)		
PANSS negative	23.1 (7.5)			20.1 (6.4)		
PANSS general	50.0 (13.9)			45.8 (13.6)		
PANSS total	94.1 (26.2)			84.1 (25.5)		

Data are shown mean (standard deviation). CPZeq: chlorpromazine equivalent of total antipsychotics. IQ: Intelligence Quotient, PANSS: Positive and Negative Symptom Scale. doi:10.1371/journal.pone.0104619.t001

sequence was acquired with a 3D-spoiled GRASS sequence with magnetization transfer contrast: TR/TE = 38.4/2.4 ms, FA = 20 degrees, matrix size 480x320 in axial plane, FOV = 220 mm, and acquisition time = 3 min 25 s. A 40-mm slab thickness was used and images were reconstructed 40 slices with a slice thickness of 2 mm with in-slice zero-fill interpolation (ZIP2). We also obtained axial T2-weighted images of the whole brain to exclude coexisting disorders and any abnormal findings that might influence the signals for the SNc or LC. The T2-weighted image parameters are as follows: TR/TE = 4500/88 ms, FOV = 220 mm, Matrix = 512x256, 24 slices with slice thickness 5 mm, and 6 mm slice interval.

Data analysis

We measured the signal intensity of the SNc, midbrain tegmentum, LC, and pons. The region of interest (ROI) for the SNc was traced manually around the high signal area on two consecutive axial slices and ellipse ROI was set at midbrain

tegmentum in the same slice (Figure 1B). An ellipse ROI for the LC and pons were indicated on three consecutive slices. The average and maximum signal intensities (MaxSR) and area were measured for each ROI. The measurements were performed by a blinded author. We calculated the contrast ratio (CR) of the SNc (CR_{SN}) and LC (CR_{LC}) using the following equations: CR_{SN} = (S_{SN} - S_{TM}) / S_{TM}, CR_{LC} = (S_{LC} - S_P) / S_P. In these equations, S_{SN} and S_{TM} are the signal intensities for the SNc and midbrain tegmentum, respectively, and S_{LC} and S_P are the signal intensities of the LC and pons, respectively.

To reduce the effects of age-related changes in the CR_{SN} and CR_{LC}, we selected a subset of subjects who were under 30 years of age (n = 24 for schizophrenia, n = 29 for healthy controls) and compared their ROI values.

Statistical analyses were performed using unpaired t-tests to determine the differences between patients with schizophrenia and healthy controls.

Table 2. Neuromelanin imaging characteristics of patients with schizophrenia and healthy controls.

	Schizophrenia	controls	Schizophrenia	controls	Schizophrenia	controls
	all age n = 52	all age n = 52	<30 years n = 24	<30 years n = 29	≥ 30 year n = 28	≥ 30 year n = 23
CR _{SN} (%)	10.89 ± 2.37*	9.60 ± 2.36	10.51 ± 2.11 [§]	8.85 ± 1.95	11.22 ± 2.80	10.55 ± 2.51
CR _{LC} (%)	14.21 ± 3.5	13.44 ± 3.37	13.73 ± 3.37	13.15 ± 3.88	14.63 ± 3.56	13.79 ± 2.69
Area-SNc (mm ²)	160.1 ± 24.1	162.2 ± 21.6	155.4 ± 16.9	164.8 ± 24.7	164.2 ± 28.1	158.9 ± 17.1
Area-LC (mm ²)	10.84 ± 2.46	11.42 ± 2.27	10.79 ± 1.93	11.67 ± 2.57	10.89 ± 2.82	11.09 ± 1.86
MaxSR SNc	1.32 ± 0.04*	1.30 ± 0.04	1.30 ± 0.03*	1.28 ± 0.03	1.33 ± 0.04	1.32 ± 0.04
MaxSR LC	1.28 ± 0.05	1.27 ± 0.05	1.27 ± 0.05	1.28 ± 0.06	1.29 ± 0.05	1.27 ± 0.04

SR, signal ratio; SNc, substantia nigra; LC, locus coeruleus; CR_{SN}, contrast ratio of SNc; CR_{LC}, contrast ratio of LC; MaxSR, maximum signal intensity. Data are presented as mean ± standard deviation. *p < 0.05 compared to controls, [§]p < 0.005 compared to controls. doi:10.1371/journal.pone.0104619.t002

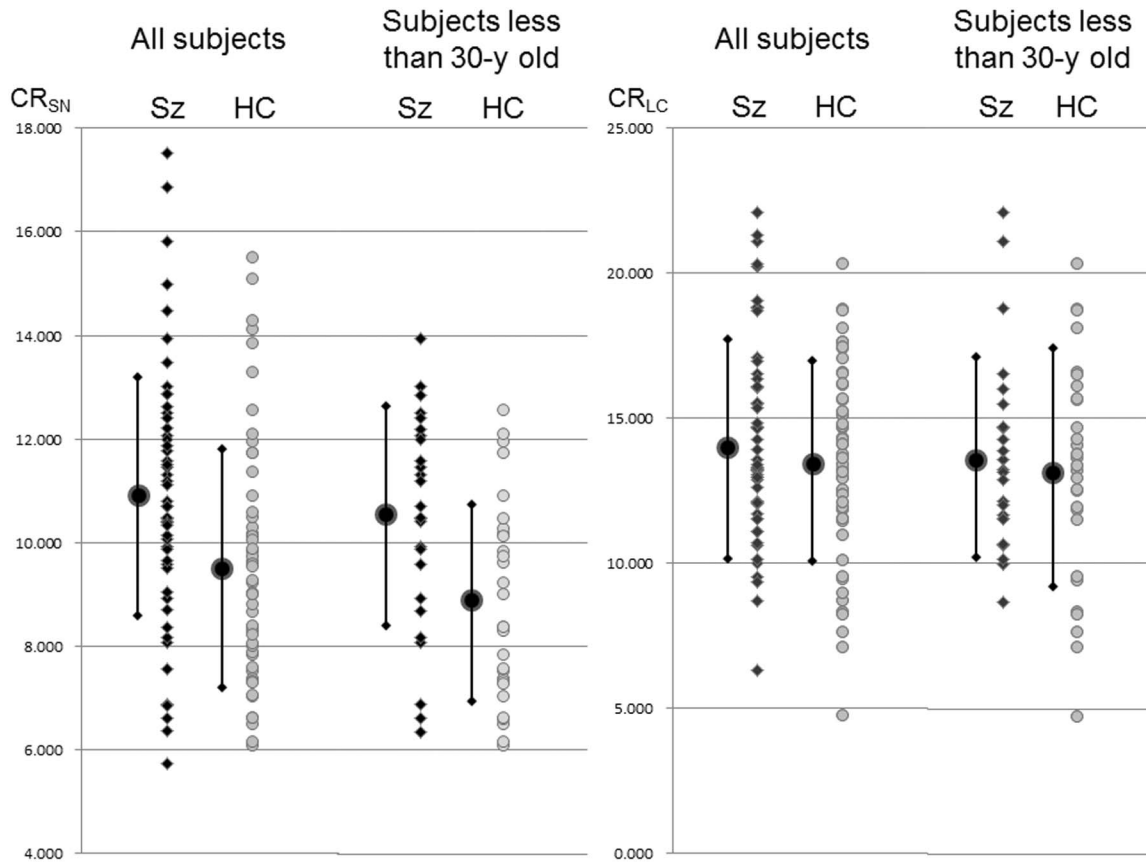


Figure 2. CR_{SN} and CR_{LC} for patients with schizophrenia and healthy controls. The left graph plots data for all subjects. The right graph plots data for selected patients under 30 years of age. The dots and bar show mean ± standard deviation. The patients showed a significantly higher CR_{SN}, but the variation in each group was large. The dispersion of data is small to select the young patients. There was no significant difference about CR_{LC} between the patients and healthy controls.
doi:10.1371/journal.pone.0104619.g002

We calculated the correlation between age and CR_{SN} or CR_{LC} for patients with schizophrenia and healthy controls. To elucidate the medication effects for the contrast ratio, the correlation between the chlorpromazine (CPZ) equivalents and CR_{SN} or CR_{LC} was analyzed.

Results

Table 1 presents the characteristics and clinical symptoms of patients and healthy controls. Compared to the patients, healthy controls had more years of education and higher IQs.

The SNc and LC were readily identified by high signal intensity areas in the posterior part of the cerebral peduncle and at the upper pontine tegmentum in both patients and healthy controls (Figure 1). Table 2 summarizes the mean signal intensities of each ROI. Our quantitative analysis showed that the CR_{SN} values and MaxSR SNc were significantly higher in patients with schizophrenia than in healthy controls (CR_{SN}: 10.89±2.37 vs. 9.6±2.36; p<0.01; Figure 2; MaxSR SNc: 1.32±0.04 vs. 1.30±0.04; p<0.05). No difference was observed in the CR_{LC} values between the patients and healthy controls (14.21±3.5 vs. 13.44±3.37; p=0.25; Figure 2). There was no difference the areas of the SNc and LC between schizophrenia and healthy controls.

In the subset of subjects that were under the age of 30, CR_{SN} values were significantly higher in patients with schizophrenia than in healthy controls (10.51±2.11 vs. 8.85±1.95; p<0.005;

Figure 2). There was no significant difference for the subset of subjects over 30 years old.

There is weak correlation between age and CR_{SN} (R=0.325, p=0.019) for healthy controls and (R=0.263, p=0.053) for schizophrenia. There is no correlation between age and CR_{LC} (R=-0.008, p=0.95) for healthy controls and (R=0.196, p=0.164) for schizophrenia. The CPZ equivalent and CR_{SN} showed weak correlation (R=0.353, p=0.010) and there is no correlation between CPZ equivalent and CR_{LC} (R=0.023, p=0.870) for patients with schizophrenia.

Discussion

Our results demonstrate the excessive levels of dopamine products in the SNc of living patients with schizophrenia and this supports the dopamine hypothesis for schizophrenia. Recently, Howers et al [17] reported the same results using a post-mortem study, which revealed that tyrosine hydroxylase staining scores were significantly greater in the schizophrenia group at substantia nigra compared to in healthy controls and in vivo imaging using PET which showed that elevated dopamine synthesis was seen in the nigral dopamine neurons in schizophrenia.

It has been suggested that dopamine dysfunction plays an important role in the pathogenesis of schizophrenia. This hypothesis is supported by evidence provided by numerous observations and studies. For example, the stimulants amphetamine and cocaine, which increase dopamine levels in the brain,

can cause symptoms resembling those for psychosis [18]. Patients with Parkinson's disease who have been treated with levodopa, a dopamine-enhancing compound, can experience psychotic adverse effects mimicking the symptoms of schizophrenia [19]. Antipsychotic drugs such as chlorpromazine, however, can antagonize dopamine D2 receptor binding and reduce the positive symptoms of psychosis [20]. Lots of in vivo studies have used PET techniques that examine receptor imaging or dopamine synthesis in order to evaluate the dopamine system in patients with schizophrenia. Dopamine D2 receptors were upregulated in patients with schizophrenia [21] and increased striatal dopamine synthesis occurs in schizophrenia [3]. However, because of low-resolution of PET, many studies evaluated at striatum and cerebral cortex.

It has been reported that T1-weighted MRI with 3T can indicate T1-shortening tissues containing neuromelanin at SNc and LC [4,5]. This technique is widely used to investigate neuromelanin signal and volume loss in the SNc of patients with Parkinson's disease [6–9,22]. We are aware of only two previous reports on neuromelanin imaging in patients with schizophrenia. Shibata et al [11] described signal changes in the SNc and LC among patients with schizophrenia, depression and controls. However, the CR_{SN} values were higher in patients with schizophrenia ($n = 20$; 22.6 ± 5.6 : mean \pm standard deviation (SD)) than in those with depression ($n = 18$; 19.2 ± 4.7), as well as controls ($n = 34$; 19.6 ± 3.8 ; one-way ANOVA, $p = 0.037$). However, a post hoc Tukey's test indicated no significant difference among schizophrenia and controls.

Sasaki et al [12] reported the CR_{SN} values were higher in patients with schizophrenia ($n = 23$; 22.6 ± 5.1) than those with depression ($n = 23$; 19.0 ± 4.3) and controls ($n = 23$; 20.5 ± 3.4). A post hoc test confirmed a significant difference between patients with schizophrenia and those with depression, but not between patients with schizophrenia and controls.

These two previous reports indicate the CR_{SN} in patients with schizophrenia is higher than that in controls, but this was not statistically significant due to a small sample size and large variations. We performed a similar comparison in our study using a larger patient group (52 patients) and observed a significant difference. The mean CR_{SN} was significantly higher in patients with schizophrenia than in healthy controls, but the CR_{SN} values showed large variations with overlap between patients and healthy controls (Figure 2). It is reported that neuromelanin levels in the SNc can increase with age using post-mortem histological examination [23,24] and also neuro-melanin MRI [23,25]. The age range in our study was very broad, ranging from 17 to 69 years. To reduce age-related changes, we selected subjects younger than 30 years. Between these groups, the CR_{SN} value showed small variations, and the difference between patients and healthy controls was more prominent (Figure 2).

References

- Heinz A, Schlagenhauf F (2010) Dopaminergic dysfunction in schizophrenia: salience attribution revisited. *Schizophr Bull* 36: 472–485.
- Abi-Dargham A, Rodenhiser J, Printz D, Zea-Ponce Y, Gil R, et al. (2000) Increased baseline occupancy of D2 receptors by dopamine in schizophrenia. *Proc Natl Acad Sci U S A* 97: 8104–8109.
- Hietala J, Syvalahti E, Vuorio K, Rakkolainen V, Bergman J, et al. (1995) Presynaptic dopamine function in striatum of neuroleptic-naive schizophrenic patients. *Lancet* 346: 1130–1131.
- Sasaki M, Shibata E, Tohyama K, Takahashi J, Otsuka K, et al. (2006) Neuromelanin magnetic resonance imaging of locus ceruleus and substantia nigra in Parkinson's disease. *Neuroreport* 17: 1215–1218.
- Sasaki M, Shibata E, Tohyama K, Kudo K, Endoh J, et al. (2008) Monoamine neurons in the human brain stem: anatomy, magnetic resonance imaging findings, and clinical implications. *Neuroreport* 19: 1649–1654.
- Kashihara K, Shinya T, Higaki F (2011) Neuromelanin magnetic resonance imaging of nigral volume loss in patients with Parkinson's disease. *J Clin Neurosci* 18: 1093–1096.
- Schwarz ST, Rittman T, Gontu V, Morgan PS, Bajaj N, et al. (2011) T1-weighted MRI shows stage-dependent substantia nigra signal loss in Parkinson's disease. *Mov Disord* 26: 1633–1638.
- Lehericy S, Sharman MA, Dos Santos CL, Paquin R, Gallea C (2012) Magnetic resonance imaging of the substantia nigra in Parkinson's disease. *Mov Disord* 27: 822–830.
- Matsuura K, Maeda M, Yata K, Ichiba Y, Yamaguchi T, et al. (2013) Neuromelanin magnetic resonance imaging in Parkinson's disease and multiple system atrophy. *Eur Neurol* 70: 70–77.
- Ohtsuka C, Sasaki M, Konno K, Koide M, Kato K, et al. (2013) Changes in substantia nigra and locus coeruleus in patients with early-stage Parkinson's disease using neuromelanin-sensitive MR imaging. *Neurosci Lett* 541: 93–98.

The absolute value of CR_{SN} observed in our study differed from those in two previous reports, which likely resulted from differences of the reference ROIs and MR sequence. We used a reference ROI located in the midbrain tegmentum, whereas previous reports used the decussation of the superior cerebellar peduncle. We use 3D-SPGR sequence to obtain T1-weighted image and previous reports performed a 2D-fast spin echo sequence. 3D acquisition is superior to obtain high signal to noise ratio image in less time. We showed significant difference using short time neuromelanin imaging and this was of great advantage to exam the schizophrenic patients who were sometimes difficult to hold steady head position for long examination time in MR unit.

There are several limitations to our study. First, we included all patients examined with neuromelanin MRI from April to November 2012. Many of these patients were under treatment with antipsychotic drugs. Our results showed that there is a weak correlation between CPZ equivalent and CR_{SN} , therefore these drugs have the potential to influence neuromelanin levels. The number of participants in this study was not enough to perform subgroup analysis and further study is needed to select first episode medication-naive patients to exclude the drug effect. Second, we could not evaluate the ventral tegmental area (VTA), which is the origin of the dopaminergic cell bodies of the mesolimbic-cortical dopaminergic system, because of the difficulty in detection the border of the VTA by neuromelanin-MRI. Third, the years of education and IQ were significantly higher in healthy controls than in patients with schizophrenia. Schizophrenia is characterized by general intellectual deficits [26,27]. The estimated premorbid IQ difference between schizophrenia and normal controls is smaller compared to that of full scale IQ, but the difference is statistically significant [28,29]. Fourth, we used 3D-SPGR imaging for neuromelanin MRI and the acquisition time was 3 min 25 s. Our acquisition time is shorter than that used for 2D-fast spin echo sequences in previous studies [4,5,11,12,30] and this short acquisition might make lower signal to noise ratio and large signal variability.

In conclusion, neuromelanin MRI revealed increased signal intensity in the SNc of patients with schizophrenia. This finding indicates the presence of an excessive level of dopamine products in the SNc of these patients. Therefore, neuromelanin imaging has the potential to be useful for accurate diagnosis of schizophrenia and to serve as a surrogate marker for medication.

Author Contributions

Conceived and designed the experiments: YW NT. Performed the experiments: YW HT AT YK MN RH HY M. Fujimoto. Analyzed the data: YW M. Fukunaga. Contributed reagents/materials/analysis tools: YW M. Fukunaga. Wrote the paper: YW.

11. Shibata E, Sasaki M, Tohyama K, Otsuka K, Endoh J, et al. (2008) Use of neuromelanin-sensitive MRI to distinguish schizophrenic and depressive patients and healthy individuals based on signal alterations in the substantia nigra and locus ceruleus. *Biol Psychiatry* 64: 401–406.
12. Sasaki M, Shibata E, Ohtsuka K, Endoh J, Kudo K, et al. (2010) Visual discrimination among patients with depression and schizophrenia and healthy individuals using semiquantitative color-coded fast spin-echo T1-weighted magnetic resonance imaging. *Neuroradiology* 52: 83–89.
13. Kay SR, Fiszbein A, Opler LA (1987) The positive and negative syndrome scale (PANSS) for schizophrenia. *Schizophr Bull* 13: 261–276.
14. Committee JW-IP (2006) Japanese Wechsler Adult Intelligence Scale Third Edition. Tokyo: Nihon Bunka Kagakusha.
15. Ota T, Iida J, Sawada M, Suehiro Y, Kishimoto N, et al. (2013) Comparison of pervasive developmental disorder and schizophrenia by the Japanese version of the National Adult Reading Test. *Int J Psychiatry Clin Pract* 17: 10–15.
16. Matsuoka K, Uno M, Kasai K, Koyama K, Kim Y (2006) Estimation of premorbid IQ in individuals with Alzheimer's disease using Japanese ideographic script (Kanji) compound words: Japanese version of National Adult Reading Test. *Psychiatry Clin Neurosci* 60: 332–339.
17. Howes OD, Williams M, Ibrahim K, Leung G, Egerton A, et al. (2013) Midbrain dopamine function in schizophrenia and depression: a post-mortem and positron emission tomographic imaging study. *Brain* 136: 3242–3251.
18. Gururajan A, Manning EE, Klug M, van den Buuse M (2012) Drugs of abuse and increased risk of psychosis development. *Aust N Z J Psychiatry* 46: 1120–1135.
19. Zahodne LB, Fernandez HH (2008) Pathophysiology and treatment of psychosis in Parkinson's disease: a review. *Drugs Aging* 25: 665–682.
20. Seeman P (2010) Dopamine D2 receptors as treatment targets in schizophrenia. *Clin Schizophr Relat Psychoses* 4: 56–73.
21. Wong DF, Wagner HN Jr, Tune LE, Dannals RF, Pearlson GD, et al. (1986) Positron emission tomography reveals elevated D2 dopamine receptors in drug-naive schizophrenics. *Science* 234: 1558–1563.
22. Ogisu K, Kudo K, Sasaki M, Sakushima K, Yabe I, et al. (2013) 3D neuromelanin-sensitive magnetic resonance imaging with semi-automated volume measurement of the substantia nigra pars compacta for diagnosis of Parkinson's disease. *Neuroradiology* 55: 719–724.
23. Zucca FA, Bellei C, Giannelli S, Terreni MR, Gallorini M, et al. (2006) Neuromelanin and iron in human locus coeruleus and substantia nigra during aging: consequences for neuronal vulnerability. *J Neural Transm* 113: 757–767.
24. Mann DM, Yates PO (1974) Lipoprotein pigments—their relationship to ageing in the human nervous system. II. The melanin content of pigmented nerve cells. *Brain* 97: 489–498.
25. Tanaka M, Aihara Y, Ikeda S, Aihara Y (2011) [Neuromelanin-related contrast in the substantia nigra semiquantitatively evaluated by magnetic resonance imaging at 3T: comparison between normal aging and Parkinson disease]. *Rinsho Shinkeigaku* 51: 14–20.
26. Bilder RM, Reiter G, Bates J, Lencz T, Szeszko P, et al. (2006) Cognitive development in schizophrenia: follow-back from the first episode. *J Clin Exp Neuropsychol* 28: 270–282.
27. Keefe RS, Easley CE, Poe MP (2005) Defining a cognitive function decrement in schizophrenia. *Biol Psychiatry* 57: 688–691.
28. Fujino H, Sumiyoshi C, Sumiyoshi T, Yasuda Y, Yamamori H, et al. (2014) Performance on the Wechsler Adult Intelligence Scale-III in Japanese patients with schizophrenia. *Psychiatry Clin Neurosci*.
29. Woodberry KA, Giuliano AJ, Seidman LJ (2008) Premorbid IQ in schizophrenia: a meta-analytic review. *Am J Psychiatry* 165: 579–587.
30. Shibata E, Sasaki M, Tohyama K, Kanbara Y, Otsuka K, et al. (2006) Age-related changes in locus ceruleus on neuromelanin magnetic resonance imaging at 3 Tesla. *Magn Reson Med* 5: 197–200.