

Available online at www.sciencedirect.com

ScienceDirect

journal homepage: www.elsevier.com/locate/ihj

Case Report

Paravalvular leak closure with two large size devices

V.K. Trehan^a, M.S.K. Subhendu^{b,*}, V. Chaturvedi^b, B.N. Pandit^c,
M. Goyal^c

^a Professor of Cardiology, Department of Cardiology, Gobind Ballabh Pant Hospital, New Delhi 110002, India

^b Assistant Professor of Cardiology, Department of Cardiology, Gobind Ballabh Pant Hospital, New Delhi 110002, India

^c Department of Cardiology, Gobind Ballabh Pant Hospital, New Delhi 110002, India

ARTICLE INFO

Article history:

Received 12 January 2013

Accepted 5 December 2013

Available online 26 December 2013

Keywords:

Paravalvular leak

Mitral regurgitation

Percutaneous closure

ABSTRACT

Paravalvular leaks (PVL) after valve replacement surgeries are not uncommon. A significant number of these patients need some form of intervention as they commonly present with heart failure or severe hemolysis. Surgical correction is associated with high mortality and morbidity. Device closure of PVLs has been found to have good results. Since there are no devices designed specifically for PVL closure, large PVL closure is difficult. Occasional larger PVLs have been closed with a combination of a device and smaller coils. We present here a case of very large sized mitral PVL, in a patient with high risk for surgery, which was closed with two large size devices.

Copyright © 2014, Cardiological Society of India. All rights reserved.

1. Introduction

Mitral paravalvular leak (PVL) subsequent to valve replacement surgery is not an uncommon occurrence having been reported in upto 4.5% of cases.^{1,2} Most of these cases are asymptomatic but a significant number need some form of intervention. Surgery is the standard treatment for such cases but is associated with high morbidity and mortality. Mortality rates are as high as 13, 15, and 37% after the first, second, and third procedures, respectively.³ Percutaneous device closure of PVLs is an acceptable mode of intervention for such patients and has shown good survival benefit.⁴ The long-term result correlates with the degree of residual mitral regurgitation (MR). We report a case which presented with severe MR,

causing symptoms of heart failure, due to a large mitral valve PVL and needed two large devices for percutaneous device closure of the PVL.

2. Case history

A 25-year-old male patient presented to us with NYHA class III dyspnea with history of having needed 2–3 hospital admissions for acute pulmonary edema in the last 6 months. He has had mitral valve replacement done 8 years back with a Starr Edward valve and had chronic persistent atrial fibrillation.

Echocardiography done showed a very large PVL at the 9 O'clock position in the parasternal short axis view measuring

* Corresponding author. Tel.: +91 9718599135.

E-mail address: drsubhendu@gmail.com (M.S.K. Subhendu).

0019-4832/\$ – see front matter Copyright © 2014, Cardiological Society of India. All rights reserved.

<http://dx.doi.org/10.1016/j.ihj.2013.12.033>

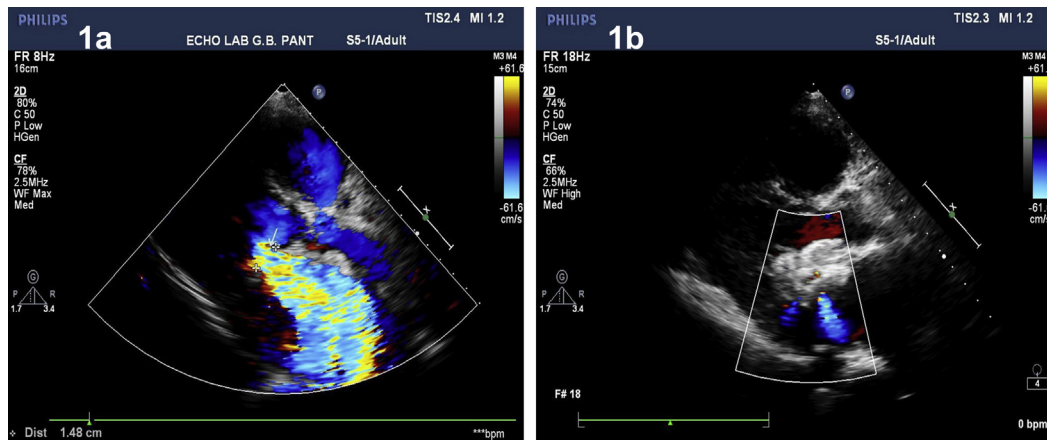


Fig. 1 – a – Shows preprocedure severe mitral regurgitation through a large PVL, b – Shows post procedure mild residual mitral regurgitation.

15–17 mm. The associated mitral regurgitation was severe (Fig. 1a) with dilated left atria (measuring 68 mm in parasternal long axis view) and left ventricle with mild left ventricular (LV) systolic dysfunction (LV ejection fraction of 45%). The patient, after being explained different management options, refused surgery and was hence taken up for a device closure after obtaining an informed written consent.

The procedure was carried out under local anesthesia with transthoracic echocardiography guidance. While a transesophageal approach may give better guidance and visibility, we opted for transthoracic guidance to avoid a prolonged general anesthesia and also for the fact that the patient had a Starr Edward valve which has a good profile under fluoroscopy. An antegrade approach for device closure was planned. A routine transeptal puncture was done and a 14F Mullins sheath (Cook Inc, Bloomington, IN) was lodged in the left atrium (LA). Since the left atrium was significantly dilated and the PVL was located relatively medially, we made a conscious decision not to make a high septal puncture which is advisable for laterally located PVLs. The PVL was crossed with a 180 cm, 0.035 inch, curve tipped Glide wire (Terumo Medical Corp., Somerset, New Jersey) taken with a 5F Judkins Right (JR) catheter through this sheath. The JR catheter was taken across the PVL after confirming that the wire was not across the valve in orthogonal fluoroscopic views. Once inside the LV, the wire was exchanged for a 300 cm, 0.032 inch Amplatz ExtraStiff wire (Cook Medical, Bloomington, Indiana). This wire was taken across the aortic valve and positioned in the right subclavian artery. Another 0.032 Amplatz ExtraStiff wire was similarly taken across the PVL and positioned alongside the first wire. The 14F sheath could now be taken across the PVL, over these two wires, without any resistance (Fig. 2). Once in the LV, one of the wires was removed and a 16/18 mm Amplatzer duct occluder like device (Cardio-O-Fix PDA occluder, Starway Medical Technology Inc., Beijing, China) was deployed across the PVL. Echocardiography done showed a significant persistent regurgitation. It was hence decided to deploy another device across the PVL. To ensure more stability, an Amplatzer muscular VSD closure device (AGA Medical Corp., Plymouth, Minnesota) was selected as the second

device. A 12 mm device easily fell across the PVL with the first device in place. It was hence decided to use an 18 mm device. The first device was resheathed and the 14F sheath was lodged across the PVL in the LV with both the devices (Fig. 3). The distal one third of both the devices were exteriorized out of the sheath on the LV side and the whole assembly was pulled back to the level of the valve ensuring that the two distal rims were aligned side by side and not affecting the movement of the ball within the valve. The sheath was now gradually pulled back exteriorizing the proximal ends of the two devices. Echocardiogram showed minimal residual MR. Both the devices were released. A stable position was confirmed by both echocardiogram and fluoroscopy.

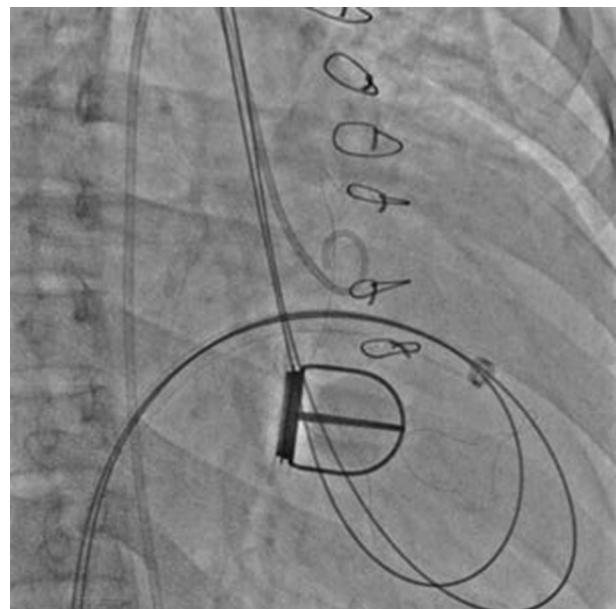


Fig. 2 – Two 0.032 wires have been taken through the PVL and then across the aortic valve and parked in the subclavian artery (not seen in figure). The sheath can be seen having been tracked over the wires through the PVL into the LV.

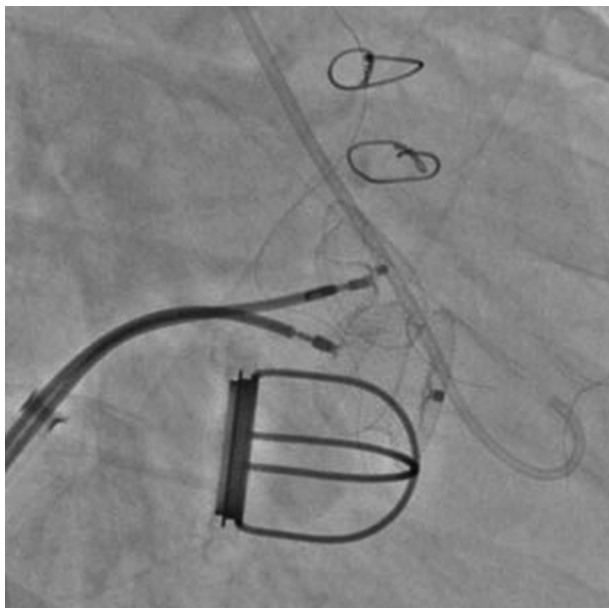


Fig. 3 – Distal rims of both devices have been opened in the LV simultaneously to prevent the devices from slipping back into the LA.

The patient has been on oral anticoagulation and 150 mg of aspirin along with other heart failure drugs since then. He was fine at 1-year follow up with significant improvement in his symptoms to NYHA functional class II and minimal residual MR (Fig. 1b).

3. Discussion

Most PVLs are asymptomatic and need no intervention. However, a small minority of cases become symptomatic and need some form of intervention. The most common reasons for presentation in patients with PVL include congestive heart failure (CHF) and hemolytic anemia with a significant number of patients having both.^{4,5} Surgical repair is probably the gold standard for treatment of a PVL. However, the morbidity and mortality with a repeat procedure is significantly high and many of the patients are hesitant to undergo another surgery with a higher risk. This has evinced a keen interest in finding alternative minimally invasive methods for their management. Device closure of PVLs has been reported in a large number of patients and has shown increasingly good results, especially after the improvement in the available hardware for intervention. Short-term follow up results have been very good with 3-year survival rates of almost 70%.⁴ Considering that most such closures are done in patients with high surgical risk, it is now an acceptable mode of treatment for PVLs.

Our patient with severe MR, associated early LV dysfunction and NYHA class III symptoms was a high-risk surgical candidate and the patient opted for a device closure. Echocardiography done showed that the PVL was at 9 O'clock position and measured 15–17 mm by echo. While there have been earlier case reports of PVLs needing more than one devices, none has been reported to have needed two such large

devices. The resulting MR almost filled the whole LA. The long term results of PVL closure depends on the residual MR and since this patient had presented with heart failure symptoms, it was important to ensure minimal residual MR post procedure. For mitral PVLs, the antegrade approach is the preferred route for device closure.^{6,7} It is important to cross the PVL carefully without affecting the valve function. We confirmed the wire route by multiple orthogonal fluoroscopic and echocardiographic views before taking the catheter across.

Amplatzer duct occluder is the most common device used to close the PVLs.⁵ We too used an Amplatzer duct occluder like device based on the echocardiographic estimation of the size. However, we had thought that this alone may not be sufficient to close the PVL. This is because of the fact that the PVLs are semilunar shaped defects and none of the devices currently in use confirm to this shape. With a large device in a large defect, significant residual leak was expected around this device. This was seen in our patient also where though there was a marked decrease in MR with the first device, significant MR persisted. For more stability with a second device, we chose a muscular VSD closure device. There have been earlier case reports where more than one device have been used for PVL.⁵ Most of these cases used additional coils or smaller devices, however our patient had a very large PVL and hence needed a large second device. To the best of our knowledge these are the largest two devices for a single PVL. Smaller sizes of this device easily slipped out across the first device and a stable position was achieved only with an 18 mm device. Since the device sizes were large, they probably were limited by the cage of the valve from interfering in the movement of the ball. Very minimal MR remained post procedure.

4. Conclusion

This case demonstrates successful closure of a very large PVL in a high-risk case. Very large PVL in itself need not be considered an indication for surgery or be confined to medical therapy but it is important to ensure minimal residual MR post procedure for the patient to have long-term benefit. Device closure of PVLs should be considered in all patients with a symptomatic PVL and is technically feasible even in large leaks.

Conflicts of interest

All authors have none to declare.

REFERENCES

1. Jindani A, Neville EM, Venn G, Williams BT. Paraprothetic leak: a complication of cardiac valve replacement. *J Cardiovasc Surg (Torino)*. 1991;32:503–508.
2. Genoni M, Franzen D, Vogt P, et al. Paravalvular leakage after mitral valve replacement: improved long-term survival with aggressive surgery? *Eur J Cardiothorac Surg*. 2000;17:14–19.

3. Echevarria JR, Bernal JM, Rabasa JM, Morales D, Revilla Y, Revuelta JM. Reoperation for bioprosthetic valve dysfunction. A decade of clinical experience. *Eur J Cardiothorac Surg*. 1991;5:523–526 [Discussion 527].
4. Sorajja P, Cabalka AK, Hagler DJ, Rihal CS. Long-term follow-up of percutaneous repair of paravalvular prosthetic regurgitation. *J Am Coll Cardiol*. 2011 Nov 15;58:2218–2224.
5. Ruiz CE, Jelnin V, Kronzon I, et al. Clinical outcomes in patients undergoing percutaneous closure of periprosthetic paravalvular leaks. *J Am Coll Cardiol*. 2011 Nov 15;58:2210–2217.
6. Rihal CS, Sorajja P, Booker JD, Hagler DJ, Cabalka AK. Principles of percutaneous paravalvular leak closure. *JACC Cardiovasc Interv*. 2012 Feb;5:121–130.
7. Pate GE, Thompson CR, Munt BI, Webb JG. Techniques for percutaneous closure of prosthetic paravalvular leaks. *Catheter Cardiovasc Interv*. 2006;67:158–166.