

Five-year Experience with Perma Facial Implant

Peter Raphael, MD*

Ryan Harris, BA†

Scott W. Harris, MD, FACS*

Summary: Augmentation cheiloplasty is becoming an increasingly popular aesthetic procedure despite current methodologies having met with disappointment among surgeons and patients. The goal of this study was to examine the benefits and drawbacks of 1 device in particular—Perma Facial Implant (PFI). The senior authors (P.R. and S.W.H.) performed 832 consecutive PFI lip augmentations with excellent results based on photographic documentation, patient satisfaction surveys, unbiased surgeon ratings, and low complication rates. In addition to augmenting thin lips, PFIs hide excess dentition and improve vermilion rhytids and pout. Contrary to alternatives, they are both permanent and reversible. However, they do not level out asymmetries or benefit razor-thin lips without prior lifting or mucosal advancement. (*Plast Reconstr Surg Glob Open* 2014;2:e153; doi: 10.1097/GOX.0000000000000091; Published online 15 May 2014.)

With age, the lips acquire a “deflated” appearance due to inversion and soft-tissue atrophy.¹ Furthermore, as youthful pout gives way to a flattened contour, labial rhytids make their way across the vermilion border. Lip augmentation is a common means of reversing these by-products of involution.

Today’s plethora of lip augmentation approaches, however, implies the absence of a definitive solution. We agree with others²⁻⁸ that such a filler should be natural in appearance and feel and permanent, yet easily reversible, replaceable, and adjustable. It should preserve labial architecture and contours (eg, Cupid’s bow, white roll, philtral dimple, central

tubercle, and tapering of lip toward the commissures), thus avoiding “sausage” lips.⁹

From a functional standpoint, it should adapt to the shape of the lips such that they are not restricted or distorted during animation. Operative goals should consist of increasing vermilion height, adding volume uniformly, enhancing pout, masking excess visible dentition, and effacing lines and wrinkles without leaving visible scarring. Lastly, the prototypic technique must be facile, reproducible, brief, and well tolerated with rapid recovery.

Based on extensive experience with Perma Facial Implant (PFI) (SurgiSil LLC, Plano, Tex.), we conclude that it meets these criteria. In 2006, it secured CE marking for lip augmentation in Europe under the label PermaLip. As of 2007, it has been Food and Drug Administration cleared for facial soft-tissue enhancement in areas such as the cheeks, chin, and nose. Composed of soft, solid, pliable silicone, this biocompatible product is ideally suited to the lips as well. Herein, we elaborate our lip implantation technique, detail the results and complications of a patient series, and compare this method with others.

From the *American Institute for Plastic Surgery, Plano, Tex.; and †UT Southwestern, Dallas, Tex.

Received for publication December 26, 2013; accepted March 3, 2014.

Presented at American Academy of Facial Plastic & Reconstructive Surgery (AAFPRS) Fall Meeting 2010, Boston; Multi-Specialty Foundation 2010 Vegas Cosmetic Surgery Symposium; and State-of-the-Art in Facial Aesthetics 2013, Atlanta.

Copyright © 2014 The Authors. Published by Lippincott Williams & Wilkins on behalf of The American Society of Plastic Surgeons. PRS Global Open is a publication of the American Society of Plastic Surgeons. This is an open-access article distributed under the terms of the Creative Commons Attribution-NonCommercial-NoDerivatives 3.0 License, where it is permissible to download and share the work provided it is properly cited. The work cannot be changed in any way or used commercially.

DOI: 10.1097/GOX.0000000000000091

Disclosure: Drs. Raphael and Harris invented Perma Facial Implant and are shareholders in SurgiSil LLC, a medical device company based in Plano, TX, responsible for its marketing and distribution. The Article Processing Charge was paid for by the authors.

Supplemental digital content is available for this article. Clickable URL citations appear in the text.

PATIENT SELECTION

Hypoplastic lips are the primary indication for augmentation, irrespective of etiology (congenital vs acquired). When evaluating the upper lip, we utilize a new classification system¹⁰ (Table 1) that categorizes patients according to philtral and labial heights. Although many surgical candidates can be identified by observation alone, borderline cases often demand objective confirmation. To that end, each category is accompanied by value ranges for 2 measurements: (1) philtral-labial score (PLS), which is defined as philtral height divided by upper lip height at the midline; and (2) dental show.

Types 1 and 3 are ideal candidates for the procedure described in this article. Characterizing type 1 patients are PLSs between 3 and 5 and at least 1 mL of dental show in repose or surplus gingival display when smiling.¹¹ Type 3 patients lack dental show, but feature PLSs above 5. Although this classification system analyzes philtral:labial balance, one can also judge upper lip deficiency relative to the lower lip. According to cephalometric norms, the upper lip is two-thirds the height of the lower lip¹² and projects slightly more on profile view.¹³

Compared to its superior counterpart, the lower lip is less commonly thin in isolation, largely because it is less prone to shrinkage.¹⁴ Thus, lower lip enhancement is usually done in the setting of a bivertical lip augmentation¹⁰ (BLA)—either because both lips are small or to maintain proportion when an upper lip augmentation is planned. Besides the thin-lipped demographic, additional candidates include type 0 patients who desire larger lips despite normal aesthetics and those seeking increased pout or rhytid effacement.

One contraindication is “razor-thin” lips. Despite the greater need for enlargement, there may be insufficient tissue or vermilion show to fit even the smallest implant unless mucosal advancement or a lip lift is staged beforehand or concomitantly. Likewise, lip augmentations are counterproductive in type 2 patients. They do not address the primary defect and usually produce a “duckbill” appearance.^{15,16}

PREPARATION

Pre-op Instructions

For 2 weeks leading up to the procedure, patients are asked to abstain from smoking, aspirin, ibuprofen, and any other herbal supplements or medications known to promote bleeding. The day prior, they are begun on 10-day courses of antiviral medication to reduce the likelihood of a posttraumatic herpetic cold sore. Oral steroids for postprocedural edema are not necessary.

Implant Selection

PFIIs are currently manufactured in 3 lengths—55, 60, and 65 mm—and 3 diameters—3, 4, and 5 mm. Proper diameter selection depends on available tissue tempered with cosmetic goals. Conversely, optimal length is several millimeters shorter than the distance from commissure to commissure, as measured with a paper ruler along the wet-dry border of slightly parted lips (Fig. 1). Due to its curvature, the upper lip sometimes requires a slightly longer implant relative to the lower one.

In making the right selection, a key aesthetic consideration is fitting the implant not just to the lip, but to the overall face as well. In general, thinner implants are better suited to smaller lips and faces. Patients will often bring images of lips they deem attractive, which aids the surgeon in getting a sense of the results they seek. Yet, their expectations of movie star lips are not always realistic. Too large an implant, for example, may dominate the visage, and the lip may not be able to accommodate it, as previously discussed.

TECHNIQUE

Anesthesia

In the conscious patient, anesthesia takes place in 3 stages, commencing with intraoral placement of Q-tips coated with lidocaine gel. After waiting for 5 minutes, 9 mL of 1% lidocaine with epinephrine is drawn into a 12-mL syringe and buffered with

Table 1. Upper Lip Classification System, Diagnostic Tools, and Surgical Management*

Type	Philtral Height	Labial Height	PLS	Dental Show† (mm)	Treatment
0	Normal	Normal	<3	1–2	None
1	Normal	Short	3–5	≥1	Lip augmentation
2	Tall	Normal	3–5	0	Lip lift
3	Tall	Short	>5	0	Combination‡

*Presupposes no maxillary deformities.

†Age- and sex-dependent.

‡Lip augmentation and lip lift.

Reproduced with permission from Raphael P, Harris R, Harris SW. Analysis and classification of the upper lip aesthetic unit. *Plast Reconstr Surg.* 2013;132:543–551.

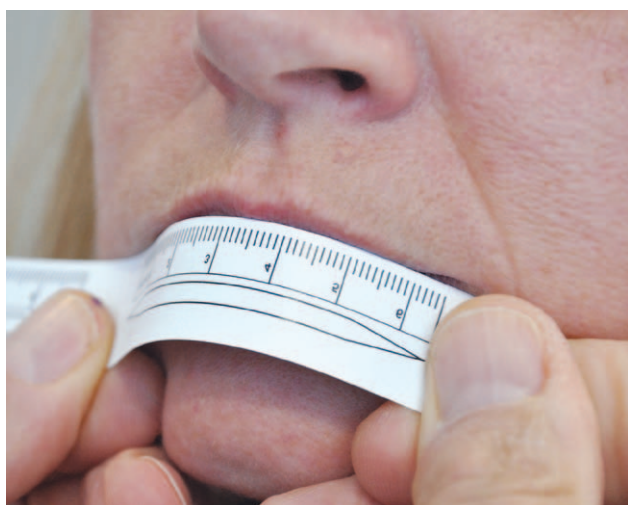

Fig. 1. Preoperative measurements. The paper ruler conveniently curves along the wet-dry border rather than traveling straight across.

3 mL of 8.4% sodium bicarbonate. This mixture is preferred for its vasoconstriction and postoperative analgesic properties and is used for regional and local blocks.

A regional block is then performed to lessen the pain associated with the local. It consists of a 5-point block targeting the infraorbital, mental, and anterior superior alveolar nerves. Specifically, four 1.5-mL aliquots are injected in the gingivolabial sulci anterior to the infraorbital and mental foramina, followed by a single 1-mL injection into the superior frenulum for the highly sensitive central third of the upper lip. Shaking the lip during injection minimizes patient discomfort.

Once this takes effect (5–10 minutes), 0.5 mL is locally infiltrated into each commissure. A conservative 1.5 mL is then injected evenly into the deep submucosa of the lip, during which care is taken to follow the wet-dry border (which the surgeon may wish to mark in advance) while staying just superficial to the orbicularis oris. Blanching appears in approximately 10 minutes. Besides serving a numbing purpose, this step is beneficial for hydrodissection. Furthermore, it is the only one required for the sedated patient. (See **Video 1, Supplemental Digital Content 1**, which guides readers through the authors' lip augmentation method using PFI. It begins with anesthetization, concludes with incision closure, and offers many clinical pearls along the way, including how to fashion the transcommissural tunnel and how to thread, seat, embed, and center the implant. This video is available in the "Related Videos" section of the full-text article at <http://www.PRSGO.com> or available at <http://links.lww.com/PRSGO/A30>.)



Video Graphic 1. Lip augmentation method. See video, Supplemental Digital Content 1, which guides readers through the authors' lip augmentation method using PFI. It begins with anesthetization, concludes with incision closure, and offers many clinical pearls along the way, including how to fashion the transcommissural tunnel and how to thread, seat, embed, and center the implant. This video is available in the "Related Videos" section of the full-text article at <http://www.PRSGO.com> or available at <http://links.lww.com/PRSGO/A30>.

Implantation

Similar to any implantation procedure, this one is performed sterilely and thus begins once peri- and intraoral Betadine prep is complete and drapes are applied. Curved Iris scissors (or a #15 blade) are used to make 4–5 mm transverse commissural incisions without crossing the vermilion border (see **Video 1, Supplemental Digital Content 1**). With the scissors closed, the commissural incisions are punctured 2–3 mm deep, allowing immediate access to the desired tunnel depth (Fig. 2). Otherwise, the implant will be too shallow peripherally.

When developing the tunnel, envisioning future implant placement (Fig. 3) is helpful. Dissection

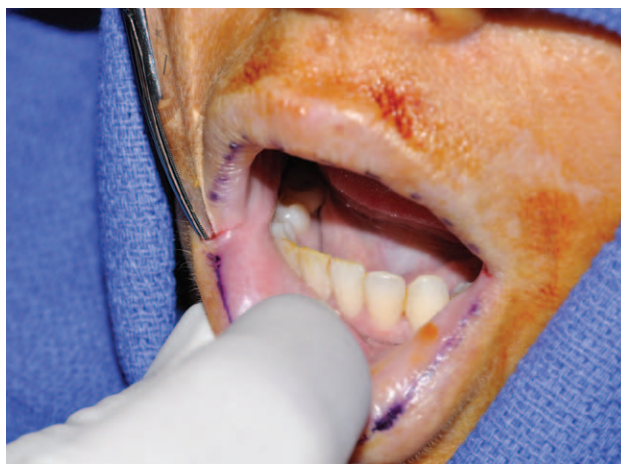

Fig. 2. Starting the tunnel. The closed scissors are gently advanced through the commissural incision at a steep angle to achieve the proper depth at the outset.

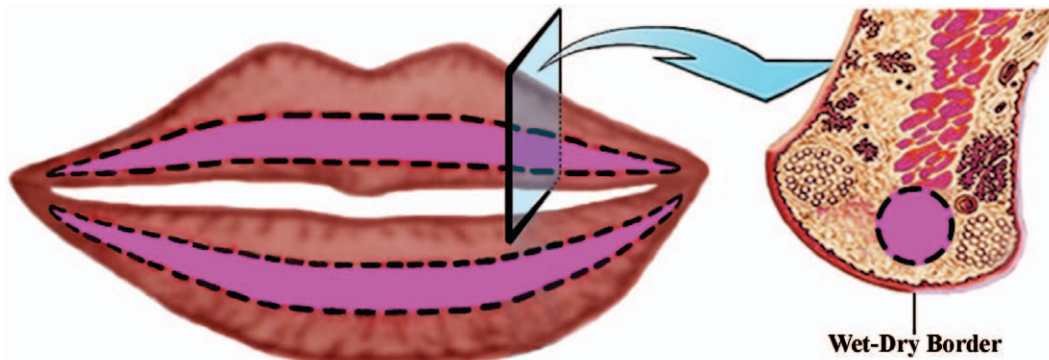


Fig. 3. Implants in situ. Note that in cross-section, half of the implant (pink) lies anterior to the wet-dry border and the other half posterior. Additionally, it is neither situated intramuscularly, where it might cause dynamic distortion, nor too superficially, where it may be noticeable or extrude. As a rule of thumb, the deeper within submucosa, the better. Original lip cross-section image (on right) was reproduced with permission from Lemperle G, Sadick NS, Knapp TR, et al. ArteFill® permanent injectable for soft tissue augmentation: II. Indications and applications. *Aesthetic Plast Surg.* 2010;34:273–286. Copyright 2010, Springer.

occurs along the same plane that was locally anesthetized, proceeding from commissure to midline with vertically oriented scissors in a “push-spread” pattern (Fig. 4) and receding in a horizontal “pull-spread” fashion. Performed bilaterally, this maneuver results in central convergence of 2 independent 3-dimensional pockets to become a single transcommissural tunnel.

While holding the lip between the thumb and index finger for stability, the Perma-Tunneler—a specialized tendon passer whose unique jaw design prevents trauma to the implant—is advanced through the tunnel (Fig. 5) until it emerges from the contralateral incision (see **Video 1, Supplemental Digital Content 1**). At this point, the lip tissue may be spread out across the body of the tunneler to assess

uniformity of depth. If there are any doubts regarding tunnel quality, retunneling is advised to optimize results and avoid revisions.

After the implant has been soaked in Betadine solution, one end is securely grasped within the tunneler jaws and threaded through the pocket, aided by Brown-Adson forceps gripping the opposite tip (Fig. 6). The implant is then “flossed” side-to-side until equal lengths extend beyond the commissural incisions. Once the surgeon is satisfied with seating, the implant is released and embedded entirely within the pocket by stretching the lips lengthwise (Fig. 7) (see **Video 1, Supplemental Digital Content 1**).

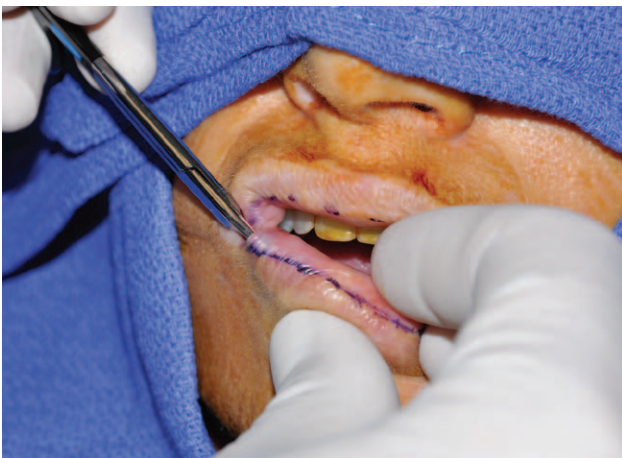

Fig. 4. Spreading dissection. The wet-dry border (dotted) serves as a guide. When angled vertically, the scissors may be within muscle if dissection is difficult and are too shallow if their tips are visible beneath the mucosa.

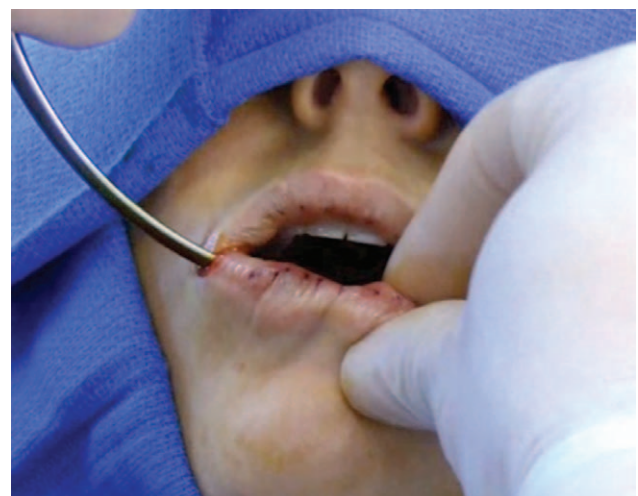


Fig. 5. First pass of tunneler. We recommend lubricating the tunneler with Betadine solution (as opposed to saline or chlorhexidine) and “accordioning” the lip during its passage. Additional spreading may be required if difficult areas (eg, fibrous tissue) are encountered, as it is imperative to remain within the pre-dissected channel.

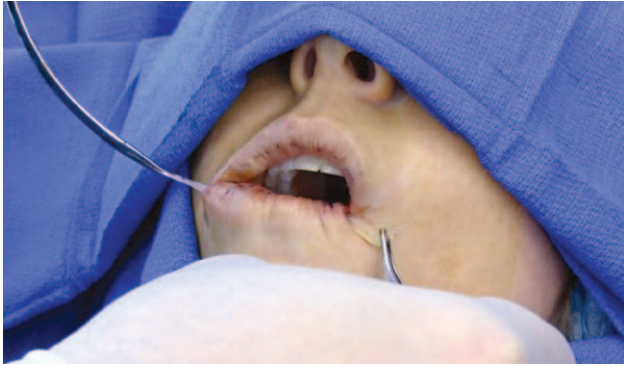

Fig. 6. Seating the implant. The tunneler securely grips the full tapering region of the implant (~1 cm worth) to avoid tearing it, while pickups control the trailing, free end before it is pulled all the way through.

In a BLA, the same process is repeated on the other lip via the same incisions. Closure is performed using 4-0 chromic catgut in a simple interrupted or figure-of-eight technique with 6–8 knots. The knots are situated buccally if a figure-of-eight technique is used. Regardless of suture technique, however, it is imperative to incorporate deep submucosa or even muscle with each stitch (Fig. 8) and to use as many stitches as necessary to obtain a secure closure.

At this point, another rationale for the judicious, even infiltration of local becomes evident; namely, it allows digital manipulation of the implant to ensure midline placement (Fig. 9) (see **Video 1, Supplemental Digital Content 1**). The procedure concludes with application of bacitracin ointment and a cold compress. Implantation may be performed in less than 30 minutes as a stand-alone procedure under local anesthesia or in conjunction with facial rejuvenation surgery.

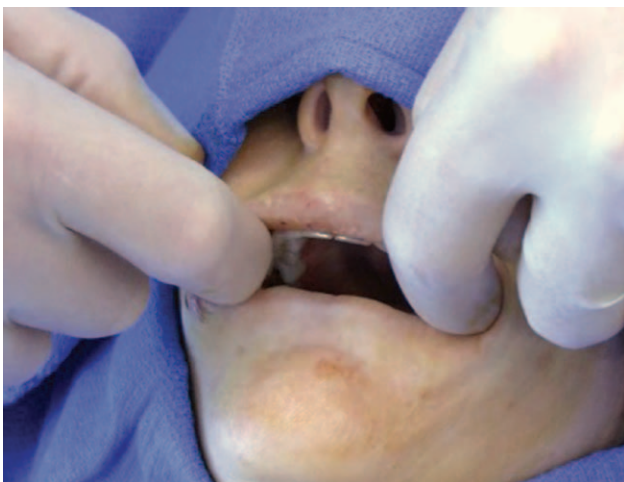

Fig. 7. Embedding the implant. The commissures are bimanually spread apart until the implant's tapered ends disappear.

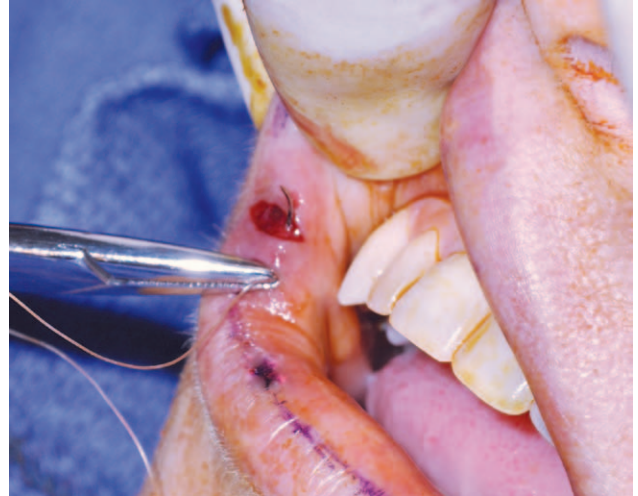

Fig. 8. Incision closure. Grasping deep tissue enables a solid closure that should prevent implant excursion and/or extrusion.

POSTPROCEDURE

Postoperative management specific to this procedure is as follows. In addition to continuing the antiviral medication, patients are prescribed both a 5-day course of cephalexin and pain medicine to take as needed. However, discomfort is generally minimal and usually stems from edema and bruising, which can last up to a week. In the event of late capsular contracture development, Accolate is begun. Occasionally, a closed capsulotomy may be necessary as well.

The lips are moisturized with petroleum jelly for 2–3 weeks, while the commissural incisions are cleaned with dilute hydrogen peroxide and dressed with antibiotic ointment for 2 weeks. Cold compress-

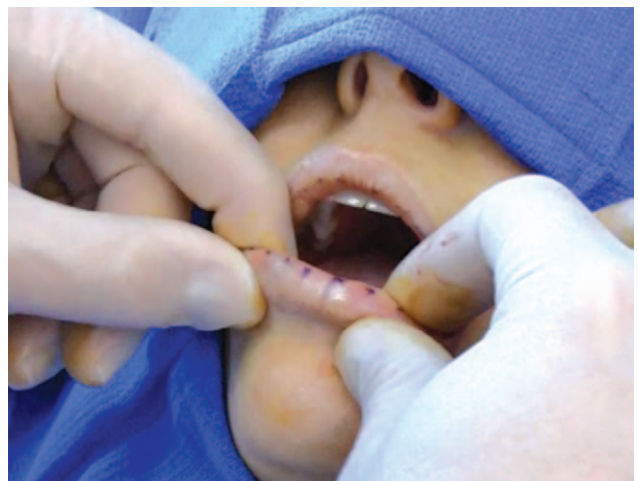

Fig. 9. Centering the implant. After assessing the implant's location, fine-tuning may be warranted. Adjustments are performed by pinching the tapered ends in the desired direction. The importance of this point cannot be overstressed. Note that the lip is even in appearance and not severely turgid from local.

es or ice packs will decrease swelling for the first 3 days. Patients should brush their teeth with a small children’s toothbrush. We ask that they refrain from massaging their lips and smoking to prevent malposition and poor wound healing, respectively.

Once sutures have dissolved and incision sites are fully healed, patients are to perform the following regimen of stretching and tightening exercises for 2–3 months, 3 times a day, 10–15 repetitions each: (1) open big; (2) smile wide; and (3) pucker. These facilitate the healing process, allowing the lips to acclimate to all the extension, retraction, and compression forces produced and incurred during normal motion. Furthermore, such exercises maintain capsule length and have been noted to decrease tightness. Starting them prematurely (ie, within 2 weeks of surgery), however, risks dehiscence and malposition. At follow-up visits, we gauge oral mobility and check for implant “buckling” (as evidenced by sharp folds in the vermilion) by having patients perform said maneuvers. We also remove any sutures present at 2 weeks and confirm centrality of the implants.

METHODS

Medical records of PFI lip augmentation patients of the senior authors (P.R. and S.W.H.) from January 1, 2008, to January 1, 2013, were retrospectively analyzed according to the Declaration of Helsinki,¹⁷ as the private office setting lacked an institutional review board. Demographics, surgery and follow-up dates, and complications were recorded. Operative summaries were examined for implant location, diameter, and length.

To gauge the success rate of PFI implantation, we computed pre- and postoperative PLSs in a random patient sample (*n* = 50). We then asked 4 unbiased plastic surgeons to rate the surgical outcomes of these patients on a 1–5 scale, 5 denoting the greatest aesthetic enhancement. Finally, we administered surveys to our patient sample in which the same 5-point scale was used and results averaged for the following attributes: overall satisfaction; natural appearance and feel; likelihood of recommending PFI to others; how PFI compared to prior augmentation methods (if applicable); and imperceptibility by partner when kissing.

RESULTS

During the aforementioned 5-year span, the senior authors performed 832 PFI lip augmentations on 420 consecutive patients, with a mean follow-up of 2.5 years (range, 1–5 years). Patients ranged between 23 and 76 years old (mean, 42). Ninety-one percent were female, 3% were male, and 6% were transgender. Whites (86%), Hispanics (10%), and Asians (4%) were represented.

Ninety-eight percent underwent a BLA, whereas 2% elected to have exclusive upper or lower augmenting. Regarding diameter of final implant placement, 4mm (78%) was the most popular; 3mm (9%) ones were reserved for extremely thin or senile, atrophic lips; and 5mm (13%) ones were mainly used in removal and replacements when patients requested additional volume. In terms of length, 60mm (45%) and 65mm (44%) implants were inserted most often, while 55mm (11%) ones were least commonly used.

Of the 832 lips analyzed in this series, the total complication rate was 12.3%. Malpositions represented the vast majority at 6.6%. Capsular contracture ranked second at 1.4%. Other less common (<1%) complications included infection; hematoma; extrusion; need for size adjustment; and dissatisfaction. No patient experienced permanent sensation impairment, which accords with the findings by Narsete et al¹⁷ that all PFI patients in his series correctly identified 3 letters traced on their lips with their eyes closed. Moreover, implant buckling was not encountered.

Average pre- and postoperative PLSs were 3.6 and 2.7, respectively, corresponding to a 25.4% shift into the normal range. The mean scores of the polled surgeons were 3.3, 3.9, 4.3, and 4.6. The patient survey response rate was 68%, and results are tabulated in Table 2. The combination of favorable PLS changes, positive marks from patients, and high subjective ratings by surgeons indicates that the implants improved perioral aesthetics. Moreover, photographs documented successful increases in vermilion show and pout; filling out of fine lines and deep wrinkles; and restoration of perioral harmony and dental show. Figure 10 displays a typical result.

DISCUSSION

Hyaluronic acid (HA) fillers currently represent the agent of choice for lip augmentation.^{16,18} However, their major drawback is requisite serial treatment,^{1,4,19} leading to greater expense and collagen deposition. As a 1-time procedure, PFI exhibits minimal scar formation and avoids “needle fatigue.” Other adverse effects of HA include asymmetry, lumpiness, granulomas, nodules, and cyst forma-

Table 2. Survey Results for 34 of 50 Polled Patients

Measure	Average Score*
Overall satisfaction	4.5
Natural appearance and feel	4.7
Likelihood of recommending PFI to others	4.6
How PFI compared to prior augmentation method(s)	4.2
Imperceptibility by partner when kissing	4.1

*On a scale of 1–5, with 5 being the highest mark.

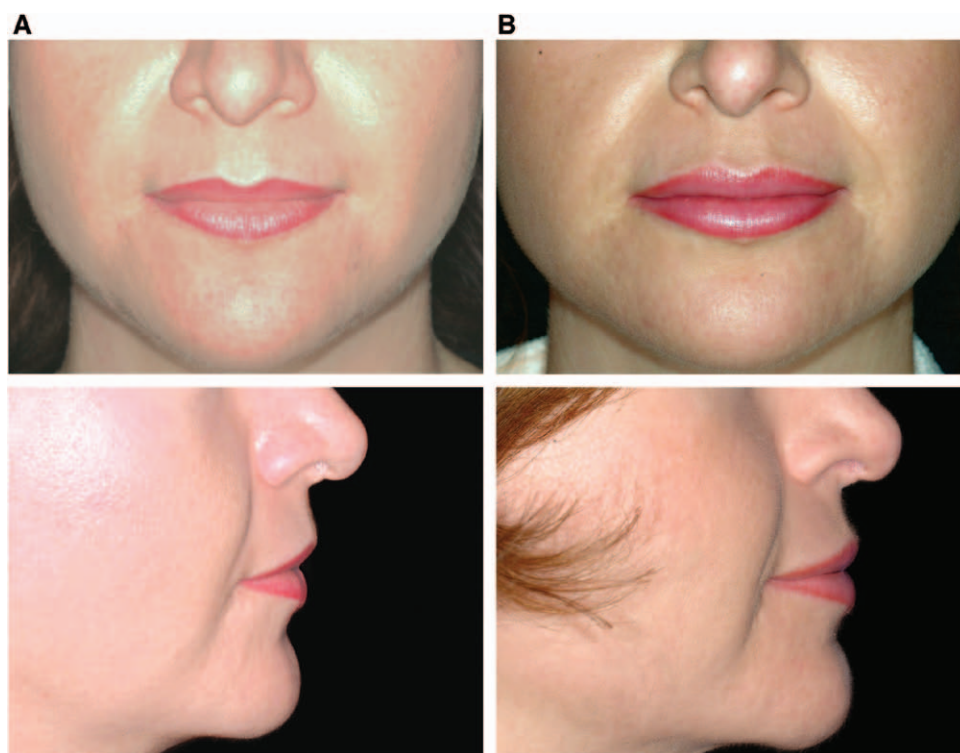

Fig. 10. A, Type 1 woman in her late 20s who complained of aging lips. B, Two years post-BLA with 4mm implants. Note the volume enhancement, rhytid effacement, and heightened vermilion.

tion.^{4,11,13} When such problems arise, the filler's limited duration ironically becomes advantageous.

Whereas HA has replaced collagen,²⁰ lipotransfer remains a popular technique despite controversy regarding autologous fat's longevity.^{9,21–25} Regardless, donor-site morbidity, potentially protracted downtime, and unreliable take^{11,12,26} render it suboptimal in our opinion. Noninjectable fillers, such as dermal-fat or fascial grafts and cadaveric dermis, exhibit resorption as well.^{1,22,26–28} By contrast, silicone implants have been used throughout the body for decades, a key incentive being their tendency not to rupture, deflate, or degrade over time.

Permanent solutions include expanded polytetrafluoroethylene (ePTFE) implants and liquid silicone. The literature cites a host of deleterious side effects that plague ePTFE, including infection, migration, scarring, extrusion, impaired function, hardening, and shrinkage.^{2,9,17,29} Moreover, its promotion of tissue ingrowth may restrict mobility and frustrate implant removal. Perhaps PFI's most unique feature is its ease of reversibility. Unlike ePTFE, its smooth, nonporous surface resists tissue ingrowth. Although silicone microdroplets continue to be championed by some,^{19,30} they have been implicated with disfiguring complications and are thus discouraged.^{9,23,27,31}

As far as PFI complications are concerned, malposition predominates. Although this frequently occurred

early in our series, its prevalence was lowered to 3% through modifications in both intraoperative technique and postoperative instructions. To curtail lateral malpositions, we became fastidious about centering the implant whenever possible and checking its location several times at the end of each case. We also dispensed the least amount of local necessary to render the lips insensate, thus permitting accurate assessment of implant location by palpation of its tapered ends.

Regarding depth malpositions, we made stalwart attempts to dissect immediately below the wet-dry border, as deep in the submucosa as possible but superficial to the muscle, and to keep the tunnel within the dissected tunnel. Finally, we addressed anteroposterior malpositions by rotating the upper lip such that the wet-dry border remained fixed in the surgeon's sightline. This promoted consistent 3-dimensional orientation at key points throughout the procedure—that is, anesthetization, spreading dissection, and tunnel passage.

We attribute our low capsular contracture rate to several factors. In the early post-op period, infrequent infection and the recommended exercises played important roles. Thereafter, we believe that the lips' mobile nature was sufficient to retain normal range of motion. Accolate successfully curtailed the majority of capsular contractures in both the short and long term.

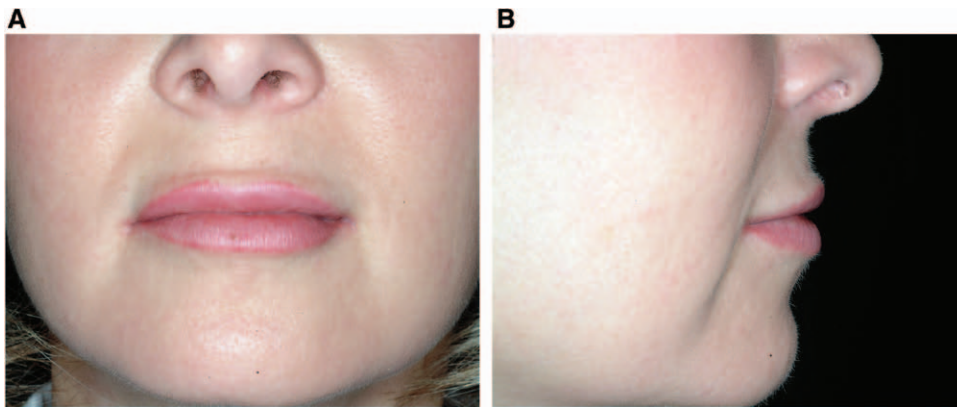


Fig. 11. In this patient, ridging manifests as (A) a shadow just above the vermilion on antero-posterior view and (B) an unnatural protrusion of the cutaneous lip on lateral view.

The need for size adjustment was rare. Errors in length, for example, were best avoided via preoperative measurements on slightly parted lips. We caution against patients closing their mouths and advise surgeons not to measure the linear transcommissural distance, as the resulting implants will be too short. On the other extreme, we disagree with Niamtu³² insofar as wide-open mouths amplify the risk of choosing too long an implant. In retrospect, it seems only logical that our best results occurred when measurements were taken with a slight interlabial gap—that is, a common position of the mouth.

Regarding implant girth, overaugmenting is relatively more common and noticeable. It tends to produce a tight appearance, a horizontal shadow, or perivermilion bulging depending on the angle of view. We term this phenomenon “ridging” (Fig. 11). Its clinical significance may correlate with (1) implant placement too superiorly (upper lip) or inferiorly (lower lip) or (2) excess swelling, especially in the early postoperative period (usually disappearing over 2–3 months). We have thus learned to avoid 5-mm implants as primary treatments. Starting with 4-mm ones (3 mm if the lip looks too thin) allows adequate tissue expansion for eventual 5 mm placement.

We now close with 2 inherent downfalls of PFIs. First, only with a prior mucosal advancement or lip lift can implantation be performed on razor-thin lips. Mucosal advancements furnish extra tissue for inserting PFIs beneath the flaps 3–6 months later. Likewise, lifting unfurls the upper lip to conceal ridging. Another weakness of PFIs, or any lip implant for that matter, is that they do not even out local irregularities. This has never posed an issue given that, in our experience, such defects rarely present, and the vast majority of patients request uniform augmentation. That said, asymmetries may be resolved with filler injections.

CONCLUSIONS

PFI eliminates stigmata common to alternate methods while fulfilling the attributes of an “ideal” filler: namely, it is permanent, reversible, and pliable; mirrors natural contours; improves pout and rhytids; and reduces long-term costs. Moreover, PFIs have elicited positive feedback from nearly all recipients at our practice including those surveyed in this study. For optimal results and minimal complications, surgeons must be discerning in patient and implant selection and observe the technical considerations submitted herein. Concurrently, patients must firmly adhere to the postoperative guidelines. One weakness of PFI is that razor-thin lips often demand lifting or mucosal advancement before augmentation.

Scott W. Harris, MD, FACS

American Institute for Plastic Surgery
6020 West Plano Parkway
Plano, TX 75093
E-mail: drharris@ai4ps.com

REFERENCES

1. Perenack J. Treatment options to optimize display of anterior dental esthetics in the patient with the aged lip. *J Oral Maxillofac Surg.* 2005;63:1634–1641.
2. Cox SE. Who is still using expanded polytetrafluoroethylene? *Dermatol Surg.* 2005;31(11, Part 2):1613–1615; discussion 1615.
3. Holden PK, Sufyan AS, Perkins SW. Long-term analysis of surgical correction of the senile upper lip. *Arch Facial Plast Surg.* 2011;13:332–336.
4. Perkins NW, Smith SP Jr, Williams EF III. Perioral rejuvenation: complementary techniques and procedures. *Facial Plast Surg Clin North Am.* 2007;15:423–432, vi.
5. Rohrich RJ, Reagan BJ, Adams WP Jr, et al. Early results of vermilion lip augmentation using acellular allogeneic dermis: an adjunct in facial rejuvenation. *Plast Reconstr Surg.* 2000;105:409–416; discussion 417–418.
6. Tzikas TL. Evaluation of the Radiance FN soft tissue filler for facial soft tissue augmentation. *Arch Facial Plast Surg.* 2004;6:234–239.

7. Truswell WH. Using permanent implant materials for cosmetic enhancement of the perioral region. *Facial Plast Surg Clin North Am.* 2007;15:433–444, vi.
8. Suryadevara AC. Update on perioral cosmetic enhancement. *Curr Opin Otolaryngol Head Neck Surg.* 2008;16:347–351.
9. Niechajev I. Lip enhancement: surgical alternatives and histologic aspects. *Plast Reconstr Surg.* 2000;105:1173–1183; discussion 1184–1187.
10. Raphael P, Harris R, Harris SW. Analysis and classification of the upper lip aesthetic unit. *Plast Reconstr Surg.* 2013;132:543–551.
11. Ponsky D, Guyuron B. Comprehensive surgical aesthetic enhancement and rejuvenation of the perioral region. *Aesthet Surg J.* 2011;31:382–391.
12. Ho LC. Augmentation cheiloplasty. *Br J Plast Surg.* 1994;47:257–262.
13. Ali MJ, Ende K, Maas CS. Perioral rejuvenation and lip augmentation. *Facial Plast Surg Clin North Am.* 2007;15:491–500, vii.
14. Fanous N. Correction of thin lips: “lip lift”. *Plast Reconstr Surg.* 1984;74:33–41.
15. Braun M, Braun S, van Eijk T. Lip tenting: a simple technique for better lip enhancement. *J Drugs Dermatol.* 2010;9:559–560.
16. Sarnoff DS, Gotkin RH. Six steps to the “perfect” lip. *J Drugs Dermatol.* 2012;11:1081–1088.
17. WMA Declaration of Helsinki—Ethical Principles for Medical Research Involving Human Subjects. <http://www.wma.net/en/30publications/10policies/b3>. Accessed March 3, 2013
18. Narsete T, Ersek R, Narsete MP. Further experience with permafacial implants for lip augmentation: a review of 100 implants. *Aesthet Surg J.* 2011;31:488–492.
19. Kane MA, Lorenc ZP, Lin X, et al. Validation of a lip fullness scale for assessment of lip augmentation. *Plast Reconstr Surg.* 2012;129:822e–828e.
20. Fulton JE Jr, Porumb S, Caruso JC, et al. Lip augmentation with liquid silicone. *Dermatol Surg.* 2005;31(11, Part 2):1577–1585; discussion 1586.
21. Greco TM, Antunes MB, Yellin SA. Injectable fillers for volume replacement in the aging face. *Facial Plast Surg.* 2012;28:8–20.
22. Haworth RD. Customizing perioral enhancement to obtain ideal lip aesthetics: combining both lip voluming and reshaping procedures by means of an algorithmic approach. *Plast Reconstr Surg.* 2004;113:2182–2193.
23. Fulton JE Jr, Rahimi AD, Helton P, et al. Lip rejuvenation. *Dermatol Surg.* 2000;26:470–474; discussion 474–475.
24. Austin HW, Weston GW. Rejuvenation of the aging mouth. *Clin Plast Surg.* 1992;19:511–524.
25. Narsete T, Ersek R. Lip augmentation in conjunction with facelift: preliminary experience with a new permanent implant. *Aesthet Surg J.* 2009;29:356–359.
26. Asaadi M, Haramis HT. Successful autologous fat injection at 5-year follow-up. *Plast Reconstr Surg.* 1993;91:755–756.
27. Chasan PE, Rahban SR. Presacral donor site for lip augmentation. *Aesthetic Plast Surg.* 2000;24:31–33.
28. Botti G, Villedieu R. Augmentation cheiloplasty by using mucomuscular flaps. *Aesthetic Plast Surg.* 1995;19:69–74.
29. Sclafani AP, Romo T III, Jacono AA, et al. Evaluation of acellular dermal graft (AlloDerm) sheet for soft tissue augmentation: a 1-year follow-up of clinical observations and histological findings. *Arch Facial Plast Surg.* 2001;3:101–103.
30. Segall L, Ellis DA. Therapeutic options for lip augmentation. *Facial Plast Surg Clin North Am.* 2007;15:485–490, vii.
31. Moscona RA, Fodor L. A retrospective study on liquid injectable silicone for lip augmentation: long-term results and patient satisfaction. *J Plast Reconstr Aesthet Surg.* 2010;63:1694–1698.
32. Rohrich RJ, Rios JL, Fagien S. Role of new fillers in facial rejuvenation: a cautious outlook. *Plast Reconstr Surg.* 2003;112:1899–1902.
33. Niamtu J III. Advanta facial implants. *Oral Maxillofac Surg Clin North Am.* 2005;17:29–39, v.