

Diagnostic Accuracy of Inverted and Unprocessed Digitized Periapical Radiographs for Detection of Peri-Implant Defects

Seyed Jalal Pourhashemi¹, Zahra Ghoncheh², Mohammad Taghi Kiani³, Raheleh Emami⁴, Mohamad Javad Kharazifard⁵

¹Associate Professor, Dental Research Center, Dentistry Research Institute, Department of Pediatric Dentistry, Faculty of Dentistry, Tehran University of Medical Sciences, International Campus Tehran, Iran

²Assistant Professor, Department of Oral and Maxillofacial Radiology, Faculty of Dentistry, Tehran University of Medical Sciences, International Campus, Tehran, Iran

³Assistant Professor, Department of Oral and Maxillofacial Surgery, Faculty of Dentistry, Tehran University of Medical Sciences, International Campus, Tehran, Iran

⁴Assistant Professor, Department of Oral and Maxillofacial Radiology, Faculty of Dentistry, Semnan University of Medical Sciences, Semnan, Iran

⁵Epidemiologist, Dental Research Center, Dentistry Research Institute, Statistical and Methodology Department, Faculty of Dentistry, Tehran University of Medical Sciences, Tehran, Iran

Abstract:

Objectives: This study aimed to compare the diagnostic accuracy of inverted and unprocessed digitized periapical radiographs for detection of peri-implant defects.

Materials and Methods: A total of 30 osteotomy sites were prepared in three groups of control, study group 1 with 0.425 mm defects and study group 2 with 0.725 mm defects using the SIC and Astra Tech drill systems with 4.25mm and 4.85mm diameters. Small and large defects were randomly created in the coronal 8mm of 20 implant sites; implants (3.4mm diameter, 14.5mm length) were then placed. Thirty periapical (PA) radiographs were obtained using Digora imaging system (Soredex Corporation, Helsinki, Finland), size 2 photostimulable storage phosphor (PSP) plate sensors (40.0mm×30.0mm) and Scanora software. Unprocessed images were inverted using Scanora software by applying image inversion and a total of 60 images were obtained and randomly evaluated by four oral and maxillofacial radiologists. Data were analyzed using the t-test.

Results: Significant differences were observed in absolute and complete sensitivity and specificity of the two imaging modalities for detection of small and large defects ($P < 0.05$). Unprocessed digital images had a higher mean in terms of absolute sensitivity for detection of small defects, complete sensitivity for detection of large peri-implant defects and definite rule out of defects compared with inverted images.

Conclusion: Unprocessed digital images have a higher diagnostic value for detection of small and large peri-implant defects and also for definite rule out of defects compared with inverted images.

Keywords: Radiography; Image Enhancement; Peri-Implantitis

Journal of Dentistry, Tehran University of Medical Sciences, Tehran, Iran (2015; Vol. 12, No. 8)

✉ Corresponding author:

Z. Ghoncheh, Department of Oral and Maxillofacial Radiology, Faculty of Dentistry, Tehran University of Medical Sciences, International Campus.

m_ghoncheh@hotmail.com

Received: 18 February 2015

Accepted: 20 June 2015

INTRODUCTION

Several imaging modalities including PA, occlusal and panoramic radiography, cone beam computed tomography (CBCT) and CT are used before and after implant treatment as well as in the maintenance sessions. After successful implant placement, periodic

radiographs are required to monitor the success or failure of implants. Periapical radiography is usually a suitable imaging modality for long-term follow-ups. Radiographically, a thin radiolucent margin around the implant indicates implant mobility and is an important sign of failed osseointegration [1-3].

The popularity of digital radiography in dentistry is mainly due to the adjustability of digital images by using image inversion, embossed tools, brightness, contrast and magnification enhancement filters [4-9]. By applying image inversion to digital images, opaque areas are converted to lucent areas and vice versa. Inverted digital images are used for various purposes in dentistry such as the measurement of bone loss due to periodontal disease and localization of the mandibular canal and mental foramen [10,11-17].

Several previous studies have compared the diagnostic accuracy of unprocessed digital images (PSP and charge-coupled device or CCD), film-based radiographs and inverted images for detection of peri-implant bone defects and simulated periodontal lesions using Image Tool and Adobe Photoshop software programs [12-14]. This study aimed to compare the diagnostic value of unprocessed (PSP) and inverted digital images for detection of peri-implant defects using Scanora software.

MATERIALS AND METHODS

Preparation of bone segments:

Cow rib was obtained fresh. Soft tissue residues were removed and the rib was trimmed to prepare bone segments suitable for the placement of 30 implants. In between imaging stages, the rib segments were stored at 1°C temperature to minimize moisture loss.

Preparation of osteotomy sites and implant placement:

Osteotomy sites were marked on the superior border of the rib with 15mm distance from one another. A total of 30 implant placement sites including 10 control sites, 10 sites with 0.425mm peri-implant space and 10 sites with 0.725mm peri-implant space were created. The SICace® screw implants (SICace, Basel Switzerland) (3.4mm/14.5mm; cylindrical parallel walled) were placed in the marked areas.

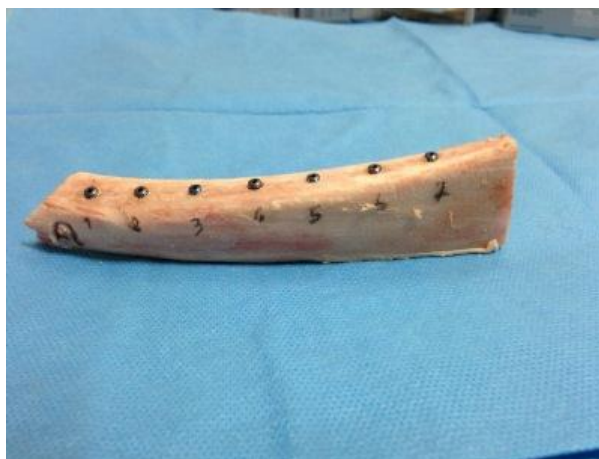


Fig. 1. Sample of fresh cow rib after fixture placement.

Osteotomy sites were prepared in two steps.

In step 1, holes were drilled using SIC drill system with 3.1mm diameter and 14.5mm length (SIC Extension Drill 3.10mm, short).

In step 2 of osteotomy, the coronal 8mm of 10 osteotomy sites was enlarged using a 4.25mm drill (SIC Extension Drill, Basel, Switzerland)(4.25mm, short) to create 0.425 mm peri-implant space.

The coronal 8mm of another 10 sites was enlarged using a 4.85mm diameter drill (Astra Tech Drill, Stockholm, Sweden) (4.85, 8-19mm) to create 0.725mm peri-implant space. To stabilize fixtures in bone, drilling was performed at a diameter of 3.1mm and height of 6mm for the apical part of fixtures and the remaining coronal 8mm was prepared with larger drills to form a gap.

All fixtures measuring 3.4×14.5mm (The SICace® screw implants 3.4mm/14.5mm Incl.) were placed into the osteotomy sites at the level of the superior border of the rib (bone level) and cover screws were inserted (Figure 1). To simulate soft tissue, an acrylic block (polymethyl methacrylate) with 1cm thickness was placed over the bone [18,19]. Periapical radiographs were obtained from the bone segments at the same day the fixtures were placed.



Fig. 2. The X ray tube (2) The simulated soft tissue (3) Bone segment with implant fixtures placed.

Radiographic procedure:

All radiographs were obtained using DIGORA Optime Imaging System (Soredex Corporation, Helsinki, Finland), PSP size 2 sensor (40.0mm×30.0mm) and Minray dental X ray system (Soredex, Tuusula, Finland) with exposure settings of 60 kV and 7mA for 0.16s. Digital intraoral sensor holder (Kerr Dental Europe, Bioggio, Switzerland) was used to ensure equal fixture-sensor distance and their parallel positioning. The focus-object distance was adjusted at 27.5cm (Figure 2).

Radiographic evaluation:

After exposure of sensors, images were stored in DICOM files on a computer using a Scanora Lite software (Palodex, Tuusula, Finland) with standard resolution. By applying image inversion, 60 digital images including 30 unprocessed and 30 inverted images were obtained. Four oral and maxillofacial radiologists with at least two years of work experience evaluated all 60 images for presence or absence of peri-implant defects using a five-point scale:

- Definite defect
- Probable defect
- Not sure
- Probably no defect
- Definitely no defect

Examiners viewed the images on an 18.5" Samsung monitor (Samsung SyncMaster E1945nx, 1360 ×768) under adequate lighting. The examiners were only allowed to adjust the brightness and contrast of digital images (Figure 3).

Data analysis:

In this study the basis of calculating the absolute sensitivity/specificity was the number of the definitely correct diagnoses and the complete sensitivity/specificity was determined based on the total number of definite and probable correct answers. The sensitivity and specificity for detection of small and large peri-implant defects were calculated and compared. Independent t-test was used to compare the diagnostic value of unprocessed and inverted digital imaging modalities. Data were analyzed using SPSS version 20 (Microsoft, IL, USA). Type 1 error was considered as 0.05.

RESULTS

A total of 60 digital PA radiographs including 30 unprocessed and 30 inverted radiographs were obtained of 30 implants with the same diameter and length: 10 implants with no defects, 10 with small (0.425mm) diameter peri-implant defects in the coronal 8mm and 10 with large (0.725mm) diameter peri-implant defects in the coronal 8mm. Based on the results, unprocessed images had a higher diagnostic value than inverted images. According to the t-test, in the equality of the means, no significant difference was detected in the sensitivity of unprocessed and inverted images for detection of peri-implant defects (absolute positive predictive value) and for detection of a probable lesion (complete positive predictive value)($P>0.05$). Considering the equality of variances, the t-test showed that unprocessed images had higher absolute negative predictive value ($P=0.049$) and complete negative predictive value ($P=0.017$) than inverted images (Table 1).

Considering the equality of variances, the t-test showed that unprocessed images had a higher absolute sensitivity for detection of small defects than inverted images ($P=0.48$). However, the mean complete sensitivity of the two modalities for detection of small defects despite the non-equality of variances ($P=0.001$)




Fig. 3. Digital images: (A) Unprocessed (B) Inverted. The white arrow points to the simulated peri-implant defects.

and equality of the means, was not significantly different ($P=0.81$)(Table 2). Considering the equality of variances ($P=0.055$), the t-test failed to find a significant difference in the absolute sensitivity for detection of large defects between the unprocessed and inverted images ($P=1.0$). However, despite the equality of variances ($P=0.003$), the t-test found a

statistically significant difference in complete sensitivity for detection of large defects and unprocessed images had a higher mean value in this respect ($P=0.019$) (Table 2). In the non-equality of the means, the mean absolute specificity of unprocessed and inverted images was significantly different based on the t-test ($P<0.05$) and unprocessed images had a higher diagnostic value. However, in the equality of the means, the complete specificity of unprocessed and inverted images was not significantly different ($P>0.05$) (Table 2).

DISCUSSION

Periapical radiography is conventionally used as the standard follow up radiography after implant placement to assess the peri-implant tissue status. The digital imaging techniques and different enhancement filters have enabled more accurate diagnoses in dentistry. Image inversion is among the commonly used enhancements. This study showed that unprocessed images had a higher diagnostic value than inverted images for detection of small and large peri-implant defects. This finding may be due to the unfamiliarity of the inverted images to the eyes of the observers.

Table 1. The mean \pm standard deviation of absolute and complete negative and positive predictive values of unprocessed and inverted images

Type of image	Absolute negative predictive value (mean \pm SD)	Complete negative predictive value (mean \pm SD)
Unprocessed image	0.93 \pm 0.12	0.93 \pm 0.12
Inverted image	0.75 \pm 0.19	0.70 \pm 0.20
Type of image	Absolute positive predictive value (mean \pm SD)	Complete positive predictive value (mean \pm SD)
Unprocessed image	1.00 \pm 0.00	1.00 \pm 0.00
Inverted image	0.95 \pm 0.08	0.95 \pm 0.08

Table 2. The mean \pm standard deviation of sensitivity and specificity of unprocessed and inverted images for detection of small and large defects

Type of image	Absolute sensitivity for large defects(mean \pm SD)	Absolute sensitivity for small defects (mean \pm SD)	Absolute specificity (mean \pm SD)
Unprocessed image	0.87 \pm 0.23	0.80 \pm 0.37	1.00 \pm 0.00
Inverted image	0.87 \pm 0.11	0.47 \pm 0.20	0.90 \pm 0.10
Type of image	Complete sensitivity for large defects(mean \pm SD)	Complete sensitivity for small defects (mean \pm SD)	Complete specificity (mean \pm SD)
Unprocessed image	1.00 \pm 0.00	0.90 \pm 0.18	1.00 \pm 0.00
Inverted image	0.87 \pm 0.11	0.62 \pm 0.35	0.95 \pm 0.09

Significantly different from zero ($P<0.05$).

Our obtained results were in accord with those of Kavadella et al, [16] de Molon et al, [17] and Jorgenson et al, [18] despite the differences in the type of receptors (film and digital sensor), type of defects and method of creating the defects. However, our results were in contrast to those of Scaf et al, in 2007 [15].

Scaf et al. [15] compared unprocessed and inverted digitized images for detection of bone loss due to periodontal disease and found no significant difference in the diagnostic value of unprocessed and inverted images. Scaf et al, in their study used PA radiographs available in the records of patients with periodontal disease.

These images were digitized using Snapscan PO scanner and inverted using Image Tool software. The difference between our results and those of Scaf et al. may be attributed to the different methodology and the software programs used [15]. Kavadella et al, [16] in their in-vitro study compared film-based conventional radiography with unprocessed and inverted digital radiography with CCD sensors for detection of peri-implant lesions. Our results had some differences with those of Kavadella et al. In our study, the sensitivity and specificity of unprocessed images were higher than those of inverted digital images. The complete sensitivity for detection of small defects was 0.90 for unprocessed and 0.62 for inverted images. The complete sensitivity for large defects was 1 for unprocessed and 0.85 for inverted images. The complete specificity was 1 and 0.95 for unprocessed and inverted images, respectively. However, Kavadella et al. [16] showed high specificity and low sensitivity values. Specificity was 0.82 in unprocessed images and 0.83 in inverted images. These rates were 0.55 and 0.47 for sensitivity, respectively. Such differences may be due to the methodology of studies i.e. method of defect formation, using fresh bone in our study and use of magnification enhancement (X2) by the observers in the study by Kavadella et al. However, our results

regarding the lower accuracy of inverted digital images compared to unprocessed images were similar to those of Kavadella et al [16].

Molon et al, [17] in their study compared the diagnostic accuracy of unprocessed and converted (CMOS Sensor) images with film-based conventional radiographs for detection of bone loss due to simulated periodontal disease. The results showed that inverted digital images had lower accuracy than film-based radiographs. Despite the difference between the type of sensors used in our study and the study by Molon et al, similar results were obtained indicating the higher diagnostic accuracy of unprocessed digital images and film-based radiographs than inverted images [17].

Jorgenson et al, [18] in their comparative study evaluated the diagnostic accuracy of conventional F-speed film radiographs, unprocessed digital radiographs and inverted digital images (PSP, Digora) in patients with vertical bone defects. The digital sensor used in our study was similar to that used by Jorgenson et al, and our results were in accord with their findings [18].

CONCLUSION

Based on the results, we found that unprocessed digital images had higher diagnostic accuracy than inverted images for detection of small and large peri-implant defects.

REFERENCES

- 1- Nyman S, Lindhe J, Karring T, Rylander H. New attachment following surgical treatment of human periodontal disease. *J Clin Periodontol.* 1982 Jul;9(4):290-6.
- 2- Zybutz M, Rapoport D, Laurell L, Persson GR. Comparisons of clinical and radiographic measurements of inter-proximal vertical defects before and 1 year after surgical treatments. *J Clin Periodontol.* 2000 Mar;27(3): 179-86.
- 3- de Azevedo Vaz SL, Neves FS, Figueirêdo EP, Haiter-Neto F, Campos PS. Accuracy of

- enhancement filters in measuring in vitro peri-implant bone level. *Clin Oral Implants Res.* 2013 Oct;24(10):1074-7.
- 4- Scaf G, Sakakura CE, Kalil PF, Dearo de Morais JA, Loffredo LC, Wenzel A. Comparison of simulated periodontal bone defect depth measured in digital radiographs in dedicated and non-dedicated software systems. *Dentomaxillofac Radiol.* 2006 Nov;35(6):422-5.
- 5- Tihanyi D, Gera I, Eickholz P. Influence of individual brightness and contrast adjustment on accuracy of radiographic measurements of infra bony defects. *Dentomaxillofac Radiol.* 2011 Mar;40(3):177-83.
- 6- de Molon RS, Sakakura CE, Morais-Camillo JA, de Almeida Junior PC, de Castro Monteiro Loffredo L, Scaf G. Comparison between embossed digital imaging and unprocessed film-based radiography in detecting periodontal bone defects: An in vitro study. *Oral Radiol.* 2012 Mar;28(2):95-100.
- 7- Tofangchiha M, Bakhshi M, Shariati M, Valizadeh S, Adel M, Sobouti F. Detection of vertical root fractures using digitally enhanced images: reverse-contrast and colorization. *Dent Traumatol.* 2012 Dec;28(6):478-82.
- 8- Mohtavipour ST, Dalili Z, Azar NG. Direct digital radiography versus conventional radiography for estimation of canal length in curved canals. *Imaging Sci Dent.* 2011 Mar;41(1):7-10.
- 9- Yokota ET, Miles DA, Newton CW, Brown CE Jr. Interpretation of periapical lesion using RdioVisioGraphy. *J Endod.* 1994 Oct; 20(10): 490-4.
- 10- Liedke GS, Spin-Neto R, Vizzotto MB, Da Silveira PF, Silveira HE, Wenzel A. Diagnostic accuracy of conventional and digital radiography for detecting misfit between the tooth and restoration in metal restored-teeth. *J Prosthet Dent.* 2015 Jan;113(1):39-47.
- 11- Raitz R, Assuncao Junior JN, Fenyopereira M, Correa L, de Lima LP. Assessment of using digital manipulation tools for diagnosing mandibular radiolucent lesions. *Dentomaxillofac Radiol.* 2012 Mar;41(3):203-10.
- 12- Dove SB, McDavid WD. A comparison of conventional intra-oral radiography and computer imaging techniques for the detection of proximal surface dental caries. *Dentomaxillofac Radiol.* 1992 Aug;21(3):127-34.
- 13- Wolf B, von Bethlenfalvy E, Hassfeld S, Staehle HJ, Eickholz P. Reliability of assessing interproximal bone loss by digital radiography: intrabony defects. *J Clin Periodontol.* 2001 Sep; 28(9):869-78.
- 14- Eickholz P, Riess T, Lenhard M, Hassfeld S, Staehle HJ. Digital radiography of interproximal bone loss; validity of different filters. *J Clin Periodontol.* 1999 May;26(5): 294-300.
- 15- Scaf G, Morihisa O, Loffredo Lde C. Comparison between inverted and unprocessed digitized radiographic imaging in periodontal bone loss measurements. *J Appl Oral Sci.* 2007 Dec;15(6):492-4.
- 16- Kavadella A, Karayiannis A, Nicopoulou-Karayianni K. Detectability of experimental peri-implant cancellous bone lesions using conventional and direct digital radiography. *Aust Dent J.* 2006 Jun;51(2):180-6.
- 17- de Molon RS, Morais-Camillo JA, Sakakura CE, Ferreira MG, Loffredo LC, Scaf G. Measurements of simulated periodontal bone defects in inverted digital image and film-based radiograph: an in vitro study. *Imaging Sci Dent.* 2012 Dec;42(4):243-7.
- 18- Jorgenson T, Masood F, Beckerley JM, Burgin C, Parker DE. Comparison of two imaging modalities: F-speed film and digital images for detection of osseous defects in patients with interdental vertical bone defects. *Dentomaxillofac Radiol.* 2007 Dec;36(8):500-5.
- 19- Dave M, Davies J, Wilson R, Palmer R. A Comparison of cone beam computed tomography and conventional periapical radiography at detecting peri-implant bone defects. *Clin Oral Implants Res.* 2013 Jun; 24(6):671-8.