



Since January 2020 Elsevier has created a COVID-19 resource centre with free information in English and Mandarin on the novel coronavirus COVID-19. The COVID-19 resource centre is hosted on Elsevier Connect, the company's public news and information website.

Elsevier hereby grants permission to make all its COVID-19-related research that is available on the COVID-19 resource centre - including this research content - immediately available in PubMed Central and other publicly funded repositories, such as the WHO COVID database with rights for unrestricted research re-use and analyses in any form or by any means with acknowledgement of the original source. These permissions are granted for free by Elsevier for as long as the COVID-19 resource centre remains active.

## Effects of prone and lateral position in non-intubated patients with 2019 Novel Coronavirus (COVID-19) pneumonia



To the Editor:

Mechanical ventilation in the prone position is a validated strategy of invasive ventilator support in the treatment of acute respiratory distress syndrome (ARDS).<sup>1</sup> Given its beneficial effects, there has been some research into the use of prone positioning also in non-intubated patients with ARDS<sup>2,3</sup> and in patients with COVID-19 to avoid intubation,<sup>4,5</sup> but few studies<sup>2,3,6,7</sup> have assessed its efficacy and possible effects during SARS Cov-2 pandemic.<sup>8–13</sup> The use of standard oxygen and High Flow Nasal Cannula (HFNC) in refractory hypoxemia due to SARS CoV-2 is controversial and many International Guidelines, while suggesting a brief trial, raise concerns about the potential risk of unduly delayed intubation. We describe the physiological changes and clinical outcome of three patients suffering from severe Acute Respiratory Failure (ARF) due to COVID-19 undergoing trials using semi-recumbent, prone and lateral position during standard oxygen and HFNC. All patients tested positive on reverse transcription-polymerase chain reaction (RT-PCR) on throat swabs; comorbidities and administered drugs are reported in [Table 1](#).

A 74 year-old woman was admitted on March 19th, after 10 days of fever. On the 24th she was transferred to our Respiratory Intensive Care Unit (RICU) due to worsening of her respiratory conditions. On arrival, she was haemodynamically stable, her respiratory rate was 18/min in a reservoir oxygen mask at 15l/min; ABG testing showed a severe impairment of gas exchange (PaO<sub>2</sub>/FiO<sub>2</sub> 87; PaO<sub>2</sub> 69 mmHg, PaCO<sub>2</sub> 33 mmHg, pH 7.49, HCO<sub>3</sub>- 27,8 mmol/L). We initiated non-invasive ventilation (NIV) with helmet interface (PSV: PS 22 cmH<sub>2</sub>O, PEEP 10 cmH<sub>2</sub>O, FiO<sub>2</sub> 80%), without improvement of gas exchange (PaO<sub>2</sub>/FiO<sub>2</sub> 80). A high resolution CT-scan (HRCT) showed bilateral consolidations with ground-glass opacities (GGO), mainly in the posterior dependent zones. Based on this radiological picture we pronated the patient whilst administering oxygen-therapy with reservoir mask. An almost immediate increase of SpO<sub>2</sub> was observed ([Fig. 1](#)). At 2 h the PaO<sub>2</sub>/FiO<sub>2</sub> had increased to 203 mmHg and this trend was maintained after 12 h of prone positioning ([Table 1](#)). She improved slowly with a schedule of pronation of two sessions lasting 6 h throughout the day and overnight and was discharged home on April 29th.

The second case was a 71-year-old man, admitted to the Emergency Department (ED) with fever and progressively worsening dry cough for one week. On admission, ABG showed ARF (PaO<sub>2</sub>/FiO<sub>2</sub> 261, PaO<sub>2</sub> 55 mmHg, PaCO<sub>2</sub> 31 mmHg, pH 7.45, HCO<sub>3</sub>-24 mmol/l). Clinical conditions and gas exchange rapidly worsened (ABG 48 h after admission: PaO<sub>2</sub>/FiO<sub>2</sub> 186, PaO<sub>2</sub> 65 mmHg, PaCO<sub>2</sub> 33 mmHg, pH 7.43, HCO<sub>3</sub>- 25,6 mmol/L) and on day 6 since admission he was referred to our RICU, where HFNC therapy was set (Flow 50L/min, FiO<sub>2</sub> 50%). The HRCT scan showed parenchymal involvement of the left lung, with relative sparing of the right one. A spontaneous breathing trial was performed placing the patient on the right lateral decubitus during HFNC

therapy. Respiratory rate rapidly decreased (from 22 to 16 breaths/min) and ABG showed a significant improvement of oxygenation (P/F ratio of 202 and 211 after 2 and 12 h respectively) ([Table 1](#)). Therefore, we scheduled at least two sessions lasting 6 h of lateral position throughout the day and overnight. He was transferred to the ward 8 days after ICU admission and discharged at home after 28 days.

The last patient was admitted to the ED after 6 days of fever, asthenia and dyspnoea. On admission, ABG was normal, but lung ultrasound documented signs suggestive of interstitial-alveolar pneumonia and a HRCT confirmed bilateral GGO associated with initial peripheral consolidations. The patient's condition deteriorated and she was transferred to our RICU, where HFNC therapy was started (Flow 45 L/min, FiO<sub>2</sub> 60%). A novel CT scan showed a relative sparing of the left lung, therefore she was placed in left lateral decubitus. Changes in oxygenation as well as in respiratory pattern are summarized in [Table 1](#). Two sessions lasting 6 h of lateral position throughout the day and overnight determined a stable improvement of gas exchange and prevented mechanical ventilation. She was discharged home after 21 days from hospital admission.

Our findings indicate that this strategy is feasible and a useful option in the management of acute respiratory failure due to this disease. In fact, patient recumbency in accordance with imaging to adjust V/Q was associated with a significant improvement of oxygenation and breathing pattern, with good tolerance. In addition, we found no significant hemodynamic adverse effects. The physiologic rationale for prone positioning and lateral decubitus in non-intubated patients is strong: firstly, redistribution of V/Q ratio due to the gravity-induced increase of blood flow to spared regions of the lung, which become better ventilated<sup>14</sup>; secondly, lung recruitment of previously dependent regions occurs as 'oedema' flows away from anti-gravitational alveoli.<sup>14</sup> Similarly, positioning patients with unilateral pleuro-parenchymal disease with the normal lung down, especially in the absence of pleural pain, can affect gas exchange.<sup>15,16</sup> Thirdly, the increase in oxygenation should also ameliorate hypoxemic vasoconstriction, reducing pulmonary vascular resistance and improving right ventricular function.<sup>17</sup> In addition, in the prone position we may obtain a relief from the weight of the mediastinum and a decrease in overdistension of the healthy areas, thanks to the distribution of trans-pulmonary pressure. In fact, recruitment of the dorsal lung, which has a higher degree of perfusion in either position, reduces shunt.<sup>18,19</sup> A retrospective study including 15 patients showed a beneficial effect of prone position during NIV in patients with severe ARF due to pneumonia.<sup>2</sup> Recently, Ding<sup>3</sup> reported a reduction in intubation rate in patients with moderate to severe ARDS when treated with combined prone positioning and NIV or HFNC.

Recent studies<sup>8–13</sup> showed that prone positioning may improve gas exchange in COVID-19 patients during oxygen therapy and non invasive support ( HFNC or NIV). However, no information about the radiological pattern has been provided. In contrast, our cases showed that the distribution of parenchymal lesions could be a valid criterion to select patient for spontaneously breathing trial in prone positioning and lateral decubitus. Chest x-ray could be useful to support diagnosis, especially during Sars-cov 2 pandemic: sensitivity values range from 57% to 89%.<sup>20</sup> However,

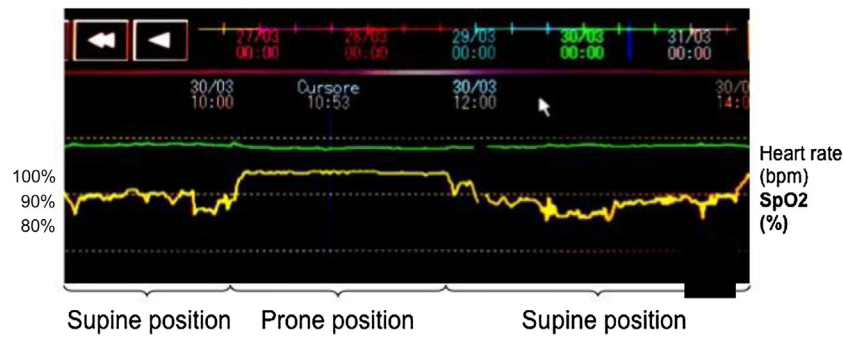
**Table 1** Demographic, clinical characteristics, laboratory and CT-scan findings at respiratory intensive care unit admission, drugs, ABGs.

	Patient 1	Patient 2	Patient 3
Demographics			
Age-yr	74	71	70
Sex	Female	Male	Female
Initial findings			
Medical history	Dyslipidemia, hypothyroidism, carotid atheroma	Hypertension, deep venous thrombosis	Hypercholesterolemia and hypertension
Symptoms at disease onset	Fever	Fever, cough	Fever, asthenia, dyspnoea
Pharmacological treatment <i>(dosages are shown for drugs initiated during RICU stay)</i>	Hydroxychloroquine, piperacillin- tazobactam, azithromycin, enoxaparin, tocilizumab 162 mg x2 s.c., methylprednisolone 1,6 mg/kg	Hydroxychloroquine, enoxaparin, ceftriaxone, tocilizumab 162 mg x2 s.c., methylprednisolone 1 mg/kg	Hydroxychloroquine, azithromycin, enoxaparin, ceftriaxone, tocilizumab, methylprednisolone
Imaging features			
Thoracic HRCT scan	GGO, bilateral pulmonary infiltrates, mainly in the posterior dependent zones	GGO and consolidations prevalent on the left lung	GGO and pulmonary infiltrates prevalent on the right lung
Days from Hospital admission to prone/lateral decubitus	6	11	8
[10pt]			

Table 1 (Continued)

ABGs	Patient 1			Patient 2			Patient 3			
	PRE	During NIV	PP/LD after 12h	PRE	During HFNC	During PP/LD	PRE	During HFNC	During PP/LD	
pH	7,49	7,48	7,47	7,42	7,45	7,43	7.48	7,49	7,45	
PaCO <sub>2</sub> (mmHg)	32	31	35	42	39	40	33	30	35	
PaO <sub>2</sub> (mmHg)	66	62	162	80	76	80	62	70	109	
PaO <sub>2</sub> /FiO <sub>2</sub>	83	80	203	160	158	211	115	116	205	
HCO <sub>3</sub> <sup>-</sup> (mmol/L)	26	26	27	27	27	26	26	26	25	
Vital Parameters										
		PRE	PP/LD after 2h	After 12h	PRE	PP/LD after 2h	After 12h	PRE	PP/LD after 2h	After 12h
RR (breaths per minute)		25	20	26	22	16	18	21	22	20
Heart rate (bpm)		87	72	80	74	60	65	68	64	65
Mean Arterial Pressure (mmHg)		97	113	107	108	97	103	88	87	96

RICU, Respiratory Intensive Care Unit; GGO, ground-glass opacities; s.c., sub cutaneous; NIV, non invasive mechanical ventilation; HFNC, High Flow Nasal Cannula; PP, prone position; LD, lateral decubitus.



**Figure 1** Pulse oximetry pleth waveform of the same patient during supine and prone position.

Chest-x-ray can not detect spared lung areas: exclusive dorsal lung areas involvement can not be detected without latero-lateral projection, not usually performed in critical setting, requiring orthostatic posture. As observed by Marini,<sup>4</sup> COVID-19 pneumonia appears to include an important vascular insult that potentially mandates a different approach from that usually applied for ARDS. Our patients, despite very poor oxygenation and extensive parenchymal lesions, recovered without needing either NIV or intubation, and such a result would not, probably, have been possible in a “traditional” ARDS. All healthcare workers exposed used personal protective equipment (PPE).<sup>21</sup> Interestingly, in all 3 cases reported we observed that PaCO<sub>2</sub> did not change, indicating that the change in PaO<sub>2</sub> was not a consequence of a change in alveolar ventilation, supporting the theory of a beneficial effect on V/Q ratio. However, we do not recommend delaying intubation or attempting this approach in a setting without intensive monitoring, which is necessary to quickly upgrade ventilatory support in non-responders.

To conclude, we have demonstrated that preferential decubitus on the least affected areas of the lung, either in prone or lateral position, in awake and spontaneously breathing, non-intubated patients with ARF due to COVID-19 pneumonia is feasible, well tolerated and is associated with a significant benefit on oxygenation. Further studies are warranted to confirm our results.

## Declaration of interests

The authors declare that they have no known competing financial interests or personal relationships that could have appeared to influence the work reported in this paper.

## References

1. Fan E, Del Sorbo L, Goligher EC, Hodgson CL, Munshi L, Walkey AJ, et al. An Official American Thoracic Society/European Society of Intensive Care Medicine/Society of Critical Care Medicine Clinical Practice Guideline: mechanical ventilation in adult patients with acute respiratory distress syndrome. *Am J Respir Crit Care Med*. 2017;195(9):1253–63.
2. Scaravilli V, Grasselli G, Castagna L, Zanella A, Isgrò S, Lucchini A, et al. Prone positioning improves oxygenation in spontaneously breathing nonintubated patients with hypoxemic acute respiratory failure: A retrospective study. *J Crit Care*. 2015;30(6):1390–4.
3. Ding L, Wang L, Ma W, He H. Efficacy and safety of early prone positioning combined with HFNC or NIV in moderate to severe ARDS: a multi-center prospective cohort study. *Crit Care*. 2020;24(1):28.
4. Marini JJ, Gattinoni L. Management of COVID-19 respiratory distress. *JAMA*. 2020;323(22):2329–30.
5. Sun Q, Qiu H, Huang M, Yang Y. Lower mortality of COVID-19 by early recognition and intervention: experience from Jiangsu Province. *Ann Intensive Care*. 2020;10(1):33.
6. Valter C, Christensen AM, Tollund C, Schønemann NK. Response to the prone position in spontaneously breathing patients with hypoxemic respiratory failure. *Acta Anaesthesiol Scand*. 2003;47:416–8.
7. Feltracco P, Serra E, Barbieri S, Persona P, Rea F, Loy M, et al. Non-invasive ventilation in prone position for refractory hypoxemia after bilateral lung transplantation. *Clin Transplant*. 2009;23(5):748–50.
8. Sartini C, Tresoldi M, Scarpellini P, Tettamanti A, Carcò F, Landoni G, et al. Respiratory parameters in patients with COVID-19 after using noninvasive ventilation in the prone position outside the intensive care unit. *JAMA*. 2020;323(22):2338–40.
9. Elharrar X, Trigui Y, Dols AM, Touchon F, Martinez S, Prud'homme E, et al. Use of prone positioning in nonintubated patients with COVID-19 and hypoxemic acute respiratory failure. *JAMA*. 2020;323(22):2336–8.
10. Coppo A, Bellani G, Winterton D, Di Pierro M, Soria A, Faverio P, et al. Feasibility and physiological effects of prone positioning in non-intubated patients with acute respiratory failure due to COVID-19 (PRON-COVID): a prospective cohort study. *Lancet Respir Med*. 2020;8(8):765–74.
11. Thompson AE, Ranard BL, Wei Y, Jelic S. Prone positioning in awake, nonintubated patients with COVID-19 hypoxemic respiratory failure. *JAMA Intern Med*. 2020 Jun;17:e203030.
12. Ng Z, Tay WC, Ho CHB. Awake prone positioning for non-intubated oxygen dependent COVID-19 pneumonia patients. *Eur Respir J*. 2020;56(1):2001198.
13. Zang X, Wang Q, Zhou H, Liu S, Xue X, Group C-EPPS. Efficacy of early prone position for COVID-19 patients with severe hypoxia: a single-center prospective cohort study. *Intensive Care Med*. 2020;46(10):1927–9.
14. Scholten EL, Beitler JR, Prisk GK, Malhotra A. Treatment of ARDS with prone positioning. *Chest*. 2017;151(1):215–24.
15. Chang SC, Shiao GM, Perng RP. Postural effect on gas exchange in patients with unilateral pleural effusions. *Chest*. 1989;96(1):60–3.
16. Romero S, Martín C, Hernández L, Arriero JM, Benito N, Gil J. Effect of body position on gas exchange in patients with unilateral pleural effusion: influence of effusion volume. *Respir Med*. 1995;89(4):297–301.
17. Jozwiak M, Teboul JL, Anguel N, Persichini R, Silva S, Chemla D, et al. Beneficial hemodynamic effects of prone positioning in

- patients with acute respiratory distress syndrome. *Am J Respir Crit Care Med.* 2013;15(12):1428–33, 188.
18. Bellani G, Messa C, Guerra L, Spagnoli E, Foti G, Patroniti N, et al. Lungs of patients with acute respiratory distress syndrome show diffuse inflammation in normally aerated regions: a [18F]-fluoro-2-deoxy-D-glucose PET/CT study. *Crit Care Med.* 2009;37(7):2216–22.
  19. Nyrén S, Mure M, Jacobsson H, Larsson SA, Lindahl SG. Pulmonary perfusion is more uniform in the prone than in the supine position: scintigraphy in healthy humans. *J Appl Physiol* (1985). 1999;86(4):1135–41.
  20. Ippolito D, Pecorelli A, Maino C, Capodaglio C, Mariani I, Giandola T, et al. Diagnostic impact of bedside chest X-ray features of 2019 novel coronavirus in the routine admission at the emergency department: case series from Lombardy region. *Eur J Radiol.* 2020;129:109092.
  21. Ippolito M, Vitale F, Accurso G, Iozzo P, Gregoretti C, Giaratano A, et al. Medical masks and respirators for the protection of healthcare workers from SARS-CoV-2 and other viruses. *Pumology.* 2020;26(4):204–12.

Schifino G<sup>a,b,\*</sup>, de Grauw A.J.<sup>a,b</sup>, Daniele F<sup>a,b</sup>, Comellini V<sup>a</sup>, Fasano L<sup>a</sup>, Pisani L<sup>a,b</sup>

<sup>a</sup> *Respiratory and Critical Care Unit, University Hospital St. Orsola-Malpighi, Bologna, Italy*

<sup>b</sup> *Respiratory and Critical Care, Sant'Orsola Malpighi Hospital, Alma Mater Studiorum, Department of Specialistic, Diagnostic and Experimental Medicine (DIMES), University of Bologna, Bologna, Italy*

\* Corresponding author.

E-mail address: [lara.pisani@aosp.bo.it](mailto:lara.pisani@aosp.bo.it) (G. Schifino).

29 May 2020

<https://doi.org/10.1016/j.pulmoe.2020.10.015>

2531-0437/ © 2020 Published by Elsevier España, S.L.U. on behalf of Sociedade Portuguesa de Pneumologia. This is an open access article under the CC BY-NC-ND license (<http://creativecommons.org/licenses/by-nc-nd/4.0/>).

## Wearing of medical mask over the high-flow nasal cannula for safer oxygen therapy in the COVID-19 era



To the Editor

The emergence of severe acute respiratory syndrome-coronavirus-2 (SARS-CoV-2) and its associated respiratory disease, coronavirus disease 2019 (COVID-19), has imposed social and medical burdens worldwide. Up to 12% of patients with SARS-CoV-2 infection required intensive care unit admission. Among them, 60–70% had acute hypoxic respiratory failure.<sup>1</sup>

High-flow nasal cannula (HFNC) oxygen therapy is the generally prescribed respiratory therapy for acute hypoxic respiratory failure. This therapy might help limit the need for invasive mechanical ventilation (IMV) and prevent the occurrence of associated adverse events such as ventilator-associated pneumonia in COVID-19 patients.<sup>2</sup> However, administration of HFNC oxygen therapy in COVID-19 patients remains controversial, owing to uncertainties regarding the potential risk of viral transmission to healthcare workers, as this therapy is considered as an aerosol-generating procedure.<sup>3</sup> Indeed, IMV can be selected when low-flow oxygen therapy through a nasal cannula fails and a shortage of ventilators is a medical and social problem in regions particularly hard-hit by this pandemic. Therefore, a safe and effective respiratory management for COVID-19 patients should be urgently established.

Recent practical recommendations for COVID-19 patients indicate the use of a medical mask over the HFNC device to limit particle dispersion due to exhaled gas flow.<sup>4,5</sup> These recommendations are partially supported by two previ-

ous experimental studies that indirectly examined exhaled breath by visualizing airflow movement using smoke<sup>6</sup> and computational fluid dynamic (CFD) simulation.<sup>7</sup> However, to the best of our knowledge, there is no direct evidence that this strategy could reduce the risk of SARS-CoV-2 transmission to healthcare workers in clinical settings due to the technical difficulty in direct visualization of particle dispersion. Here we present an experimental trial with a novel fine particle visualization system, which allowed evaluating whether particle dispersion from coughing while on HFNC oxygen could be suppressed by an appropriately placed medical mask.

We ran six scenarios with a healthy volunteer with nasal cannula at 3 L/min and 21% fraction of inspired oxygen (room air) delivered at 40 L/min 37°C via HFNC (AIRVO™ 2 device with an Optiflow™ nasal interface [Fisher & Paykel, Auckland, New Zealand]). The volunteer was in a sitting position (seat height: 45 cm), and the evaluation was performed with and without wearing a standard medical mask. Particle dispersion was visualized by a video camera set at 29.97 frames per second (Eye Scope). This system used a light emitting diode (wavelength 400–410 nm; Parallel Eye D), which permitted a visualization of particle  $\geq 1 \mu\text{m}$  in diameter. Images obtained were reconstructed as videos using commercial software (Particle Eye). Equipment described above depended on Shin Nippon Air Technologies (Tokyo, Japan).

First, we identified exhaled particles dispersed from coughing in the absence of either nasal cannula, HFNC, or a mask, which reached a horizontal distance of 57 cm (Fig. 1A and supplemental video A). Second, exhaled particles were dispersed from coughing in a similar fashion when using nasal cannula (Fig. 1B and supplemental video B) and HFNC (Fig. 1C and supplemental video C), which reached a horizontal distance of 62 cm and 59 cm, respectively. Notably, when the volunteer wore a standard medical mask, no exhaled particles were detected from coughing either without (Fig. 1D and supplemental video D) or with concurrent nasal cannula (Fig. 1E and supplemental video E) or HFNC therapy (Fig. 1F and supplemental video F).

**Abbreviations:** CFD, computational fluid dynamic; COVID-19, coronavirus disease 2019; HFNC, high-flow nasal cannula; IMV, invasive mechanical ventilation; SARS-CoV-2, severe acute respiratory syndrome-coronavirus-2.