

Submitted:  
29.01.2018  
Accepted:  
16.03.2018  
Published:  
06.09.2018

## Spontaneous resolution of unifocal Langerhans cell histiocytosis of the skull: potential role of ultrasound in detection and imaging follow-up

Filip M. Vanhoenacker<sup>1,2,3</sup>, Joris Verlooy<sup>4</sup>, Mania De Praeter<sup>5</sup>

<sup>1</sup> Department of Radiology, Antwerp University Hospital and Antwerp University, Edegem, Belgium

<sup>2</sup> Department of Radiology, AZ Sint-Maarten, Duffel-Mechelen, Belgium

<sup>3</sup> Department of Radiology and Faculty of Medicine and Health Sciences, Ghent University, Ghent, Belgium

<sup>4</sup> Department of Pediatrics, Antwerp University Hospital and Antwerp University, Edegem, Belgium

<sup>5</sup> Department of Neurosurgery, Antwerp University Hospital and Antwerp University, Edegem, Belgium

Correspondence: Filip M. Vanhoenacker, M.D., Ph.D., Department of Radiology, Antwerp University Hospital, Wilrijkstraat, 10, 2650 Edegem, Belgium, e-mail: filip.vanhoenacker@telenet.be

DOI: 10.15557/JoU.2018.0038

### Keywords

Langerhans cell histiocytosis, ultrasound, CT, MRI

### Abstract

Langerhans cell histiocytosis is a tumor-like condition characterized by idiopathic proliferation of Langerhans cells. The disease may involve the skeleton as well as other organs systems. Bone involvement may be solitary or multifocal. Unifocal osseous Langerhans cell histiocytosis may involve virtually any bone, with the calvarium being most frequently involved. Plain radiography, computed tomography and magnetic resonance imaging are the most used techniques for detection and characterization of the lesion. The use of ultrasound is less known, although it may be a valuable technique in detection and follow-up of superficially located lesions such as calvarial lesions. This case report describes an 8-year-old girl, in whom the lesion was initially detected by ultrasound. Furthermore, ultrasound was used to evaluate spontaneous resolution of the lesion. The knowledge of ultrasound characteristics may be important to avoid unnecessary radiation and gadolinium administration, particularly in a pediatric population.

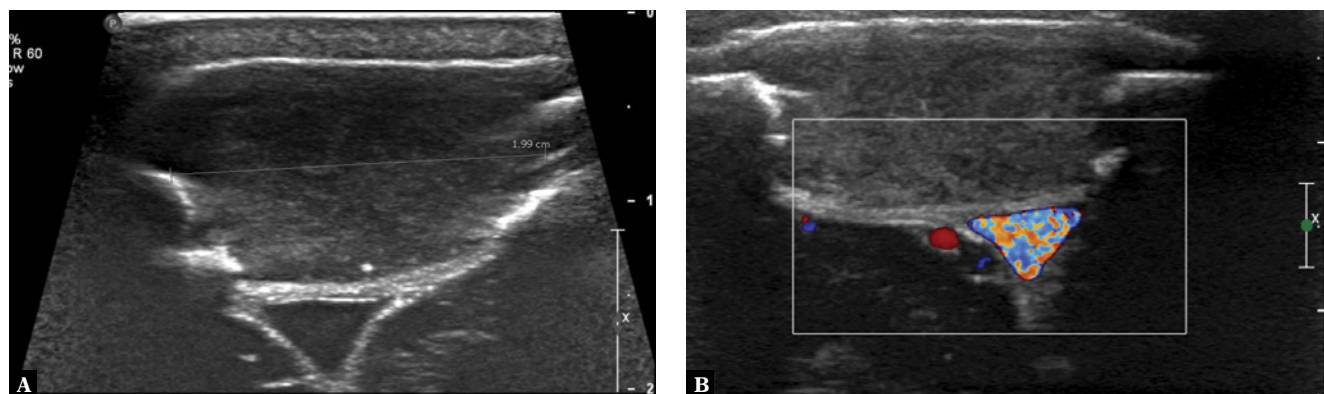
### Case report

An 8-year-old girl was referred to our department for an ultrasound of the skull. She had been complaining for 6 weeks of focal pain at the scalp. Initially, the parents felt no palpable lump, but a progressive soft lump at the right paramedian posterior parietal region was revealed by the father of the child a few weeks later. There was no clear history of a trauma and further medical history was unremarkable. There were no systemic complaints.

Ultrasound demonstrated a focal skull defect in the right parietal bone near the midline. The bony defect

was filled with a hypoechogenic solid mass, extending both within the soft tissue and intracranially. The lesion showed intimate contact with the superior sagittal sinus. The lesion measured 2 × 1.7 and 1.2 cm. Color Doppler and Power Doppler showed absence of intralesional flow (Fig. 1). Contrast-enhanced ultrasound and elastography were not performed at the time of the admission.

Subsequent computed tomography (CT) confirmed a large osteolytic defect with non-sclerotic margins and beveled edges. The outer table was more involved than the inner table (Fig. 2).



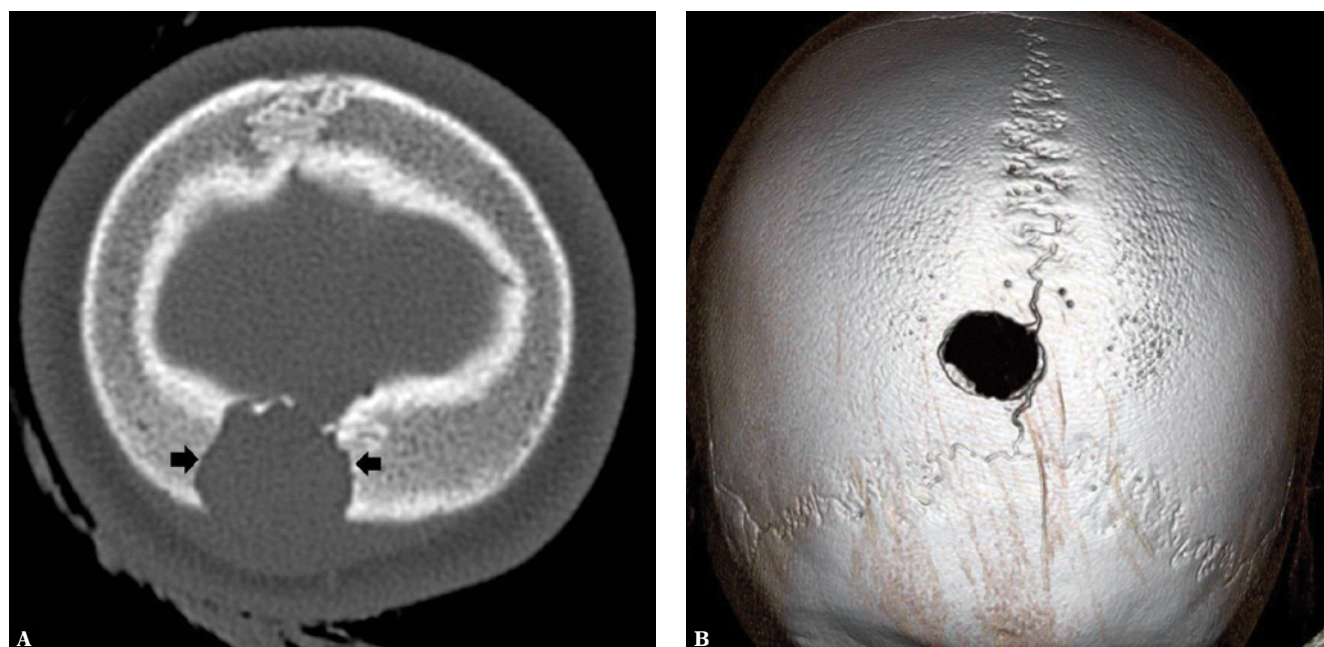
**Fig. 1.** *Ultrasound on admission. A. Transverse gray scale image showing a focal paramedian skull defect extending within the outer and inner table of the right parietal bone. There is an intracranial hypoechoic mass with extracranial and intracranial extension. B. Transverse color Doppler image clearly demonstrates the intimate relationship with the superior sagittal sinus. Color Doppler and Power Doppler showed absence of intracranial flow*

On magnetic resonance imaging (MRI), the lesion was isointense to brain tissue on T1-weighted images (WI) and of intermediate signal on T2-WI. There was vivid enhancement and there was no diffusion restriction (Fig. 3). Intra- and extracranial extension was better demonstrated on MRI than CT.

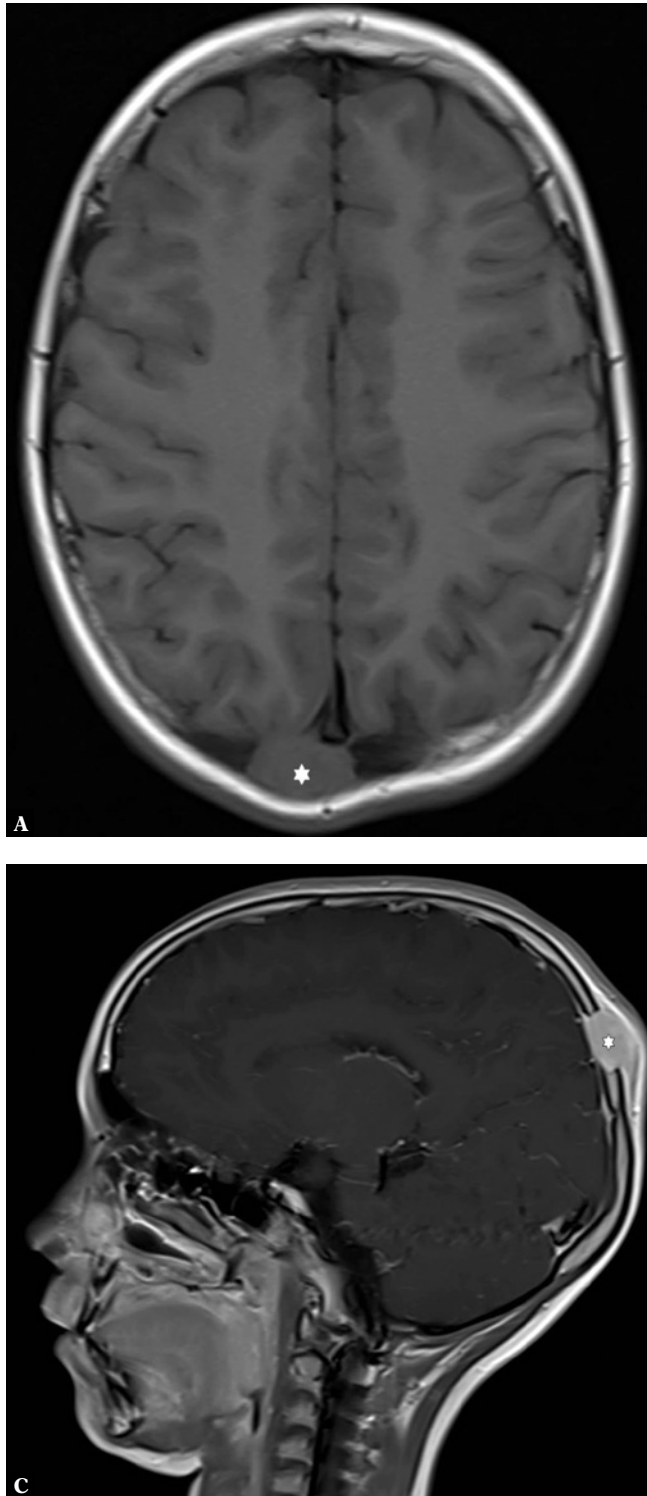
The presumptive imaging diagnosis of unifocal Langerhans cell histiocytosis was made. The differential diagnoses included epidermoid cyst, congenital skull defect and growing fracture. Absence of diffusion restriction argued against the diagno-

sis of an epidermoid cyst. As the lesion appeared de novo clinically and there was no history of trauma, congenital skull defect and growing fracture were unlikely. The absence of an oncologic history (e.g. neuroblastoma) argued against the hypothesis of a metastatic lesion of the calvarium.

Further clinical examination was negative for systemic diseases and was completely normal. Plain radiographs of the chest and spine showed no additional lesions.



**Fig. 2.** *CT on admission. A. Axial image in bone window. Note an osteolytic defect of the right parietal bone, with beveled edges (arrows). There is also subtle soft tissue swelling (white asterisk). B. 3D Volume Rendering Technique (VRT) image shows that the lesion is located adjacent to the sagittal suture but there is no crossing of the suture*



**Fig. 3.** MRI on admission. **A.** Axial T1-WI. The lesion is isointense to gray matter (white asterisk). **B.** Axial T2-WI. The lesion is of intermediate signal with intralésional areas of high signal compared to gray matter (white asterisk). **C.** Sagittal T1-WI after intravenous administration of gadolinium contrast. The lesion enhances slightly more at the periphery than in the center (white asterisk)

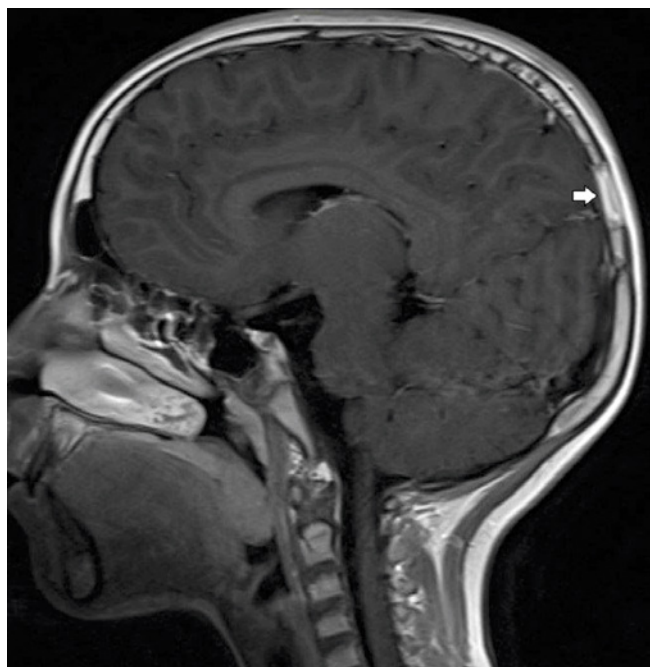
A biopsy was initially planned, but 6 weeks later, there was no residual palpable lump. Repeat MRI at 6 weeks revealed a residual skull defect, but the soft tissue component had disappeared (Fig. 4).

Because of the characteristic imaging findings and the spontaneous resolution of the soft tissue lump,

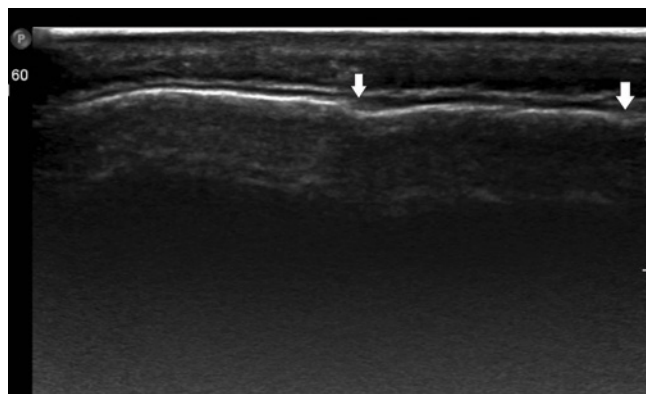
we judged that biopsy was not justified and a watchful waiting policy was recommended. Further clinical follow-up was uneventful at 3 and 6 months.

Follow-up ultrasound (Fig. 5) and MRI performed 14 months (Fig. 6) after the initial presentation showed complete resolution and reossification of the lesion.





**Fig. 4.** Follow-up MRI 6 weeks after the initial presentation. Sagittal T1-WI after intravenous administration of gadolinium contrast. The intra- and extra-cranial component of the lesion has disappeared (white arrow)



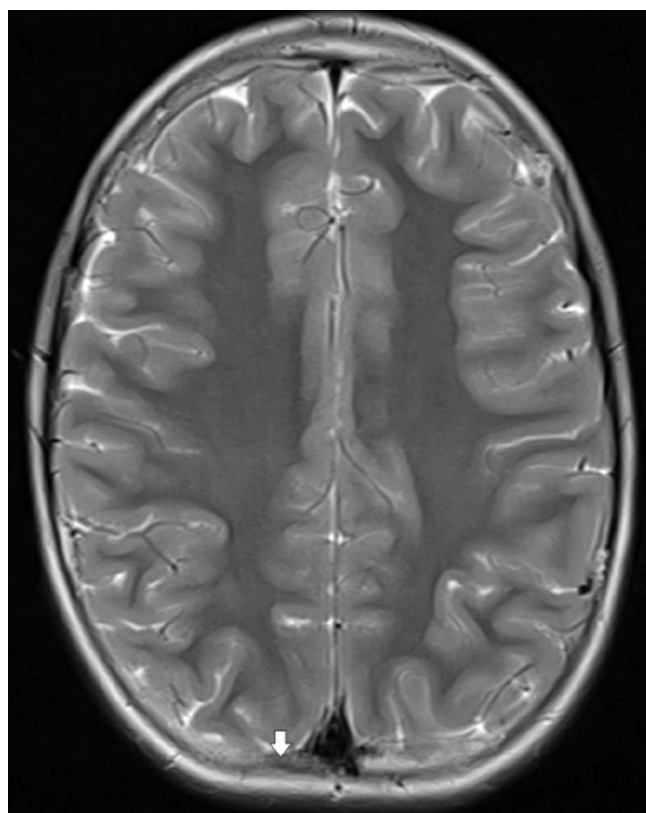
**Fig. 5.** Follow-up ultrasound of the skull 14 months after the initial presentation. Apart from a minor residual contour irregularity (white arrows), there is no residual skull defect

Although there was a lack of histopathological proof, the presumed diagnosis of unifocal Langerhans cell histiocytosis eosinophilic granuloma of the skull was made based on the combination of the location, characteristic imaging features and the spontaneous resolution. Clinical follow-up performed 20 months following the initial presentation was unremarkable.

## Discussion

Langerhans cell histiocytosis (LCH) is a rare systemic disorder characterized by idiopathic proliferation of histiocytes, called Langerhans cells, in different organs including the bones, lungs, central nervous system, liver and spleen, skin, thymus and lymph nodes. The severity and clinical behavior depend on the number and type of organ systems involved. Skeletal involvement is common and may affect one or multiple bones. Involvement of a solitary bone was previously referred to as eosinophilic granuloma (EG) and is the most common presentation of LCH in children<sup>(1)</sup>.

Unifocal LCH of bone may involve virtually any bone, with peak presentation between the ages of 5 and 15 years. Typical locations are the pelvis, the long bones and the skull. Solitary calvarial lesions are the most frequent presentation<sup>(2)</sup>.



**Fig. 6.** MRI 14 months after the initial presentation. Axial T2-WI. There is complete reossification of the bony defect (white arrow)

Clinically, calvarial LCH often presents as a painful lump at the scalp.

Further diagnosis is most often made on plain radiographs, CT or MRI.

Skull radiographs typically demonstrate as a “punched-out” osteolytic lesion, initially without sclerosis. Dur-

ing the healing phase, the lesion may develop a sclerotic rim.

On CT, the edges of the osteolytic defect are often beveled due to uneven destruction of the outer and inner table. A button sequestrum representing residual bone may be present and is more readily detected on CT than on plain radiographs. The lesion typically does not cross the sutures. CT may also allow to visualize the soft tissue component<sup>(3)</sup>.

On MRI, the lesion is isointense to gray or white matter on T1-WI, heterogeneously hyperintense on T2-WI and there is vivid enhancement. The enhancement of the lesion is variable. Often, there is enhancement of an associated dural tail and extraosseous component<sup>(2)</sup>.

Ultrasound has been rarely used to demonstrate EG<sup>(4)</sup>. However, as demonstrated in our case, it is a quick tool for initial detection of superficially located calvarial lesions, evaluation of the associated soft tissue lesion and contact with the extradural sinuses. Similar to CT, ultrasound shows unequal destruction of the outer and inner table of the skull.

B-mode ultrasound is limited in the evaluation of musculoskeletal lesions with a sensitivity of 76.9% and a specificity of 78.8% for the differentiation of benign versus malignant soft tissue tumors<sup>(5)</sup>. Power Doppler ultrasound allows to evaluate the vascularity of the lesion, but this is not always helpful in further characterization of the lesion. In contrast to the case reported by Holley, our case showed absence of intralesional Doppler signal.

Analysis of perfusion pattern and time of enhancement on Contrast Enhanced Ultrasound (CEUS) has been used for characterization and differentiation of benign versus malignant soft tissue masses<sup>(6,7)</sup>. Intense inhomogeneous enhancement with avascular areas and rapid enhancement favors the diagnosis of a malignant soft tissue mass.

## References

1. Azouz EM, Saigal G, Rodriguez MM, Podda A: Langerhans' cell histiocytosis: pathology, imaging and treatment of skeletal involvement. *Pediatr Radiol* 2005; 35: 103–115.
2. D'Ambrosio N, Soohoo S, Warshall C, Johnson A, Karimi S: Craniofacial and intracranial manifestations of langerhans cell histiocytosis: Report of findings in 100 patients. *AJR Am J Roentgenol* 2008; 191: 589–597.
3. Zhang XH, Zhang J, Chen ZH, Sai K, Chen YS, Wang J *et al.*: Langerhans cell histiocytosis of skull: A retrospective study of 18 cases. *Ann Palliat Med* 2017; 6: 159–164.
4. Holley A: Sonographic diagnosis of unifocal Langerhans cell histiocytosis of the skull. *J Clin Ultrasound* 2010; 38: 440–442.
5. Pass B, Jafari M, Rowbotham E, Hensor EM, Gupta H, Robinson P: Do quantitative and qualitative shear wave elastography have a role in evaluating musculoskeletal soft tissue masses? *Eur Radiol* 2017; 27: 723–731.
6. Loizides A, Peer S, Plaikner M, Djurdjevic T, Gruber H: Perfusion pattern of musculoskeletal masses using contrast-enhanced ultrasound: A helpful tool for characterisation? *Eur Radiol* 2012; 22: 1803–1811.

The potential role of quantitative and qualitative shear wave elastography in evaluating musculoskeletal soft tissue masses has been recently evaluated. Although there may be some evidence of an association between lower shear wave velocity and soft tissue malignancy, there is no statistically significant correlation between shear wave velocity and soft tissue malignancy, and there is no substantive improvement to detect malignancy over B-mode ultrasound<sup>(5)</sup>. Moreover, there are no specific data in the current literature regarding the imaging pattern of LCH of the musculoskeletal system in particular on CEUS or elastography.

Unifocal LCH is a self-limiting disease and the prognosis is generally good, if appropriate treatment is provided. Spontaneous resolution or decrease in size has been previously reported and usually starts within 2 months, with initial disappearance of the soft tissue component, followed by complete repair and reossification over the following months<sup>(8)</sup>.

When the lesion has a characteristic imaging appearance, biopsy may not be justified and a watchful waiting policy with clinical and radiologic examinations at regular intervals may be preferable<sup>(9)</sup>. Spontaneous resolution of the lesion proven on imaging makes the diagnosis highly probable.

Ultrasound has the advantage that there is no radiation nor need for administration of contrast and therefore it may be an ideal tool for imaging follow-up of calvarial lesions.

The differential diagnosis of EG of the skull in children includes a congenital skull defect<sup>(10)</sup>, an epidermoid or dermoid cyst<sup>(3)</sup>, a growing fracture<sup>(8)</sup>, a hemangioma and metastatic neuroblastoma<sup>(4)</sup>.

## Conflict of interest

*The authors do not report any financial or personal connections with other persons or organizations, which might negatively affect the contents of this publication and/or claim authorship rights to this publication.*

7. De Marchi A, del Prever EB, Cavallo F, Pozza S, Linari A, Lombardo P *et al.*: Perfusion pattern and time of vascularisation with CEUS increase accuracy in differentiating between benign and malignant tumours in 216 musculoskeletal soft tissue masses. *Eur J Radiol* 2015; 84: 142–150.
8. Steinbok P: Healing calvarial eosinophilic granuloma or healing skull fracture? *Childs Nerv Syst* 2015; 31: 1175–1176.
9. Haupt R, Minkov M, Astigarraga I, Schäfer E, Nanduri V, Jubran R *et al.*: Langerhans cell histiocytosis (LCH): Guidelines for diagnosis, clinical work-up, and treatment for patients till the age of 18 years. *Pediatr Blood Cancer* 2013; 60: 175–184.
10. Dharwal K: Foramina parietalia permagna: The ins and outs. *Folia Morphol (Warsz)* 2012; 71: 78–81.