

Received: 2019.03.19
Accepted: 2019.04.27
Published: 2019.06.29

Unusual Changing Calcification Patterns on the Mammogram in a Pure Mucocele-Like Lesion of the Breast: A Case Report

Authors' Contribution:
Study Design A
Data Collection B
Statistical Analysis C
Data Interpretation D
Manuscript Preparation E
Literature Search F
Funds Collection G

ABDEF 1 **Suk Jung Kim**
BD 2 **Ji Yeon Kim**

1 Department of Radiology, Haeundae Paik Hospital, Inje University College of Medicine, Busan, South Korea
2 Department of Pathology, Haeundae Paik Hospital, Inje University College of Medicine, Busan, South Korea

Corresponding Author: Suk Jung Kim, e-mail: pure0815@hanmail.net
Conflict of interest: None declared

Patient: Female, 39
Final Diagnosis: Mucocele-like lesion
Symptoms: None
Medication: —
Clinical Procedure: —
Specialty: Radiology





Objective: Rare disease
Background: Mucocele-like lesions are rare breast lesions composed of mucin filled cysts and extravasated mucin that frequently undergo calcification. The most common radiologic feature of a mucocele-like lesion is mammographic microcalcifications of indeterminate nature. The present report demonstrated unusual fluctuation of calcification number and a changing pattern of calcification morphology on mammography in a benign mucocele-like lesion.

Case Report: A 39-year-old female was referred to our breast clinic because of a screening mammography-detected abnormality in her right breast. The magnification mammogram of her right breast revealed approximately 8 cm of multiple adjacent masses accompanying regional coarse heterogeneous microcalcifications in the inner central area, which corresponded to multiple aggregated cystic lesions on sonography. Each cystic lesion had internal echoes of a complex cystic with solid and septated pattern. Although a biopsy was recommended, the patient refused the tissue diagnosis. During the first 12 months, the overall extent of mass and calcifications did not discernably change on magnification mammograms. However, minute focal changes in the calcification number were detected; single coarse calcification disappeared at 6-month follow-up, and new coarse calcification developed at 12-month follow-up. At 24-month follow-up magnification mammogram, coarse calcification overtly increased in number and size, and changed into a large bizarre dystrophic morphology. A pathologic diagnosis of a benign mucocele-like lesion without upgrade to atypia or malignancy was made using ultrasonography-guided vacuum-assisted biopsy and surgical excision.

Conclusions: When calcifications accompany cystic masses and chronologically change their morphologic pattern from indeterminate (coarse heterogeneous) to benign (dystrophic), a diagnosis of mucocele-like lesion should be considered.

MeSH Keywords: Breast • Mammography • Mucocele • Ultrasonography, Mammary

Full-text PDF: <https://www.amjcaserep.com/abstract/index/idArt/916335>

 1863   3  26



Background

The mucocele-like lesion is a rare breast lesion that is pathologically defined as a mucin-filled cyst with extravasation of mucin into the surrounding stroma [1,2]. Cysts frequently contain microscopic calcifications [1]. Reflecting such pathologic characteristics, the radiologic features of mucocele-like lesion of the breast are mainly coarse heterogeneous microcalcifications on mammography and various cystic lesions on sonography [3,4]. Despite its rarity, increased detection, likely due to a large volume of breast cancer screenings, sometimes poses diagnostic challenges for radiologists. This report described a case of pure mucocele-like lesion that demonstrated a dramatic pattern of changing calcification from indeterminate (coarse heterogeneous) to benign (large bizarre dystrophic) morphology and fluctuating calcification number during a 2-year follow-up period. Specific mammographic presentation of dystrophic calcification has been reported in a previous case of mucocele-like lesion [5]. Furthermore, changes in the calcification morphology and fluctuations in number over a 2-year follow-up period have not been previously reported in mucocele-like lesion cases. Herein, the clinical, mammographic, gray-scale, and color-Doppler sonographic features of this case are presented.

Case Report

A 39-year-old female was referred to our breast clinic due to screening-detected abnormalities in her right breast on mammography. This was her first screening mammography. She did not complain of any breast symptoms and had no relevant medical history, except a surgical history of an atrial septal defect at 9 years of age. Physical examination did not reveal any discernable abnormalities. She had no family history of breast cancer.

The magnification mammogram of her right breast demonstrated multiple aggregated irregular or oval masses, and focal asymmetries with regional coarse heterogeneous calcifications in the inner central area (Figures 1A, 1B, 2A, 2E). Successive ultrasonography showed multiple aggregated cystic lesions corresponding to mammographic abnormalities (Figure 1C–1E). The individual cysts had multiple septa, and complex cystic and solid echoes. Based on an indeterminate morphology of microcalcifications and the complex cystic and solid echo patterns of the cysts, the radiological assessment was Breast Imaging Reporting and Data System (BI-RADS) 4; therefore, a biopsy was recommended. However, the patient refused the tissue diagnosis and preferred an imaging follow-up. Follow-up magnification mammography and sonography were performed at intervals of 6, 12, and 24 months from the initial image acquisition. There were no significant changes in the imaging features on mammography (Figure 2B, 2C, 2F, 2G) or

on sonography, up to 12 months follow-up (not presented). However, at 24 months follow-up, the magnification mammography showed a dramatic change in calcification morphology from a previous coarse heterogeneous pattern into a large bizarre dystrophic calcification, and an increase in calcification number and size (Figure 2D, 2H). Under the sonography guidance, an 8G-vacuum assisted needle biopsy was performed on the mass. Microscopically, the biopsied specimen showed multiple dystrophic calcifications within extravasated mucin and cysts (Figure 3A–3C), which were consistent with a diagnosis of an mucocele-like lesion. The mass was further excised surgically to remove it completely. Final diagnosis did not change, with no upgrade to atypia or malignancy.

Discussion

This was an unusual case of a pure mucocele-like lesion of the breast. On mammography examinations, calcification number fluctuated and eventually increased, and the morphology changed from the initial coarse heterogeneous pattern into the later typically benign dystrophic pattern over a 2-year period. Although the calcification morphologically changed to the benign pattern reported, tissue diagnosis could not be obviated because of the accompanying masses observed on the mammogram and the complex cystic lesions observed on the sonogram.

In 1986, Rosen first introduced the diagnosis of mucocele-like lesion of the breast, which exhibited pathologically mucin filled cysts with extravasated mucin in the adjacent stroma [6]. Rosen initially recognized this lesion as entirely benign [6]; however, successive studies further documented that the biology of mucocele-like lesion is determined by the epithelium lining, which includes benign proliferative and non-proliferative changes, atypical ductal hyperplasia, and *in situ* or invasive carcinoma [1,7–9]. Microscopically, the cysts are lined by flat to cuboidal epithelium in benign mucocele-like lesion; whereas, the epithelium may exhibit proliferative changes ranging from usual ductal hyperplasia to atypical ductal hyperplasia, and neoplastic proliferations *in situ* or invasive carcinoma [1]. The later introduced the term, mucocele-like tumor, which is synonymous with the initial term, mucocele-like lesion [4]. The exact pathogenesis of mucocele-like lesion had not yet been revealed; however, Rosen hypothesized that excess production of mucin or a ductal obstruction may contribute to the distension of a duct or cyst, and incidental trauma from daily activity may cause a rupture and extravasation of mucin [6].

The incidence of mucocele-like lesion has been reported to be between 0.24% to 0.6% of the breast screening population who undergo core biopsy [2,10,11], which is relatively rare when compared with other high-risk lesions in the breast [2].

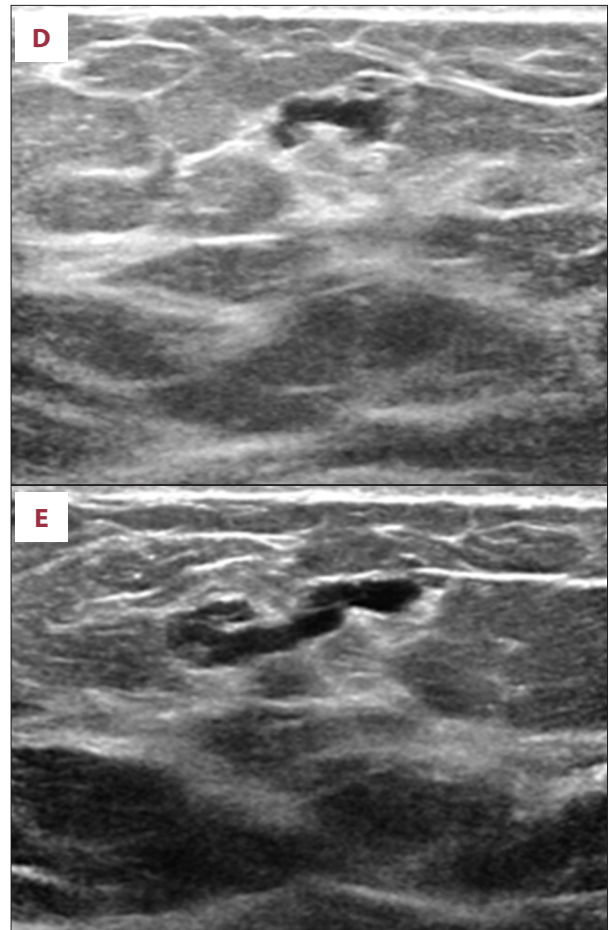
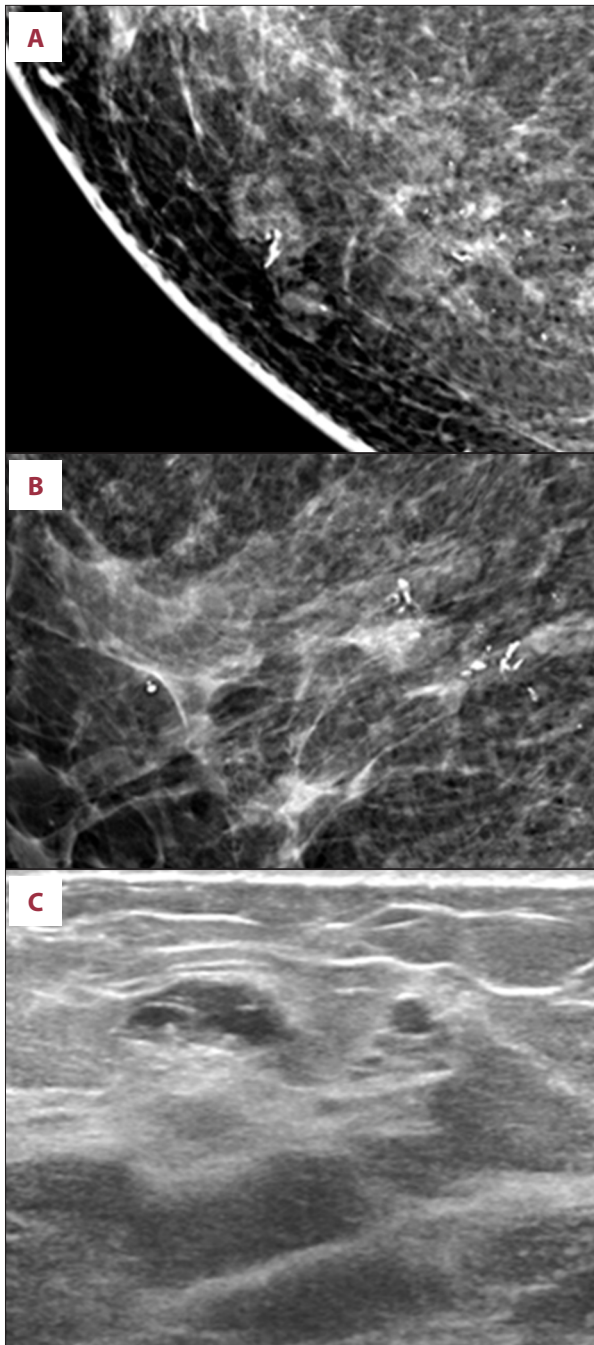


Figure 1. The craniocaudal (A), mediolateral (B) magnification mammograms of the right breast show multiple aggregated irregular or oval masses, and focal asymmetries accompanying regional coarse heterogeneous calcifications, which extend approximately 8 cm in the inner central area (arrows). Transverse (C, D) and radial (E) grayscale sonograms scanned in the corresponding area of the right breast show multiple aggregated cystic lesions. The cysts have multiple septa, and complex cystic and solid internal echoes (C-E). On a radial scan, the cysts tend to be connected like a ductal structure (E).

Therefore, despite current international efforts to determine a consensus for the management of an uncertain malignant potential in the breast [12], there is no consensus for the diagnosis of mucocele-like lesion by core needle biopsy [2]. The small case numbers and varying definition of upgrade (including atypical ductal hyperplasia) of each case series means that reported upgrade rates upon surgical excision have varied as widely as 0–43% [1]. Based on a literature review in 2016, Gibreel et al. summarized the overall rate of malignant upgrade to *in situ* or invasive carcinoma as 17.3% (8% and 9.3% for invasive and

in situ disease, respectively) for 75 mucocele-like lesions with atypia, and 2.9% (1.5% and 1.5% to invasive and *in situ* disease, respectively) for 204 mucocele-like lesions without atypia [13]. In 2017, a large series of 113 women with mucocele-like lesion identified on core biopsy reported a 5% upgrade rate to malignancy, with no upgrade to invasive carcinoma, which was comparable to papillary lesion upgrade rates [2]. Surgical excision is recommended for atypical mucocele-like lesions diagnosed on needle biopsy [1,2]. However, some investigators have advocated close clinical or imaging surveillance, or vacuum-assisted biopsy for pure mucocele-like lesions as a reasonable alternative to surgical excision [14–16].

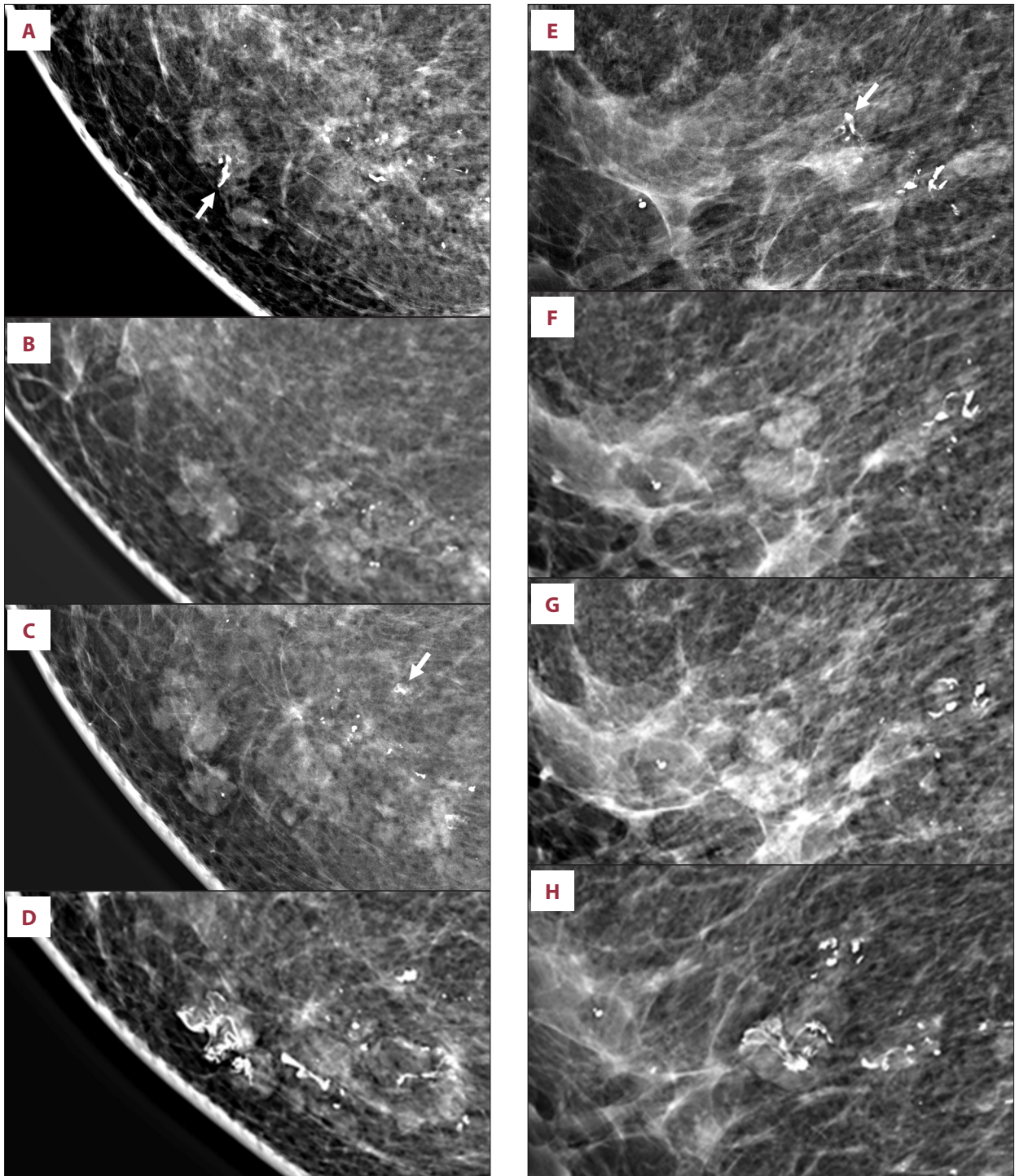


Figure 2. The sequential craniocaudal (A–D) and mediolateral (E–H) magnification mammograms of the right breast taken initially (A, E) and at follow-up intervals of 6 months (B, F), 12 months (C, G), and 24 months (D, H) shows chronological changes in the number and shape of calcifications. On the 6-month magnification mammogram (B, F), a large coarse calcification that was seen on initial magnification mammogram (arrows in A, E) had disappeared focally. On the 12-month magnification mammogram (C, G), a coarse calcification newly appeared focally (arrow in C). On the 24-month magnification mammogram (D, H), the number and size of calcifications overtly increased, and the morphology of calcifications changed into a large bizarre dystrophic calcification.

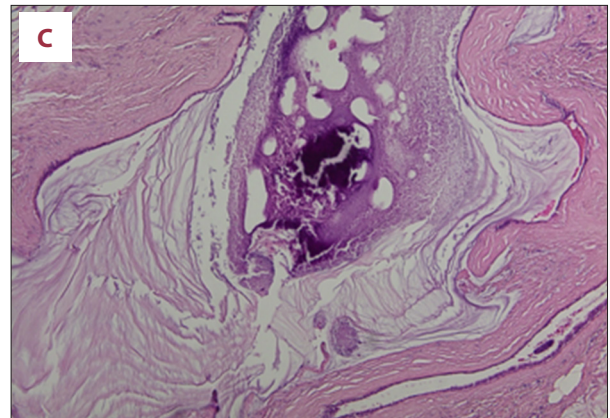
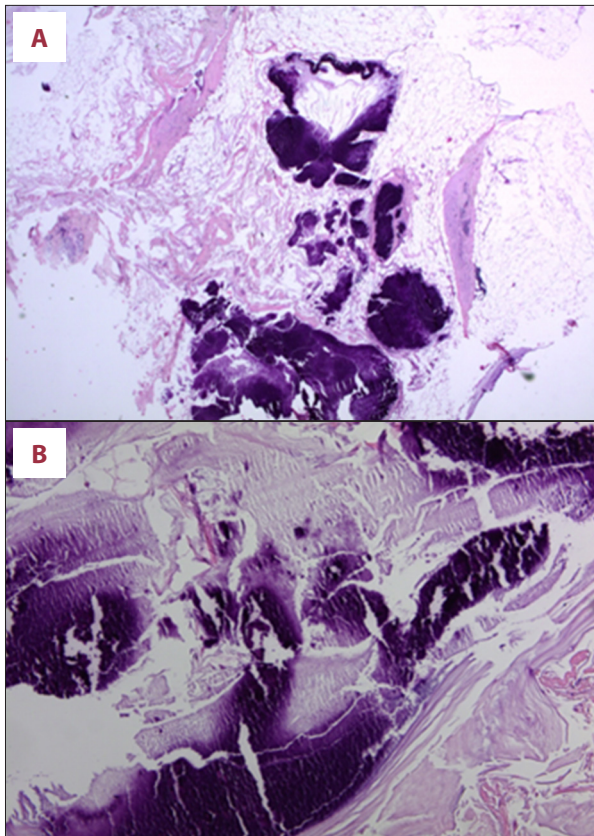


Figure 3. (A) The low power microscopic view shows clumped and variably sized basophilic materials in the fatty stroma (hematoxylin and eosin stain, 20×). (B) At higher magnification, the calcium salts are admixed with excessive mucin and reveal amorphous granular appearance (hematoxylin and eosin stain, 100×). (C) Focally, calcified mucinous secretion is present within a cystically dilated duct lined by flat epithelium (hematoxylin and eosin stain, 100×).

When cysts rupture, mucus content collects as pools within the stroma [1]. Microscopically, the presence of large, coarse microcalcification within the cysts and in the extravasated mucous secretion is characteristic [8]. Extravasated mucin develops into dystrophic calcification, which enables mammographic detection of mucocele-like lesions [5,17]. Conversely, the presence of calcification on mammogram infers the presence of a mucin pool [4]. Radiologically, the most common reported features of mucocele-like lesions were microcalcifications on mammography [2,3,18]. In the literature, the calcification morphology of mucocele-like lesion on mammogram is predominantly described as coarse [4,5,18–21] or pleomorphic [18,22], which largely fits the range of coarse heterogeneous calcifications of indeterminate concern in the BI-RADS classification [4,5]. The morphologic features of calcifications in are infrequently reported as round [16,18], punctate [16,18,22], amorphous [16], lucent-centered [22], crescentic (tea-cup) [17], and fine pleomorphic [16,18]. The distribution of calcification in mucocele-like lesions on mammogram is predominantly described as grouped [2,5,16,18,22] and less commonly as regional [5], diffuse [2,16,22], linear [11,18], or segmental [3,22]. Previously, shape, number, and distribution of calcifications have been hard to differentiate between benign and malignant [18,20–24]; however, a recent large case series of 72 patients with mucocele-like lesions found that calcifications of indeterminate concern or a higher probability of malignancy, and calcifications

of clustered or segmental distribution, were more frequently presented with atypical ductal hyperplasia or malignancy than pure mucocele-like lesions [3]. In addition, in 25 patients with mucocele-like lesions, calcifications extended to a greater area on mammogram in malignant mucocele-like lesions than benign mucocele-like lesions [22]. Further, in 21 patients with pure mucocele-like lesions, the majority (70%) showed a clustered distribution [16]. Microscopically, calcifications are more frequently found in malignant mucocele-like lesions (71%) than benign mucocele-like lesions (46%) [8], which might imply that mammography is more likely to reveal malignant mucocele-like lesions [23]. In the current case, although initially the calcification manifested as an indeterminate shape (coarse heterogeneous) and involved a large area (approximately 8 cm in size), the calcifications eventually changed to an overtly benign morphology, despite the increasing number of calcification. Finally, a diagnosis of a benign mucocele-like-lesion without upgrade to atypia or malignancy was made.

The pattern of benign dystrophic calcification as a mammographic feature of mucocele-like lesions has been reported in only 1 case, in which a single large dystrophic calcification was contained centrally within circumscribed, oval, isodense mass on mammogram, corresponding to a complex cystic and solid mass on sonogram [5]. In another study, a different benign morphologic pattern of calcification was described as large coarse eggshell-shaped calcifications accompanying pleomorphic calcifications [22]. Furthermore, this case described a characteristic distribution of multiple calcific clusters connected like a rosary [22]. The differences in size of calcifications on sonogram has been reported previously; macrocalcifications were

present in 29.2% of pure mucocele-like lesions, 16.7% of mucocele-like lesions with atypical ductal hyperplasia, and 4.2% of mucocele-like lesions with malignancy [3].

Changing patterns of microcalcifications relating to the number or extent in mucocele-like lesions on mammogram have been described [22,25]. Glazebrook et al. reported the development of new calcifications accompanied by increasing size of the nodule over 24-months follow-up in benign mucocele-like lesion [23]. Kim et al. reported interval increases in the numbers of calcifications in 5 cases of benign mucocele-like lesions [22]. In addition, Farshid et al. reported that in 53.8% of cases, microcalcifications were new or had grown since the previous mammogram [25]. In line with this, Carkaci et al. reported that in 63% of cases, calcifications had developed since the patient's most recent mammogram [18]. However, these previous studies did not address the focal disappearance of calcification in mucocele-like lesions on mammogram. Furthermore, changing morphologic calcification patterns have not been reported in mucocele-like lesions; and generally, in breast imaging, changing microcalcification patterns on mammography have been insufficiently discussed. However, one recent study has shown that the appearance or increased extent of microcalcification on screening mammography can more accurately predict breast cancer than shape or changes in the number microcalcifications without extension [26]. In our current case of benign mucocele-like lesion, calcifications increased in terms of number rather than their extent.

References:

1. Harrison BT, Dillon DA: An update of mucinous lesions of the breast. *Surg Pathol Clin*, 2018; 11: 61–90
2. Dash, I, Dessauvagie B, Hardie M et al: Mucocele-like lesions: Is surgical excision still necessary? *Clin Radiol*, 2017; 72: 992.e1–e6
3. Kim SM, Kim HH, Kang DK et al: Mucocele-like tumors of the breast as cystic lesions: sonographic-pathologic correlation. *Am J Roentgenol*, 2011; 196: 1424–30
4. Tanaka A, Imai A, Goto M et al: Which patients require or can skip biopsy for breast clustered microcysts? Predictive findings of breast cancer and mucocele-like tumor. *Breast Cancer*, 2016; 23: 590–96
5. Tsang H, Wai JWC, Chiu JLF, Wong OK: Mucocele-like lesions of the breast: mammographic, sonographic, and pathologic findings and upgrade rate. *Hong Kong J Radiol*, 2016; 19: 279–86
6. Rosen PP: Mucocele-like tumors of the breast. *Am J Surg Pathol*, 1986; 10: 464–69
7. Fisher CJ, Millis RR: A mucocele-like tumour of the breast associated with both atypical ductal hyperplasia and mucoid carcinoma. *Histopathology*, 1992; 21: 69–71
8. Hamele-Bena D, Cranor ML, Rosen PP: Mammary mucocele-like lesions. Benign and malignant. *Am J Surg Pathol*, 1996; 20: 1081–85
9. Weaver MG, Abdul-Karim FW, Al-Kaisi N: Mucinous lesions of the breast. A pathological continuum. *Pathol Res Pract*, 1993; 189: 873–76
10. Diorio C, Provencher L, Morin J et al: Is there an upgrading to malignancy at surgery of mucocele-like lesions diagnosed on percutaneous breast biopsy? *Breast J*, 2016; 22: 173–79
11. Ha D, Dialani V, Mehta TS et al: Mucocele-like lesions in the breast diagnosed with percutaneous biopsy: Is surgical excision necessary? *Am J Roentgenol*, 2015; 204: 204–10
12. Rageth CJ, O'Flynn EAM, Pinker K et al: Second International Consensus Conference on lesions of uncertain malignant potential in the breast (B3 lesions). *Breast Cancer Res Treat Breast Cancer Res Treat*, 2019; 174(2): 279–96
13. Gibreel WO, Boughey JC: Mucocele-like lesions of the breast: Rate of up-staging and cancer development. *Ann Surg Oncol*, 2016; 23: 3838–42
14. Sutton B, Davion S, Feldman M et al: Mucocele-like lesions diagnosed on breast core biopsy: Assessment of upgrade rate and need for surgical excision. *Am J Clin Pathol*, 2012; 138: 783–88
15. Rakha EA, Shaaban AM, Haider SA et al: Outcome of pure mucocele-like lesions diagnosed on breast core biopsy. *Histopathology*, 2013; 62: 894–98
16. Park YJ, Kim EK: A pure mucocele-like lesion of the breast diagnosed on ultrasonography-guided core-needle biopsy: Is imaging follow-up sufficient? *Ultrasonography*, 2015; 34: 133–38
17. Davies J, Kutt E, Kulka J et al: Mucocele-like lesions detected by the mammographic presence of suspicious clustered microcalcifications. *The Breast*, 1996; 5: 135–40
18. Carkaci S, Lane DL, Gilcrease MZ et al: Do all mucocele-like lesions of the breast require surgery? *Clin Imaging*, 2011; 35: 94–101
19. Tanaka K, Komoike Y, Egawa C et al: Indeterminate calcification and clustered cystic lesions are strongly predictive of the presence of mucocele-like tumor of the breast: A report of six cases. *Breast Cancer*, 2009; 16: 77–82
20. Leibman AJ, Staeger CN, Charney DA: Mucocele-like lesions of the breast: Mammographic findings with pathologic correlation. *Am J Roentgenol*, 2006; 186: 1356–60
21. Carder PJ, Murphy CE, Liston JC: Surgical excision is warranted following a core biopsy diagnosis of mucocele-like lesion of the breast. *Histopathology*, 2004; 45: 148–54

Mammographic findings in cases of mucocele-like lesions also can include a mass with microcalcification [11,25], a mass without calcification [5,11,16,25], asymmetry [16], and architectural distortion [25]. On sonography, mucocele-like lesions exhibit as various cystic lesions, which reflects the pathologic characteristics of mucin filled cysts in mucocele-like lesions [3,5,11,16,18,22,23,25]. Cysts show various internal echo patterns, ranging from anechoic, clustered microcystic, complicated, and complex cystic and solid. Mucocele-like lesions with atypia or malignancy tend to present with clustered cysts, cysts with thick septations, or complex masses [3]. Less common sonographic features include solid mass [3,5,11,18,22,25], tubular structure with low-level internal echoes [25], calcification only [22], and slight architectural distortion [25].

Conclusions

In this case report, we described a rare case of mucocele-like lesion exhibiting dramatic changing patterns of calcification morphology, from coarse heterogeneous to large bizarre dystrophic calcifications, and fluctuations in the number of calcification over a 2-year period. In this case, the presence of morphologic changes in calcification into a typical benign dystrophic pattern did not preclude the possibility of an indeterminate breast lesion. Awareness of this unusual pattern might aid in the provision of a differential diagnosis when faced with cystic breast lesion accompanying calcifications.

22. Kim JY, Han BK, Choe YH, Ko YH: Benign and malignant mucocele-like tumors of the breast: mammographic and sonographic appearances. *Am J Roentgenol*, 2005; 185: 1310–16
23. Glazebrook K, Reynolds C: Mucocele-like tumors of the breast: Mammographic and sonographic appearances. *Am J Roentgenol*, 2003; 180: 949–54
24. Ramsaroop R, Greenberg D, Tracey N, Benson-Cooper D: Mucocele-like lesions of the breast: An audit of 2 years at BreastScreen Auckland (New Zealand). *Breast J*, 2005; 11: 321–25
25. Farshid G, Pieterse S, King JM, Robinson J: Mucocele-like lesions of the breast: A benign cause for indeterminate or suspicious mammographic microcalcifications. *Breast J*, 2005; 11: 15–22
26. Kim KI, Lee KH, Kim TR et al: Changing patterns of microcalcification on screening mammography for prediction of breast cancer. *Breast Cancer*, 2016; 23: 471–78