



## Case Report

# Surgical management of simultaneous supra- and infratentorial hemorrhages in a pediatric patient with multiple cavernomas

Gaurav Tyagi, Abhay Sikaria, Gyani Jail Singh Birua, Manish Beniwal,  
Dwarakanath Srinivas

*Department of Neurosurgery, National Institute of Mental Health and Neurosciences (NIMHANS), Bengaluru, India*

**J Cerebrovasc Endovasc Neurosurg.**  
**2022 September;24(3):263-266**

Received: 2 August 2021

Revised: 5 October 2021

Accepted: 27 October 2021

### Correspondence to

**Gaurav Tyagi**

Department of Neurosurgery, National  
Institute of Mental Health and Neurosciences  
(NIMHANS), Hosur Road, Bengaluru,  
Karnataka, India

Tel +91-80-26995403

E-mail [gauravyagi6886@gmail.com](mailto:gauravyagi6886@gmail.com)

ORCID <http://orcid.org/0000-0002-3189-2641>

Multiple intracranial cavernomas are rare and occur mostly in familial cases. Clinical presentation with simultaneous rupture of two or more lesions has only been reported in four cases to date. A 15-year-old boy presented with simultaneous right frontal and superior vermian hematomas with hydrocephalus. The patient underwent a ventriculo-peritoneal shunt, and his magnetic resonance imaging (MRI) revealed multiple cavernomas with bleed in the above-mentioned locations. The patient underwent a midline suboccipital craniotomy and excision of the cavernoma. The supratentorial lesions were left in situ in lieu of small size, no history of seizures, mass effect, or other neurological deficits. The patient recovered well from surgery with significant improvement in truncal ataxia. He remained asymptomatic for supratentorial lesions at follow-up. Cavernomas should be considered as differential diagnoses in cases of multiple intraparenchymal hemorrhages, especially in pediatric patients. The surgical management should be rationalized based on the lesion location, the eloquence of the surrounding parenchyma, mass effect, and the risks of re-rupture. Due to the rarity of multiple simultaneous hemorrhages, the management of multiple cavernomas remains controversial. The patient's relatives can be screened with MRI to rule out the familial form of the disease. Strict clinical and radiological follow-up is a must in such patients.

**Keywords** Cavernoma, Intracerebral hemorrhage, Intracranial cavernous malformations, Multiple cavernomas, Stroke in young

## INTRODUCTION

Multiple intracranial cavernomas represent up to 20% of all cavernoma cases. They are more likely to occur as a familial disease.<sup>4)7)9)</sup> Overall, the common presenting symptoms are seizures, episodic progressive neurological deficits (especially in infratentorial lesions), and rarely headache.<sup>9)</sup> Up to one-third of all cavernoma cases present with hemorrhage.<sup>4)9)</sup>

In a systematic pooled analysis, Gross et al., found the annual risk of cavernoma

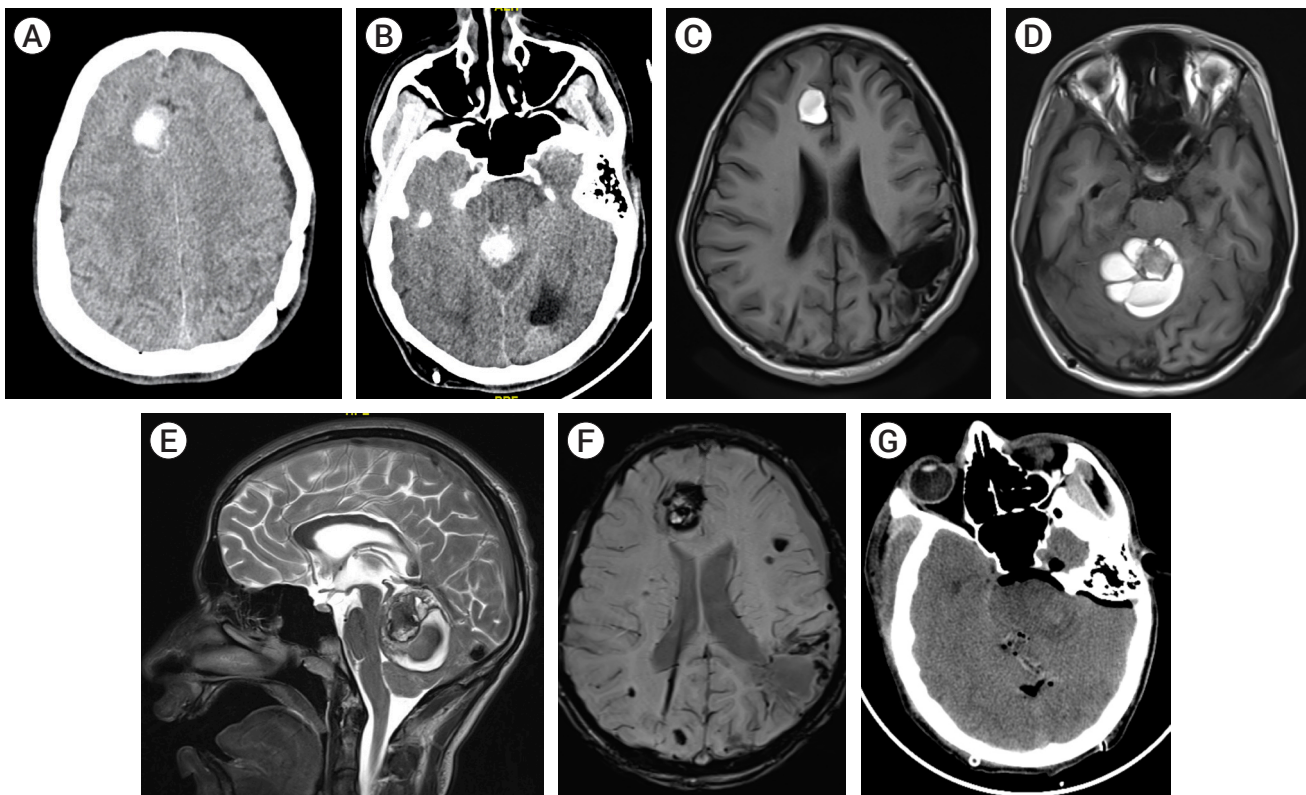
This is an Open Access article distributed under the terms of the Creative Commons Attribution Non-Commercial License (<http://creativecommons.org/licenses/by-nc/4.0/>) which permits unrestricted non-commercial use, distribution, and reproduction in any medium, provided the original work is properly cited.

hemorrhage to be 2.4% per patient-year (range 1.6-3.1%).<sup>9)</sup> The annual hemorrhage rate in the pediatric population can be higher (3.3%), especially in cases with prior history of hemorrhage (11.3%).<sup>8)</sup> The predisposing risks factors for bleed are age, female sex, prior hemorrhage, familial disease, multiple cavernomas, associated venous anomaly, and residual lesion after surgery.<sup>4)8)12)13)</sup>

Simultaneous occurrence of multiple parenchymal hemorrhages in separate arterial territories is a rare clinical event that can occur due to cerebral amyloid angiopathy, venous sinus thrombosis, coagulopathy, vasculitis, hemorrhagic transformation of cerebral infarcts, and multiple intracranial tumors.<sup>5)</sup> Presentation of sporadic multiple cavernomas with simultaneous rupture is even rarer.<sup>2)4)5)10)11)</sup> In this report we present the first reported case of pediatric sporadic multiple cavernomas with simultaneous hemorrhages and its surgical management.

CASE REPORT

A 15-year-old boy presented to the emergency department with a progressive headache for one month. For the past seven days, he started having recurrent episodes of vomit and imbalance while walking. On examination, he was drowsy, arousable, had bilateral papilledema with gross appendicular and axial ataxia. He had prior surgery for traumatic brain hemorrhage (left parietal) 10 years back, the details of which were not available. There was no history of brain hemorrhage or cranial surgery in the family. Computed tomography (CT) brain done in the emergency room (ER) showed hemorrhagic lesions in the right frontal lobe and the vermis with hydrocephalus (Fig. 1A, B). Written informed consent was taken for surgery and the patient underwent a ventriculoperitoneal (VP) shunt, following which his sensorium



**Fig. 1.** (A, B) Plain CT images of the patient showing hemorrhagic lesion in right frontal (cingulate gyrus) and superior vermis region causing obliteration of the aqueduct. (C, D) Axial T1WI showing mixed hyperintensities suggesting bleed with varying timeline with central hypodense multilobulated cavernoma seen in the vermis lesion. In C, we can also see the gliotic changes of previous surgery on left parietal lobe. (E) Sagittal T2WI showing superiorly located cavernoma within the hematoma, with surrounding venous anomaly. The hematoma is causing mass effect on upper brainstem and 4<sup>th</sup> ventricle. (F) Multiple supratentorial cavernomas (black lesions) on susceptibility image. Right ventriculoperitoneal shunt is also seen in situ. (G) Post-op CT following excision of cerebellar lesion. CT, computed tomography

improved. His magnetic resonance imaging (MRI) brain revealed a multiloculated non-enhancing superior vermian lesion, 4.5×4.6×4 cm in size, predominantly T1WI hyperintense with a mixed-signal on T2WI and blooming seen on susceptibility weighted imaging (SWI) (Fig. 1C-F). Perilesional edema was seen with mass effect on the fourth ventricle and brain stem (Fig. 1E). Similar lesions with bleed were seen in the right cingulate gyrus, left superior occipital gyrus, and left peritrigonal white matter. Multiple microbleeds were noted in both cerebral hemispheres, bilateral thalami, left anterior limb of the internal capsule, left cerebral peduncle, and bilateral cerebellar hemispheres (Fig. 1F). There were no vascular malformations on MR angiography. Gliosis with cystic encephalomalacia changes was noted in the left parietal lobe (previous surgery).

The patient underwent midline suboccipital craniotomy, right supra-cerebellar approach, and resection of the cavernoma with the evacuation of the hematoma (Fig. 1G). Lesion histopathology revealed a nidus of vascular malformation composed of dilated cavernous blood vessels of varying calibre. The surrounding cerebellar parenchyma shows piloid gliosis with few Rosenthal fibres. The patient recovered well from surgery and had improvement in ataxia. At 12 weeks follow-up, he was walking without support with minimal residual ataxia. He remained asymptomatic for the supratentorial lesions.

## DISCUSSION

Hemorrhage from cavernomas usually occurs due to a ruptured peripheral cavern. This extra-lesional bleed is seldom as devastating as hemorrhages from a high-flow, high-pressure arteriovenous malformation, and tends to resolve spontaneously.<sup>4)</sup> Thus, surgical intervention for hemorrhage in non-eloquent regions, especially in the presence of multiple cavernomas should be weighed against the surgical risks involved. Since our patient had one supratentorial lesion with hematoma, no history of seizures, multiple other lesions with micro-bleeds,

and no clinical or radiological features of mass effect, surgery was considered only for the cerebellar lesion. The remaining lesions would be managed with clinical and radiological follow-up.

Incidentally detected cavernomas do not warrant any treatment and can be followed radiologically.<sup>3)</sup> Since, the overall risk of hemorrhage remains small, the management of cavernomas should be restricted to symptomatic lesions only.<sup>4)</sup> Repeat hemorrhage is more likely to occur in deep lesions, e.g., those in the brainstem, deep cerebellar nuclei, thalamus, and basal ganglia. These are the lesions that require surgical resection.<sup>4)7)</sup>

Surgery provides excellent results in pediatric cavernomas.<sup>1)</sup> The surgical approach should be through the point where the lesion is closest to the pial surface. In our case, the hematoma was surfacing towards the superior cerebellar surface, so we chose a right superior cerebellar corticectomy. The excision of a ruptured cavernoma should be preferably performed in the subacute stage of hematoma. The hematoma is soft, suckable and the lesion appears as a “lotus in the pond” with a clear plane with the surrounding parenchyma.<sup>4)</sup> The cavernoma should be resected completely as the residual lesion is a risk factor for re-rupture.<sup>3)</sup>

The evidence on seizure control following surgical resection is controversial,<sup>4)6)14)</sup> especially in the presence of multiple lesions.<sup>3)</sup> The perilesional hemosiderin-laden parenchyma is the cause of seizures in most cases.<sup>6)</sup> On the other hand, more than 90% of patients with infratentorial cavernomas have neurological improvement.<sup>14)</sup>

To date, only four cases of multiple simultaneous hemorrhages in cavernomas have been reported in the literature.<sup>4)5)10)11)</sup> The cause of simultaneous bleeds can be multifactorial with external influences (chronic hypertension, etc.) also affecting the natural history.<sup>10)</sup> Ours is the first report of such an event in a pediatric patient with no known hypertension or similar family history. Due to its rarity, the surgical approach for simultaneous bleeds in multiple cavernomas remains controversial; with authors suggesting an aggressive approach for all lesions to operating only the symptomatic one.<sup>4)11)</sup> Although, the current patient was a sporadic case of

multiple cavernomas, we counseled the family members regarding the possibility of a similar disease in siblings.<sup>11)</sup>

## CONCLUSIONS

Cavernomas should be considered an important differential diagnosis in cases of multiple intraparenchymal hemorrhages, especially in pediatric patients. The surgical management should be rationalized based on the lesion location, mass effect, eloquence of the surrounding parenchyma, and risks of re-rupture. The patient's family can be screened to rule out a familial form of the disease. Strict clinical and radiological follow-up is a must in such patients.

## Disclosure

The authors report no conflict of interest concerning the materials or methods used in this study or the findings specified in this paper.

## REFERENCES

1. Acciarri N, Galassi E, Giulioni M, Pozzati E, Grasso V, Palandri G, et al. Cavernous malformations of the central nervous system in the pediatric age group. *Pediatr Neurosurg*. 2009;45(2):81-104.
2. Awad IA. Commentary. *Surg Neurol*. 2002 May;57(5):344-5.
3. Awad IA, Polster SP. Cavernous angiomas: deconstructing a neurosurgical disease. *J Neurosurg*. 2019 Jul;131(1):1-13.
4. Chanda A, Nanda A. Multiple cavernomas of brain presenting with simultaneous hemorrhage in two lesions: A case report. *Surg Neurol*. 2002 May;57(5):340-4.
5. El Asri AC, Derraz S, Gazzaz M, Mostarchid BE. Simultaneous bleeding of supratentorial and infratentorial cavernomas. *Headache*. 2015 May;55(5):680-1.
6. Gogoleva SM, Ryvlin P, Sindou M, Fischer G, Jouvet A, Saint Pierre G, et al. Brain glucose metabolism with [<sup>18</sup>F]-Fluorodeoxyglucose and positron emission tomography before and after surgical resection of epileptogenic cavernous angiomas. *Stereotact Funct Neurosurg*. 1997;69(1-4 Pt 2):225-8.
7. Gross BA, Du R. Hemorrhage from cerebral cavernous malformations: A systematic pooled analysis. *J Neurosurg*. 2017 Apr;126(4):1079-87.
8. Gross BA, Du R, Orbach DB, Scott RM, Smith ER. The natural history of cerebral cavernous malformations in children. *J Neurosurg Pediatr*. 2016 Feb;17(2):123-8.
9. Gross BA, Lin N, Du R, Day AL. The natural history of intracranial cavernous malformations. *Neurosurg Focus*. 2011 Jun;30(6):E24.
10. Louis N, Marsh R. Simultaneous and sequential hemorrhage of multiple cerebral cavernous malformations: A case report. *J Med Case Reports*. 2016 Feb;10(1):36.
11. Panciani PP, Agnoletti A, Fornaro R, Fontanella M, Ducati A. Multiple cavernomas of the brain: Simultaneous hemorrhage of two lesions in a non-familial form. *Turk Neurosurg*. 2011;22(6):671-4.
12. Porter PJ, Willinsky RA, Harper W, Wallace MC. Cerebral cavernous malformations: Natural history and prognosis after clinical deterioration with or without hemorrhage. *J Neurosurg*. 1997 Aug;87(2):190-7.
13. Pozzati E, Acciarri N, Tognetti F, Marliani F, Giangaspero F. Growth, subsequent bleeding, and de novo appearance of cerebral cavernous angiomas. *Neurosurgery*. 1996 Apr;38(4):662-9; discussion 669-70.
14. Sawarkar DP, Janmatti S, Kumar R, Singh PK, Gurjar HK, Kale SS, et al. Cavernous malformations of central nervous system in pediatric patients: Our single-centered experience in 50 patients and review of literature. *Childs Nerv Syst*. 2017 Sep;33(9):1525-38.