



Since January 2020 Elsevier has created a COVID-19 resource centre with free information in English and Mandarin on the novel coronavirus COVID-19. The COVID-19 resource centre is hosted on Elsevier Connect, the company's public news and information website.

Elsevier hereby grants permission to make all its COVID-19-related research that is available on the COVID-19 resource centre - including this research content - immediately available in PubMed Central and other publicly funded repositories, such as the WHO COVID database with rights for unrestricted research re-use and analyses in any form or by any means with acknowledgement of the original source. These permissions are granted for free by Elsevier for as long as the COVID-19 resource centre remains active.



Contents lists available at ScienceDirect

Journal of Cardiothoracic and Vascular Anesthesia

journal homepage: [www.jcvaonline.com](http://www.jcvaonline.com)

Review Article

## Lung, Heart, Vascular, and Diaphragm Ultrasound Examination of COVID-19 Patients: A Comprehensive Approach

Fabio Guarracino, MD<sup>\*</sup>, Luigi Vetrugno, MD<sup>†,‡,1</sup>,  
 Francesco Forfori, MD<sup>\*,§</sup>, Francesco Corradi, MD, PhD<sup>\*,§</sup>,  
 Daniele Orso, MD<sup>†,‡</sup>, Pietro Bertini, MD, PhD<sup>\*</sup>,  
 Alessandro Ortalda, MD<sup>||</sup>, Nicola Federici, MD<sup>†,‡</sup>,  
 Roberto Copetti, MD<sup>¶</sup>, Tiziana Bove, MD<sup>†,‡</sup>

<sup>\*</sup>Department of Anesthesia and Critical Care Medicine, Azienda Ospedaliero Universitaria Pisana, Pisa, Italy

<sup>†</sup>Department of Medicine, Anesthesia and Intensive Care Clinic, University of Udine, Udine, Italy

<sup>‡</sup>Department of Anesthesia and Intensive care, University-Hospital of Udine, Italy, Udine, Italy

<sup>§</sup>Department of Surgical, Medical and Molecular Pathology and Critical Care Medicine, University of Pisa, Pisa, Italy

<sup>||</sup>Department of Anesthesia and Intensive Care, IRCCS San Raffaele Scientific Institute, Milan, Italy

<sup>¶</sup>Emergency Department, Azienda Sanitaria Universitaria Friuli Centrale, Latisana General Hospital, Latisana, Italy

Lung ultrasound (LU) has a multitude of features and capacities that make it a useful medical tool to assist physicians contending with the pandemic spread of novel coronavirus disease-2019 (COVID-19) caused by coronavirus severe acute respiratory syndrome coronavirus 2 (SARS-CoV-2). Thus, an LU approach to patients with suspected COVID-19 is being implemented worldwide. In noncritical COVID-19 patients, 2 new LU signs have been described and proposed, the “waterfall” and the “light beam” signs. Both signs have been hypothesized to increase the diagnostic accuracy of LU for COVID-19 interstitial pneumonia. In critically ill patients, a distinct pattern of LU changes seems to follow the disease’s progression, and this information can be used to guide decisions about when a patient needs to be ventilated, as occurs in other disease states similar to COVID-19. Furthermore, a new algorithm has been published, which enables the automatic detection of B-lines as well as quantification of the percentage of the pleural line associated with lung disease. In COVID-19 patients, a direct involvement of cardiac function has been demonstrated, and ventilator-induced diaphragm dysfunction might be present due to the prolonged mechanical ventilation often involved, as reported for similar diseases. For this reason, cardiac and diaphragm ultrasound evaluation are highly important. Last but not least, due to the thrombotic tendency of COVID-19 patients, particular attention also should be paid to vascular ultrasound. This review is primarily devoted to the study of LU in COVID-19 patients. The authors explain the significance of its “light and shadows,” bearing in mind the context in which LU is being used—the emergency department and the intensive care setting. The use of cardiac, vascular, and diaphragm ultrasound is also discussed, as a comprehensive approach to patient care.

© 2020 Elsevier Inc. All rights reserved.

**Key Words:** lung ultrasound; cardiac ultrasound, diaphragm ultrasound, COVID-19

F. Guarracino, L. Vetrugno, T. Bove, R. Copetti, and F. Forfori contributed to the concept, design, and drafting the manuscript. F. Corradi, P. Bertini, D. Orso, A. Ortalda, and N. Federici performed critical revision of the manuscript for important intellectual content. All authors read and approved the final manuscript.

<sup>1</sup>Corresponding author. Luigi Vetrugno, MD, Department of Medicine, University of Udine, Italy, Anesthesia and Intensive Care Clinic, Via Colugna n° 50, 33100 Udine, Italy.

E-mail address: [luigi.vetrugno@uniud.it](mailto:luigi.vetrugno@uniud.it) (L. Vetrugno).

FROM THE Wuhan district in China—where the first cases of novel coronavirus disease-2019 (COVID-19) were isolated in early January 2020—the coronavirus called “severe acute respiratory syndrome coronavirus 2 (SARS-CoV-2)” quickly spread to many other countries around the world.<sup>1</sup> The organ most affected by COVID-19 is the lung, where the virus enters

the host's cells via the plasma membrane receptor protein angiotensin-converting enzyme 2, expressed most abundantly in the alveolar type II cells of the lungs.<sup>2</sup> Although SARS-CoV-2 also affects other body systems,<sup>3</sup> the pulmonary involvement of COVID-19 is of particular concern, because the leading cause of COVID-19-related death is severe acute respiratory failure.<sup>4</sup> The proper examination of a COVID-19 patient's entire respiratory system is therefore of utmost importance. Direct cardiac involvement also has been demonstrated, and diaphragm dysfunction is possible, as in other diseases similar to COVID-19.<sup>5,6</sup> The characteristics of COVID-19 patients, who as a result of their pathology must be isolated and whose transfers must be limited, make ultrasound a useful tool for the bedside management of these patients.<sup>7</sup> In fact, in the early phase of the disease, lung ultrasound (LU) seems to show similar findings compared with computed tomography (CT), and its data are superior compared with that obtained by chest x-ray.<sup>8</sup> The ultrasound machine is also easy to clean—an essential characteristic during a pandemic. In marked contrast, the use of chest x-rays and CT scans may increase the risk of contamination and infection spread.<sup>9</sup> Notwithstanding, LU sonographers are divided into 2 groups: those who believe in a specific LU pattern of COVID-19 interstitial pneumonia and those who reject this hypothesis.<sup>10-11</sup>

This review is primarily devoted to the study of LU in COVID-19 patients. The authors explain the significance of its “light and shadows,” bearing in mind the context in which LU is being used—the emergency department and the intensive care setting. The use of cardiac, vascular and diaphragm ultrasound also is discussed in the context of a comprehensive approach to patient care.

## LU “Signs” in Covid-19 Patients

In the present context of the COVID-19 pandemic, Huang Y et al<sup>12</sup> and Volpicelli et al<sup>13</sup> described 2 new B-line signs using LU. In patients with respiratory symptoms, these signs are supposed to have a high probability of detecting COVID-19 interstitial pneumonia. The authors have coined the terms “waterfall” and “light beam” to describe these artifacts, respectively; however, these signs may be equivalent. The waterfall sign constitutes fused B-lines (note, the authors did not describe any other particular characteristic), which are localized more frequently in the posterior and inferior areas of the lungs. On the other hand, the light beam sign, which has been described in more depth, is “a shining band-form artifact spreading down from a large portion of a regular pleural line, often appearing and disappearing with an on-off effect in the context of a normal A-line lung pattern visible in the background”<sup>14</sup> (Fig 1 and Supplemental Video 1).

From the pathophysiologic standpoint, Volpicelli et al stated that the light beam matches the ground glass opacification seen on the CT scan. This sign seems to correspond to the commencement of interstitial syndrome (B-lines) in the context of a normal lung profile. An international observational multicenter study on this subject is ongoing.<sup>13,14</sup>

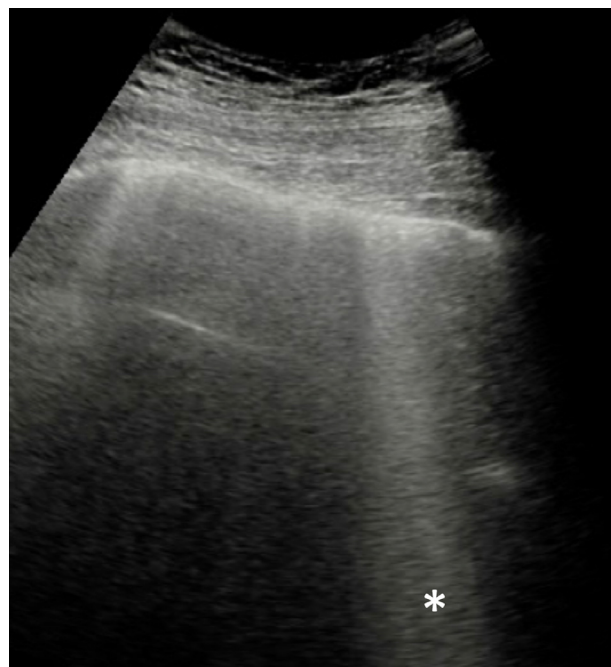


Fig. 1. The “light beam” LU sign has been proposed as a characteristic sign of COVID-19. Corresponding to ground glass opacification in computed tomography scans, it is represented by a shining band-form artifact spreading down from a large portion of a regular pleural line (white star). See also Video 1.

Table 1  
Summarizing Lung Ultrasound Findings in COVID-19 Patients.

- |                                     |
|-------------------------------------|
| - Separate B-line                   |
| - Fuse B-lines (white lung)         |
| - Fixed B-lines (waterfall sign)    |
| - Shining on-off band (light beam)  |
| - Irregular, disrupted pleural line |
| - Small consolidation               |
| - Large consolidation               |
| - Air bronchogram                   |

Abbreviation: COVID-19; coronavirus disease-2019.

The entire spectrum of LU signs in COVID-19 interstitial pneumonia is reported in Table 1.

## LU for Triage of COVID-19- Positive Patients Within the Emergency Department

As stated above, the ultrasound characteristics of COVID-19 pneumonia have been extensively described and mainly include morphologic alterations of the pleural line, the presence of multiple B lines, “white lung” areas, and consolidations.<sup>12-15</sup> However, the diagnostic approaches used in Italy during the COVID-19 outbreak have been highly heterogeneous,<sup>16</sup> reflecting the organization of each individual hospital and the radiologic imaging tools (LU, chest radiography, and CT scanners) and expertise at their disposal—all of which will have influenced the decisions regarding the first diagnostic approach to apply.<sup>17</sup> Furthermore, the combination of specific and differentiated routes for patients suspected or not of

COVID-19 could have played a decisive role in determining the diagnostic path to take.

Although obtaining sufficient access to radiologic diagnostics has been complicated for many hospitals, the ongoing pandemic has certainly fostered a rise in the awareness about LU. The LU 12 zones approach (6 for each hemithorax) in patients with suspected COVID-19 infection has been implemented in many situations.<sup>18</sup> Its primary objective has been to “rule in” or “rule out” COVID-19 pneumonia.<sup>16,17,19,20</sup> Determination of the absence or presence of hypoxemia, and its degree, together with the LU findings, presents a quick and straightforward approach that is also sufficiently accurate and feasible, even in logistically difficult contexts.

The flowchart in Figure 2 summarizes a triage hypothesis, based mainly on a clinical and ultrasonography approach to the adult patient arriving in the emergency department with clinically suspected COVID-19. The nasopharyngeal swab is performed in all patients, and despite the nonoptimal sensitivity of the test, its specificity is in fact absolute.<sup>21</sup> An accurate diagnostic gold standard is currently lacking, and the diagnosis can only be confirmed with certainty if the swab is positive. Indeed, a negative LU exam only rules out COVID-19 pneumopathy, but it does not exclude infection or, therefore, the contagiousness of a patient. Thus, in the case of a patient requiring hospitalization, if their swab is negative and LU

cannot confirm clinically suspected COVID-19, the patient can be safely admitted to a non-COVID-19 ward.

Three categories of patients with known or suspected COVID-19 can be shown: patients without hypoxemia ( $SpO_2 \geq 95\%$ ), patients with mild hypoxemia ( $SpO_2$  between 90% and 95%), and patients with severe hypoxemia ( $SpO_2 \leq 90\%$ ).

Thanks to the high sensitivity of LU, a normal LU picture (A-profile with lung sliding) in a nonhypoxic patient can safely rule out COVID-19 pneumopathy. The presence of ultrasound signs compatible with COVID-19 pneumopathy allows these patients to be discharged, although under a strict surveillance program. It is recommended to perform the walking-test in these patients if possible. The patient can be discharged safely if saturation does not fall by more than 3 points following physical exertion.<sup>22</sup>

In the case of hypoxemia (mild or severe), a negative LU means that COVID-19 can be excluded as the cause of pneumonia, requiring that an alternative diagnosis be identified. If LU detects signs compatible with a COVID-19 lung infection, the patient needs to be hospitalized (in the ward with the most appropriate intensity of care) following more detailed clinical evaluations. With that said, given the high pretest probability of infection in a pandemic context, like that for SARS-CoV-2, the specificity of the LU signs becomes much higher, but is still low and often not sufficient to confirm the diagnosis alone.<sup>11</sup>

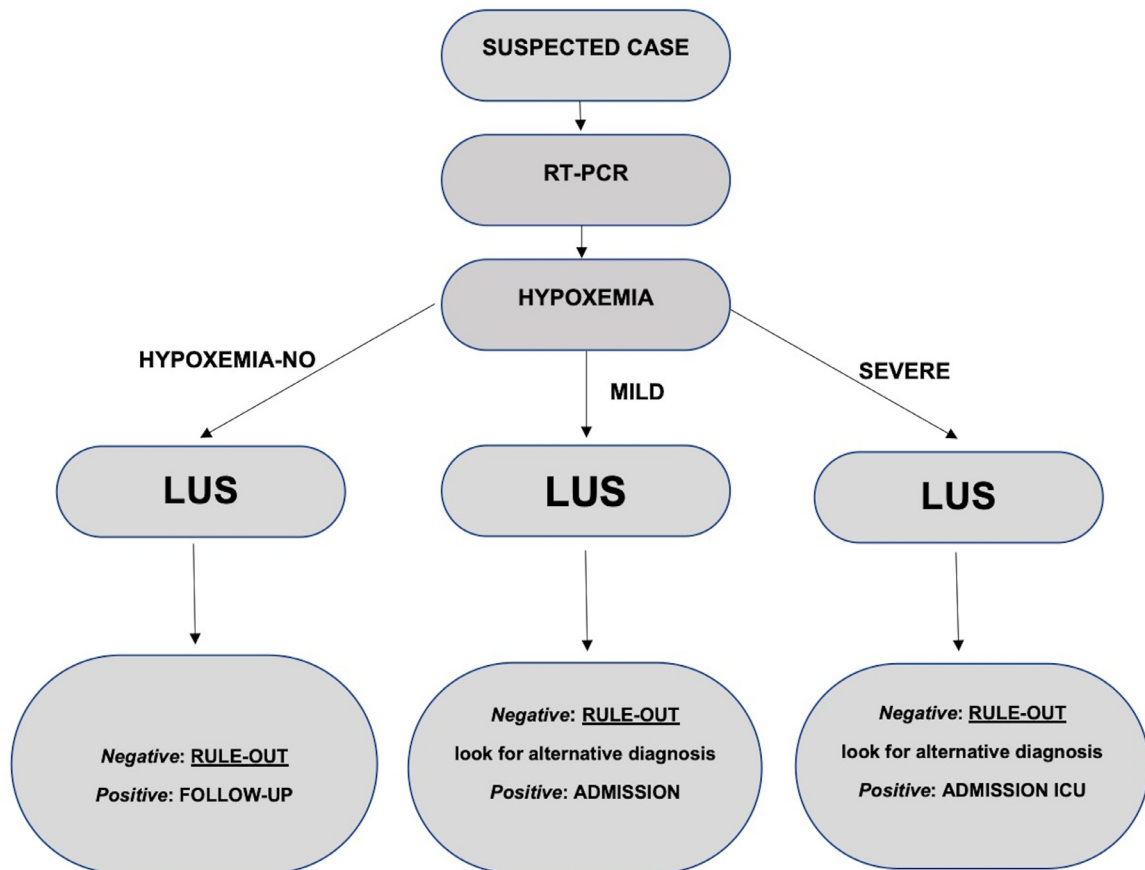


Fig. 2. The flowchart summarizes the clinical and LU approach to the adult patient with suspected COVID-19 arriving in the emergency department. LU, lung ultrasound; RT-PCR, reverse transcription-polymerase chain reaction via nasal swab.

## Roles of LU in Covid-19- Positive Patients Within the Intensive Care Unit

The LU pattern in COVID-19 patients requiring intensive care may include any or all of the following signs demonstrated in other forms of interstitial pneumonia and acute respiratory distress syndrome (ARDS): B-line patterns with multiform vertical artifacts ranging from well-spaced B-lines, coalescent B-lines, and the so-called “white lung.”<sup>23</sup> In the latter, multiple coalescent B-lines tend to merge, providing a homogenous white shining pattern, implicating severe aeration loss (Fig 3 and Supplemental Video 1). LU also is useful for monitoring the appearance of consolidations suggestive of atelectasis or superimposed pneumonia.<sup>24,25</sup>

Following a definite COVID-19 diagnosis, the proportion of the affected subpleural lung can be inferred from the extent of the pleural line involved, and this quantification permits assessment of the severity and extension of the disease. In this scenario, emerging ultrasound methods based on computer-aided diagnosis are now available<sup>26–28</sup> and provide a further and potentially promising option in terms of faster data analysis and applicability to large sets of data, especially for novice sonographers with little or no previous LU experience.<sup>29,30</sup>

From the pathophysiologic standpoint, severe COVID-19 is a disease with biphasic evolution, and 2 main phenotypes have been recognized, “type 1” and “type 2,” reflecting different parenchymal alterations.<sup>31</sup> LU can help differentiate between the 2 types by demonstrating the degree of heterogeneity of aeration loss.<sup>24</sup> In “type 1,” the aeration loss is homogeneously distributed among lung regions, with a more diffuse LU B-pattern, whereas in “type 2” loss of aeration and consolidations prevail in the dependent lung regions. In ARDS patients (but yet to be proven in COVID-19), a simple LU has been shown to be able to predict the response to positive end-expiratory pressure-induced lung recruitment<sup>32,33</sup> and pronation in terms of effective re-aeration of the dorsal lung. The evolution of the disease and the response to treatments can be inferred from LU aeration and re-aeration scores that are associated with extravascular lung water content and the average lung tissue

density, as evaluated by CT scan.<sup>8,34</sup> Moreover, LU can diagnose secondary complications of mechanical ventilation, such as pneumothorax, and detect central venous line malpositioning,<sup>35</sup> thus reducing the need for chest radiography.<sup>36</sup>

## Light and Shadows in the Use of LU in the COVID-19 Outbreak

As outlined above, LU has the capacity to answer precise questions, depending on the setting in which it is used. In the emergency department, its high sensitivity allows for the rapid ruling in or out of COVID-19, as in other diseases similar to COVID-19. In particular, it has very high sensitivity in relation to the diagnosis of interstitial syndrome and ARDS.<sup>37</sup> Furthermore, the “light beam sign” seems to be associated with a high percentage of patients with COVID-19 pneumonia with a high pretest probability, and may lean toward the diagnosis of lung involvement by COVID-19 in patients suspected of being infected.<sup>14</sup>

LU allows for the clinical progress of patients admitted to the intensive care unit (ICU) to be monitored (eg, by ultrasound profiling and the LU score) and can predict the probability of successful extubation (the possibility of heart and diaphragm involvement and their ultrasound evaluation are discussed below).<sup>18,38,39</sup> The LU strategy also may allow for the transfer of a patient from the ICU to departments with a lower level of patient care intensity.

However, some aspects of LU still require more detailed assessment. As mentioned above, the specificity of the signs detected by LU in relation to SARS-CoV-2 infection is not very high.<sup>11</sup> This constitutes a real risk of misdiagnosis or the lack of recognition of other pathologies persisting during this pandemic. Pulmonary edema, bacterial pneumonia, other forms of viral pneumonia (eg, cytomegalovirus or H1N1 virus), and pulmonary fibrosis continue to be causes of acute respiratory failure and must be kept in mind when making a differential diagnosis. Finally, it needs to be mentioned that LU cannot detect lesions deep within the lung parenchyma.<sup>40</sup>

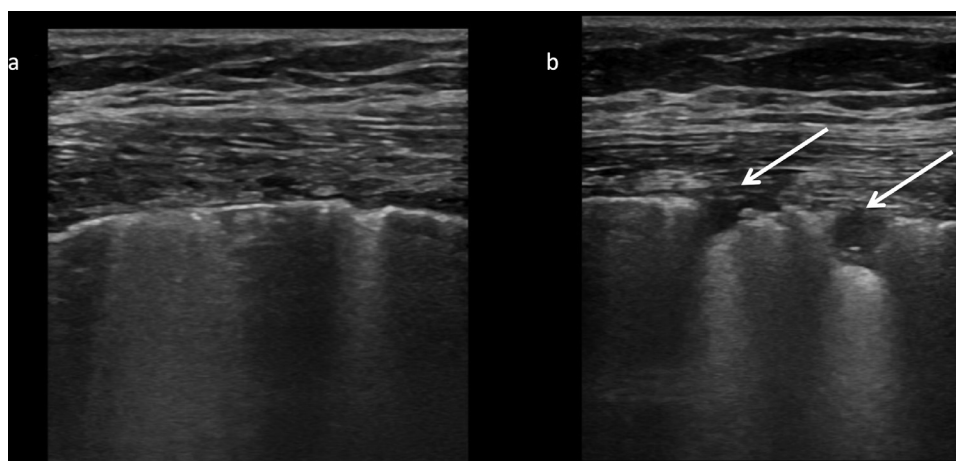


Fig. 3. (A) Bilateral B-lines are visualized both in separate and coalescent forms. (B) They can arise from small peripheral subpleural consolidations (white arrows) and spread down like rays, maintaining their brightness until the edge of the screen. See also Video 1.



It also should be noted that although numerous papers have been published dealing with the use of LU during this COVID-19 pandemic, very few (if any) offer evaluations of diagnostic accuracy in terms of sensitivity and specificity. It is the authors' opinion that lung abnormalities may develop before clinical manifestations. A patient with respiratory symptoms compatible with COVID-19 pneumonia and a suspect ultrasound pattern should be treated as COVID-19-positive until proven otherwise. However, the specificity of the nasopharyngeal swab is currently probably higher than any imaging test. Therefore, the only current test (pending the serologic tests under development) is positivity to the reverse transcription-polymerase chain reaction assay.<sup>21</sup>

### Cardiac and Vascular Ultrasound in COVID-19- Positive Patients Within the Intensive Care Unit

#### Cardiac Ultrasound

Echocardiography and vascular ultrasound also should be applied in the management of critical COVID-19 patients. As reported in Table 2, cardiac involvement may occur in these patients, either as a direct effect of the SARS-CoV-2 virus or as a consequence of lung disease and ventilatory management.<sup>5,41,42</sup> Vascular involvement also has been reported in COVID-19, and vascular ultrasound may be required for the clinical management of these patients.<sup>43</sup>

Direct cardiac involvement may manifest as dilated cardiomyopathy, as a severe decrease in ventricular systolic function and pericardial effusion in the case of viral myocarditis, or as localized wall motion abnormalities or global ventricular depression in the case of ST-elevation myocardial infarction.<sup>41,42</sup>

When looking at the effects of the virus on the lung, the following 2 pulmonary phenotypes of COVID-19 can be observed: the L phenotype, which shows preserved compliance; and the H phenotype, with high pulmonary elastance.<sup>44,45</sup> The cardiac abnormalities related to these 2 types are likely to be distinct. In the L phenotype, less severe right heart impairment would be expected because the pressure to deliver tidal volume should be lower, even in the setting of nonabsolute protective ventilation; whereas in the H phenotype, repercussions on the right heart are more probable.

In L-type dyspneic patients, either spontaneously breathing or on noninvasive respiratory support, the cardiac ultrasound exam may reveal ventricular interdependence elicited by the increased respiratory effort, causing considerable pleural negative pressure and showing diastolic ventricular septal shift, leading to left ventricular hypodiastole and reduced stroke volume. At the other end of the spectrum, in a COVID-19 H-type patient under positive-pressure mechanical ventilation, the cardiac ultrasound exam can detect cardiac insults directly connected to ventilation. In this case, the previously reported alterations secondary to mechanical ventilation<sup>46</sup> are found, with particular involvement of the right ventricle, leading to ventricular dilation, tricuspid insufficiency, reduced systolic right heart function, and possible secondary left heart

Table 2  
Summarize Cardiac Findings in COVID-19 Patients

ECG
- mild ST-elevation
- acute ST-elevation myocardial infarction
- T-wave inversions
- complete heart-block
- nonspecific intraventricular conduction delay
- multiple premature ventricular complexes
- sinus node dysfunction
Cardiac ultrasound
- moderate left ventricular systolic dysfunction
- severe left ventricular systolic dysfunction
- pulmonary arterial hypertension
- left ventricular apical ballooning syndrome
- left ventricular inverse ballooning syndrome;
- acute venous thromboembolism
- pericardial effusion
- cardiac tamponade
Coronary angiography
- nonthrombotic stenosis
- thrombotic stenosis
- plaque rupture
Reported diagnosis
- spontaneous coronary artery disease
- myocardial infarction
- pulmonary embolism
- thrombotic coronary occlusion
- typical takotsubo syndrome
- reverse takotsubo syndrome pattern
- myocarditis
- miopericarditis

Abbreviations: COVID-19; coronavirus disease-2019; ECG, electrocardiogram.

compression (Fig 4). Ventilator-induced heart dysfunction might even be present in a patient with no previous cardiac dysfunction.<sup>47</sup>

A cardiac ultrasound examination should assess right ventricular dimensions and function (usually by recording tricuspid annular plane excursion), tricuspid regurgitation, systolic pulmonary arterial pressure, and the ratio of tricuspid annular plane excursion over systolic pulmonary arterial pressure, a surrogate of right ventricular-arterial coupling.<sup>47</sup>

Left ventricular function, although less influenced by inspiratory pressures, can be directly altered by right heart dysfunction and needs to be evaluated. Considering that 50% of COVID-19 pneumonia patients are reported to suffer from systemic arterial hypertension,<sup>4</sup> diastolic evaluation always should be assessed carefully. Particular attention also should be paid to the diastolic profile of COVID-19 patients in whom LU reveals a pattern of increased extravascular lung water, especially when associated with reduced left ventricular function.

In COVID-19, increased thromboembolic risk has been reported<sup>48</sup> in the form of venous thrombosis and pulmonary embolism. This can lead to acute pulmonary hypertension, right heart enlargement, and severe tricuspid regurgitation, besides the presence of thrombi in the venous system, right atrium or ventricle—all of which can be seen using transesophageal echocardiography (Supplemental Video 2).

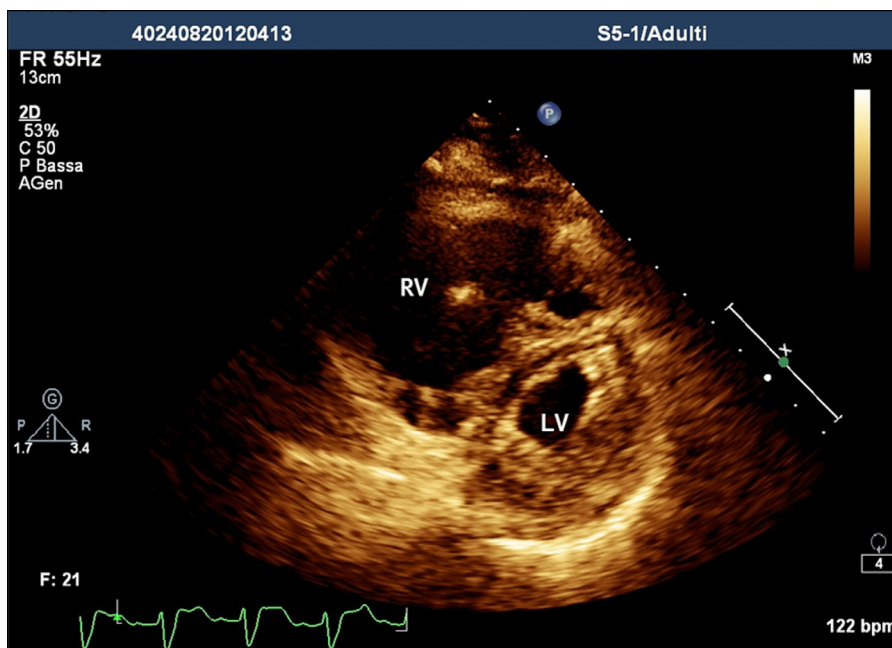


Fig. 4. Dilated right heart ventricle with a small left ventricle secondary left heart compression. See also Video 2; a transesophageal 55 Hz probe showing an intra-hepatic inferior vena cava thrombus. LV, left ventricle; RV, right ventricle.

### Vascular Ultrasound

In critically ill COVID-19 patients, a prothrombotic status seems to be frequently observed, leading to venous thrombosis and pulmonary embolism.<sup>49</sup> A vascular ultrasound assessment, with the routine use of compression ultrasonography to rule in the presence of deep vein thrombosis, seems reasonable in mechanically ventilated critically ill subjects. Compression ultrasonography should be performed in the presence of neuromuscular blocking agent infusion, especially before pronation or changing postures, or before vascular cannulation.<sup>50</sup>

Central venous cannulation in such patients may be tricky due to the physical interference caused by personal protective equipment, which could impair smooth maneuvers and finger perceptual sensitivity. This may result in the rapid deterioration of a patient's condition, deep vein thrombosis, or the use of more low-molecular-weight heparin. Furthermore, although specific guidelines on central venous cannulation have yet to be published, to the best of the authors' knowledge, the need to avoid complications in patients ventilated with elevated positive pressure, as required in pneumothorax, is clear; hence, it seems rational to prefer the routine use of ultrasonography to guide the cannulation procedure rather than relying on landmark approaches.

### What About the Diaphragm and the Weaning Process?

Identifying the right time to wean COVID-19 patients from mechanical ventilation is of critical importance. Although this invasive support used in severe forms of COVID-19 is to be considered as lifesaving, prolonged use in this particular type of patient is directly associated with further complications (ventilator-associated pneumonia, pneumothorax and

pneumomediastinum, and ventilator-induced diaphragmatic dysfunction, to name few).<sup>51,52</sup>

The decision to complete the weaning process must be made with caution because extubation failure carries serious complications.<sup>53,54</sup> Recently published case series showed that length of stay in the ICU and the duration of mechanical ventilation in severe cases of COVID-19 were almost always more than 7 days, despite the fact that most of the patients were not elderly (mean age 63 years) and had few comorbidities other than COVID-19 respiratory distress.<sup>4,52</sup>

A long length of ICU stay and duration of mechanical ventilation (especially with prolonged use of neuromuscular blocking agents) can make weaning particularly challenging and increase the risk of ventilation-induced diaphragm dysfunction.<sup>55</sup> In patients deemed difficult to wean due to ultrasound-diagnosed ventilation-induced diaphragm dysfunction, the possibility of performing a tracheostomy also must be taken into consideration. Therefore, although the role of tracheostomy in COVID-19-related ARDS is still unknown, there are several reasons why it may be helpful in this setting. First, a lower level of sedation is required, due to improved patient comfort, putting the patient in the best possible condition to generate effort. Furthermore, the reduction in airway resistance leads to reduced respiratory work; both of which may facilitate the reduction in, and ultimately the liberation from, ventilatory support.<sup>56,57</sup> However, these advantages must be weighed against the risks related to this aerosol-generating procedure. With that said, a recently published case series reported no cases of medical team infection with the virus after the performance of 28 tracheostomies in COVID-19 patients.<sup>58</sup>

In recent years, much emphasis has been placed on the study of diaphragmatic dysfunction as a predictor of weaning failure (in non-COVID-19 patients), and 2 sonographic indexes have

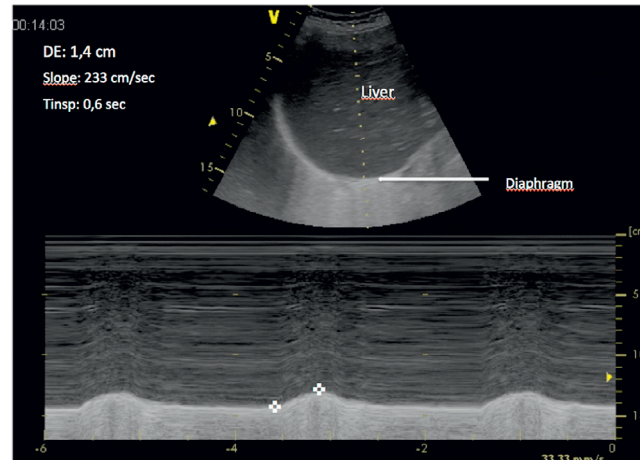


Fig. 5. Right diaphragm excursion. DE, diaphragmatic excursion; Slope, diaphragmatic contraction speed; Tinsp, inspiration time.

been studied and validated for this purpose, diaphragmatic excursion (DE) and the diaphragm thickening fraction (DTF). DE is the maximum displacement of the diaphragm during breathing, quantified in M-Mode with a low-frequency probe (2-5 MHz), preferentially in the right subcostal area (Fig 5).<sup>59</sup> An excellent diaphragm excursion measured with ultrasound and a long inspiratory time during the spontaneous breathing trial may help predict successful weaning. At the same time, DE <10 mm has been proved to be linked to a prolonged weaning period and increased weaning failure.<sup>60-62</sup>

Because DE is associated only with lung volume during the inspiratory phase, and it cannot discern whether the excursion rate is due to the contractile activity of the diaphragm or to the ventilator's positive pressure, its application is only reliable during a T-piece or low-level Continuous positive airway pressure (CPAP) spontaneous breathing trial.<sup>6</sup>

Diaphragm thickness can be assessed using a 10- to 15-MHz linear array transducer in the zone of apposition between the mid-axillary or anterior-axillary line, in the 8th- to 11th intercostal space.<sup>6,63</sup> The DTF is calculated as the difference between the end-inspiration thickness and end-

expiration thickness divided by the end-expiration thickness (Fig 6, Supplemental Video 3). The DTF also is known as the "ejection fraction" of the diaphragm and can provide a reliable indicator of diaphragm function and its actual contribution to respiratory effort. For this reason, the DTF can be helpful in choosing the appropriate time for weaning (a DTF  $\geq 30\%$  is a robust predictor of weaning success in both spontaneous breathing trials and pressure support tests) and in the daily assessment of the ventilation support tailored to the patient. During mechanical ventilation, both decreases and increases from baseline DTF (due to excessive or insufficient muscle unloading) are strongly connected to the risk of prolonged ventilator dependence.<sup>64</sup> After the first few days, when total support in COVID-19 severe patients is often needed, targeting an inspiratory effort level may accelerate liberation from ventilation.<sup>65</sup>

## Conclusion

Lung ultrasound—when in the hands of experts—is a useful bedside tool for the care of COVID-19 patients, and its capacity to rule out involvement of the respiratory system is of particular value. LU experts can presently be divided into 2 categories, those who believe in a "specific" LU pattern in COVID-19 versus those who are skeptics. Thus, LU constitutes an evolving area of interest—one in urgent need of further, accurate data. Assessing diaphragmatic function with ultrasound undoubtedly supports the clinical management of COVID-19 patients during the weaning process. In ventilated patients, cardiac, vascular and LU always should be evaluated together in order to gain a more comprehensive understanding of the relationship between lung and potential cardiac and vascular abnormalities.

## Declaration of Competing Interest

Luigi Vetrugno received travel support for Congress Lecture by Cook Medical. The other authors declare no conflict of interest.

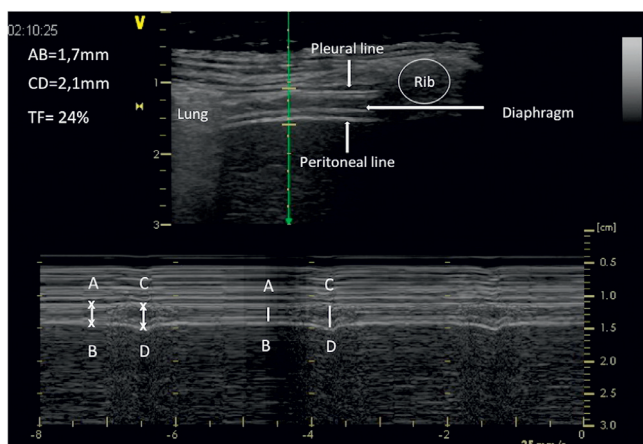


Fig. 6. Diaphragm thickening fraction (DTF) assessment in a difficult to wean 52-year-old man affected by COVID-19 respiratory distress following 10 days of invasive ventilation (see also supplemental video 3). Legend: AB (end of expiration thickness); CD (end of inspiration thickness).



## Supplementary materials

Supplementary material associated with this article can be found, in the online version, at doi:[10.1053/j.jvca.2020.06.013](https://doi.org/10.1053/j.jvca.2020.06.013).

## References

- Guan WJ, Ni ZY, Hu Y, et al. Clinical characteristics of coronavirus disease 2019 in China. *N Engl J Med* 2020;382:1708–20.
- Brojakowska A, Narula J, Shimony R, et al. Clinical implications of SARS-Cov2 interaction with renin angiotensin system. *J Am Coll Cardiol* 2020;75:3085–90. <https://doi.org/10.2174/1871530320666200427112902>. [e-pub ahead of print].
- Nikolich-Zugich J, Knox KS, Rios CT, et al. SARS-CoV-2 and COVID-19 in older adults: What we may expect regarding pathogenesis, immune responses, and outcomes. *Geroscience* 2020;42:505–14.
- Grasselli G, Zangrillo A, Zanella A, et al. Baseline Characteristics and Outcomes of 1591 patients infected with SARS-CoV-2 Admitted to ICUs of the Lombardy Region, Italy. *JAMA* 2020;323:1574–81.
- Inciardi RM, Lupi L, Zaccone G, et al. Cardiac involvement in a patient with coronavirus disease 2019 (COVID-19). *JAMA Cardiol* 2020. <https://doi.org/10.1001/jamacardio.2020.1096>. [e-pub ahead of print].
- Vetruigno L, Guadagnin GM, Barbarioli F, et al. Ultrasound imaging for diaphragm dysfunction: A narrative literature review. *J Cardiothorac Vasc Anesth* 2019;33:2525–36.
- Buonsenso D, Pata D, Chiaretti A. COVID-19 outbreak: Less stethoscope, more ultrasound. *Lancet Respir Med* 2020;8:e27.
- Yoon SH, Lee KH, Kim JY, et al. Chest radiographic and CT findings of the 2019 novel coronavirus disease (COVID-19): Analysis of nine patients treated in Korea. *Korean J Radiol* 2020;21:494–500.
- Smith MJ, Hayward SA, Innes SM, et al. Point-of-care lung ultrasound in patients with COVID-19 – a narrative review. *Anaesthesia* 2020. <https://doi.org/10.1111/anae.15082>. [e-pub ahead of print].
- Soldati G, Smargiassi A, Inghingolo R, et al. Is there a role for lung ultrasound during the COVID-19 pandemic? *J Ultrasound Med* 2020;39:1459–62.
- Vetruigno L, Bove T, Orso D, et al. Lung ultrasound and the COVID-19 “Pattern”: Not all that glitter today is gold tomorrow. *J Ultrasound Med* 2020. <https://doi.org/10.1002/jum.15327>. [e-pub ahead of print].
- Huang, Yi and Wang, Sihan and Liu, Yue and Zhang, Yaohui and Zheng, Chuyun and Zheng, Yu and Zhang, Chaoyang and Min, Weili and Zhou, Huihui and Yu, Ming and Hu, Mingjun, A Preliminary Study on the Ultrasonic Manifestations of Peripulmonary Lesions of Non-Critical Novel Coronavirus Pneumonia (COVID-19) (February 26, 2020). Available at SSRN: <https://ssrn.com/abstract=3544750> or <https://dx.doi.org/10.2139/ssrn.3544750>. [e-pub ahead of print].
- Volpicelli G, Gargani L. Sonographic signs and patterns of COVID-19 pneumonia. *Ultrasound J* 2020;12:22.
- Volpicelli G, Lamorte A, Villén T. What’s new in lung ultrasound during the COVID-19 pandemic. *Intensive Care Med* 2020;1–4. <https://doi.org/10.1007/s00134-020-06048-9>. [e-pub ahead of print].
- Peng QY, Wang XT, Zhang LN, et al. Findings of lung ultrasonography of novel corona virus pneumonia during the 2019-2020 epidemic. *Intensive Care Med* 2020;46:849–50.
- Vetruigno L, Bove T, Orso D, et al. Our Italian experience using lung ultrasound for identification, grading and serial follow-up of severity of lung involvement for management of patients with COVID-19. *Echocardiography* 2020;37:625–7.
- Salehi S, Abedi A, Balakrishnan S, et al. Coronavirus disease 2019 (COVID-19): A systematic review of imaging findings in 919 patients. *Am J Roentgenol* 2020;215:87–93.
- Mongodi S, Bouhemad B, Orlando A, et al. Modifizierter lungen-US-Score zur bewertung und überwachung der belüftung der lunge [Modified lung ultrasound score for assessing and monitoring pulmonary aeration]. *Ultraschall Med* 2017;38:530–7;German].
- Zotzmann V, Lang CN, Bamberg F, et al. Are subpleural consolidations indicators for segmental pulmonary embolism in COVID-19? *Intensive Care Med* 2020;46:1109–10.
- Soldati G, Smargiassi A, Inghingolo R, et al. Proposal for international standardization of the use of lung ultrasound for patients with COVID-19: A simple, quantitative, reproducible method. *J Ultrasound Med* 2020;39:1413–9.
- Zitek T. The appropriate use of testing for COVID-19. *West J Emerg Med* 2020;21:470–2.
- National Institute for Health and clinical Excellence. COVID-19 rapid guideline: Managing suspected or confirmed pneumonia in adults in the community. London: NICE; 2020. Available at: <https://www.nice.org.uk/guidance/ng165>. Accessed May 19, 2020.
- Mojoli F, Bouhemad B, Mongodi S, et al. Lung ultrasound for critically ill patients. *Am J Respir Crit Care Med* 2019;199:701–14.
- Mongodi S, Via G, Girard M, et al. Lung ultrasound for early diagnosis of ventilator-associated pneumonia. *Chest* 2016;149:969–80.
- Chiumello D, Mongodi S, Algieri I, et al. Assessment of lung aeration and recruitment by CT scan and ultrasound in acute respiratory distress syndrome patients. *Crit Care Med* 2018;46:1761–8.
- Corradi F, Brusasco C, Garlaschi A, et al. Quantitative analysis of lung ultrasonography for the detection of community-acquired pneumonia: A pilot study. *Biomed Res Int* 2015;2015:868707.
- Corradi F, Brusasco C, Vezzani A, et al. Computer-aided quantitative ultrasonography for detection of pulmonary edema in mechanically ventilated cardiac surgery patients. *Chest* 2016;150:640–51.
- Corradi F, Ball L, Brusasco C, et al. Assessment of extravascular lung water by quantitative ultrasound and CT in isolated bovine lung. *Respir Physiol Neurobiol* 2013;187:244–9.
- Gullett J, Donnelly JP, Sinert R, et al. Interobserver agreement in the evaluation of B-lines using bedside ultrasound. *J Crit Care* 2015;30:1395–9.
- Pičuljan A, Šuštić M, Brumini G, et al. Reliability of B-line quantification by different-level observers and a software algorithm using point-of-care lung ultrasound. *J Clin Monit Comput* 2019. <https://doi.org/10.1007/s10877-019-00440-7>. [e-pub ahead of print].
- Copetti R, Soldati G, Copetti P. Chest sonography: A useful tool to differentiate acute cardiogenic pulmonary edema from acute respiratory distress syndrome. *Cardiovasc Ultrasound* 2008;6:16.
- Bouhemad B, Brisson H, Le-Guen M, et al. Bedside ultrasound assessment of positive end-expiratory pressure-induced lung recruitment. *Am J Respir Crit Care Med* 2011;183:341–7.
- Haddam M, Zieleskiewicz L, Perbet S, et al. Lung ultrasonography for assessment of oxygenation response to prone position ventilation in ARDS. *Intensive Care Med* 2016;42:1546–56.
- Brusasco C, Santori G, Bruzzo E, et al. Quantitative lung ultrasonography: A putative new algorithm for automatic detection and quantification of B-lines. *Crit Care* 2019;23:288.
- Vezzani A, Brusasco C, Palermo S, et al. Ultrasound localization of central vein catheter and detection of postprocedural pneumothorax: An alternative to chest radiography. *Crit Care Med* 2010;38:533–8.
- Brogi E, Bignami E, Sidoti A, et al. Could the use of bedside lung ultrasound reduce the number of chest x-rays in the intensive care unit? *Cardiovasc Ultrasound* 2017;15:23.
- Orso D, Guglielmo N, Copetti R. Lung ultrasound in diagnosing pneumonia in the emergency department: A systematic review and meta-analysis. *Eur J Emerg Med* 2018;25:312–21.
- Vetruigno L, Guadagnin GM, Brussa A, et al. Mechanical ventilation weaning issues can be counted on the fingers of just one hand: Part 1. *Ultrasound J* 2020;12:9.
- Vetruigno L, Brussa A, Guadagnin GM, et al. Mechanical ventilation weaning issues can be counted on the fingers of just one hand: Part 2. *Ultrasound J* 2020;12:15.
- Lichtenstein DA, Lascols N, Mezière G, et al. Ultrasound diagnosis of alveolar consolidation in the critically ill. *Intensive Care Med* 2004;30:276–81.

- 41 Stefanini GG, Montorfano M, Trabattoni D, et al. ST-Elevation myocardial infarction in patients with COVID-19: Clinical and angiographic outcomes. *Circulation* 2020;141:2113–216.
- 42 European Society of Cardiology. European Heart Journal Cardiovascular Imaging. Available at: <https://www.escardio.org/Education/COVID-19-and-Cardiology>. Accessed May 19, 2020.
- 43 Ackermann M, Verleden SE, Kuehnel M, et al. Pulmonary vascular endothelialitis, thrombosis, and angiogenesis in covid-19. *N Engl J Med* 2020. <https://doi.org/10.1056/NEJMoa2015432>. [e-pub ahead of print].
- 44 Gattinoni L, Chiumello D, Caironi P, et al. COVID-19 pneumonia: Different respiratory treatments for different phenotypes? *Intensive Care Med* 2020;46:1099–102.
- 45 Marini JJ, Gattinoni L. Management of COVID-19 respiratory distress. *JAMA* 2020. <https://doi.org/10.1001/jama.2020.6825>. [e-pub ahead of print].
- 46 Repessé X, Charron C, Vieillard-Baron A. Assessment of the effects of inspiratory load on right ventricular function. *Curr Opin Crit Care* 2016;22:254–9.
- 47 Mekontso Dessap A, Boissier F, Charron C, et al. Acute cor pulmonale during protective ventilation for acute respiratory distress syndrome: Prevalence, predictors, and clinical impact. *Intensive Care Med* 2016;42:862–70.
- 48 Llitjos JF, Leclerc M, Chochois C, et al. High incidence of venous thromboembolic events in anticoagulated severe COVID-19 patients. *J Thromb Haemost* 2020. <https://doi.org/10.1111/jth.14869>. [e-pub ahead of print].
- 49 Wichmann D, Sperhake JP, Lütgehetmann M, et al. Autopsy findings and venous thromboembolism in patients with COVID-19: A prospective cohort study. *Ann Intern Med* 2020:M20–2003. <https://doi.org/10.7326/M20-2003>. [e-pub ahead of print].
- 50 Pujol S, Laurent J, Markarian T, et al. Compression with a pocket-sized ultrasound device to diagnose proximal deep vein thrombosis. *Am J Emerg Med* 2018;36:1262–4.
- 51 Peñuelas O, Frutos-Vivar F, Fernández C, et al. Characteristics and outcomes of ventilated patients according to time to liberation from mechanical ventilation. *Am J Respir Crit Care Med* 2011;184:430–7. <https://doi.org/10.1164/rccm.201011-1887OC>.
- 52 Zangrillo A, Beretta L, Scandroglio AM, et al. Characteristics, treatment, outcomes and cause of death of invasively ventilated patients with COVID-19 ARDS in Milan, Italy. *Crit Care Resusc* 2020. [e-pub ahead of print].
- 53 Lemaire F, Teboul JL, Cinotti L, et al. Acute left ventricular dysfunction during unsuccessful weaning from mechanical ventilation. *Anesthesiology* 1988;69:171–9.
- 54 Richardson S, Hirsch JS, Narasimhan M, et al. Presenting characteristics, comorbidities, and outcomes among 5700 patients hospitalized with COVID-19 in the New York City Area. *JAMA* 2020;323:2052–9.
- 55 Vassilakopoulos T, Petrof BJ. Ventilator-induced diaphragmatic dysfunction. *Am J Respir Crit Care Med* 2004;169:336–41.
- 56 MacIntyre NR. Evidence-based ventilator weaning and discontinuation. *Respir Care* 2004;49:830–6.
- 57 Pierson DJ. Tracheostomy and weaning. *Respir Care* 2005;50:526–33.
- 58 Shiba T, Ghazizadeh S, Chhetri D, et al. Tracheostomy considerations during the COVID-19 pandemic. *OTO Open* 2020;4:2473974X20922528.
- 59 Tuinman PR, Jonkman AH, Dres M, et al. Respiratory muscle ultrasonography: Methodology, basic and advanced principles and clinical applications in ICU and ED patients—a narrative review. *Intensive Care Med* 2020;46:594–605.
- 60 Palkar A, Narasimhan M, Greenberg H, et al. Diaphragm excursion-time index: A new parameter using ultrasonography to predict extubation outcome. *Chest* 2018;153:1213–20.
- 61 Kim WY, Suh HJ, Hong SB, et al. Diaphragm dysfunction assessed by ultrasonography: Influence on weaning from mechanical ventilation. *Crit Care Med* 2011;39:2627–30.
- 62 Dubé BP, Dres M, Mayaux J, et al. Ultrasound evaluation of diaphragm function in mechanically ventilated patients: Comparison to phrenic stimulation and prognostic implications. *Thorax* 2017;72:811–8.
- 63 Matamis D, Soilemezi E, Tsagourias M, et al. Sonographic evaluation of the diaphragm in critically ill patients. Technique and clinical applications. *Intensive Care Med* 2013;39:801–10.
- 64 Goligher EC, Dres M, Fan E, et al. Mechanical ventilation-induced diaphragm atrophy strongly impacts clinical outcomes. *Am J Respir Crit Care Med* 2018;197:204–13.
- 65 DiNino E, Gartman EJ, Sethi JM, et al. Diaphragm ultrasound as a predictor of successful extubation from mechanical ventilation. *Thorax* 2014;69:423–7.