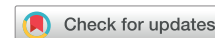

Incessant ventricular tachycardia with simultaneous recording of separate exits with common isthmus wavefront propagation



Marianne Tetreault-Langlois, MD,^{*} Antonio Frontera, MD, PhD,[†]
Alexios E. Hadjis, MD, MSc^{*}

From the ^{*}Division of Cardiology, Hôpital du Sacré-Coeur de Montréal, University of Montreal, Montreal, Quebec, Canada, and [†]Cardiac Arrhythmia department, IRCCS Humanitas Research Hospital, Rozzano, Milan, Italy.

Background

The mechanisms of bimorphic ventricular tachycardia (VT) have been studied since the 1980s. Miller et al¹ described possible mechanisms that could explain variable QRS morphologies on surface electrocardiogram (ECG): different expressions of the same VT circuit due to preferential exit points along a shared isthmus; distinct circuits closely placed; and widely unconnected arrhythmogenic sites. The first 2 mechanisms seem to account for most cases of bimorphic VT seen in clinical practice. Bogun et al² reported that a shared isthmus with different exit points may account for up to 40% of bimorphic VTs in ischemic cardiomyopathy. However, the dynamic 3-dimensional nature of isthmus conduction in bimorphic VT has yet to be clearly elucidated.

Case report

The patient was a 77-year-old woman known for ischemic cardiomyopathy with a left ventricular ejection fraction of 20%–25%, a history of sustained monomorphic VT, and an implantable cardioverter-defibrillator. She presented to an outside hospital with VT storm. The patient was transferred to our center for hemodynamically stable VT with alternating QRS morphologies, left bundle left inferior axis, and left bundle right superior axis, which was incessant despite several attempts at pharmacologic and electrical cardioversion. The patient was brought to the electrophysiology laboratory for urgent ablation. Electroanatomic imaging of the entire diastolic pathway recorded

2 separate exit electrograms (EGMs) preceding each morphologically distinct QRS. Isthmus EGMs, recorded within the same mapping catheter location, demonstrated a beat-to-beat alternating wavefront pattern. The 2 different exit sites (1 anteroseptal, 1 inferolateral) from an extensive anteroapical scar led the wavefront to travel in 2 separate outer loops as demonstrated by the 2 different timings of QRS to isthmus (Figure 1). Timing from each alternate QRS offset to early diastolic potentials was identical, thus supporting equivalent entrance timing for both morphologies and corresponding common isthmus.

In patients with left bundle morphology and only partial diastolic pathway activity recorded, we routinely map the right ventricular septum to identify the missing segments, assess for an intramural component, and potentially prepare for bipolar ablation if needed. In this particular patient, because we were able to record the entire diastolic pathway in the left ventricular endocardium, we did not pursue further right-sided mapping.

Ablation at the site of the common isthmus resulted in immediate termination of the VT (Figure 2). All areas that recorded diastolic activity and were operational during VT were subsequently targeted for ablation. After ablation of the entire diastolic pathway, programmed extrastimulation resulted in no inducible VT.

Discussion

It is well established that the primary mechanism of VT in structural heart disease is electrical reentry within scar tissue. In ischemic cardiomyopathy, surviving myocyte bundles serve as conduction channels through fibrosis and thus create VT circuits. These circuits can be composed of different loops, with the isthmus being the segment where all loops connect. It is known that ablation at the site of the isthmus has the best chance to successfully disrupt the circuit and terminate the arrhythmia.³

KEYWORDS diastolic pathway mapping; Dual exit; High-density mapping; Separate exit; Shared isthmus; Ventricular tachycardia (Heart Rhythm 0² 2022;3:710–712)

Address reprint requests and correspondence: Dr Alexios E. Hadjis, Division of Cardiology, Hôpital du Sacré-Coeur de Montréal, Montreal, Quebec H4J 1C5, Canada. E-mail address: alexios.hadjis.med@sss.gouv.qc.ca.

KEY FINDINGS

- Recording of separate exit electrograms from a common isthmus during bimorphic ventricular tachycardia is possible using high-density mapping.
- Differential propagation through a common isthmus may lead the wavefront to travel in 2 separate outer loops.
- The difference in timing and cycle length observed arise from the different exit points from the isthmus and the subsequent time from the late diastolic signals to the onset of the QRS. This phenomenon highlights an alternate functional block within the common isthmus demonstrating the dynamic and 3-dimensional nature of the reentry isthmus, which previously was thought of as a 2-dimensional structure.

Patients with ischemic cardiomyopathy in VT may present with different QRS morphologies on surface ECG. These bimorphic VTs may occur spontaneously or may be induced by stimulation during electrophysiological study. These patients are less likely to respond favorably to ablation therapy, reflecting a more complex arrhythmia substrate. One mechanism that may account for multiple VT morphologies on surface ECG is different exit points along a common isthmus, which has been shown to occur in almost half of patients with underlying ischemic heart disease.²

High-density mapping of VT circuits allows better localization and characterization of the structure and function of arrhythmogenic zones. In the case described here, high-density mapping of the VT circuit demonstrated distinct exit EGMs from a single isthmus and allowed successful catheter ablation of the arrhythmia.

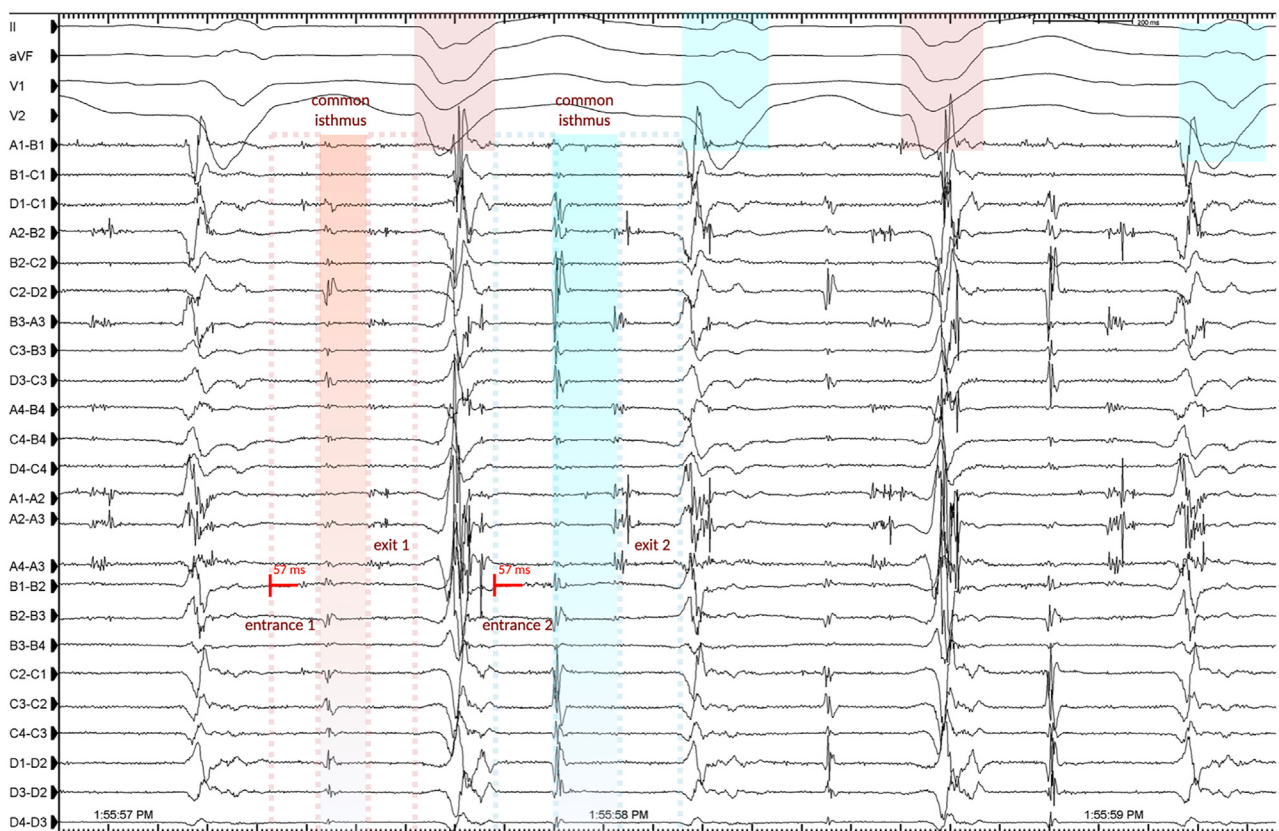


Figure 1 Activation mapping during ventricular tachycardia. Alternating isthmus electrogram wavefront before 2 distinct exit electrogram (EGM) patterns preceding the alternating QRS morphologies. Distinct entrance EGM patterns from QRS offset to isthmus further indicate separate entrances.

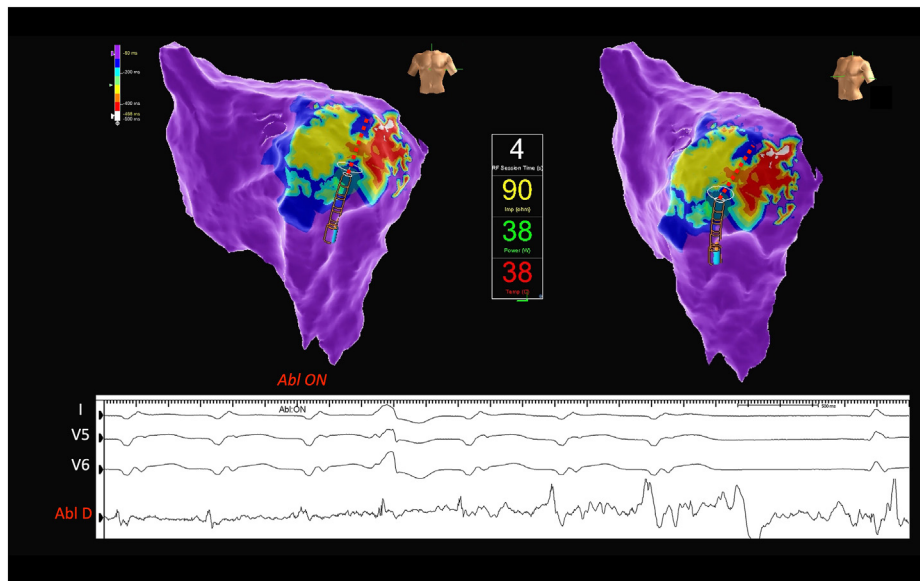


Figure 2 Ablation at the common isthmus results in near immediate termination of ventricular tachycardia. Red dotted line depicts transecting line of ablation across the isthmus.

During activation mapping of the VT, we did not pursue entrainment maneuvers for fear of terminating the clinical tachycardia with failure to reinduce or changing the clinical tachycardia. Our assessment of isthmus was based not only on EGM timing but also on isthmus electrogram morphology, as reported by Ciaccio et al.⁴ The isthmus EGMs manifest low amplitude and relatively shorter duration compared to the entrance and exit sites. Termination of VT within 4 seconds of ablation strongly suggested participation of the isthmus in the VT circuit.

Furthermore, the difference in timing and cycle length observed arises from the different exit points from the isthmus and the subsequent time from the late diastolic signals to the onset of the QRS. This phenomenon highlights an alternate functional block within the common isthmus demonstrating the dynamic and 3-dimensional nature of the reentry isthmus, which was previously thought of as a 2-dimensional structure.⁴

Conclusion

This case demonstrates that recording of separate exit EGMs from a common isthmus during VT with dual exits is feasible using high-density mapping, and differential

propagation through a common isthmus during dual exit VT also may lead the wavefront to travel in 2 separate outer loops.

Funding Sources: The authors have no fundings sources to disclose.

Disclosures: Dr Hadjis discloses consultant fees from Abbott, Medtronic, and Biosense Webster. Drs Tetreault-Langlois and Frontera have no conflicts of interest to disclose.

Authorship: All authors attest they meet the current ICMJE criteria for authorship.

Patient Consent: The patient reported in this paper provided written informed consent for VT mapping and ablation.

References

1. Miller JM, Kienle MG, Harken AH, Josephson ME. Morphologically distinct sustained ventricular tachycardias in coronary artery disease: significance and surgical results. *J Am Coll Cardiol* 1984;4:1073–1079.
2. Bogun F, Li YG, Groenefeld G, et al. Prevalence of a shared isthmus in postinfarction patients with pleiomorphic, hemodynamically tolerated ventricular tachycardias. *J Cardiovasc Electrophysiol* 2002;13:237–241.
3. Hadjis A, Frontera A, Limite LR, et al. Complete electroanatomic imaging of the diastolic pathway is associated with improved freedom from ventricular tachycardia recurrence. *Circ Arrhythm Electrophysiol* 2020;13:e008651.
4. Ciaccio EJ, Anter E, Coromilas J, et al. Structure and function of the ventricular tachycardia isthmus. *Heart Rhythm* 2022;19:137–153.