

Evaluating the Correlation between Alzheimer's Amyloid- β Peptides and Glaucoma in Human Aqueous Humor

Francesca Cappelli^{1,*}, Francesca Caudano^{2,*}, Maria Marengo¹, Valeria Testa¹, Alessandro Masala³, Daniele Sindaco¹, Angelo Macrì³, Carlo E. Traverso^{1,3}, Michele Iester^{1,3}, and Roberta Ricciarelli^{2,3}

¹ Department of Neurosciences, Rehabilitation, Ophthalmology, Genetics, Maternal and Child Health (DiNOGMI), University of Genoa, Genoa, Italy

² Department of Experimental Medicine, University of Genoa, Genoa, Italy

³ IRCCS Ospedale Policlinico San Martino, Genoa, Italy

Correspondence: Roberta Ricciarelli, Department of Experimental Medicine, University of Genoa, Via LB Alberti 2, 16132 Genoa, Italy.

e-mail: ricciarelli@medicina.unige.it

Michele Iester, Department of Neurosciences, Rehabilitation, Ophthalmology, Genetics, Maternal and Child Health (DiNOGMI), University of Genoa, Viale Benedetto XV, 7, Genova 16132 Genoa, Italy. e-mail: iester@unige.it

Received: January 10, 2020

Accepted: February 23, 2020

Published: April 25, 2020

Keywords: Alzheimer's disease; glaucoma; beta-amyloid; aqueous humor

Citation: Cappelli F, Caudano F, Marengo M, Testa V, Masala A, Sindaco D, Macrì A, Traverso CE, Iester M, Ricciarelli R. Evaluating the correlation between Alzheimer's amyloid- β peptides and glaucoma in human aqueous humor. *Trans Vis Sci Tech.* 2020;9(5):21, <https://doi.org/10.1167/tvst.9.5.21>

Purpose: Recent studies suggest that glaucoma may share common pathogenic mechanisms with Alzheimer's disease. To test this hypothesis, we investigated the correlation between glaucoma and amyloid- β_{42} ($A\beta_{42}$) concentration in human samples of aqueous humor (AH).

Methods: Eighty-one candidates for cataract or glaucoma surgery were consecutively enrolled, with a median age of 77 years; of these, 32 subjects were affected by glaucoma and 49 were controls. Before surgery, each patient received an ophthalmological examination including biometry, intraocular pressure (IOP) measurement, fundus photography, and determination of the mean thickness of the ganglion cell complex (GCC) and/or retinal nerve fiber layer. During the surgical procedure, an AH sample was collected and immediately processed for total protein (TP) and $A\beta_{42}$ evaluation.

Results: $A\beta_{42}$ levels were not statistically different between the glaucomatous and control samples, but a significant increase in TP concentration was found in the AH of glaucoma patients compared with controls ($P = 0.02$). In addition, positive correlations were observed between TP and $A\beta_{42}$ ($r = 0.51$; $P < 0.0001$), between TP and IOP ($r = 0.44$; $P < 0.0001$), and between $A\beta_{42}$ and IOP ($r = 0.22$; $P = 0.033$).

Conclusions: Our results indicate that an increased protein concentration in the AH could play a role in the pathogenesis of glaucomatous disease.

Translational Relevance: This study strongly supports the hypothesis that increased TP in the AH may have a pathogenic role in glaucoma. Further investigations are needed to clarify whether the protein enhancement represents a causative factor and whether it can be used as a marker of disease or as a novel therapeutic target.

Introduction

Glaucoma is an optic neuropathy caused by apoptosis of retinal ganglion cells that leads to visual field loss and eventually to blindness.¹ A combination of genetic predisposition, immune system alterations, and stress factors is believed to contribute to the pathogenesis of

glaucoma,² which is now considered a neurodegenerative syndrome rather than simply an eye disease.

Recent evidence indicates that neurodegenerative lesions in glaucoma extend to the retina, intracranial optic nerve, lateral geniculate body, and visual cortex. In the lateral geniculate nucleus (LGN), apoptosis is characterized by neuronal shrinkage and is accompanied by glial activation and a decreased thickness of both LGN and visual cortex.^{3,4}

Glaucoma shares some features with Alzheimer's disease (AD), such as age-related incidence, apoptosis of specific neuronal populations, protein misfolding, production of reactive oxygen species, and vascular abnormalities.^{5,6} Remarkably, optic nerve degeneration and apoptosis of retinal ganglion cells have been described in AD patients,^{7,8} but the existence of a pathogenic link between glaucoma and AD, if any, remains to be elucidated.

One of the key hallmarks of AD is the progressive accumulation of amyloid- β ($A\beta$) peptides in the brain, particularly in the frontal, parietal, and temporal cortices. Recently, the presence of $A\beta$ peptides has also been reported in the retina of AD patients.⁹ Additionally, $A\beta$ peptides and other AD-related proteins were found in the aqueous humor (AH) of patients affected by glaucoma and pseudoexfoliation syndrome, suggesting $A\beta$ as a possible common etiologic factor for AD and glaucoma.^{10,11} To further investigate this issue, we analyzed the AH concentration of $A\beta_{42}$, the most toxic $A\beta$ species, in glaucomatous and control patients undergoing ocular surgery.

Methods

Research Design and Participants

From April to October 2018, 81 candidates for cataract or glaucoma surgery were consecutively enrolled according to the criteria set by the Declaration of Helsinki. Thirty-two males and 49 females (median age, 77 years) who were attending the University Eye Clinic of Genoa to undergo ocular surgery were grouped according to the presence of glaucoma. Thirty-two subjects (12 males and 20 females) were affected by glaucoma, including primary open-angle glaucoma, secondary open-angle glaucoma (pseudo-exfoliative glaucoma, pigmentary glaucoma), or primary closed-angle glaucoma; 49 patients were glaucoma free (20 control males and 29 control females). Two patients with glaucoma and three control subjects underwent surgery in both eyes, but only one eye was randomly selected for the statistical analysis. The institutional review board of the Department of Neurosciences, Rehabilitation, Ophthalmology, Genetics, Maternal and Child Health at the University of Genoa approved this study. All patients signed the informed consent form.

Clinical Procedures

Detailed medical, pharmacological, and ocular histories of patients were obtained and recorded.

Before surgery, all patients underwent ophthalmological examinations that included fundus photography, best-corrected visual acuity measurement, slit-lamp biomicroscopy, and intraocular pressure (IOP) measurement with Goldmann applanation tonometry. In glaucomatous patients, visual field indices were recorded when feasible. Biometry was performed with a Nidek AL-Scan (Aichi, Japan) and Haag-Streit Lenstar LS900 (Köniz, Switzerland). Axial length (AXL), anterior chamber depth (ACD), and central corneal thickness (CCT) were recorded. All patients underwent optical coherence tomography (OCT) examination (unless not possible due to media opacities), and ganglion cell complex (GCC) and retinal nerve fiber layer (RNFL) mean thickness analyses were conducted using an Optovue RTVue RT-100 (Fremont, CA). During the procedure of cataract or glaucoma surgery, an AH sample was collected and immediately processed for total protein (TP) and $A\beta_{42}$ analyses.

$A\beta_{42}$ Evaluation

Because $A\beta$ peptides undergo temperature- and time-dependent aggregation changes that may interfere with their quantitative evaluation, fresh samples of AH underwent specific $A\beta_{42}$ highly sensitive enzyme-linked immunosorbent assay (ELISA; Waco Human/Rat β Amyloid(42), Fujifilm, Tokyo, Japan) immediately upon collection. ELISA analyses were carried out following the manufacturer's protocol, and the levels of $A\beta_{42}$ peptides were calculated according to the standard curves prepared on the same ELISA plates.

Total Protein Measurement

TP concentrations were analyzed in freshly collected AH samples using the Pierce BCA Protein Assay Kit (Thermo Fisher Scientific, Waltham, MA), according to the manufacturer's instructions.

Data Analysis

All data are expressed as mean \pm SD. Statistical analysis was performed using SPSS Statistics 21.0 (IBM, Armonk, NY). Differences between the control and glaucomatous groups were evaluated with unpaired *t*-tests. Pearson's correlation was used to measure the strength of linear association between $A\beta_{42}$ levels and the other tested parameters. Statistical significance was set at $P < 0.05$.

Table 1. Differences Between Control and Glaucomatous Patients

Analyzed Parameter	Control	Glaucoma	P
AH Aβ ₄₂ , pg/ml	47.19 ± 20.21	53.33 ± 23.21	0.211
IOP, mm Hg	15.20 ± 2.74	17.67 ± 4.58	0.006
OCT GCC, μm	88.65 ± 9.67	73.74 ± 12.10	0.0002
OCT RNFL (overall), μm	82.59 ± 12.69	67.18 ± 14.23	0.032
AXL, mm	23.89 ± 1.57	23.20 ± 0.57	0.026
ACD, mm	3.13 ± 0.33	3.27 ± 0.33	0.211
CCT, μm	555.10 ± 31.61	527.40 ± 37.87	0.003

Data are expressed as mean ± SD. Statistical analysis was performed with unpaired t-tests. Bold means statistically significant values.

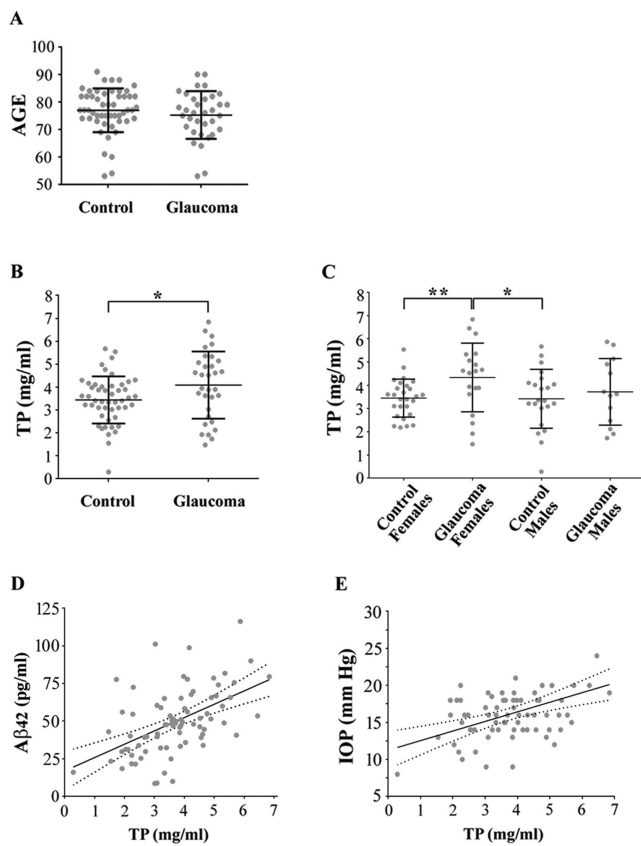


Figure. Comparison between the glaucoma and control groups for (A) age and (B, C) TP concentration in the AH. Correlation between AH TP concentration and (D) Aβ₄₂ levels or (E) IOP. Data are expressed as mean ± SD. *P < 0.05; **P < 0.01.

Table 2. Pearson’s Correlation Between AH Aβ₄₂ Levels and Clinical Variables

	r	P
IOP	0.222	0.033
OCT GCC	-0.026	0.102
OCT RNFL	0.028	0.917
ACD	0.163	0.173
CCT	0.045	0.737
Patient age	0.029	0.792

control samples (Fig. B). Particularly, such increases were greater within the glaucomatous female group when compared to both female controls (+27%; P = 0.010) and male controls (+32%; P = 0.038) (Fig. C). A moderate positive correlation was observed either between TP concentration and Aβ₄₂ levels (r = 0.51; P < 0.0001) (Fig. D) or between TP concentration and pre-operative IOP (r = 0.44; P < 0.0001) (Fig. E).

Pre-operative IOP was slightly higher in glaucomatous patients than in controls (+16%; P < 0.01), despite anti-glaucoma medications not being discontinued (Table 1). As expected,¹² a significant reduction in terms of OCT GCC (-17%; P < 0.001), OCT RNFL (-19%; P < 0.05), AXL (-3%; P < 0.05), and CCT (-5%; P < 0.01) was detected in the glaucomatous group of patients compared to controls, whereas no differences were measured in terms of AH Aβ₄₂ concentration and ACD (Table 1).

In line with the results indicating a relationship between TP and Aβ₄₂ and between TP and pre-operative IOP, levels of AH Aβ₄₂ were found to increase with increasing IOP (r = 0.222; P = 0.033), whereas no correlation was observed between AH Aβ₄₂ concentration and the other clinical parameters analyzed (Table 2).

Results

The glaucoma and control groups were homogeneous for gender and age (Fig. A). A significant increase in TP concentration (+20%; P = 0.02) was found in the AH of glaucoma patients compared with

Discussion

The AH is a clear transparent fluid that fills the anterior and posterior chamber of the eye. When produced by the ciliary processes in the posterior chamber, it flows through the pupil into the anterior chamber. This fluid delivers neurotransmitters and provides nutrients for the metabolism of the avascular cornea and lens. In addition, it removes waste products, allows drug distribution, and, during inflammation, carries inflammatory mediators and cells.¹³

Samples of AH can be relatively easily collected from the anterior chamber and used for diagnostic and therapeutic purposes. Indeed, microbiological and molecular AH analyses are widely used for cases of infectious and inflammatory eye diseases. Moreover, proteomic studies have revealed that AH composition might change in ocular pathologies such as glaucoma, macular edema, and optic neuritis.^{14–17}

AH A β peptides and other AD-related proteins can be found in the AH of patients with pseudoexfoliation syndrome and glaucoma, suggesting a common etiology for these diseases and implicating A β as a possible mutual therapeutic target.^{10,11,18} However, in line with studies performed by others,^{10,19} our results did not show any statistically significant difference in terms of AH A β_{42} concentration between the glaucoma and control groups or with respect to other clinical parameters. Conversely, we found a significant increase of TP in the AH of glaucomatous patients, consistent with previous reports showing an increment of pro-inflammatory cytokine^{20–23} and proteins related to the extracellular matrix remodeling²⁴ in the AH of subjects affected by glaucoma. Interestingly, our results indicate that this increase in TP was greater within the female group of glaucomatous patients, although the lower number of male patients could have biased these results (12 male vs. 20 female glaucomatous AH samples). Nevertheless, there is evidence that hormonal factors and, in particular, variations in estrogen levels over the lifetime of a woman may play a pathogenic role in glaucoma.²⁵ Indeed, Janciauskiene and colleagues¹⁰ found that women have significantly higher frequencies of detected inflammatory-related proteases in the AH compared to males, but whether female gender is a real risk factor for the ocular disease remains controversial. Certainly, there is an increased incidence of Alzheimer's disease cases in women compared to men, and this cannot simply depend on higher female longevity.²⁶ Of note, in this context, we found a significant positive correlation between A β_{42} and TP concentration in AH samples (Fig. D), although the amyloidogenic peptide did not increase within the glaucomatous group. Even if we cannot yet exclude the suggestion

that the increased TP in glaucomatous AH samples could be due to the increase of particular proteins, the number of specific proteins found to be augmented in glaucomatous AH would suggest the existence of a generic protein disequilibrium that may affect IOP.

In our study, pre-operative IOP was still slightly higher in glaucomatous patients, even if they did not stop anti-glaucoma treatments. Interestingly, a significant positive correlation was found between pre-operative IOP and TP concentration, further supporting the hypothesis that increased TP in AH may have a pathogenic role in glaucoma. Yet, from this point of view, the slight positive correlation found between pre-operative IOP and A β_{42} concentration (Table 2) could simply reflect the increase in TP.

On the other hand, the fact that all glaucomatous subjects were on pharmacological therapy represents a limitation in this study, and a validation of the observed phenomena in untreated glaucomatous patients would certainly allow a better understanding of their pathology.

In conclusion, although further studies on larger sample sizes are definitively needed, characterization of the AH protein profile in glaucomatous patients would help us to clarify whether the protein enhancement (1) represents a causative factor or is a disease consequence; (2) involves specific proteins, such as A β peptides; and (3) can be used as a marker of disease or as a novel therapeutic target.

Acknowledgments

This work was partially supported by the University of Genoa.

This work was developed within the framework of the DINOGMI Department of Excellence of MIUR 2018-2022 (legge 232 del 2016).

RR devised the study, analyzed the data, and wrote the manuscript. MI collected AH samples, analyzed the data, and critically revised the manuscript. FC collected and analyzed clinical data. FC performed ELISA, BCA assays, and statistical analyses. AM and CET collected AH samples. MM, VT, AM, and DS collected clinical data. All authors contributed to manuscript revisions and read and approved the submitted version.

Disclosure: **F. Cappelli**, None; **F. Caudano**, None; **M. Marengo**, None; **V. Testa**, None; **A. Masala**, None; **D. Sindaco**, None; **A. Macri**, None; **C.E. Traverso**, None; **M. Iester**, None; **R. Ricciarelli**, None

* FC and FC contributed equally to this article.

References

- Kingman S. Glaucoma is second leading cause of blindness globally. *Bull World Health Organ.* 2004;82:887–888.
- Li G, Luna C, Liton PB, Navarro I, Epstein DL, Gonzalez P. Sustained stress response after oxidative stress in trabecular meshwork cells. *Mol Vis.* 2007;13:2282–2288.
- Weber AJ, Chen H, Hubbard WC, Kaufman PL. Experimental glaucoma and cell size, density, and number in the primate lateral geniculate nucleus. *Invest Ophthalmol Vis Sci.* 2000;41:1370–1379.
- Gupta N, Ang LC, Noel de Tilly L, Bidaisee L, Yücel YH. Human glaucoma and neural degeneration in intracranial optic nerve, lateral geniculate nucleus, and visual cortex. *Br J Ophthalmol.* 2006;90:674–678.
- Quigley HA. Neuronal death in glaucoma. *Prog Retin Eye Res.* 1999;18:39–57.
- Ray K, Mookherjee S. Molecular complexity of primary open angle glaucoma: current concepts. *J Genet.* 2009;88:451–467.
- Parisi V, Restuccia R, Fattapposta F, Mina C, Bucci MG, Pierelli F. Morphological and functional retinal impairment in Alzheimer's disease patients. *Clin Neurophysiol.* 2001;112:1860–1867.
- Blanks JC, Torigoe Y, Hinton DR, Blanks RH. Retinal degeneration in the macula of patients with Alzheimer's disease. *Ann N Y Acad Sci.* 1991;640:44–46.
- Koronyo Y, Biggs D, Barron E, et al. Retinal amyloid pathology and proof-of-concept imaging trial in Alzheimer's disease. *JCI Insight.* 2017;2:93621.
- Janciauskiene S, Krakau T. Alzheimer's peptide and serine proteinase inhibitors in glaucoma and exfoliation syndrome. *Doc Ophthalmol.* 2003;106:215–223.
- Inoue T, Kawaji T, Tanihara H. Elevated levels of multiple biomarkers of Alzheimer's disease in the aqueous humor of eyes with open-angle glaucoma. *Invest Ophthalmol Vis Sci.* 2013;54:5353–5358.
- Zhang X, Parrish RK, 2nd, Greenfield DS, et al. Predictive factors for the rate of visual field progression in the advanced imaging for glaucoma study. *Am J Ophthalmol.* 2019;202:62–71.
- Goel M, Picciani RG, Lee RK, Bhattacharya SK. Aqueous humor dynamics: a review. *Open Ophthalmol J.* 2010;4:52–59.
- Izzotti A, Longobardi M, Cartiglia C, Sacca SC. Proteome alterations in primary open angle glaucoma aqueous humor. *J Proteome Res.* 2010;9:4831–4838.
- Adav SS, Wei J, Terence Y, Ang BCH, Yip LWL, Sze SK. Proteomic analysis of aqueous humor from primary open angle glaucoma patients on drug treatment revealed altered complement activation cascade. *J Proteome Res.* 2018;17:2499–2510.
- Yao J, Chen Z, Yang Q, et al. Proteomic analysis of aqueous humor from patients with branch retinal vein occlusion-induced macular edema. *Int J Mol Med.* 2013;32:1421–1434.
- De Simone L, Belloni L, Aldigeri R, et al. Aqueous tap and rapid diagnosis of cytomegalovirus anterior uveitis: the Reggio Emilia experience. *Graefes Arch Clin Exp Ophthalmol.* 2018;257:181–186.
- Guo L, Salt TE, Luong V, et al. Targeting amyloid-beta in glaucoma treatment. *Proc Natl Acad Sci USA.* 2007;104:13444–13449.
- Janciauskiene S, Westin K, Grip O, Krakau T. Detection of Alzheimer peptides and chemokines in the aqueous humor. *Eur J Ophthalmol.* 2011;21:104–111.
- Khalef N, Labib H, Helmy H, El Hamid MA, Moemen L, Fahmy I. Levels of cytokines in the aqueous humor of eyes with primary open angle glaucoma, pseudoexfoliation glaucoma and cataract. *Electron Physician.* 2017;9:3833–3837.
- Kokubun T, Tsuda S, Kunikata H, et al. Characteristic profiles of inflammatory cytokines in the aqueous humor of glaucomatous eyes. *Ocul Immunol Inflamm.* 2017;26:1177–1188.
- Duvesh R, Puthuran G, Srinivasan K, et al. Multiplex cytokine analysis of aqueous humor from the patients with chronic primary angle closure glaucoma. *Curr Eye Res.* 2017;42:1608–1613.
- Hondur G, Goktas E, Yang X, et al. Oxidative stress-related molecular biomarker candidates for glaucoma. *Invest Ophthalmol Vis Sci.* 2017;58:4078–4088.
- Nikhalashree S, George R, Shantha B, et al. Detection of proteins associated with extracellular matrix regulation in the aqueous humour of patients with primary glaucoma. *Curr Eye Res.* 2019;44:1018–1025.
- Tehrani S. Gender difference in the pathophysiology and treatment of glaucoma. *Curr Eye Res.* 2014;40:191–200.
- Vina J, Lloret A. Why women have more Alzheimer's disease than men: gender and mitochondrial toxicity of amyloid-beta peptide. *J Alzheimers Dis.* 2010;20(Suppl. 2):S527–S533.