



Case report

Step-up approach and video assisted retroperitoneal debridement in infected necrotizing pancreatitis: A case complicated by retroperitoneal bleeding and colonic fistula



Eugene Lim ^{a,*}, R.S. Sundaraamoorthy ^a, David Tan ^b, Hui-Seong Teh ^c, Tzu-Jen Tan ^a, Anton Cheng ^a

^a Department of Surgery, Khoo Teck Puat Hospital, 90 Yishun Central, Singapore 768828, Singapore

^b Department of Anaesthesia, Khoo Teck Puat Hospital, 90 Yishun Central, Singapore 768828, Singapore

^c Department of Radiology, Khoo Teck Puat Hospital, 90 Yishun Central, Singapore 768828, Singapore

HIGHLIGHTS

- Step-up approach consists of the 3 D's: Delay, Drain, Debride.
- VARD is generalizable in most surgical units using standard laparoscopic equipment.
- Defunctioning ileostomy diverts faecal stream and controls sepsis in colon fistula.
- Endoscopic clips and histoacryl glue may help to treat colo-cutaneous fistulas.

ARTICLE INFO

Article history:

Received 16 June 2015

Received in revised form

11 July 2015

Accepted 20 July 2015

Keywords:

Step-up approach

Video assisted retroperitoneal debridement

Minimally invasive necrosectomy

Colonic fistula

Endoscopy

ABSTRACT

Introduction: Infected Necrotizing Pancreatitis carries a high mortality and necessitates intervention to achieve sepsis control. The surgical strategy for proven infected necrosis has evolved, with abandonment of open necrosectomy to a step-up approach consisting of percutaneous drains and Video-assisted retroperitoneal debridement (VARD). We present a case that underwent VARD complicated by bleeding and colonic perforation and describe its management.

Presentation of case: A 38 year-old male with acute pancreatitis developed infected necrotizing pancreatitis. Initial treatment was by percutaneous drainage under radiological guidance and intravenous antibiotics. The infected retroperitoneal necrosis was then debrided using gasless laparoscopy through a mini-incision. Post-operatively, he developed peripancreatic bleeding which was controlled with angioembolisation. He also developed a descending colon fistula which was treated with laparotomy and defunctioning loop ileostomy. He recovered and subsequently had his ileostomy closed twelve months later. The colonic fistula recurred and was treated with endoscopic clips and histoacryl glue injection and finally closed.

Discussion: Step-up approach consists of the 3 D's: Delay, drain and debride. VARD is recommended as it is replicable in general surgical units using standard laparoscopic instruments. Bleeding and colon perforation are potential complications which must have multi-disciplinary input, aggressive resuscitation and timely radiologic intervention. Defunctioning ileostomy is recommended to control sepsis in colonic fistulation. Novel fistula closing methods using endoscopic clips and histoacryl glue are potential treatment options.

Conclusion: Step-up approach and VARD is the new paradigm to treat necrotizing pancreatitis. Complications of bleeding and colon fistula are uncommon and require multi-disciplinary management.

© 2015 The Authors. Published by Elsevier Ltd on behalf of IJS Publishing Group Limited. This is an open access article under the CC BY-NC-ND license (<http://creativecommons.org/licenses/by-nc-nd/4.0/>).

1. Introduction

Necrotizing Pancreatitis carries a high mortality rate of 15%. When necrotizing pancreatitis gets infected the mortality rate rises

* Corresponding author.

E-mail address: limkw2@yahoo.com (E. Lim).

to 39% [1], this necessitates intervention to achieve sepsis control. The surgical strategy for necrotizing pancreatitis has been evolving, with traditional open necrosectomy largely abandoned for the Step-up approach and minimally invasive necrosectomy [2]. We present our experience of a case of infected necrotizing pancreatitis treated with the Step-Up approach and Video-assisted Retroperitoneal Debridement (VARD) and discuss the management of subsequent retroperitoneal bleeding and colonic fistula.

2. Presentation of case

A 38 year-old man was admitted for acute pancreatitis secondary to alcohol and hypertriglyceridemia. He had a past history of essential hypertension not treated with medications. He presented with generalized abdominal pain without radiation for one day. He had stable vital signs and abdominal examination revealed tenderness in the epigastrium. His serum amylase was 436 U/L (normal < 100 U/L) and Lipase 1400 U/L (normal 5–50 U/L). Glasgow score was 2 on admission for leukocytosis and hypocalcaemia, CRP was 60.4 mg/L and Triglyceride level of 11.77 mmol/L. Abdominal contrast-enhanced computed tomography (CECT) scan showed diffuse enlargement of the pancreas and peripancreatic fluid without areas of non-enhancement. He was given targeted fluid resuscitation with crystalloids to achieve a urine output of 0.5 ml/kg/h. Subsequently, he was started on total parenteral nutrition as enteral feeding via nasogastric tube failed because of vomiting and abdominal distension. He continued to have Systemic Inflammatory Response Syndrome (SIRS) but blood cultures were negative. He was not started on antibiotics. 2 further CECT scans were performed at one week interval showed no acute necrotic collections. He was classified as moderately severe acute pancreatitis because of peripancreatic fluid collections. He improved clinically with decreasing CRP from a peak of 267 mg/L and resumed oral feeding and discharged himself after 3 weeks in hospital.

However, he was re-admitted 2 weeks later with sepsis and abdominal CT scan showed increased peripancreatic inflammatory changes, bilateral retroperitoneal walled-off necrosis with gas formation indicating infection (Fig. 1). He was started on antibiotics ceftriaxone and metronidazole and underwent radiological guided percutaneous drainage bilaterally. The percutaneous drains were sited on the flanks placed midway between the costal margin and the iliac crest into the retroperitoneal collection using 16Fr Skater catheter on the right and 14Fr on the left, avoiding intercostal vessels. The drains were flushed thrice daily. After 72 h, antibiotics were changed to piperacillin/tazobactam according to culture sensitivities, drain adjustment of position without upsizing and an additional 14Fr transrectal drain was performed because the retroperitoneal collection extended into the presacral space (Fig. 2). The drain microbiological cultures grew gram-negative organisms. After another 72 h, because there was no improvement of his sepsis as evidenced by increasing total white cell counts of $21 \times 10^9/L$ to $36 \times 10^9/L$, hypotension and a CECT scan done prior to VARD showed minimal decrease in retroperitoneal gas and fluid collections, decision was made to perform VARD. This was performed under General Anesthesia, with the patient in a supine position with left flank propped up by a cushion. A 5 cm incision on the left flank drain was made near to the percutaneous drain and deepened. Necrotic material was removed by aspiration and a 10 mm laparoscope was inserted into the retroperitoneal cavity through the incision without gas insufflation and a sponge holder forceps was used to debride the necrotic material under vision. A jet irrigation device (Pulsavac) was used to augment the debridement. There was minimal bleeding encountered and at the end of the procedure 2 Penrose drains were placed into the space superiorly and inferiorly and the fascia closed over (Fig. 3). The procedure was

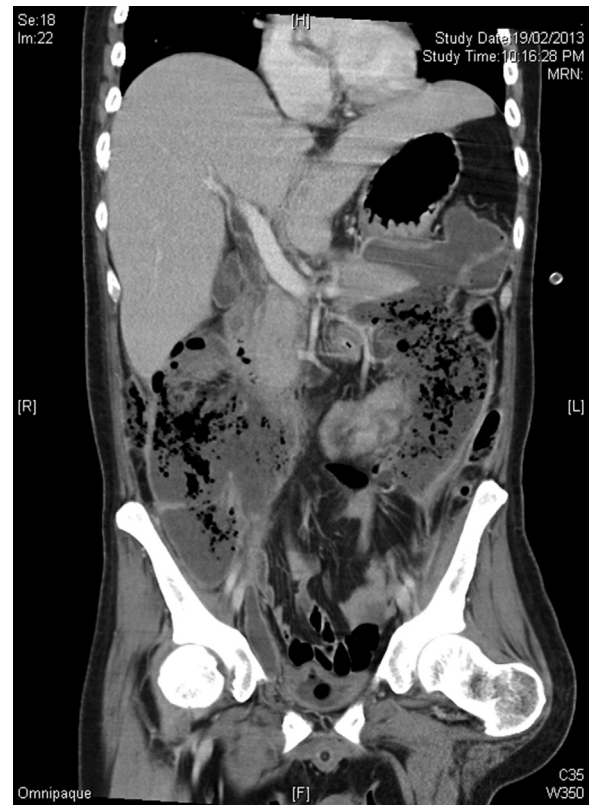

Fig. 1. CT scan showing gas formation and bilateral retroperitoneal peripancreatic necrosis.

repeated on the right side. The incisions were covered with a ureterostomy bag and continuous saline irrigation through the percutaneous drains was started at 200 ml per hour.

His sepsis improved (Fig. 4) but 2 days later he developed bleeding from both flanks and per rectal bleeding. CT angiogram

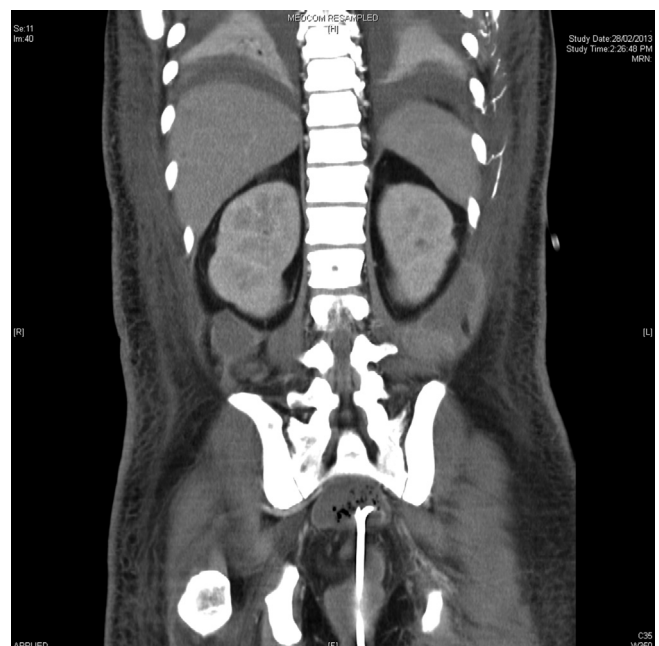

Fig. 2. Transrectal drain to presacral collection.

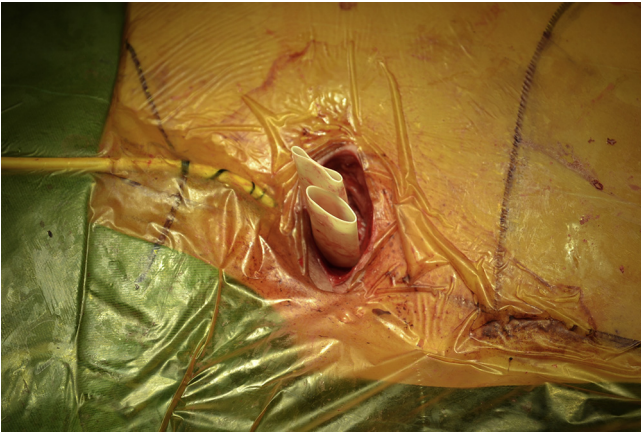


Fig. 3. Placement of Penrose drains at the end of procedure.

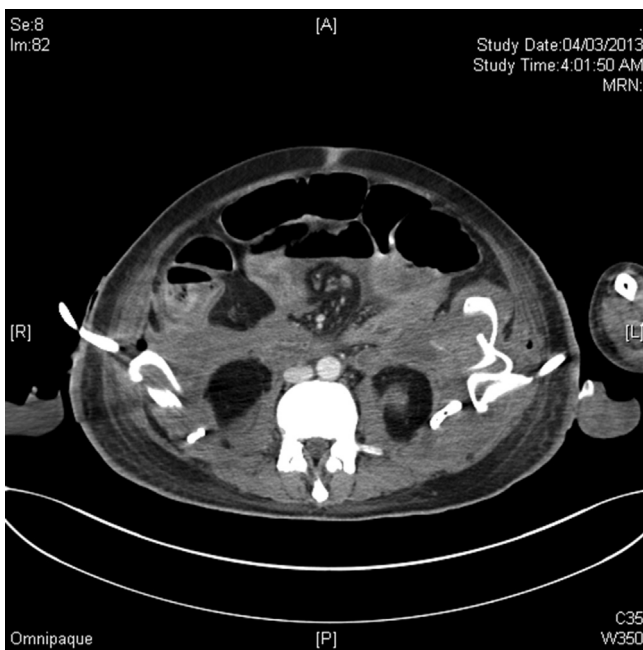


Fig. 4. Post VARD CT scan showing bilateral drains.

showed active contrast extravasation in the pancreatic bed and mesenteric angiogram showed the splenic artery to be in spasm but no active contrast extravasation, empiric mesenteric embolization of the splenic artery was then performed. He became coagulopathic and required massive blood product transfusions and Prothrombin Complex Concentrate (PCC) to correct. Feculent discharge from the left flank wound was noted concurrently, flexible sigmoidoscopy showed a perforation in the descending colon just distal to the splenic flexure. Hence, the initial per rectal bleeding was from the retroperitoneal bleed which entered the colonic perforation. He underwent a laparotomy with the aim to treat the colonic perforation by colon resection and stoma. However, the colon was densely adhered to the retroperitoneum and since there was no evidence of colonic ischemia or necrosis, a defunctioning loop ileostomy and omental patch of the colonic defect was performed.

Subsequently he had a tracheostomy and deep vein thrombosis involving the left common femoral and external iliac vein requiring a temporary inferior cava filter insertion. There were splenic infarcts noted on CECT evidenced by hypodensities in the spleen but

this was asymptomatic and repeat CECT scan after one year showed that the infarcted spleen had involuted. He spent 44 days in Surgical Intensive Care Unit. After 2 months from the VARD procedure, he recovered and was discharged. His hypertriglyceridemia was treated with Fenofibrate 300 mg daily and followed-up by an endocrinologist. He was able to stop alcohol completely. The ileostomy was closed after 12 months from the ileostomy creation after colonoscopy and gastrograffin enema examinations confirmed no leaks. However, 2 weeks after the operation he developed feculent discharge from the previous left flank wound site. The colo-cutaneous fistula was low output and initially treated conservatively for 6 months but did not close. Sigmoidoscopy then performed showed an internal opening in the descending colon and fistulogram showed the abnormal connection to the skin (**Fig. 5**). Histoacryl glue was injected percutaneously in an attempt to close the fistula (**Fig. 6**). However, the fistula recurred the next day. Another attempt one month later was made with endoscopic clips to close the internal opening and histoacryl glue applied externally, however, initially successful, this failed as well as he developed recurrence of the fistula a few days later. It was felt that the clip was not optimally applied and another attempt was planned. However the fistula closed spontaneously about 2 months later before another attempt was required. Review at 3 months confirmed that the fistula had closed.

3. Discussion

This case study illustrates the Step-up approach to pancreatic necrosis and the complexities of managing infected pancreatic necrosis. The Step-up approach can be regarded simplistically to consist of the 3 D's: Delay, Drain and Debride [3]. Delay of surgical debridement allows demarcation and 'walling-off' of necrotic tissue. Drainage of infected focus aims to treat the infected necrosis as an abscess, allowing a third of patients to avoid surgical debridement, which carries high risks. This can be performed percutaneously or endoscopically via a transgastric route. The choice depends on the location of the infected space and expertise available. In this patient, transgastric route was not possible as the necrosis affected

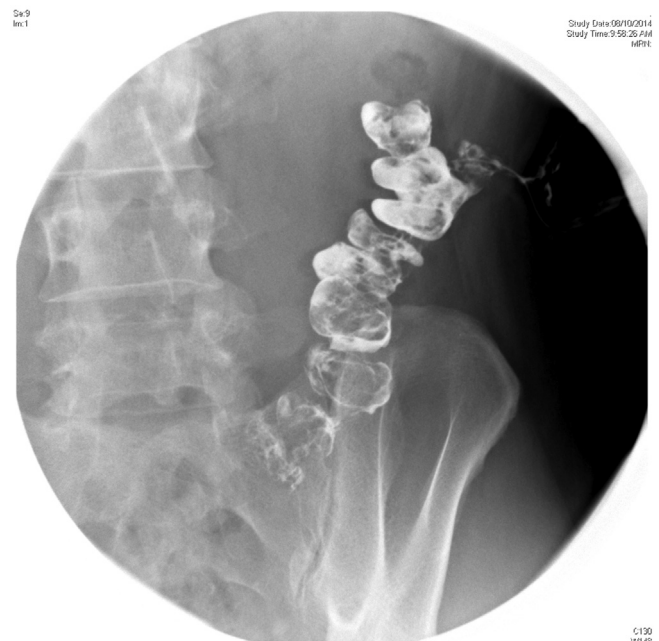

Fig. 5. Fistulogram of Descending colon fistula.

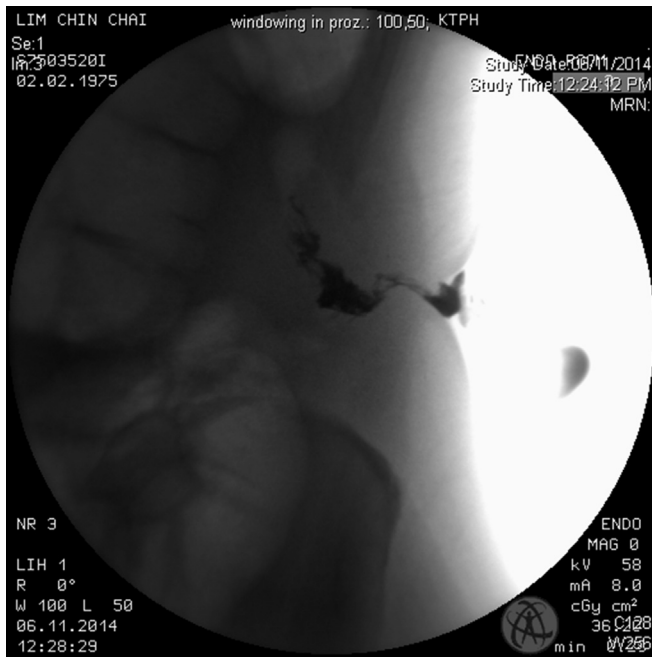

Fig. 6. Histoacryl glue with lipiodol injection into fistula tract.

the bilateral retroperitoneum with pelvic extension. Debridement when performed is done in a minimally invasive fashion, which reduces the surgical stress in an already physiologically compromised patient. In this case, we used a modification of the VARD procedure [4] where the incision was adjacent to the percutaneous drain, standard laparoscope was used without gas insufflation and the percutaneous drain was used post-operatively for continuous saline lavage. Collection of the lavage was through the penrose drains into a stoma bag connected to a container, which allowed for easy nursing. We feel that this method is replicable in most surgical units without the need for specialized instruments or expertise. Sinus tract endoscopy was considered an alternative to VARD but requires the use of urology instruments such as Amplatz dilators and a nephroscope. The principles of access and debridement remains essentially the same for VARD except the drain tract is followed under direct vision and laparoscopic instruments used which are more familiar to general surgeons.

The main complications encountered in this patient were post VARD bleeding and colonic perforation. Bleeding post VARD has an incidence of 16–20% [5,6]. In this case, CT angiography showed bleeding in the peripancreatic retroperitoneum. However, on mesenteric angiography, the splenic artery was in spasm without active contrast extravasation. Embolization of the splenic artery was performed, because bleeding was suspected to come from branches of the splenic artery and the most common site of bleeding or pseudoaneurysm in acute pancreatitis is from the splenic artery [7]. The use of PCC in coagulopathy was beneficial in this case. PCC together with FFP has been reported to lower INR quicker, decrease blood transfusions and mortality compared to FFP alone [8]. It is also less expensive than recombinant active Factor VII. To avoid bleeding complications, less aggressive debridement at the first operation is recommended which allows for the necrosis to liquefy and followed by subsequent debridement sessions [9]. We felt that the initial debridement may have been too aggressive as a jet irrigation device (Pulsavac) was used in addition to the forceps and advice against its use in the future. The limit to debridement requires surgical judgment.

Colon perforation is seen in 15% of cases post VARD [10]. There

are various hypotheses for the pathogenesis of colon perforation: broadly they can be classified into ischemic or iatrogenic [11,12]. Ischemia may be secondary to inflammation extending to the colon or hypotension affecting the watershed area of the colon around the splenic flexure, which happens to be the most common site of colon involvement. Iatrogenic causes may be due to drain erosion or direct procedural injury. The cause in this case is most likely due to localized ischemia resulting from peripancreatic inflammation, rather than drain erosion since soft Penrose drains were used. Treatment of the colonic perforation can either be resection or proximal diversion. Defunctioning ileostomy used in this case helped to control the ongoing contamination of fecal stream from the colonic perforation, and colon resection was not performed because the colon was viable at surgery and resection would have been hazardous in the presence of severe inflammation. Previous reports of colon resection may not be beneficial unless the colon is non-viable and may have contributed to higher mortality. Histopathologic examination of all 10 patients in the Aldridge series [11] who had colon resected because of suspected non-viability or perforation showed only 4 with ischemic necrosis and the other 6 had pericolicitis, with the authors commenting that resection may not have been necessary in some. The mortality rate was 60%. Hence, a defunctioning ileostomy is sufficient when the colon is viable.

After the ileostomy was closed, another problem of persistent colocutaneous fistula was encountered. Literature has reports of using histoacryl glue [13] and endoscopic clipping [14,15] to manage these fistulas, as spontaneous closure is uncommon. This is probably due to high colonic pressures in the left colon. Indeed, after each attempt of glue and clipping, the patient reported popping sounds which heralded the fistula recurrence. Furthermore, fistula output was less when the patient cleared his bowels frequently with the help of enemas. The use of histoacryl glue and endoscopic clipping to treat colon fistulas are novel approaches yet to be proven, but are low risk, inexpensive and repeatable. In our experience, preparation of the patient with adequate bowel preparation, followed by frequent bowel movement with enemas post treatment were helpful. Although the treatment success was not immediately evident as the fistula recurred, it probably hastened the recovery and closure of the tract.

4. Conclusion

This case illustrates the complexities of managing infected pancreatic necrosis and its complications. The Step-up approach and minimally invasive necrosectomy represents a new paradigm in treating pancreatic necrosis. The complications of post VARD bleeding and colonic fistulation are uncommonly encountered and the need for a multi-disciplinary and novel approach is recommended.

Ethical approval

NA.

Sources of funding

Nil.

Author contribution

Dr Eugene Lim: Study concept, data collection, writing the paper.

Dr Sundaraamoorthy RS: Study design.

Dr David Tan: Study concept.

Dr Teh Hui Seong: Study concept.
 Dr Tan Tzu-Jen: Study concept.
 Dr Anton Cheng: Study concept.

Conflict of interest

None declared.

Guarantor

Dr Eugene Lim.

References

- [1] G. Trikudanathan, R. Attam, M.A. Arain, S. Mallery, M.L. Freeman, Endoscopic interventions for necrotizing pancreatitis, *Am. J. Gastroenterol.* 109 (7) (2014 Jul) 969–981.
- [2] D.W. da Costa, D. Boerma, H.C. van Santvoort, K.D. Horvath, J. Werner, C.R. Carter, et al., Staged multidisciplinary step-up management for necrotizing pancreatitis, *Br. J. Surg.* 101 (1) (2014 Jan) e65–79.
- [3] M.G. Besselink, The 'step-up approach' to infected necrotizing pancreatitis: delay, drain, debride, *Dig. Liver Dis.* 43 (6) (2011 Jun) 421–422.
- [4] H.C. van Santvoort, M.G. Besselink, K.D. Horvath, M.N. Sinanan, T.L. Bollen, B. van Ramshorst, et al., Dutch acute pancreatitis study group. Videoscopic assisted retroperitoneal debridement in infected necrotizing pancreatitis, *HPB (Oxford)* 9 (2) (2007) 156–159.
- [5] H.C. van Santvoort, M.G. Besselink, O.J. Bakker, H.S. Hofker, M.A. Boermeester, C.H. DeJong, et al., Dutch Pancreatitis Study Group, A step-up approach or open necrosectomy for necrotizing pancreatitis, *N. Engl. J. Med.* 362 (16) (2010 Apr 22) 1491–1502.
- [6] D. Bausch, U. Wellner, S. Kahl, S. Kuesters, H.J. Richter-Schrag, S. Utzolino, et al., Minimally invasive operations for acute necrotizing pancreatitis: comparison of minimally invasive retroperitoneal necrosectomy with endoscopic transgastric necrosectomy, *Surgery* 152 (3 Suppl 1) (2012 Sep) S128–S134.
- [7] J. Kim, J.H. Shin, H.K. Yoon, G.Y. Ko, D.I. Gwon, E.Y. Kim, et al., Endovascular intervention for management of pancreatitis-related bleeding: a retrospective analysis of thirty-seven patients at a single institution, *Diagn Interv. Radiol.* 21 (2) (2015 Mar-Apr) 140–147.
- [8] B. Joseph, H. Aziz, V. Pandit, D. Hays, N. Kulvatunyou, Z. Yousuf, et al., Prothrombin complex concentrate versus fresh-frozen plasma for reversal of coagulopathy of trauma: is there a difference? *World J. Surg.* 38 (8) (2014 Aug) 1875–1881.
- [9] A.P. Wysocki, C.J. McKay, C.R. Carter, Infected pancreatic necrosis: minimizing the cut, *ANZ J. Surg.* 80 (1–2) (2010 Jan) 58–70.
- [10] S. Ulagendra Perumal, S.A. Pillai, S. Perumal, J. Sathyanesan, R. Palaniappan, Outcome of video-assisted translumbar retroperitoneal necrosectomy and closed lavage for severe necrotizing pancreatitis, *ANZ J. Surg.* 84 (4) (2014) 270–274.
- [11] M.C. Aldridge, N.D. Francis, G. Glazer, H.A. Dudley, Colonic complications of severe acute pancreatitis, *Br. J. Surg.* 76 (4) (1989) 362–367.
- [12] G.G. Tsiotos, C.D. Smith, M.G. Sarr, Incidence and management of pancreatic and enteric fistulas after surgical management of severe necrotizing pancreatitis, *Arch. Surg.* 130 (1) (1995 Jan) 48–52.
- [13] L. Cambj Sapunar, B. Sekovski, D. Matić, A. Tripković, L. Grandić, N. Družijanić, Percutaneous embolization of persistent low-output enterocutaneous fistulas, *Eur. Radiol.* 22 (9) (2012 Sep) 1991–1997.
- [14] P. Familiari, A. Macri, P. Consolo, L. Angiò, M.G. Scaffidi, C. Famulari, et al., Endoscopic clipping of a colcutaneous fistula following necrotizing pancreatitis: case report, *Dig. Liver Dis.* 35 (12) (2003 Dec) 907–910.
- [15] K. Ito, Y. Igarashi, T. Mimura, Y. Kishimoto, I. Kamata, S. Kobayashi, et al., Severe acute pancreatitis with complicating colonic fistula successfully closed using the over-the-scope clip system, *Case Rep. Gastroenterol.* 7 (2) (2013 Jul 23) 314–321.