

# Corneal shape changes after vitreoretinal surgery with fluid–gas exchange

Akira Watanabe, MD, PhD\*<sup>1</sup>, Wakana Ninomiya, PhD, Kei Mizobuchi, MD, PhD, Tomoyuki Watanabe, MD, Tadashi Nakano, MD, PhD

## Abstract

To investigate changes in the corneal shape caused by fluid–gas exchange after vitrectomy.

This retrospective case-control study included 43 eyes that underwent a combination of cataract surgery and vitrectomy. The corneal shape was measured using anterior segment optical coherence tomography CASIA2. The corneal shape measurements were performed preoperatively, 1 day, 1 week, 1 month, and 3 months after surgery. After calculating the real K value from the actual measured values of the posterior shape of the corneal refracting power and the single posterior corneal refracting power value, Fourier analysis values were examined. Fluid–gas exchange was performed in 23 eyes (gas group), while it was not performed in 20 eyes (nongas group).

There was a significant increase in the real K value in the regular and asymmetry components ( $0.61 \pm 0.36$ ,  $0.82 \pm 0.64$ ) in the gas group only on the first day after surgery (Steel–Dwass test;  $P < .05$ ). There was also a significant increase in the real K value in the higher-order irregular astigmatism components (Steel–Dwass test;  $P < .05$ ) for longer periods in the gas versus the nongas group. The shape of the posterior cornea increased in all components in the gas group on the first day after surgery (spherical power  $-6.35 \pm 0.20$ , regular astigmatism  $0.32 \pm 0.12$ , asymmetry  $0.22 \pm 0.13$ , and higher-order irregular astigmatism  $0.12 \pm 0.05$ , Steel–Dwass test;  $P < .05$ ).

Postoperative changes caused by surgical invasion in the corneal shape appeared to be greater in the gas versus the nongas group, in addition to affecting the time periods of the postoperative corneal shape changes.

**Abbreviation:** OCT = optical coherence tomography.

**Keywords:** anterior segment optical coherence tomography, corneal shape, fluid–gas exchange, postoperative change, vitreoretinal surgery

## 1. Introduction

In recent years, vitrectomy for retinal diseases has become less invasive due to the increased use of small incision cataract surgeries and vitrectomy systems. In association with this increased implementation of these methods, it has been shown that the anterior segment has little influence on the corneal shape after vitreoretinal surgery.<sup>[1–6]</sup> A small change in the corneal shape is known to contribute to early visual function recovery after surgery. However, in some complicated cases, additional multiple vitreous surgeries may be required. Changes have been observed in the corneal shape, corneal thickness, corneal

endothelium, and inflammation in the anterior chamber even during vitrectomy alone without any anterior chamber procedures.<sup>[3,7–11]</sup> Therefore, the degree of invasiveness associated with vitrectomy needs to be further evaluated.

Vitreous surgeries involve various procedures, which include laser photocoagulation, fluid–gas exchange, and inner limiting membrane peeling. In addition these procedures can vary depending on the disease or medical condition that is present. Moreover, increases in the number and intensity of procedures performed are expected to cause a greater surgical invasion. During vitreous surgery for macular hole and retinal detachment,

Editor: Rosa E. Alvarado-Villacorta.

The authors have no funding and conflicts of interest to disclose.

This study complied with the Declaration of Helsinki and was approved by the Ethics Committee of The Jikei University School of Medicine. (28–166[8409]).

All authors participating in this study have provided their consent for publication.

Informed consent was obtained from all individual participants included in the study.

The datasets generated during and/or analyzed during the current study are available from the corresponding author on reasonable request.

Department of Ophthalmology, The Jikei University School of Medicine, Tokyo, Japan.

\* Correspondence: Akira Watanabe, Department of Ophthalmology, The Jikei University School of Medicine, 3-25-8 Nishi-shinbashi, Minato-ku Tokyo 105-8461, Japan (e-mail: akirawahhka@gmail.com).

Copyright © 2022 the Author(s). Published by Wolters Kluwer Health, Inc.

This is an open access article distributed under the terms of the Creative Commons Attribution-Non Commercial License 4.0 (CCBY-NC), where it is permissible to download, share, remix, transform, and build up the work provided it is properly cited. The work cannot be used commercially without permission from the journal.

How to cite this article: Watanabe A, Ninomiya W, Mizobuchi K, Watanabe T, Nakano T. Corneal shape changes after vitreoretinal surgery with fluid–gas exchange. *Medicine* 2022;101:18(e29205).

Received: 11 June 2021 / Received in final form: 14 March 2022 / Accepted: 14 March 2022

<http://dx.doi.org/10.1097/MD.00000000000029205>

fluid–gas exchange is performed, with gas tamponade for the retina performed after the surgery. In patients undergoing fluid–gas exchange, it has been reported that there are greater changes in the corneal thickness after surgery in subjects who did not undergo fluid–gas exchange due to concerns related to the increased surgical invasion of the cornea.<sup>[8]</sup> Furthermore, Teke et al<sup>[12]</sup> reported finding changes in the corneal biological properties due to fluid–gas exchange performed during the vitrectomy. However, to the best of our knowledge there have yet to be any reports on how fluid–gas exchange affects the corneal shape after vitreous surgery.

In recent years, numerous corneal shape measuring apparatuses have been developed, including the Placido disk type corneal shape analysis, Scheimpflug-type corneal shape analysis, and anterior ocular optical coherence tomography (OCT).<sup>[3]</sup> Each corneal shape measuring apparatus has its own unique characteristics. As corneal shape measurements using anterior segment OCT are less affected by the condition of the tear film, this method is suitable for use in accurately measuring the postoperative corneal shape, since the postoperative tear film condition has been shown not to be stable.<sup>[13]</sup> Scheimpflug and anterior segment OCT for corneal shape analysis can be used to analyze the posterior shape of the cornea.<sup>[13–15]</sup> Using these methods makes it possible to perform more detailed measurements of the corneal shape changes. However, at the present time there have yet to be many reports that have analyzed the posterior corneal shape changes after vitrectomy.<sup>[3]</sup>

In our current study, we evaluated the changes in the corneal shape using anterior segment OCT in order to comprehensively examine whether fluid–gas exchange had an effect on the corneal shape after 25-gauge vitrectomy.

## 2. Methods

We reviewed the medical records of the 43 patients who underwent 25-gauge vitrectomy and phacoemulsification (2.4 mm scleral tunnel incision at 11 o'clock) during simultaneous surgery at The Jikei University School of Medicine Hospital between February 2017 and July 2018.

The purpose of this study was to statistically examine the effects of fluid–gas exchange on the corneal shape. Since 79% of the cases in our hospital utilized sutures, our evaluation only included data on sutured cases. In addition, eyes were excluded if they had a pre-existing corneal pathology, such as corneal dystrophy, corneal ectasia, and corneal infection, or if they had severe refractive error (more than  $-6$  diopters).

Surgeries were performed by 4 expert vitreous surgeons. The mean age of the patients was  $64 \pm 9$  years (range, 51–78 years). Surgery was performed for epiretinal membrane in 25 eyes and macular hole in 18 eyes. Fluid–gas exchange was performed in 23 eyes (gas group) with 20 eyes not undergoing the exchange (nongas group) (Table 1). Sulfur hexafluoride was used for endotamponade in the gas group. BSS Plus (Alcon Laboratories, Fort Worth, TX) was used for endotamponade in the nongas group. In all cases, internal limiting membrane peeling was performed using brilliant blue G. In the gas group, patients were instructed to maintain a prone position immediately after surgery and continue to do so for 3 or 4 days after surgery. All cataract surgeries were performed without sutures. At the end of the vitrectomy, if there was a slight leakage of intraocular fluid from the scleral wound, the scleral wound was sutured with 7-0 Vicryl (Ethicon Division, Johnson and Johnson, Somerville, NJ).

**Table 1**

### Baseline patient characteristics.

Number of cases	Gas group	Nongas group
	23	20
Age, yr		
Mean $\pm$ SD	65.3 $\pm$ 7.2	66.4 $\pm$ 5.4
Range age (yr)	51–75	55–78
<b>Diagnosis</b>	<b>ERM:5 MH:18</b>	<b>ERM:20</b>
Male, n (%)	13 (56.5%)	14 (70%)
Female, n (%)	10 (43.5%)	6 (30%)

ERM=epiretinal membrane, MH=macular hole, SD = standard deviation.

The difference in corneal shape preoperatively and after undergoing the simultaneous cataract vitreous surgery was compared between the 2 groups. The corneal shape measurements were performed preoperatively, 1 day, 1 week, 1 month, and 3 months after surgery.

The corneal shape was measured using anterior segment OCT, CASIA2 (Tomey, Nagoya, Japan). After calculating the real K value from the actual measured value of the posterior shape of the corneal refracting power and the single posterior corneal refracting power value, Fourier analysis values were then examined. The Fourier analyses were performed at the same 5 time points in order to extract the components for spherical power, regular astigmatism, asymmetry, and higher-order irregular astigmatism. Each item was examined preoperatively, 1 day, 1 week, 1 month, and 3 months after surgery (Fig. 1).

The study protocols were performed in accordance with the tenets set forth in the Declaration of Helsinki (1964). All study protocols were approved by the Ethics Committee of The Jikei University School of Medicine. Informed consent was obtained from all individual participants included in the study.

### 2.1. Statistical analyses

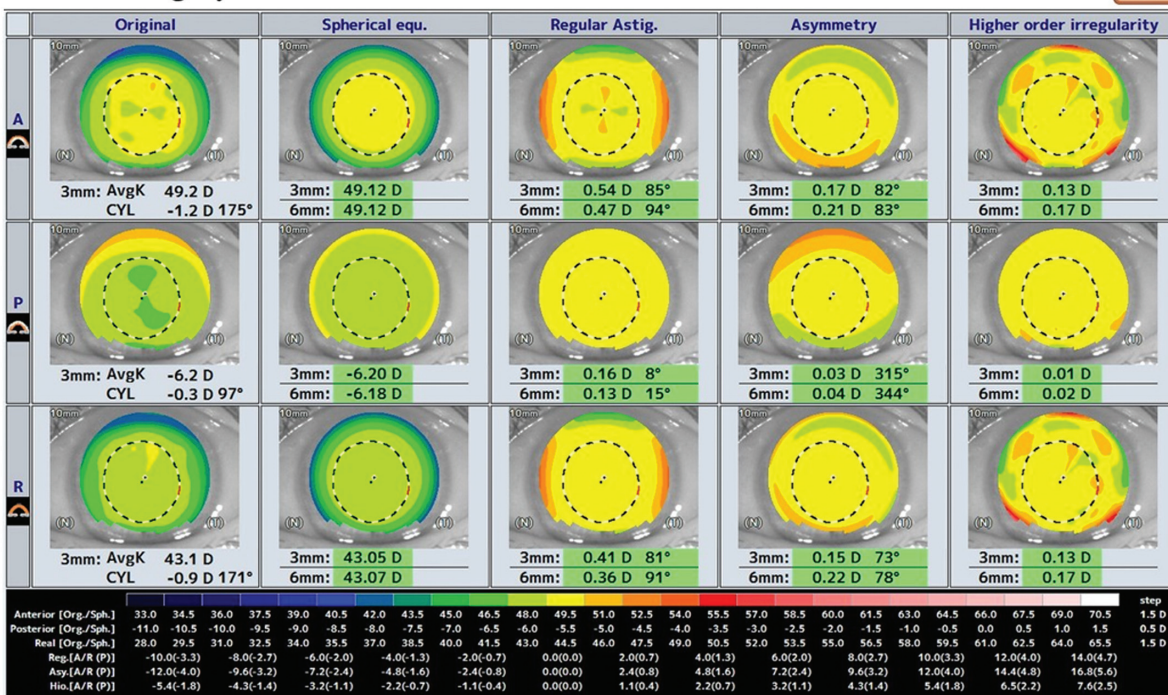
Statistical analyses were performed with software programmed by Hisae Yanai (Statcel-3; OMS Publication, Saitama, Japan) using Excel (Microsoft Corp., Redmond, WA). *P* values  $<.05$  were considered statistically significant. Comparisons of data were made using the Steel–Dwass test and Mann–Whitney *U* test.

## 3. Results

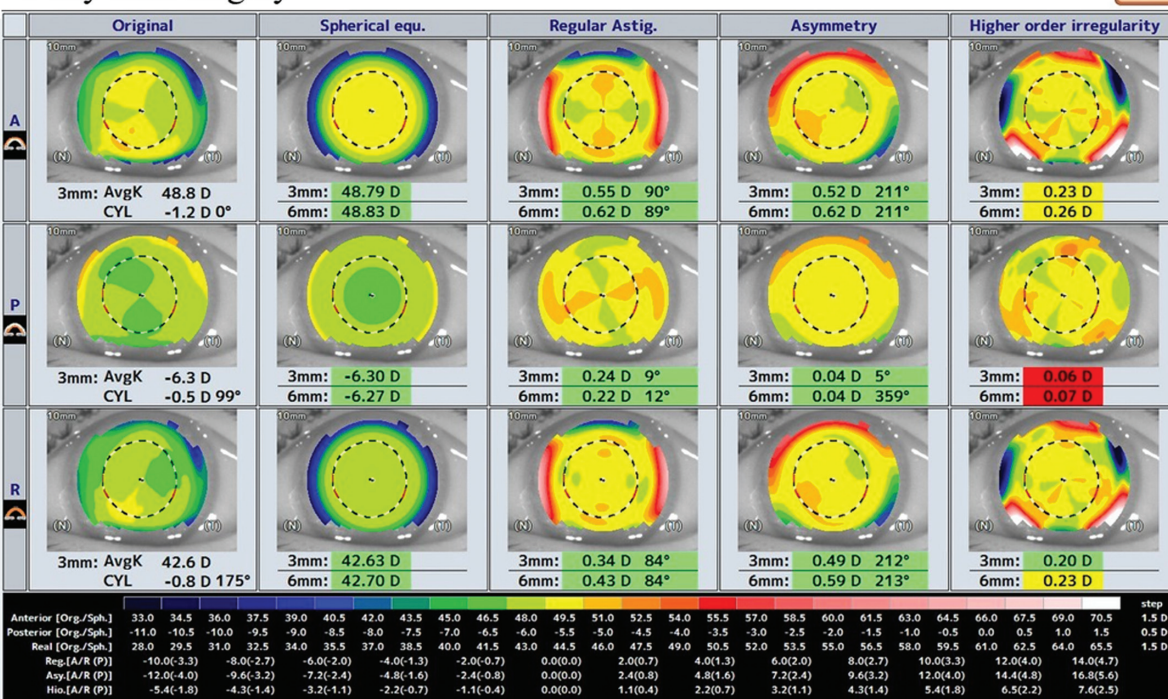
At the measurement range of 6 mm in the gas group, the regular astigmatism, asymmetry, and higher-order irregular astigmatism components in the real K value ( $0.61 \pm 0.36$ ,  $0.82 \pm 0.64$ ,  $0.28 \pm 0.10$ , respectively) were significantly increased at 1 day after surgery. Although the regular and asymmetric components were no longer significantly different at 1 week after the operation, the higher-order irregular astigmatism component was significantly increased for up to 1 month after the operation. The higher-order irregular astigmatism component returned to baseline levels at 3 months after the operation (Fig. 2).

In terms of the posterior corneal shape in the gas group, all components increased 1 day after surgery (spherical power  $-6.35 \pm 0.20$ , regular astigmatism  $0.32 \pm 0.12$ , asymmetry  $0.22 \pm 0.13$ , and higher-order irregular astigmatism  $0.12 \pm 0.05$ , Steel–Dwass test; *P*  $<.05$ ) compared to that observed preoperatively. With the exception for the higher-order irregular

before surgery



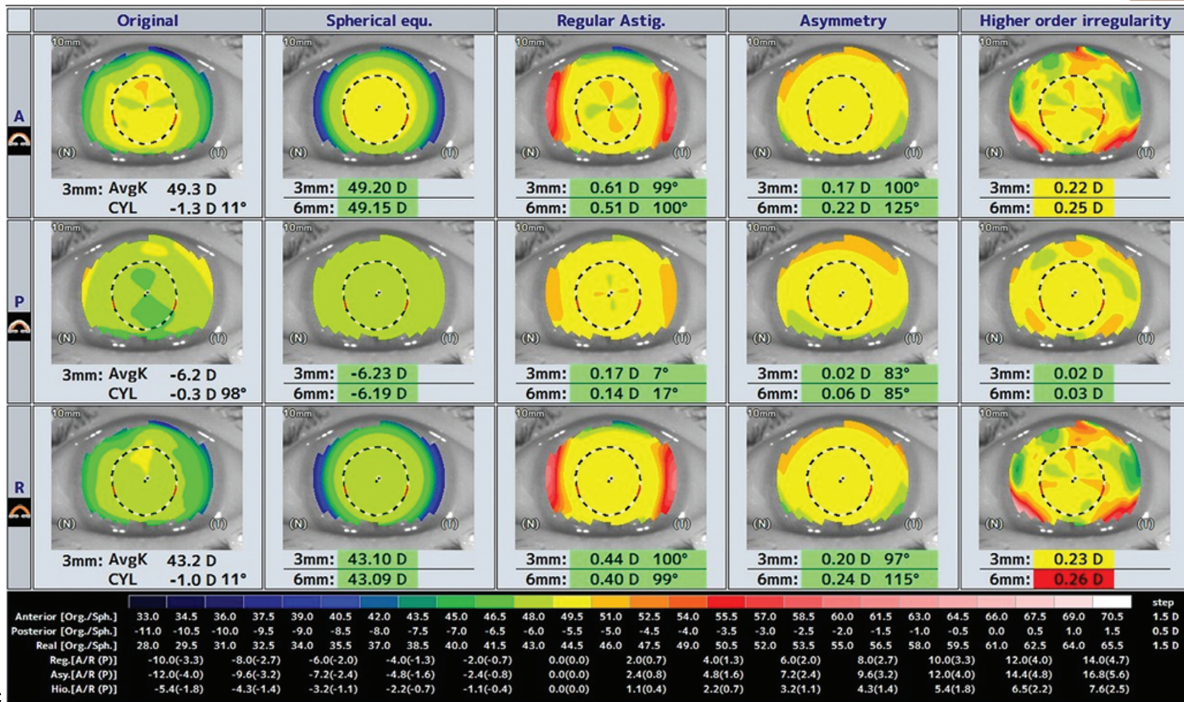
1 day after surgery



**Figure 1.** A representative case in the gas group. The Fourier analysis components for spherical power, regular astigmatism, asymmetry, and higher-order irregular astigmatism. (A) Preoperatively, (B) 1 d, (C) 1 wk, (D) 1 mo, and (E) 3 mo after surgery. 1 mo = 1 mo after vitrectomy, 1 wk = 1 wk after vitrectomy, 3 mo = 3 months after vitrectomy, pre = preoperatively.



1 week after surgery



1 month after surgery

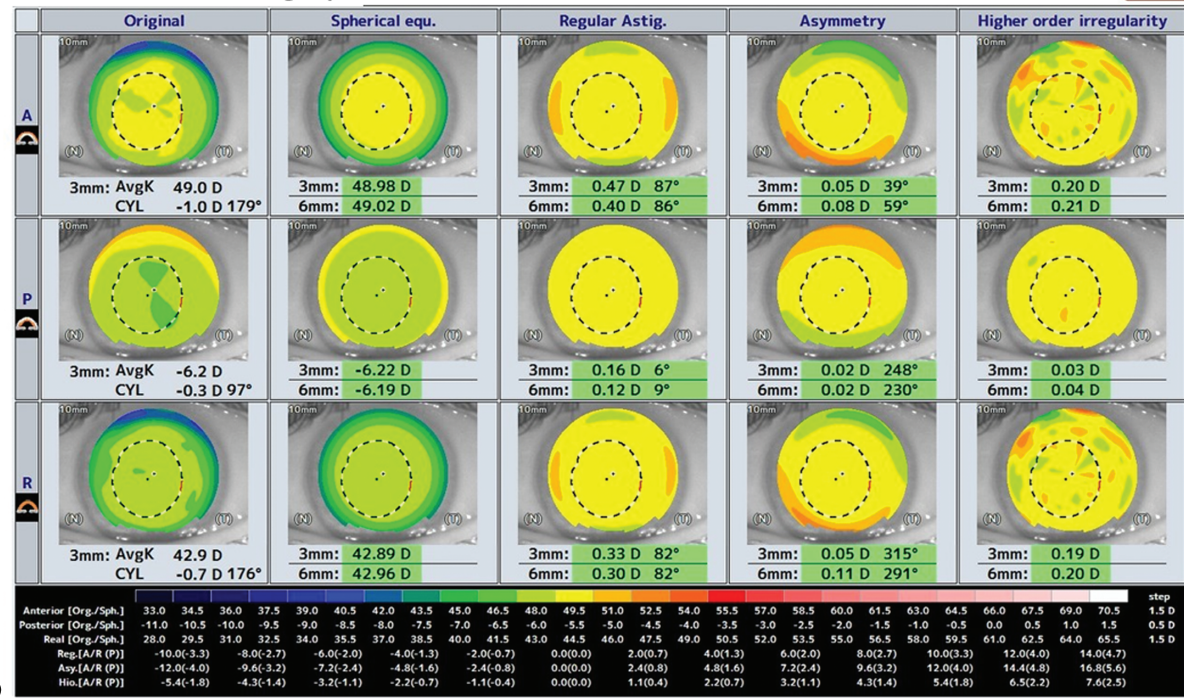


Figure 1. (Continued)



3 months after surgery

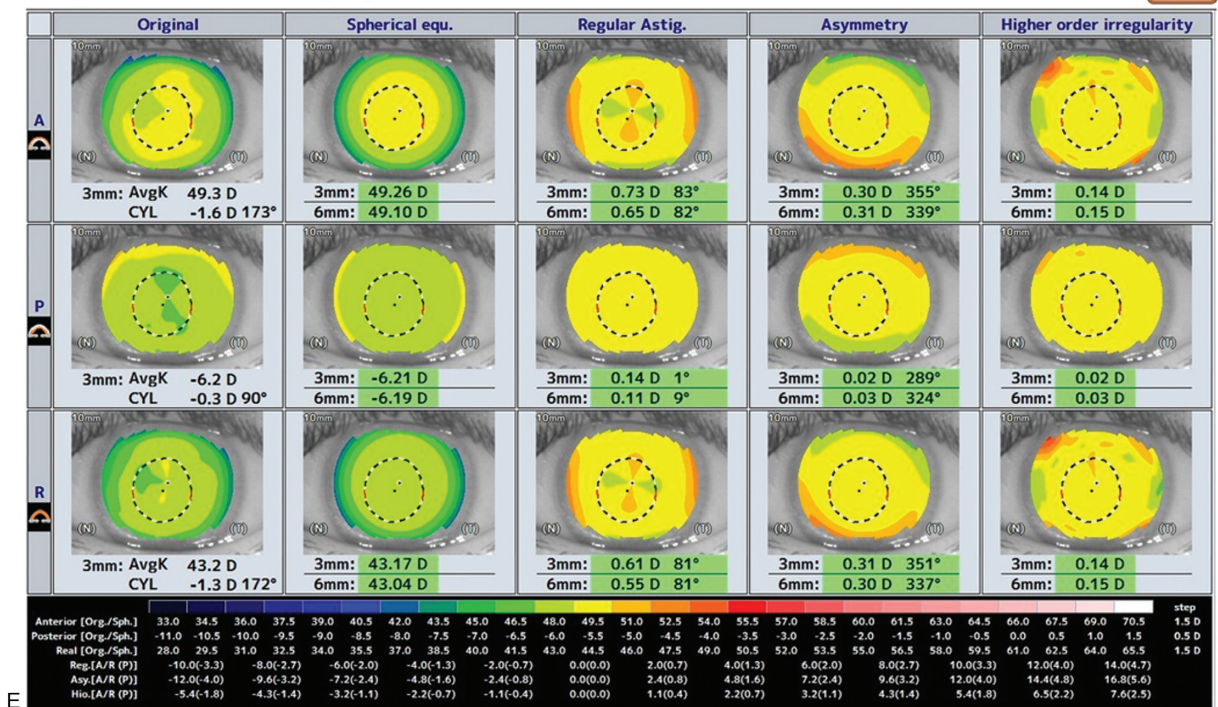


Figure 1. (Continued).

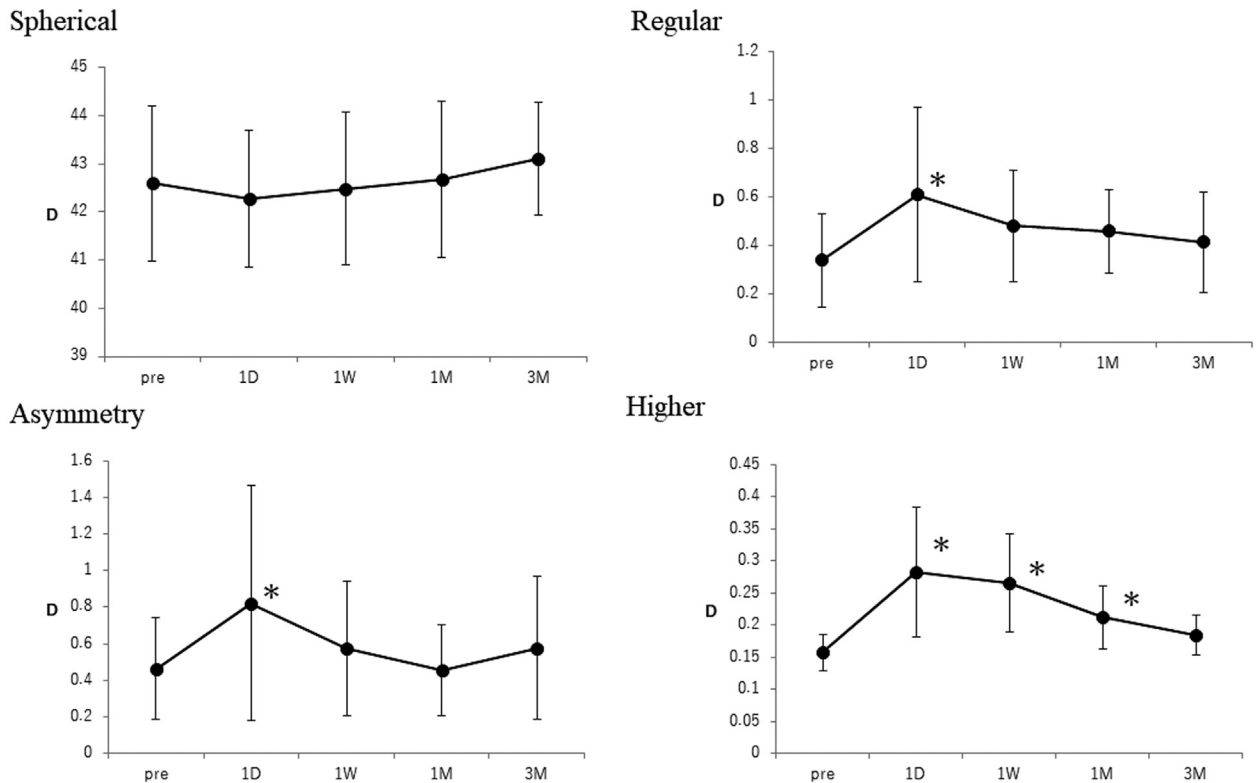
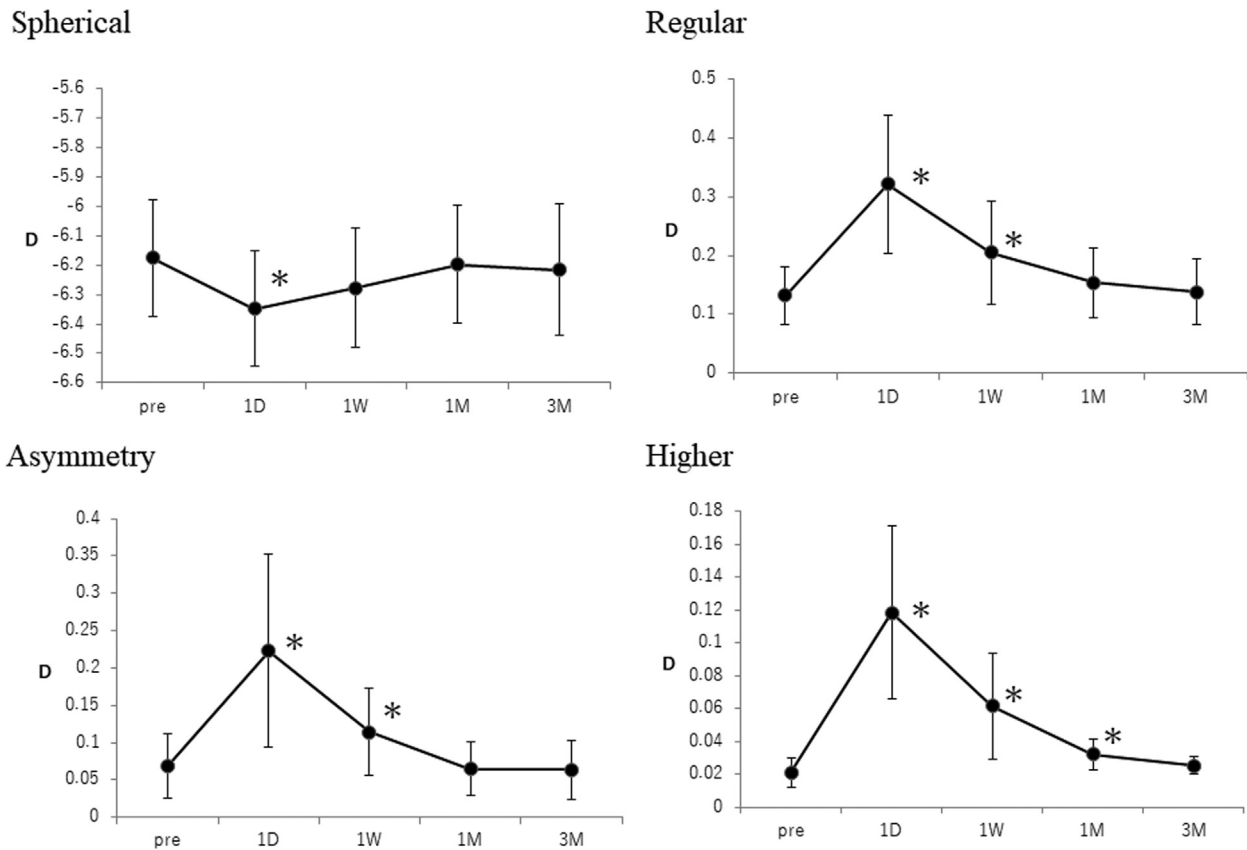


Figure 2. Real K value power (Real) at the measurement range of 6mm (mean ± standard deviation) in the gas group. 1M=1 mo after surgery, 1D=1 d after surgery, 1W=1 wk after surgery, 3M=3 mo after surgery, asymmetry=asymmetry, higher=higher-order irregular astigmatism, pre=before surgery, regular=regular astigmatism, spherical=spherical power. Steel-Dwass test; \**P* < .05 postoperative compared to preoperative values. Each *P* value shows the statistical difference from the preoperative values.



**Figure 3.** Posterior power at the measurement range of 6 mm (mean  $\pm$  standard deviation) in the gas group. 1 M = 1 mo after surgery, 1D = 1 d after surgery, 1W = 1 wk after surgery, 3M = 3 mo after surgery, asymmetry = asymmetry, higher = higher-order irregular astigmatism, pre = before surgery, regular = regular astigmatism, spherical = spherical power. Steel–Dwass test. \* $P < .05$  postoperative compared to preoperative values. Each  $P$  value shows the statistical difference from the preoperative values.

astigmatism component, there was no significant difference observed at 1 month after the operation. The higher-order irregular astigmatism component was not significantly different at 3 months after the operation (Fig. 3).

In the nongas group, the real K value significantly increased only in the higher-order irregular astigmatism component ( $0.31 \pm 0.11$ ) at 1 day after surgery as compared to that observed preoperatively. Changes in the higher-order irregular astigmatism component continued until 1 week after the surgery, with no significant difference found at 1 month after the surgery (Fig. 4).

The shape of the posterior cornea in the nongas group was significantly increased in the regular astigmatism, asymmetry, and higher-order irregular astigmatism components at 1 day after surgery ( $0.28 \pm 0.13$ ,  $0.26 \pm 0.27$ ,  $0.13 \pm 0.06$ , respectively. Steel–Dwass test;  $P < .05$ ). In the regular astigmatism and higher-order irregular astigmatism components ( $0.17 \pm 0.08$ ,  $0.06 \pm 0.03$ ), the shape of the posterior cornea was significantly increased at 1 week after surgery. Changes in the higher-order irregular astigmatism component continued until 1 month after the surgery (Fig. 5).

In the gas group, the change in the real K value of the higher-order irregular astigmatism component continued for a longer period as compared with the nongas group (Table 2).

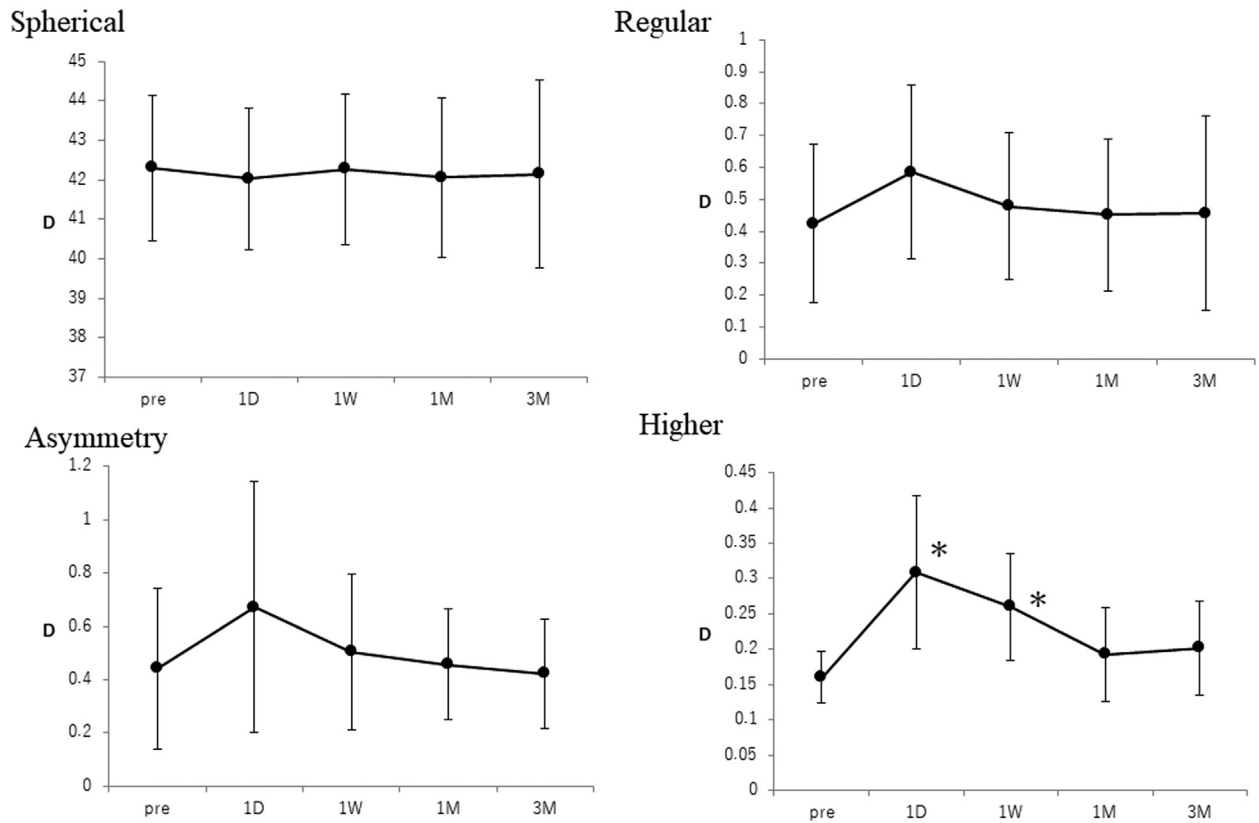
Changes in posterior corneal shape were observed in both groups at 1 day after surgery, with the changes continuing for a longer period in the gas versus the nongas group (Table 2).

There was no significant difference in the postoperative intraocular pressure as compared with that preoperatively in both the gas and nongas groups. The postoperative intraocular pressure was lower in the nongas versus the gas group at 3 months after the surgery (Fig. 6).

#### 4. Discussion

When using the conventional 20-gauge vitreous surgery system, incision, suturing, and scleral suturing of the conjunctiva are indispensable. However, it has been reported that the corneal shape changes after surgery.<sup>[16,17]</sup> In contrast, many other reports have stated that there were no changes in the postoperative corneal shape that occurred when using 23-, 25-, and 27-gauge small incision vitrectomy.<sup>[1–5]</sup> In our current study, changes in the higher-order irregular astigmatism component of the corneal shape were even transiently observed in the nongas group on the day after the operation. However, it should be noted that differences associated with the corneal shape measuring devices used may have contributed to this result. Ueno et al<sup>[18]</sup> reported that there was a difference between the calculated corneal refractive power, when assuming that the relationship between the anterior and posterior surfaces of the cornea was constant and that the total corneal refractive power was calculated from the measured values for both the anterior and posterior surfaces. The measurement principle of the corneal shape analyzer CASIA2



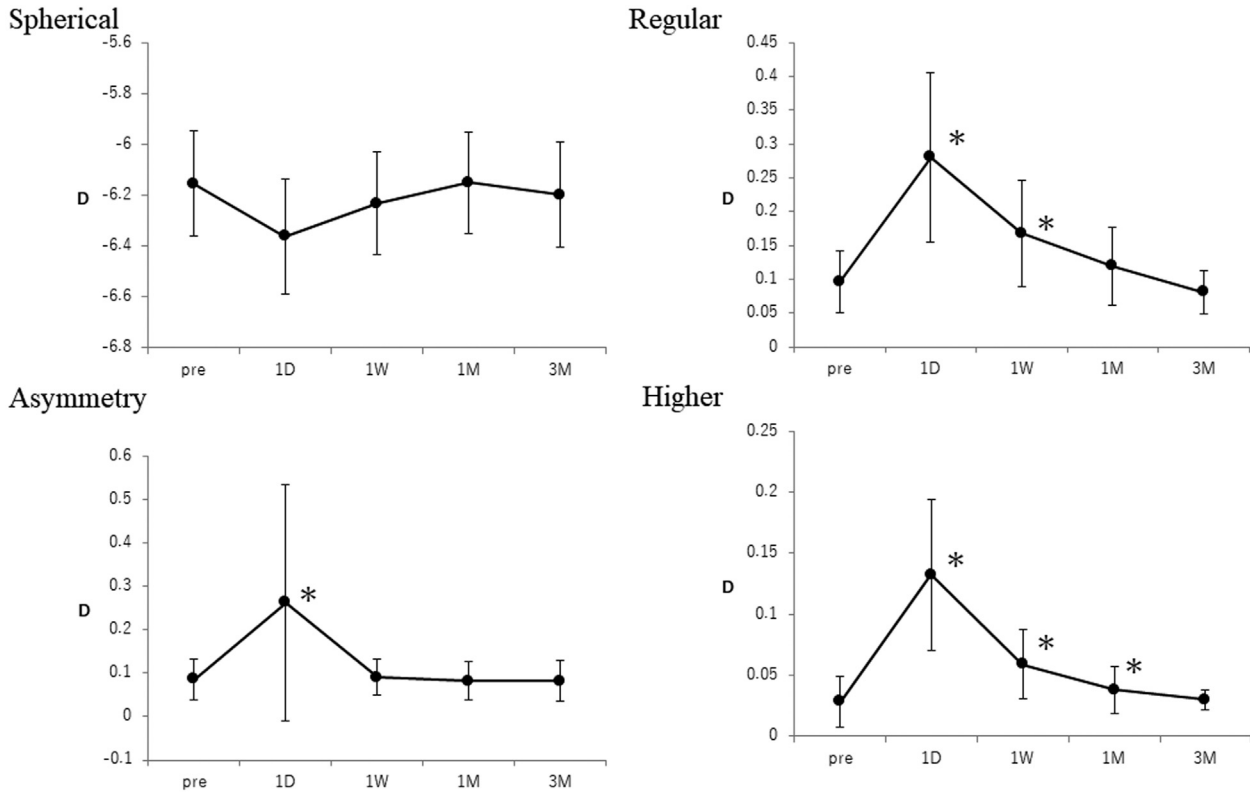


**Figure 4.** Axial power (Real) at the measurement range of 6 mm (mean ± standard deviation) in the nongas group. 1M=1 mo after surgery, 1D=1 d after surgery, 1W=1 wk after surgery, 3M=3 mo after surgery, asymmetry=asymmetry, higher=higher-order irregular astigmatism, pre=before surgery, regular=regular astigmatism, spherical=spherical power. Steel-Dwass test; \**P*<.05 postoperative compared to preoperative values. Each *P* value shows the statistical difference from the preoperative values.

that was used in this study is a Fourier-domain swept source OCT. The CASIA2 has a measurement range of 16 mm in diameter, 800 measurement points, and a measurement time of 0.3 seconds, which makes it possible to measure the shape of the posterior cornea.<sup>[13,19]</sup> The merits of corneal shape measurement with CASIA2 are that the measurement time is short, artifacts are less likely to occur, the shape of the posterior corneal shape can be measured, and the cornea is less susceptible to tears. This enables highly accurate corneal shape measurements to be performed.<sup>[13-15,20,21]</sup> In our current study, the use of the CASIA2 made it possible to detect detailed changes in the corneal shape on the day after the vitreoretinal surgery. Although previous existing studies have examined changes in the corneal shape at 1 week after surgery,<sup>[2-4]</sup> our current study examined early postoperative changes in the corneal shape at 1 day after surgery. Therefore, the detection of changes in the corneal shape after the surgery may have been due to our earlier examinations. In this current study, changes in the corneal shape in the gas group continued for a longer period as compared with the nongas group. Therefore, the postoperative changes in the corneal shape were considered to be greater in the gas versus the nongas group. It has been previously reported that corneal shape changes that occur after vitreous surgery may be due to scleral wound closure, changes in the intraocular pressure, and the effects of intraocular inflammation.<sup>[2,4,8,16,17]</sup>

In a study that used a 20-gauge vitreous surgery system for rhegmatogenous retinal detachment with gas replacement, the aqueous flare intensity after vitrectomy for retinal detachment was found to decrease to a stable level at 3 months postoperatively,

although it remained significantly higher as compared to the normal levels.<sup>[22]</sup> A multiple regression analysis revealed that the aqueous flare intensity at 3 months postoperatively was significantly correlated with the size of the retinal breaks and the number of laser photocoagulation spots. Furthermore, when there are increases in the surgical invasiveness, it is believed that the anterior chamber flare becomes stronger due to the destruction of the blood-retinal barrier. In our current study, we found that there was no significant difference in the postoperative intraocular pressure compared with that before surgery in both groups. Additionally, the scleral wound was sutured in all cases. Therefore, postoperative intraocular inflammation might have become stronger due to the increase in the surgical invasion due to the gas replacement, which affected the postoperative changes in the corneal shape. Park et al<sup>[23]</sup> pointed out the possibility that gas tamponade may affect surgically induced astigmatism. Although our previous study found no difference in the intraocular pressure with or without gas replacement, we did find that gas replacement affected the corneal shape.<sup>[24]</sup> We have also previously reported that the postoperative corneal thickness was greater in patients with gas replacement versus those without gas replacement. The decrease in corneal endothelial function due to postoperative anterior chamber inflammation was considered to be a possible reason for the increase in the postoperative corneal thickness.<sup>[8]</sup> In our current study, we also examined the posterior corneal shape. Our results showed that all components, and the regular astigmatism, asymmetry, and higher-order irregular astigmatism were changed on the day after the surgery in the nongas group.



**Figure 5.** Posterior power at the measurement range of 6 mm (mean ± standard deviation) in the nongas group. 1M = 1 mo after surgery, 1D = 1 d after surgery, 1W = 1 wk after surgery, 3M = 3 mo after surgery, asymmetry = asymmetry, higher = higher-order irregular astigmatism, pre = before surgery, regular = regular astigmatism, spherical = spherical power. Steel–Dwass test; \**P* < .05 postoperative compared to preoperative values. Each *P* value shows the statistical difference from the preoperative values.

**Table 2**  
**The foveal analysis components.**

GAS group				
Axial power (Real) 6 mm (mean ± standard deviation)				
	Spherical	Regular	Asymmetry	Higher
Pre	42.6 ± 1.6	0.34 ± 0.20 <sub>s</sub>	0.46 ± 0.28 <sub>s</sub>	0.16 ± 0.03 <sub>s</sub>
1D	42.3 ± 1.4	0.61 ± 0.36	0.82 ± 0.64	0.28 ± 0.10 <sub>s</sub>
1W	42.5 ± 1.6	0.48 ± 0.23	0.57 ± 0.37	0.27 ± 0.08 <sub>s</sub>
1M	42.7 ± 1.6	0.46 ± 0.17	0.46 ± 0.25	0.21 ± 0.05 <sub>s</sub>
3M	43.1 ± 1.2	0.41 ± 0.20	0.58 ± 0.39	0.18 ± 0.03 <sub>s</sub>
Posterior power 6 mm (mean ± standard deviation)				
	Spherical	Regular	Asymmetry	Higher
Pre	-6.18 ± 0.20	0.13 ± 0.05 <sub>s</sub>	0.07 ± 0.04 <sub>s</sub>	0.02 ± 0.01 <sub>s</sub>
1D	-6.35 ± 0.20	0.32 ± 0.12*	0.22 ± 0.13 <sub>s</sub>	0.12 ± 0.05 <sub>s</sub>
1W	-6.28 ± 0.20	0.21 ± 0.09 <sub>s</sub>	0.11 ± 0.06 <sub>s</sub>	0.06 ± 0.03 <sub>s</sub>
1M	-6.20 ± 0.20	0.15 ± 0.06	0.06 ± 0.04	0.03 ± 0.01*
3M	-6.22 ± 0.22	0.14 ± 0.06	0.06 ± 0.04	0.03 ± 0.01
Nongas group				
Axial power (Real) 6 mm (mean ± standard deviation)				
	Spherical	Regular	Asymmetry	Higher
Pre	42.3 ± 1.8	0.42 ± 0.25	0.44 ± 0.30	0.16 ± 0.04 <sub>s</sub>
1D	42.0 ± 1.8	0.59 ± 0.27	0.67 ± 0.47	0.31 ± 0.11 <sub>s</sub>
1W	42.3 ± 1.9	0.48 ± 0.23	0.50 ± 0.29	0.26 ± 0.08 <sub>s</sub>
1M	42.1 ± 2.0	0.45 ± 0.24	0.46 ± 0.21	0.19 ± 0.07 <sub>s</sub>
3M	42.2 ± 2.4	0.46 ± 0.31	0.42 ± 0.20	0.20 ± 0.07 <sub>s</sub>
Posterior power 6 mm (mean ± standard deviation)				
	Spherical	Regular	Asymmetry	Higher
Pre	-6.15 ± 0.21	0.10 ± 0.05 <sub>s</sub>	0.09 ± 0.05 <sub>s</sub>	0.03 ± 0.02 <sub>s</sub>
1D	-6.36 ± 0.23	0.28 ± 0.13 <sub>s</sub>	0.26 ± 0.27 <sub>s</sub>	0.13 ± 0.06 <sub>s</sub>
1W	-6.23 ± 0.20	0.17 ± 0.08 <sub>s</sub>	0.09 ± 0.04 <sub>s</sub>	0.06 ± 0.03 <sub>s</sub>
1M	-6.15 ± 0.20	0.12 ± 0.06	0.08 ± 0.04	0.04 ± 0.02 <sub>s</sub>
3M	-6.20 ± 0.21	0.08 ± 0.03	0.08 ± 0.05	0.03 ± 0.01

1M = 1 mo after surgery, 1D = 1 d after surgery, 1W = 1 wk after surgery, 3M = 3 mo after surgery, asymmetry = asymmetry, higher = higher-order irregular astigmatism, pre = before surgery, regular = regular astigmatism, spherical = spherical power, Steel–Dwass test; \**P* < .05 postoperative compared to preoperative values. Each *P* value shows the statistical difference from the preoperative values.

In terms of the real K value, that not all of the components were significantly changed on the day after surgery suggested that the analysis of the posterior corneal shape more sensitively reflected the invasiveness of the surgery.

A limitation of our current study was that it was a retrospective study. Furthermore, the numbers of cases in the gas replacement group and the nongas replacement group were not equal, and the total number of cases included in this study was small. Thus, a further prospective multicenter study will need to be undertaken. In our current study, as scleral wounds are often sutured in our hospital, it was decided to only evaluate cases with sutured scleral wounds. In further studies, the effects of gas replacement will need to be examined in detail by also including cases without sutures.

In conclusion, the postoperative changes caused by surgical invasion in the corneal shape were considered to be greater in the gas versus the nongas group and it was also considered that these changes affected the time periods observed for the postoperative corneal shape changes.

**Author contributions**

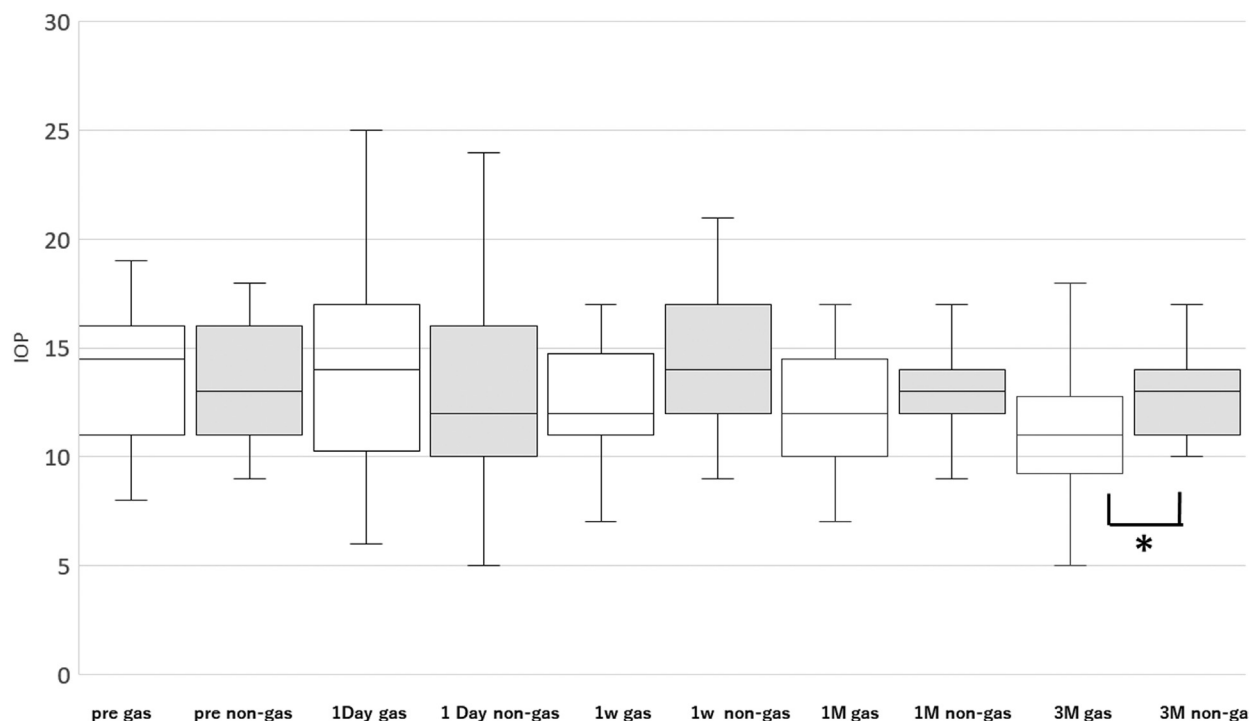
All authors read and approved the final manuscript.

**Conceptualization:** Akira Watanabe, Wakana Ninomiya, Kei Mizobuchi, Tomoyuki Watanabe, Tadashi Nakano.

**Data curation:** Wakana Ninomiya, Kei Mizobuchi, Tomoyuki Watanabe.

**Formal analysis:** Wakana Ninomiya, Kei Mizobuchi, Tomoyuki Watanabe.





**Figure 6.** Preoperative and postoperative IOP values (mm Hg). The serial changes in the mean intraocular pressure (IOP). The bars indicate the median, and the ends of the high–low line indicate the maximum and minimum values of the IOP. \* $P < .05$  Mann–Whitney  $U$  test significant difference in the intraocular pressure both the gas group and the nongas group. 1M=1 mo after surgery, 1D=1 d after surgery, 1W=1 wk after surgery, 3M=3 mo after surgery, asymmetry=asymmetry, higher=higher-order irregular astigmatism, pre=before surgery, regular=regular astigmatism, spherical=spherical power.

**Writing – original draft:** Akira Watanabe.

**Writing – review & editing:** Akira Watanabe, Wakana

Ninomiya, Kei Mizobuchi, Tomoyuki Watanabe, Tadashi Nakano.

## References

- [1] Yanyali A, Celik E, Horozoglu F, Nohutcu AF. Corneal topographic changes after transconjunctival (25-gauge) sutureless vitrectomy. *Am J Ophthalmol* 2005;140:939–41.
- [2] Okamoto F, Okamoto C, Sakata N, et al. Changes in corneal topography after 25-gauge transconjunctival sutureless vitrectomy versus after 20-gauge standard vitrectomy. *Ophthalmology* 2007; 114:2138–41.
- [3] Tekin K, Sonmez K, Inanc M, Ozdemir K, Goker YS, Yilmazbas P. Evaluation of corneal topographic changes and surgically induced astigmatism after transconjunctival 27-gauge microincision vitrectomy surgery. *Int Ophthalmol* 2018;38:635–43.
- [4] Hirashima T, Utsumi T, Hirose M, Oh H. Influences of 27-gauge vitrectomy on corneal topographic conditions. *J Ophthalmol* 2017;8320909doi: 10.1155/2017/8320909.
- [5] Shibata T, Watanabe A, Takashina H, Tsuneoka H. Effect on corneal shape of suturing the scleral wound during 23-gauge vitreous surgery. *Jpn J Ophthalmol* 2012;56:441–4.
- [6] Hassan H, Morten La C. Refractive changes after vitrectomy and phacovitrectomy for macular hole and epiretinal membrane. *J Cataract Refract Surg* 2013;39:942–7.
- [7] Paris GT, Bruce A, Miltiadis B. Comparison of postoperative refractive outcome in eyes undergoing combined phacovitrectomy vs cataract surgery following vitrectomy. *Graefes Arch Clin Exp Ophthalmol* 2020;258:987–93.
- [8] Watanabe A, Shibata T, Takashina H, Tsuneoka H. Changes in corneal thickness following combined cataract and vitreous surgery. *BMC Res Notes* 2015;8:1676–9.
- [9] Koushan K, Mikhail M, Beattie A, et al. Corneal endothelial cell loss after pars plana vitrectomy and combined phacoemulsification–vitrectomy surgeries. *Can J Ophthalmol* 2017;52:4–8.
- [10] Coman Cernat CC, Malita D, Stanca S, et al. Corneal endothelial changes induced by pars plana vitrectomy with silicone oil tamponade for retinal detachment. *Exp Ther Med* 2021;22:961.
- [11] Watanabe A, Shibata T, Takashina H, Ogawa S, Tsuneoka H. Changes in corneal thickness following vitreous surgery. *Clin Ophthalmol* 2012;6:1293–6.
- [12] Teke MY, Elgin U, Sen E, Ozdal P, Ozturk F. Early effects of pars plana vitrectomy combined with intravitreal gas tamponade on corneal biomechanics. *Ophthalmologica* 2013;229:137–41.
- [13] Shoji T, Kato N, Ishikawa S, et al. In vivo crystalline lens measurements with novel swept-source optical coherence tomography: an investigation on variability of measurement. *BMJ Open Ophth* 2017;1:e000058.
- [14] Schröder S, Mäurer S, Eppig T, et al. Comparison of corneal tomography: repeatability, precision, misalignment, mean elevation, and mean pachymetry. *Curr Eye Res* 2018;43:709–16.
- [15] Chan TCY, Biswas S, Yu M, Jhanji V. Comparison of corneal measurements in keratoconus using swept-source optical coherence tomography and combined placido-scheimpflug imaging. *Acta Ophthalmol* 2017;95:e486–94.
- [16] Grandinetti AA, Kniggenndorf V, Moreira LB, Moreira JCA, Moreira ATR. A comparison study of corneal topographic changes following 20-, 23-, and 25-G pars plana vitrectomy. *Arq Bras Oftalmol* 2015;78:283–5.
- [17] Shao Y, Dong LJ, Zhang Y, et al. Surgical induced astigmatism correlated with corneal pachymetry and intraocular pressure: transconjunctival sutureless 23-gauge versus 20-gauge sutured vitrectomy in diabetes mellitus. *Int J Ophthalmol* 2015;8:528–33.
- [18] Ueno Y, Hiraoka T, Miyazaki M, Ito M, Oshika T. Corneal thickness profile and posterior corneal astigmatism in normal corneas. *Ophthalmology* 2015;122:1072–8.
- [19] Chansangpetch S, Nguyen A, Mora M, et al. Agreement of anterior segment parameters obtained from swept-source Fourier-domain and time-domain anterior segment optical coherence tomography. *Invest Ophthalmol Vis Sci* 2018;59:1554–61.
- [20] Jhanji V, Yang B, Yu M, Ye C, Leung CKS. Corneal thickness and elevation measurements using swept-source optical coherence tomography and slit scanning topography in normal and keratoconic eyes. *Clin Experiment Ophthalmol* 2013;41:735–45.

- [21] Szalai E, Berta A, Hassan Z, Módos JL. Reliability and repeatability of swept-source Fourier-domain optical coherence tomography and Scheimpflug imaging in keratoconus. *J Cataract Refract Surg* 2012; 38:485–94.
- [22] Hoshi S, Okamoto F, Hasegawa Y, et al. Time course of changes in aqueous flare intensity after vitrectomy for rhegmatogenous retinal detachment. *Retina* 2012;32:1862–7.
- [23] Park DH, Shin JP, Kim SY. Surgically induced astigmatism in combined phacoemulsification and vitrectomy; 23-gauge transconjunctival sutureless vitrectomy versus 20-gauge standard vitrectomy. *Graefes Arch Clin Exp Ophthalmol* 2009;247:1331–7.
- [24] Watanabe T, Gekka T, Watanabe A, Nakano T. Analysis of changes in corneal topography after 27-gauge transconjunctival microincision vitrectomy combined with cataract surgery. *J Ophthalmol* 2019;2019:9658204.