




Taibah University

Journal of Taibah University Medical Sciences

www.sciencedirect.com



Case Report

The invasive *Klebsiella pneumoniae* syndrome: Case series

Radthiga Chelvaraj, MBBS^b, Tinesh Thamotaran, MD^b,
Cheong M. Yee, MS (Ophthal)^a, Chong M. Fong, MS (Ophthal)^a,
Ngoo Q. Zhe, MMed(Ophthal)^b and Yaakub Azhany, MMed (Ophthal)^{b,*}

^a Department of Ophthalmology, Hospital Raja Permaisuri Bainun, Jalan Hospital, Ipoh, Malaysia

^b Department of Ophthalmology and Visual Sciences, School of Medical Sciences, Universiti Sains Malaysia, Malaysia

Received 1 June 2021; revised 12 October 2021; accepted 20 October 2021; Available online 27 November 2021



المخلص

تهدف سلسلة الحالات هذه لعرض ثلاث حالات لالتهاب باطن المقلة ذاتية النمو الناتجة عن متلازمة العنوية الرئوية الغزوية.

الحالة ١: سيدة تبلغ من العمر ٣٤ عاما أدخلت بالتهاب رئوي وتعرضت لضبابية مؤلمة في الرؤية واحمرار في العين اليمنى لمدة أسبوع. أظهر فحص حدة البصر في العين اليمنى إحساسا خفيفا بالضوء مع عيب حدقي واردة نسبي إيجابي، وجحوظ، وتقييد حركة خارج العين وغمير قبيحي. تم علاج التهاب العين اليمنى الشامل مع خراج الرئة لدى المريضة وبدأت على المضادات الحيوية المجموعية والموضعية. نمت مزرعة الجسم الزجاجي العنوية الرئوية. بالرغم من العلاج، تدهورت حالة المريضة، وتم استئصال العين.

الحالة ٢: حضرت سيدة تبلغ من العمر ٣٨ عاما تعاني من ألم مفاجئ في العين اليمنى مع ضبابية في الرؤية، احمرار لمدة يومين، وحمي لمدة أسبوع. كانت حدة البصر للعين اليمنى هي حركة اليد مع عيب حدقي واردة نسبي إيجابي وخلايا غرفة العين الأمامية +٢. أظهر فحص بي كتلة تحت الشبكية على شكل قبة مع انفصال الشبكية النضحي. تم علاج المريضة بالتهاب العين اليمنى الشامل الذي تعقد بمضاعفات خراج العقد القاعدية. نمت مزرعة البول والجسم الزجاجي العنوية الرئوية. استجابت المريضة لجرعة عالية من المضادات الحيوية عن طريق الوريد وداخل الجسم الزجاجي. للأسف، أصبحت العين اليمنى فاقدة للوظيفة.

الحالة ٣: حضرت سيدة تبلغ من العمر ٧٠ عاما مع ضبابية غير مؤلمة في الرؤية على العين اليمنى. أظهرت مزرعة الدم والبول بكتيريا العنوية الرئوية. كانت حدة البصر للعين اليمنى هي إحساس خفيف للضوء، وتم علاجها بالتهاب

باطن المقلة ذاتية النمو. نمت مزرعة الجسم الزجاجي العنوية الرئوية. للأسف، أصبحت العين اليمنى فاقدة للوظيفة.

يتضح من الحالات المذكورة أن التهاب باطن المقلة الناتج عن العنوية الرئوية يعتبر غزويا ويحمل نذيرا سينا إذا لم يتم تقديم العلاج الفوري.

الكلمات المفتاحية: العنوية الرئوية؛ خراج الكبد؛ التهاب باطن المقلة؛ التهاب العين الشامل؛ خراج العقد القاعدية

Abstract

This case-series aims to report three cases of endogenous endophthalmitis due to invasive *Klebsiella pneumoniae* syndrome.

Case 1: A 34-year-old lady who was admitted for pneumonia developed painful blurring of vision and redness in the right eye (RE) for one week. An examination of the RE revealed visual acuity (VA) of light perception (PL) with positive relative afferent pupillary defect (RAPD), proptosis, and restriction of extraocular movement with hypopyon. The patient was treated for RE panophthalmitis with a lung abscess and was started on systemic and topical antibiotics. The vitreous tap culture grew *Klebsiella pneumoniae*. Despite treatment, the patient's condition deteriorated, and evisceration was undertaken.

Case 2: A 38-year-old lady presented with a acute onset of RE pain associated with blurred vision and redness for two days, and fever for one week. RE VA was hand movement with a positive RAPD and anterior chamber cells of 2+. A B-scan revealed a dome-shaped subretinal mass with exudative retinal detachment. The patient was treated for RE panophthalmitis complicated by a basal ganglia abscess. The urine and vitreous tap cultures grew *Klebsiella pneumoniae*. She responded to high-dose

* Corresponding address: Department of Ophthalmology and Visual Sciences, School of Medical Sciences, Universiti Sains Malaysia, 16150 Kubang Kerian, Kelantan, Malaysia.

E-mail: azhany@usm.my (Y. Azhany)

Peer review under responsibility of Taibah University.



Production and hosting by Elsevier

intravenous and intravitreal antibiotics. Unfortunately, her RE became phthisical.

Case 3: A 70-year-old lady presented with painless blurring of vision over the RE. The blood and urine cultures grew *Klebsiella pneumoniae*. RE VA was PL, and she was treated for endogenous endophthalmitis. The vitreous culture grew *Klebsiella pneumoniae*. Unfortunately, the RE became phthisical.

Keywords: Basal ganglia abscess; Endophthalmitis; *Klebsiella pneumoniae*; Liver abscess; Panophthalmitis

© 2022 Taibah University.

Production and hosting by Elsevier Ltd. This is an open access article under the CC BY-NC-ND license (<http://creativecommons.org/licenses/by-nc-nd/4.0/>).

Introduction

Klebsiella pneumoniae is a gram-negative, nonencapsulated, anaerobic bacterium that forms part of the normal nasopharyngeal and gut flora. It is a bacterium with a high rate of antibiotic resistance. Notably, *Klebsiella pneumoniae* has dominated the microbiological spectrum of endogenous endophthalmitis in East Asia.¹ Often, endogenous endophthalmitis caused by *Klebsiella pneumoniae* leads to devastating outcomes due to its increased affinity for crossing the blood ocular barrier. Despite its increasing incidence, infection is commonly misdiagnosed and undertreated with a common group of antibiotics. The hypervirulent strain of *Klebsiella pneumoniae* is often associated with rapid dissemination; hence, a more potent antibiotic, such as ceftriaxone, should be initiated early. Detailed investigations are not routinely performed in isolated cases of endophthalmitis because we perceive that endophthalmitis is confined to the intraocular region only. Here, we highlight *Klebsiella pneumoniae* as a secondary nidus of hypervirulent *Klebsiella pneumoniae* metastatic spread. Conversely, patients who are diagnosed with *Klebsiella* septicaemia may harbour infection in multiple organs. We aim to demonstrate the importance of prompt diagnosis and early treatment of metastatic *Klebsiella* endophthalmitis in patients presenting with painful red eye associated with fever.

Materials and Methods

Three retrospective case series were collected from Hospital Raja Permaisuri Bainun, Ipoh, Malaysia. Ethical approval by Ministry of Health, Malaysia and patients consent were obtained prior. Ethical approval number NMRR-21-402-59110.

Results

Case 1

A 34-year-old woman with poorly controlled diabetes mellitus presented with painful blurring of vision and redness

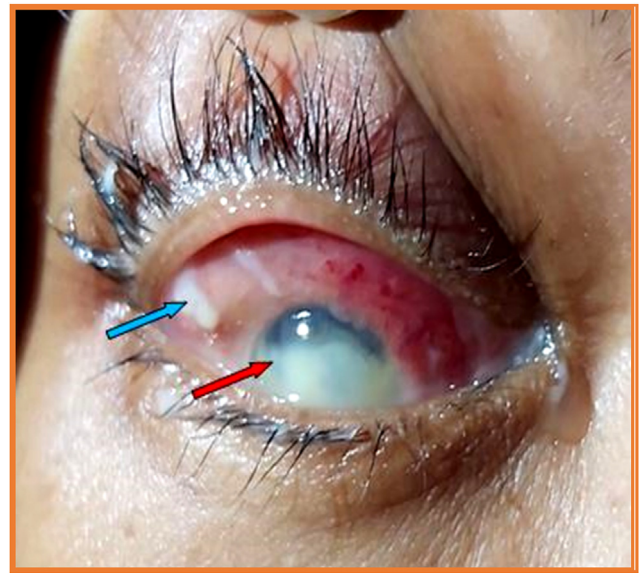

Figure 1: Presence purulent discharge, subtotal hypopyon (red arrow) with scleral abscess (blue arrow).

in the right eye (RE) for one week. She was treated for pneumonia after presenting with fever and lethargy a week prior to the ocular symptoms that warranted admission. However, the patient refused and was discharged with oral erythromycin 800 mg twice daily (BD). Upon presentation to the eye clinic, the visual acuity (VA) was light perception (PL) RE and 6/9 left eye (LE). Examination of the RE showed positive RAPD, proptosis, swollen eyelid, injected conjunctiva, and chemosis. The cornea was oedematous with dilated pupil. There was fibrin and a streak of hypopyon in the anterior chamber. The intraocular pressure (IOP) of both eyes was normal. Extraocular movement of the RE was

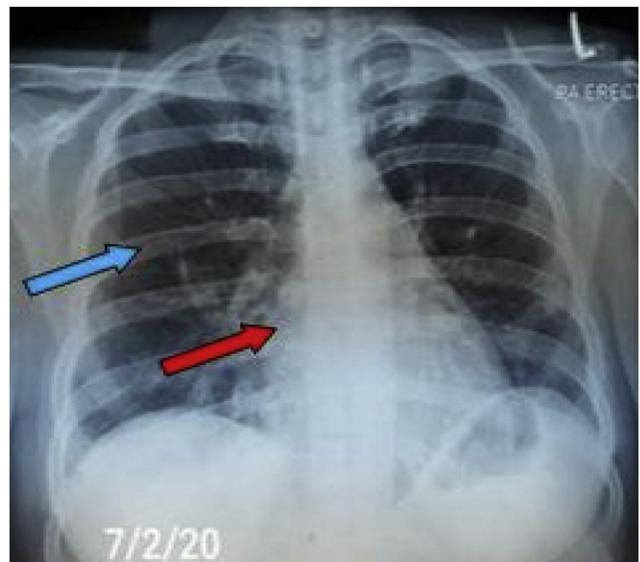


Figure 2: PA view CXR showed ill-defined opacity at right middle lobe (red arrow) with the presence of air-fluid level within the transverse fissure (blue arrow).

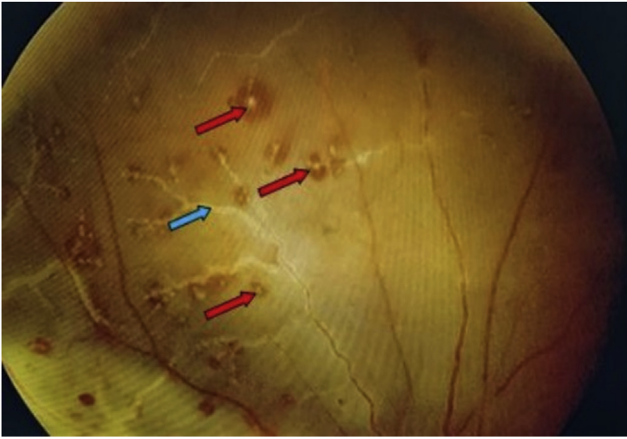


Figure 3: Area of multiple Roth spots (red arrow) with vasculitis (blue arrow) seen on the right fundus.

restricted. The view of the fundus was hazy. A B-scan ultrasound revealed dense loculations with thickened sclera. The LE was unremarkable. A systemic examination revealed crepitations over the lower zone of the right lung, with temperature spikes (See Figures 1 and 2).

Blood investigations showed a raised white cell count ($19.5 \times 10^9/L$), predominantly neutrophil, with a high C-reactive protein level (104.5 mg/L) and erythrocyte sedimentation rate (94 mm/Hr). The patient's random blood sugar level was 14.6 mmol/L. Diabetic ketoacidosis was ruled out. Computed-tomography (CT) brain and orbit showed features of right pre-septal cellulitis, with no intra-orbital pathology. She was diagnosed with RE endogenous endophthalmitis and proceeded with right intravitreal tap and antibiotics injection. IV ceftazidime (1 g daily) and hourly topical antibiotic eye drops were commenced. The patient was co-managed with the medical team and was started on subcutaneous insulin for blood sugar optimisation.

Due to persistent dense loculations and vitreous abscess, she underwent right anterior chamber washout and vitrectomy. The vitreous sample grew *Klebsiella pneumoniae*, which was sensitive to amoxicillin/clavulanic acid, ceftazidime, cefuroxime, ciprofloxacin, trimethoprim/sulfamethoxazole, and gentamicin.

Repeated chest X-rays showed the development of a left lung abscess with consolidation seen over the right middle

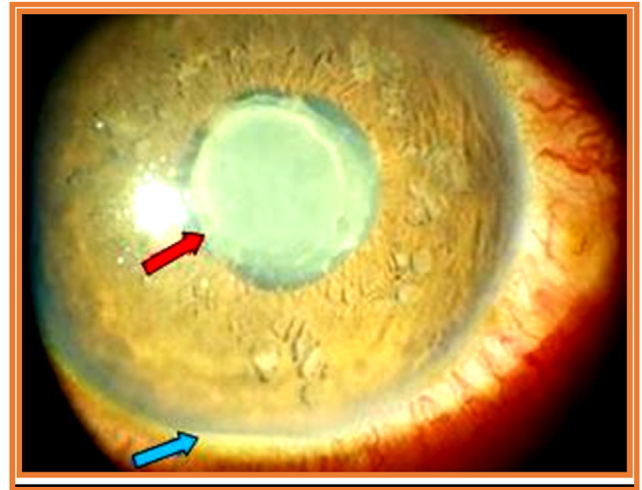


Figure 5: Presence of injected conjunctiva with fibrin plaque around the pupillary axis (red arrow) and a streak of hypopyon (blue arrow) over the right eye.

lobe. Other investigations, such as echocardiogram, ultrasound liver, urine, and blood cultures, were unremarkable. Subsequently, the patient developed RE panophthalmitis and eventually proceeded with evisceration. She completed IV ceftriaxone 2 g once daily (OD) for two weeks and continued with oral ampicillin/sulbactam 750 mg twice daily (BD). The eviscerated eye culture was sterile. Repeated chest X-rays showed improvement in lung opacity.

Case 2

A 38-year-old lady with no comorbidity presented with fever for one week and a sudden, painful RE associated with blurred vision and redness for two days. VA was hand movement (HM) RE and 6/9 LE with positive RAPD. An initial eye examination showed features of panuveitis, with the presence of cells 2+ in the anterior chamber, and vitritis. There was a raised lesion involving the entire posterior pole with optic disc swelling and numerous intraretinal haemorrhages, with Roth's spots at the periphery. The LE was unremarkable. The IOP of both eyes was normal. An initial B-scan of the RE revealed a subretinal mass involving the posterior pole with vitreous opacity. The patient was worked up for causes of panuveitis. Her condition deteriorated with

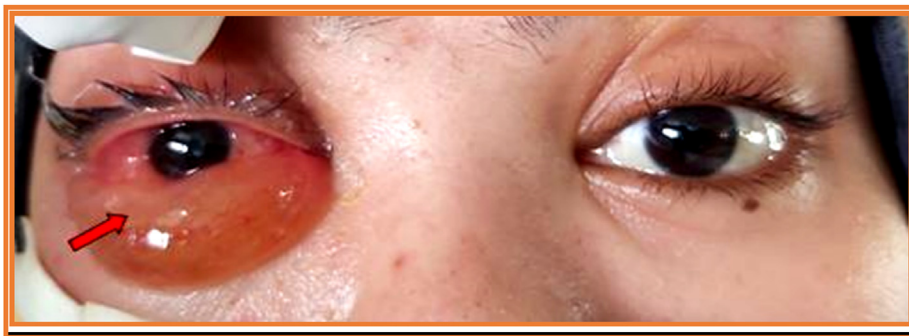


Figure 4: Severe lower lid chemosis with injected conjunctiva over the right eye.

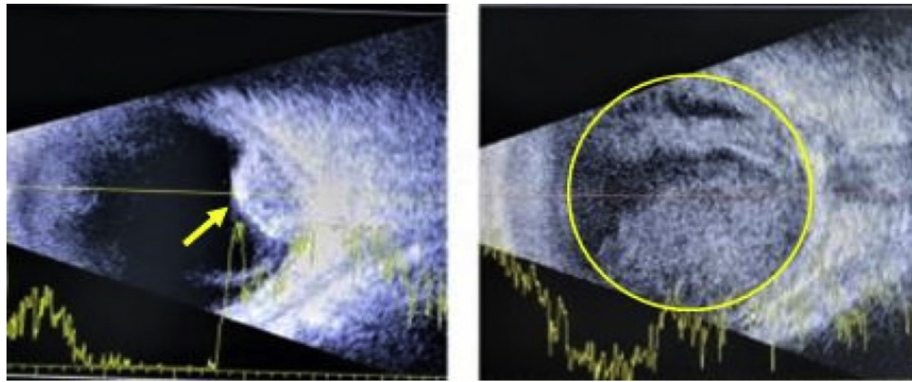


Figure 6: B-scan over the right eye (A) On day 1 showing subretinal dome-shaped mass involving the posterior pole. (B) On day 4 showing worsening of loculations with exudative retinal detachment.

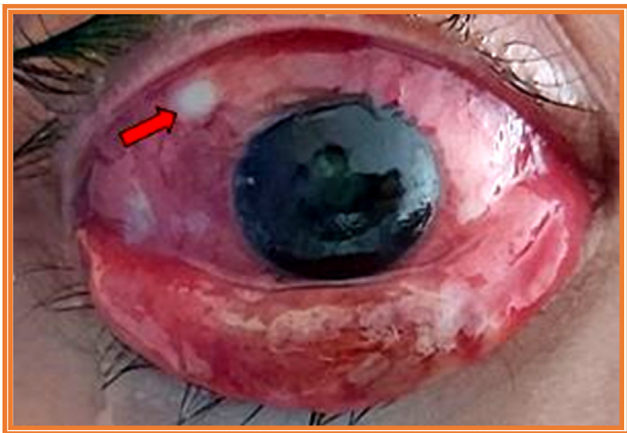


Figure 7: Presence of scleral abscess at the intravitreal injection site over the right eye.

RE proptosis, severe conjunctival chemosis, and hypopyon. There was formation of a fibrin membrane adhered on the anterior lens capsule with early seclusio pupillae. Extraocular

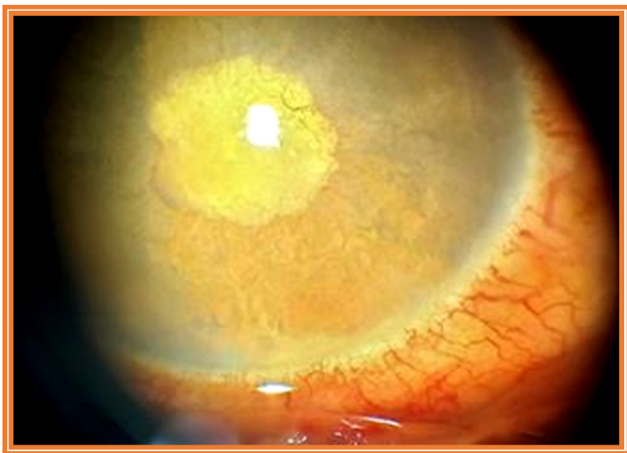

Figure 8: Anterior segment on week three of antibiotics showed improving inflammatory signs with peripheral synechiae 360° and tuft of iris vessels formation at the pupillary region on the right eye.

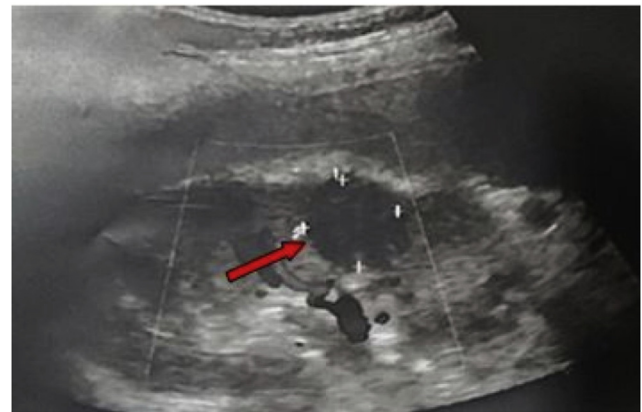


Figure 9: Pointed arrow area is hypoechoic lesion at the mid pole of left kidney measuring 2.2 × 2.2 cm.

movements were restricted, with elevated IOP over the RE. The fundus was no longer visible. Repeated B-scans revealed a worsening of the subretinal mass, vitreous opacity, and retinal detachment involving the superior and inferior quadrants with thickened sclera (See [Figures 3–10](#)).

Blood parameters showed an increasing white cell count from $12.3 \times 10^9/L$ to $18.2 \times 10^9/L$ and a raised C-reactive protein level of 178.1 mg/L. Urine full examination and microscopic examination (FEME) had leucocytes and pus cells >2250 cells/ μl . Urine culture and sensitivity reported *Klebsiella pneumoniae* to be sensitive to cefuroxime, trimethoprim/sulfamethoxazole, amoxicillin/clavulanic acid, and ampicillin/sulbactam. CT brain and orbit showed features of pre-septal cellulitis and vitreous chamber hyper density. The abdominal ultrasound reported hypoechoic lesion at the mid pole of the left kidney measuring 2 × 2 cm. The patient was diagnosed with RE panophthalmitis secondary to a left renal abscess. She was co-managed with the infectious disease team and started on IV ceftriaxone 2 g daily for two weeks and topical moxifloxacin and ceftazidime hourly. Intravitreal injection was deferred in the initial phase due to the risk of retinal detachment.

Repeated CT brain and orbit revealed a small rim-enhancing lesion in the brain at the right lentiform nucleus, suggestive of early abscess and orbital cellulitis features. We

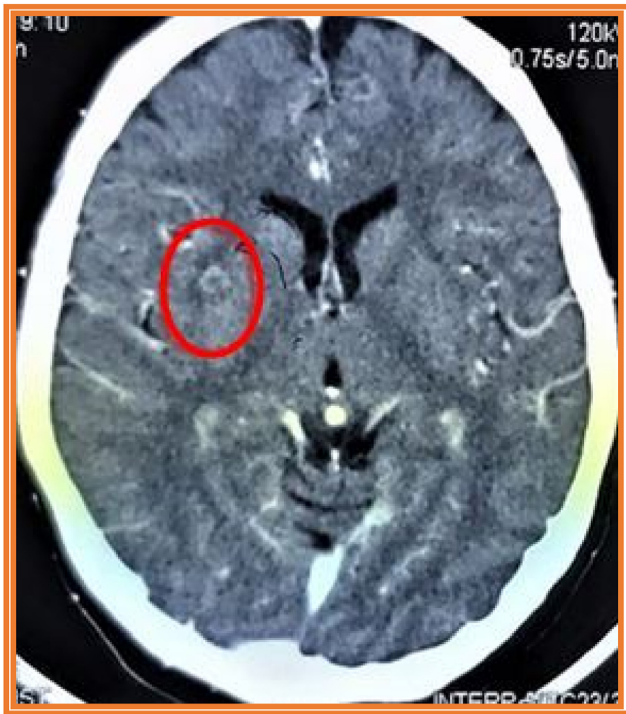

Figure 10: Axial cut of CT brain showed early rim enhancing lesion at right external capsule suggestive of abscess.

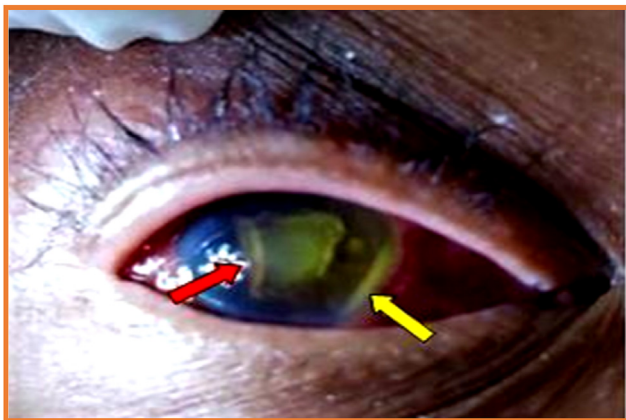


Figure 11: Anterior segment showed injected conjunctiva with the presence of fibrin plaque (red arrow) around the pupillary margin and hypopyon (yellow arrow).

proceeded with the first right intravitreal tap and antibiotic injection (vancomycin 2 mg/0.1 ml, ceftazidime 2 mg/0.1 ml) and repeated the second course after 48 hours. The patient refused a third intravitreal antibiotic injection. The first vitreous tap demonstrated pus aspirate that yielded *Klebsiella pneumoniae* sensitive to cefuroxime, trimethoprim/sulfamethoxazole, amoxicillin/clavulanic acid, and ampicillin/sulbactam, while the latter had no growth. At this point, with the development of a brain abscess due to *Klebsiella pneumoniae*, IV ceftriaxone was increased to 2 g thrice daily for six weeks. Repeated ultrasound of the kidney, ureter, and bladder reported no evidence of residual renal abscess. The repeated urine FEME and urine culture and sensitivity were also unremarkable.

The patient's condition improved with subsiding external signs of ocular inflammation and resolved scleral abscess, with improvement in blood parameters. Serial CT brain and orbit reported an improving RE condition with complete resolution of the brain abscess. She was discharged home with 625 mg oral amoxicillin/clavulanic acid twice daily for two weeks, after completing six weeks of IV antibiotics, with follow-up in two weeks. The RE eventually became phthisical.

Case 3

A 70-year-old lady with a history of adenocarcinoma of the colon presented with fever associated with vomiting and lethargy for two weeks. The patient was treated for community-acquired pneumonia. On Day two of admission, she had a sudden onset of painless blurring of vision with floaters on the RE. VA was PL (RE) and 6/18 (LE) with positive RAPD over the RE. The right conjunctiva was mildly injected with a clear cornea. Hypopyon was seen measuring 1.6 mm in height, with fibrin masking the pupil aperture. The left anterior segment was unremarkable. The IOP of both eyes was 18 mmHg. The RE fundus was not viewable, while the LE fundus was unremarkable (See Figures 11 and 12).

An initial B-scan of the RE revealed dense loculations and vitritis. A systemic examination revealed coarse crepitations at the lower zones of the bilateral lungs and fever. She was diagnosed with RE endogenous endophthalmitis secondary to community-acquired pneumonia. An intravitreal tap for culture and sensitivity was done, and an antibiotic injection (vancomycin 2 mg/0.1 ml, ceftazidime 2 mg/0.1 ml) given and repeated after 48 hours.

The blood parameters showed a raised white cell count ($21.1 \times 10^9/L$), predominantly neutrophils. A urine FEME showed leucocytes 2+. All the cultures from the blood, urine, and intravitreal tap were positive for *Klebsiella pneumoniae* and were sensitive to cephalosporin (ceftazidime, cefuroxime, and ceftriaxone), ciprofloxacin, gentamicin, and amoxicillin/clavulanic acid. Radio imaging to rule out a possible nidus of infective metastasis of *Klebsiella* infection was unremarkable. The diagnosis was revised to RE endogenous endophthalmitis secondary to *Klebsiella pneumoniae* sepsis. The patient was managed with the medical team and was started on IV amoxicillin/clavulanic acid 1.2 g thrice daily for two weeks, with hourly topical moxifloxacin and dexamethasone.

Her condition improved following two intravitreal antibiotic injections; however, vision deteriorated to no PL on the RE. She completed two weeks of intravenous antibiotics and was discharged well, with follow-up at one month. Eventually, the patient's eye became phthisical.

Discussion

Endogenous endophthalmitis is part of the invasive *Klebsiella* syndrome characterised by multifocal metastatic infections.¹ *Klebsiella pneumoniae* is the causative microbe for 90% of endogenous endophthalmitis in East Asia.² Wong et al. reported that *Klebsiella pneumoniae* was the commonest pathogen isolated among endogenous endophthalmitis cases in Singapore.² This is also evident in a few local studies.³⁻⁵

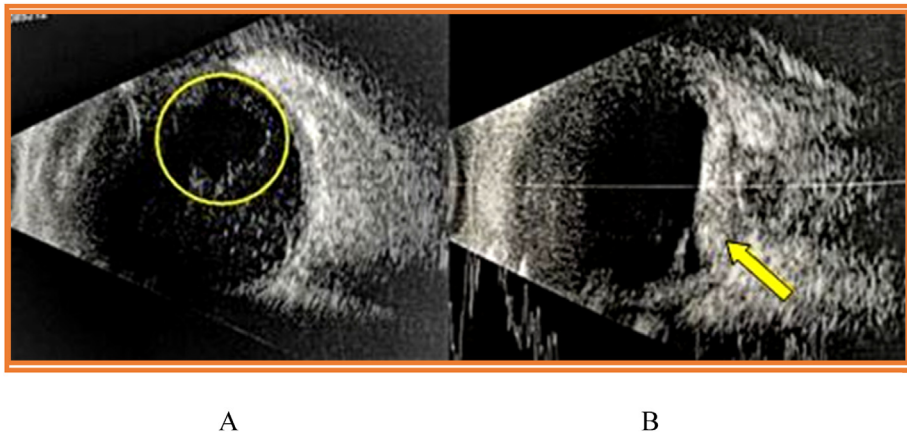


Figure 12: B-Scan over the right eye (A) Initial B-scan upon presentation presence of loculations with vitreous opacity. (B) Finding after intravitreal antibiotic injection showed absence of loculations with thickened sclera.

Clinical presentation

The *Klebsiella pneumoniae* strains gained increased notoriety due to their propensity to acquire antimicrobial resistance determinants.⁶ Commonly, *Klebsiella pneumoniae* causes liver abscess via its entry into the portal circulation.¹ Other organs of metastasis are the lungs, brain, prostate, and kidney.¹ Steven et al. reported that half of the patients who were treated for *Klebsiella* liver abscess developed endophthalmitis because of extrahepatic metastasis. Some studies have established the association of endogenous endophthalmitis concerning the hypervirulent *Klebsiella pneumoniae* strain with K1 and K2 serovars, which have exemplified a hypermucoviscous property.^{1,7,8} Wu et al. described that the hypervirulent *Klebsiella pneumoniae* strain produced more biofilm than the classic *Klebsiella pneumoniae* strain; thus, there was increased virulence in this strain.⁶ Hypervirulent *Klebsiella pneumoniae* presents numerous capsule polysaccharides (CPS) on its surface to escape a host's immune system. They evade opsonisation and phagocytosis by macrophages, dendritic cells, epithelial cells, and neutrophils by preventing binding of the cells on its surface. CPS also prevent dendritic cell maturation, thus allowing the bacteria to avoid a host's defence and multiply effectively. In addition, hypervirulent *Klebsiella pneumoniae* secretes many siderophores for its survival, as it relies on iron uptake for bacterial growth. For instance, enterobactin is an example of siderophores that are produced by *Klebsiella pneumoniae*, and has the highest affinity to iron. Consequently, this works as an advantage to scavenge iron from a host.¹⁷ Endophthalmitis itself may be the presenting manifestation of hypervirulent *Klebsiella pneumoniae* infection.^{3,9}

The initial presentation of *Klebsiella* endophthalmitis may be deceiving at times, as it may take up atypical features such as panuveitis, as seen in our second case. Greenwald et al. also acknowledged the difficulty in making a prompt diagnosis of metastatic endophthalmitis.¹⁰ Additionally, limited laboratory analytical instruments to detect *Klebsiella* hypervirulent capsular antigens, such as

immunochromatographic strip assay and polymerase chain reaction, further complicate the management of *Klebsiella* endophthalmitis.¹¹ In our study, all the patients were affected over the RE, owing to the proximity and direct arterial blood flow to the right carotid.^{10,12}

Comorbidities

Chronic illness, such as diabetes mellitus, is a recognised risk factor for *Klebsiella* infection.^{1,13,2,5,6,14} A similar finding was reported by Rosiah et al. and Kuo et al., who found that diabetes mellitus was the most common comorbidity associated with endogenous endophthalmitis, followed by renal failure and malignancy.^{3,15} Our patient in Case 1 is a diabetic patient, while the one in Case 3 is a colon cancer patient.

Outcome

Metastatic endophthalmitis, generally, can be classified into focal (anterior or posterior), anterior or posterior diffuse, and panophthalmitis.¹⁰ Focal endophthalmitis usually results in a better visual outcome, while panophthalmitis is often associated with a worse visual outcome.¹⁰ This has been shown in several studies, in which the visual outcome prognoses are based on the extent of the ocular infection. Chung et al. reported that the presence of hypopyon and diffuse posterior segment involvement were poor prognostic factors for *Klebsiella* endophthalmitis.¹

Treatment

Some studies have reported that gram-negative bacteremia results in elevated inflammatory markers such as C-reactive protein and interleukin-6 in the blood compared to gram-positive bacterial infection.¹⁶ This could be another diagnostic tool in deciding the appropriate antibiotics while waiting for the culture results. As there were no specific guidelines for *Klebsiella* endophthalmitis treatment, and the management of endophthalmitis in our centre was based on

the Endophthalmitis Vitrectomy Study (EVS), all the patients in our study were given intravitreal vancomycin and ceftazidime empirically. Chung et al. stated that intravenous ceftriaxone was recommended in the treatment of *Klebsiella* endophthalmitis, as it had a good vitreous and cerebral spinal fluid penetration.¹ A few studies concluded that early vitrectomy in endogenous endophthalmitis remained debatable.^{1,10} The rationale for early vitrectomy is to reduce the inflammatory mediators and bacterial load that cause tissue damage, and to facilitate the diffusion of antibiotics from the bloodstream to the vitreous cavity.^{1,10} To the best of our knowledge, there are no reviews on or meta-analyses of the specific treatment of *Klebsiella* endophthalmitis, hence more studies are required to establish effective antimicrobial and surgical treatments. Generally, *Klebsiella* endophthalmitis carries a grave prognosis as most of the cases either eviscerate due to complication, or become phthisical. As we saw, of the three patients, the Case 1 patient underwent evisceration, while those in Cases 2 and 3 became phthisical. All three patients are subject to regular follow-ups for assessment regarding complications of phthisical bulbi, such as ocular irritation and pain, or potential long-term complications, such as sympathetic ophthalmia, ulceration, and perforation.

Conclusion

We should be aware of the devastating complications of metastatic endophthalmitis due to *Klebsiella pneumoniae* as part of its invasive syndrome spectrum. A complete systemic and ocular examination should be advocated early in patients with focal endophthalmitis or *Klebsiella* septicemia to avoid the sight-threatening complications of *Klebsiella* endophthalmitis.

Source of funding

This research did not receive any specific grant from funding agencies in the public, commercial, or not-for-profit sectors.

Conflict of interest

The authors have no conflict of interest to declare.

Ethical approval

By Ministry of Health, Malaysia, National Medical Register. Ethical Approval ID- NMRR-21-402-59110. Approval Date 26/03/21. Informed consent was obtained from all patients.

Authors contributions

All the authors contributed to the patient management, literature review, and preparation of the manuscript. All the authors read and approved the final manuscript.

RC was responsible for the conceptualisation of the study, methodology, software, investigation, data curation, and writing of the original draft. TT assisted with the writing of the original draft, methodology, and investigation. CMY

reviewed the manuscript, clinical supervision, and editing of the manuscript. CMF was mainly involved in the clinical supervision and case management. NQZ contributed by reviewing the manuscript writing and editing. Last, AY contributed to the conceptualisation, review, and editing of the manuscript, and to the project administration. All authors have critically reviewed and approved the final draft and are responsible for the content and similarity index of the manuscript.

Acknowledgment

We would like to express our gratitude to Madam N, Madam A, and Madam Y who gave us full cooperation throughout the preparation of this case study. We would also like to thank the Director General of Health of Malaysia for his permission to publish this article.

References

1. Chung CY, Wong ES, Liu CCH, Wong MOM, Li KKW. **Clinical features and prognostic factors of *Klebsiella* endophthalmitis - 10-year experience in an endemic region**, vol. 31. *Eye (Basingstoke)*; 2017. pp. 1569–1575.
2. Wong Jun-Shyan, Chan Tat-Keong, Hung-Ming Lee S-PC. Endogenous bacterial endophthalmitis. An East Asian experience and a reappraisal of a severe ocular afflictio. *Intraocular Inflamm* 2016; 6420: 1087–1090 (00).
3. Muda R, Vayavari V, Subbiah D, Ishak H, Adnan A, Mohamed SO. Endogenous endophthalmitis: a 9-year retrospective study at a tertiary referral hospital in Malaysia. *J Ophthalmic Inflamm Infect* 2018; 8(1).
4. Michael NDB, Gunaseelan S, Tengku Norina TJ, Noordin Z, Hussein A. Endogenous endophthalmitis: a five-year review of cases at the Raja perempuan zainab II hospital, kelantan, Malaysia. *Cureus* 2018; 10(7).
5. Muhd H, Phang LK, Vendargon FM. *A five-year retrospective hospital-based study of endogenous endophthalmitis in South Malaysia*; 2020. pp. 18–26.
6. Xu M, Li A, Kong H, Zhang W, Chen H, Fu Y, et al. *Endogenous endophthalmitis caused by a multidrug-resistant hypervirulent *Klebsiella pneumoniae* strain belonging to a novel single locus variant of ST23 : first case report in China*; 2018. pp. 1–6.
7. Sridhar J, Flynn Jr HW, Kuriyan AE, Dubovy S, Miller D. Endophthalmitis caused by *Klebsiella* species. *Retina [Internet]* 2014 Sep; 34(9): 1875–1881. Available from: <https://pubmed.ncbi.nlm.nih.gov/24801652>.
8. Russo TA, Marr CM. *crossm* 2019; 32(3): 1–42.
9. Taylor P, Shon AS, Bajwa RPS, Russo TA. *Hypervirulent (hypermucoviscous) *Klebsiella pneumoniae* A new and dangerous breed*; February 2015. pp. 37–41.
10. Greenwald MJ, Wohl LG, Sell CH. Metastatic bacterial endophthalmitis: a contemporary reappraisal. *Surv Ophthalmol* 1986; 31(2): 81–101.
11. Wang CH, Lu PL, Liu EYM, Chen YY, Lin FM, Lin YT, et al. Rapid identification of capsular serotype K1/K2 *Klebsiella pneumoniae* in pus samples from liver abscess patients and positive blood culture samples from bacteremia cases via an immunochromatographic strip assay. *Gut Pathog [Internet]* 2019; 11(1): 1–8. Available from: <https://doi.org/10.1186/s13099-019-0285-x>.
12. Moore RF. Metastatic endophthalmitis. *J R Soc Med* 1933; 26(8): 1036.
13. Kawai T. **Hypermucoviscosity: an extremely sticky phenotype of *Klebsiella pneumoniae* associated with emerging destructive tissue abscess syndrome**, vol. 42; 2006. pp. 1359–1361.

14. Ang M, Jap A, Chee SP. Prognostic factors and outcomes in endogenous *Klebsiella pneumoniae* endophthalmitis. **Am J Ophthalmol [Internet]** 2011; 151(2): 338–344.e2. Available from: <http://doi.org/10.1016/j.ajo.2010.08.036>.
15. Kuo G, Lu YA, Sun WC, Chen CY, Kao HK, Lin Y, et al. Epidemiology and outcomes of Endophthalmitis in chronic dialysis patients: a 13-year experience in a tertiary referral center in Taiwan. **BMC Nephrol** 2017; 18(1): 1–9.
16. Abe R, Oda S, Sadahiro T, Nakamura M, Hirayama Y, Tateishi Y, et al. Gram-negative bacteremia induces greater magnitude of inflammatory response than Gram-positive bacteremia. **Crit Care** 2010; 14(2).
17. Li B, Zhao Y, Liu C, Chen Z, Zhou D. Molecular pathogenesis of *Klebsiella pneumoniae*. **Future Microbiol** 2014; 9(9): 1071–1081. <https://doi.org/10.2217/fmb.14.48>, fPMID: 25340836.

How to cite this article: Chelvaraj R, Thamotaran T, Yee CM, Fong CM, Zhe NQ, Azhany Y. The invasive *Klebsiella pneumoniae* syndrome: Case series. *J Taibah Univ Med Sc* 2022;17(2):332–339.