



## Case Report

## Coronavirus case presentation in a patient with loss of consciousness due to dyspnea



Peyman Astaraki, Babak Hadian\*

Department of Internal Medicine, Faculty of Medicine, Lorestan University of Medical Sciences, Khorramabad, Iran

## ARTICLE INFO

## Keywords:

Coronavirus  
Infection  
Respiratory distress  
Fever  
Dyspnea  
Virus

## ABSTRACT

**Introduction and importance:** Severity of corona virus disease 2019 (COVID19) is presented with respiratory distress.

**Case presentation:** We present a case of a 29-year-old male who was not presented with typical symptoms of COVID19 at the time of referral but loss of consciousness.

**Clinical discussion:** The importance of testing patients without typical symptoms for coronavirus infection and multi-system manifestation of the virus is presented in this case.

**Conclusion:** Severe drop in oxygen saturation in asymptomatic patients can lead to encephalopathy.

## 1. Introduction

In December 2019, a novel strain of coronavirus (2019-nCoV) was first reported to cause pneumonia-like infection named as coronavirus disease (COVID19). To the date, more than 30 million people are reported to be infected by coronavirus and it has been declared as pandemic by the World Health Organization (WHO) in February 2020. In comparison to other coronaviruses reported, transmission rate of 2019-nCoV is very high [1].

The infection is now believed to have multi-system manifestations however, primarily it causes lower respiratory tract infections. Symptomatic patients are commonly reported to be presented with fever, cough, dyspnea and headache and in critical cases, acute respiratory distress syndrome followed by respiratory failure [2,3]. Furthermore, a number of patients tested positive remain asymptomatic [4]. 50% of viral shedding is reported in asymptomatic patients [5,6]. Polymerase chain reaction (PCR) and lung CT and X-ray are used to confirm the diagnosis [7,8]. Other than respiratory tract infection, the virus is known to cause neurological, gastrointestinal, renal and cardiovascular ailments [9,10].

## 2. Case presentation

A 29 years-old male was admitted to emergency department with the loss of consciousness. One-hour before admission, patient was found comatose in his bathroom. Gas poisoning from water heater (carbon

monoxide) or neurologic event was suspected. He had the history of acute lymphoblastic leukemia during her adolescence (complete remission since last 10 years) and he consumed clobazam tab 10 mg/day (due to febrile convulsion in childhood). The patient was an otherwise healthy nonsmoker, with no other comorbidities or other drug history.

During examination, patient responded to central pain stimulus and her eye-movement response was also intact. Cardiovascular (ECG) and pulmonary (inspection, auscultation and percussion) examinations were normal and no evidence of trauma or skin discoloration. Her body temperature was 37.2 °C, blood pressure 110/70 mmHg, and heart rate 98/min, respiratory rate 25/min and oxygen saturation was 65%. Arterial blood gases analysis showed: PH: 7.33, Pco2:34 mmHg, Hco3:16.6 meq/l, Pao2: 70 mmHg. Brain CT scan findings were normal, indicating that patient did not undergo stroke. Ultrasound did not show any blood clots in knee, thigh, calf or arm, ruling out pulmonary thrombosis. Furthermore, his CBC also indicated that he was non-anemic. First lung x-ray did not show fluid or any other abnormalities. The patient was intubated for oxygenation and referred to central hospital. The following day, severe leucopenia was seen from blood test and patient condition was deteriorated. Chest x-ray of the patient showed mild ground glass opacities and haziness bilaterally (Fig. 1). These findings did not confirm with the primary suspicion of gas poisoning or hypoxemia in bathroom or superimposed aspiration pneumonia. Chest CT scan was performed which revealed, consolidation associated with air bronchogram in RLL (right lung lobe) along with ground glass opacity and patchy consolidation in both the lung (Fig. 2).

\* Corresponding author. Lorestan University of Medical Sciences, Khorramabad, Iran, Tel.: 09161613836.

E-mail address: [md.b.hadian@gmail.com](mailto:md.b.hadian@gmail.com) (B. Hadian).

<https://doi.org/10.1016/j.amsu.2021.102994>

Received 16 September 2021; Received in revised form 18 October 2021; Accepted 28 October 2021

Available online 30 October 2021

2049-0801/© 2021 The Authors. Published by Elsevier Ltd on behalf of IJS Publishing Group Ltd. This is an open access article under the CC BY-NC-ND license

(<http://creativecommons.org/licenses/by-nc-nd/4.0/>).

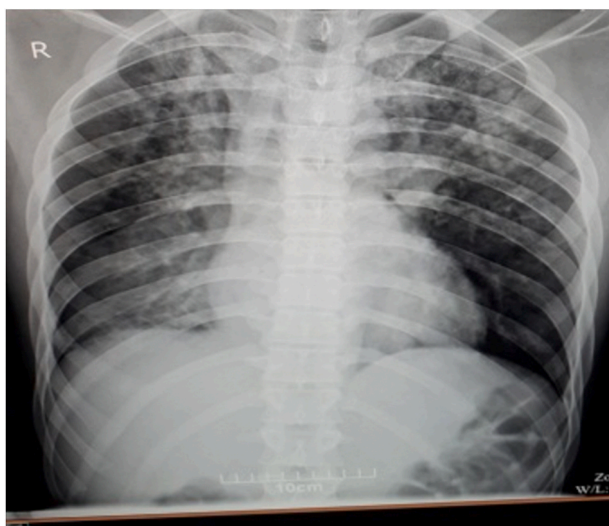


Fig. 1. Chest x-ray of the patient showed ground glass opacities.

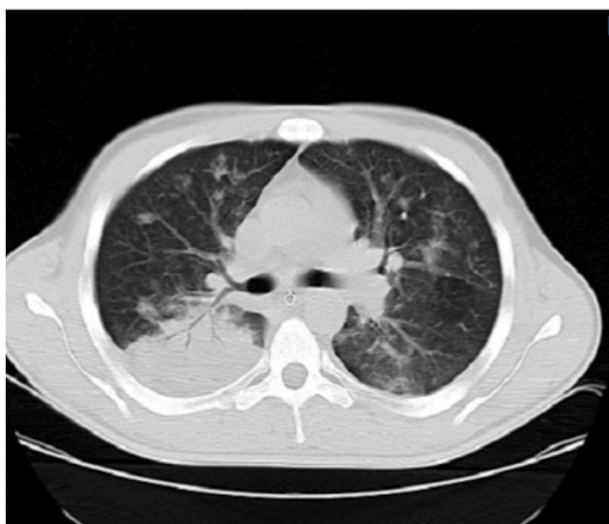

Fig. 2. Pulmonary bilateral ground glass appearance.

At his second day of hospitalization, the patient was admitted to ICU owing to decline in respiration. Supplementary data are summarized in Table 1.

Concerning insufficient oxygen saturation (refractory to mechanical ventilation) and an increase in body temperature (T: 38.4%), aspiration pneumonia was suggested by infectious disease specialist, for which antibiotic therapy was initiated (clindamycin and ceftriaxone).

The lung aspiration did not show any bacterial strain. The nasal specimen was then subjected to polymerase chain reaction (PCR) testing

Table 1  
Supplementary data about second day of hospitalization.

Hematologic data (on admission)	Metabolic data (on admission)	Important biomarkers (on admission)	Important data (2nd day)	Important data (3rd day)
WBC:14400, N:71%, L:28% Hb:17.9, Plt: 233000. CRP: ++, ESR: 14.	BS:166mg/dl, Urea:16 mg/ dl,Cr:0.9mg/ dl,Na:138 meq/l,K:3.3 meq/l.	AST:48, ALT:51, Alp:129iu/l, CPK: 2028 u/l, LDH:444 u/l	CPK:4000, LDH:1040, B/C:N.	WBC:2400 (N:85%, L:10%) Plt:79000, Hb:12.5

through which coronavirus infection was confirmed. Conservative ICU management with favorable oxygenation and hydration was continued along with antiviral therapy using oseltamivir and hydroxychloroquine, as per the national and international guidelines. Following diagnosis, he recounted his recent travelling to city Qom where from the spread of coronavirus infection was reported country wide. He had no complaint except sudden dyspnea in bathroom resulting in the loss of consciousness.

On 4th day, leukocyte count was corrected along with other ailments such as altered sensorium and respiratory distress. The patient was discharged after 8 days of hospitalization in good condition following negative PCR testing.

This case report has been reported in line with the SCARE 2020 criteria [11] Written informed consent was obtained from the patient for publication of this case report and accompanying images.

### 3. Discussion

More than 30 million cases of coronavirus infection are reported globally. The incidence of asymptomatic patients is different ranging from 1.4% from initial studies conducted in China, to 56.5% in Washington D.C. These variations are based on the difference in the sample size of these studies. However, transmission of virus from asymptomatic patients is same as that of symptomatic ones [12]. In this case study, we reported an initial case of asymptomatic patient of coronavirus infection reported in the region with positive chest imaging. The patient did not have any clinical sign of COVID19. However, his oxygen saturation was quite low and was later seen to have leucopenia. Neurological manifestations of COVID19 include dizziness, headache, loss of consciousness, skeletal muscle injury, altered sensorium and impairment of vision, taste and hearing [13]. These might be seen in 36.4% patients, depending on the study and sample size, along with common clinical symptoms such as fever and cough [14]. Altered mental state in asymptomatic geriatric patients, without respiratory problems, is also reported due to the infection [15]. Furthermore, encephalopathy, ranging from loss of consciousness, confusion, delirium to coma, is now reported in these patients as a result of cytokine storm leading to hypoxia and metabolic alteration [16].

At the time of admission, our patient was not presented with fever and/or coughing but loss of consciousness. A study by Ellul, Benjamin [17] reported that neurological manifestations like stroke, encephalitis, anosmia and ageusia can be presented in COVID19 patients without the presence of typical symptoms. Identifying infection among patients presented with neurological signs with mild or asymptomatic symptoms can be challenging, similar to the case presented here. Case presentations by Morassi, Bagatto [18] regarding stroke in COVID19 patients reported a patient presented with multiple episode of loss of consciousness following clinical and lab-based findings indicating possible coronavirus infection. The patient was later diagnosed to be presented by ischemic stroke. Age of the patients can lead to the variations in the manifestations of the symptoms of COVID-19 [19].

### 4. Conclusion

Severe impairment in the oxygen levels can lead to the encephalopathy such as loss of consciousness in otherwise, asymptomatic COVID19 patients.

### Ethical approval

All procedures performed in this study involving human participants were in accordance with the ethical standards of the institutional and/or national research committee and with the 1964 Helsinki Declaration and its later amendments or comparable ethical standards.

## Author statement

**Dr. Peyman Astaraki:** conceptualized and designed the study, drafted the initial manuscript, and reviewed and revised the manuscript.

Designed the data collection instruments, collected data, carried out the initial analyses, and reviewed and revised the manuscript.

**Dr. Babak Hadian:** Coordinated and supervised data collection, and critically reviewed the manuscript for important intellectual content.

## Registration of research studies

Name of the registry:

Unique Identifying number or registration ID:

Hyperlink to the registration (must be publicly accessible):

## Funding

This research did not receive any specific grant from any funding agency in the public, commercial or not-for-profit sector.

## Availability of data and material

Data sharing is not applicable to this article as no datasets were generated or analyzed during the current study.

## Consent for publication

Written informed consent was obtained from the patient for publication of this case report and accompanying images. A copy of the written consent is available for review by the Editor-in-Chief of this journal on request.

## Guarantor

**Dr. Peyman Astaraki.**

## Consent

Not applicable.

## Provenance and peer review

Not commissioned, externally peer-reviewed.

## Declaration of competing interest

The authors deny any conflict of interest in any terms or by any means during the study.

## Appendix A. Supplementary data

Supplementary data to this article can be found online at <https://doi.org/10.1016/j.amsu.2021.102994>.

## References

- [1] K. Dhama, S. Khan, R. Tiwari, S. Sircar, S. Bhat, Y.S. Malik, et al., Coronavirus disease 2019-COVID-19, *Clin. Microbiol. Rev.* 33 (4) (2020) e00028-20.
- [2] H.F. Rajani, F.A. Alshaiikh, A. Anushiravani, SARS-CoV-2; what We Know so far, *Arch. Iran. Med.* 23 (7) (2020) 498–502.
- [3] N. Farzan, P. Ghezlbash, F. Hamidi, A. Zeraatchi, Pulmonary thromboembolism with transthoracic ultrasound and computed tomography angiography, *The Clinical Respiratory Journal* (2021), 34402595, <https://doi.org/10.1111/crj.13437>.
- [4] R. Alizadeh, Z. Aghsaefard, Does COVID19 activates previous chronic pain? A case series, *Annals of Medicine and Surgery* 61 (2021) 169–171.
- [5] Z.D. Tong, A. Tang, K.F. Li, P. Li, H.L. Wang, J.P. Yi, et al., Potential presymptomatic transmission of SARS-CoV-2, zhejiang province, China, 2020, *Emerg. Infect. Dis.* 26 (5) (2020) 1052–1054.
- [6] Z. Aghsaefard, R. Alizadeh, The role of angiotensin converting enzyme in immunity: shedding light on experimental findings, *Endocr. Metab. Immune Disord. - Drug Targets* (2021), 33583391, <https://doi.org/10.2174/1871530321666210212144511>.
- [7] S.P. Stawicki, R. Jeanmonod, A.C. Miller, L. Paladino, D.F. Gaieski, A.Q. Yaffee, et al., The 2019-2020 novel coronavirus (severe acute respiratory syndrome coronavirus 2) pandemic: a joint American college of academic international medicine-world academic council of emergency medicine multidisciplinary COVID-19 working group consensus paper, *J. Global Infect. Dis.* 12 (2) (2020) 47–93.
- [8] N. Farzan, S. Vahabi, R. Shirvani, M. Shakeri, M. Araghi, M. Birjandi, et al., Evaluation of invasive ventilation (intubation) prognosis in patients with Covid-19 symptoms, *International Journal of Surgery Open* 27 (2020) 149–153.
- [9] J. Machhi, J. Herskovitz, A.M. Senan, D. Dutta, B. Nath, M.D. Oleynikov, et al., The natural history, pathobiology, and clinical manifestations of SARS-CoV-2 infections, *J. Neuroimmune Pharmacol.* 15 (3) (2020) 359–386.
- [10] S. Marzban-Rad, P. Sattari, M. Heidarian Moghadam, G. Azimi, Early percutaneous dilational tracheostomy in COVID-19 patients: a case report, *Clinical Case Reports* 9 (2) (2021) 1014–1017.
- [11] R.A. Agha, T. Franchi, C. Sohrabi, G. Mathew, A. Kerwan, A. Thoma, et al., The SCARE 2020 guideline: updating consensus surgical Case Report (SCARE) guidelines, *Int. J. Surg.* 84 (2020) 226–230.
- [12] Z. Gao, Y. Xu, C. Sun, X. Wang, Y. Guo, S. Qiu, et al., A systematic review of asymptomatic infections with COVID-19, *J. Microbiol. Immunol. Infect.* (2020), <https://doi.org/10.1016/j.jmii.2020.05.001>.
- [13] G. Nepal, J.H. Rehrig, G.S. Shrestha, Y.K. Shing, J.K. Yadav, R. Ojha, et al., Neurological manifestations of COVID-19: a systematic review, *Crit. Care* 24 (1) (2020) 421.
- [14] L. Mao, H. Jin, M. Wang, Y. Hu, S. Chen, Q. He, et al., Neurologic manifestations of hospitalized patients with coronavirus disease 2019 in wuhan, China, *JAMA Neurology* 77 (6) (2020) 683–690.
- [15] C.F. Ward, G.S. Figiel, W.M. McDonald, Altered mental status as a novel initial clinical presentation for COVID-19 infection in the elderly, *Am. J. Geriatr. Psychiatr.* 28 (8) (2020) 808–811.
- [16] R.K. Garg, V.K. Paliwal, A. Gupta, Encephalopathy in patients with COVID-19: a review, *J. Med. Virol.* 93 (1) (2021) 206–222.
- [17] M.A. Ellul, L. Benjamin, B. Singh, S. Lant, B.D. Michael, A. Easton, et al., Neurological associations of COVID-19, *Lancet Neurol.* 19 (9) (2020) 767–783.
- [18] M. Morassi, D. Bagatto, M. Cobelli, S. D'Agostini, G.L. Gigli, C. Bnà, et al., Stroke in patients with SARS-CoV-2 infection: case series, *J. Neurol.* 267 (8) (2020) 2185–2192.
- [19] N.G. Davies, P. Klepac, Y. Liu, K. Prem, M. Jit, C.A.B. Pearson, et al., Age-dependent effects in the transmission and control of COVID-19 epidemics, *Nat. Med.* 26 (8) (2020) 1205–1211.