

Evolution of the Konyang Standard Method for single incision laparoscopic cholecystectomy: the result from a thousand case of a single center experience

Min Kyu Kim, In Seok Choi, Ju Ik Moon, Sang Eok Lee, Dae Sung Yoon, Seong Uk Kwon, Won Jun Choi, Nak Song Sung, Si Min Park

Department of Surgery, Konyang University Hospital, Daejeon, Korea

Purpose: Single incision laparoscopic cholecystectomy (SILC) is increasingly performed worldwide. Accordingly, the Konyang Standard Method (KSM) for SILC has been developed over the past 6 years. We report the outcomes of our procedures.

Methods: Between April 2010 and December 2016, 1,005 patients underwent SILC at Konyang University Hospital. Initially 3-channel SILC with KSM was changed to 4-channel SILC using a modified technique with a snake retractor for exposure of Calot triangle; we called this a modified KSM (mKSM). Recently, we have used a commercial 4-channel (Glove) port for simplicity.

Results: SILC was performed in 323 patients with the KSM, in 645 with the mKSM, and in 37 with the commercial 4-channel port. Age was not significantly different between the 3 groups ($P = 0.942$). The postoperative hospital days ($P = 0.051$), operative time ($P < 0.001$) and intraoperative bleeding volume ($P < 0.001$) were significantly improved in the 3 groups. Drain insertion ($P = 0.214$), additional port insertion ($P = 0.639$), and postoperative complications ($P = 0.608$) were not significantly different in all groups. Postoperative complications were evaluated with the Clavien-Dindo classification. There were 3 cases (0.9%) over grade IIIb (bile duct injury, incisional hernia, duodenal perforation, or small bowel injury) with KSM and 3 (0.5%) with mKSM.

Conclusion: We evaluated the evolution of the KSM for SILC. The use of the mKSM with a commercial 4-channel port may be the safest and most effective method for SILC.

[Ann Surg Treat Res 2018;95(2):80-86]

Key Words: Laparoscopic cholecystectomy, Single-incision, Laparoscopy

INTRODUCTION

Cholecystectomy is one of the most commonly performed procedure in abdominal surgery. Laparoscopic procedures continue to develop with improvements in surgical instruments and techniques. Since Erich Muhe of Germany performed the first procedure in 1985, laparoscopic cholecystectomy has become the gold standard for surgical treatment of gallbladder

disease worldwide [1,2]. This procedure is minimally invasive and results in less postoperative pain, better cosmesis, shorter hospital stays, and less disability for work than large-incision open cholecystectomy [3-5]. Many surgeons have tried to reduce the number of ports and size of incisions [6,7]. In 1997, Navarra et al. [8] performed single-incision laparoscopic cholecystectomy (SILC) with transumbilical trocars and used transabdominal gallbladder traction sutures. Recently, many surgeons have

Received October 11, 2017, Revised November 21, 2017,
Accepted December 1, 2017

Corresponding Author: In Seok Choi

Department of Surgery, Konyang University Hospital, 158 Gwanjeodong-ro, Seo-gu, Daejeon 35365, Korea

Tel: +82-42-600-8956, Fax: +82-42-543-8956

E-mail: choiins@kyuh.ac.kr

ORCID code: https://orcid.org/0000-0002-9656-3697

Copyright © 2018, the Korean Surgical Society

© Annals of Surgical Treatment and Research is an Open Access Journal. All articles are distributed under the terms of the Creative Commons Attribution Non-Commercial License (<http://creativecommons.org/licenses/by-nc/4.0/>) which permits unrestricted non-commercial use, distribution, and reproduction in any medium, provided the original work is properly cited.

shown interest in the feasibility of SILC [9,10].

There are many different SILC approaches with regard to transumbilical trocar position, liver retraction, and additional port insertion. However, many studies have reported that SILC is not suitable for acute complicated gallbladder disease because of technical difficulty and procedure risk. Moreover, there are still no definite indications and standard methods for SILC. Therefore, we introduced the Konyang Standard Method (KSM) for SILC since April 2010. Initially, we used 3-channel SILC which we called the KSM, and the KSM has been improved over the past 6 years. This report aimed to evaluate the adequacy and feasibility of the KSM for SILC, and the development of KSM is discussed.

METHODS

Patients

Between April 2010 and December 2016, 1,005 patients underwent SILC. Two hepatobiliary surgeons performed SILC in all patients, and all patients provided informed consent before the operation. Initially we excluded patients aged more than 70 years, and those with systemic medical problems, cystic duct abnormalities, and complications of acute cholecystitis. However, after 50 cases, all patients except for those with suspected malignancy were acceptable for SILC because of experience and improved technique. Between April 2010 and September 2012, 323 patients underwent SILC with the KSM using a hand-made 3-channel (3-trocar) single port. From October 2012 to August 2016, 645 patients underwent SILC with KSM using a modified 4-channel technique with a snake retractor for exposure of the hepatocystic triangle (Calot triangle); we called this a modified KSM (mKSM). Since September 2016, we have used a commercial 4-channel (Glove) port for simplicity in 37 patients; we call this a commercially modified KSM (C-mKSM).

Konyang Standard Method

Instruments and port

KSM is performed with a hand-made 3-channel port constructed with a 10-mm wound protector/retractor (Alexis, Applied Medical, Rancho Santa Margarita, CA, USA) covered with a size 7 sterile glove connected to two 5-mm ports and one 10-mm port (Laport, Sejong Medical, Paju, Korea). The wound retractor is inserted through a transumbilical incision and the 3-channel hand-made glove port is used as a working port for laparoscopic instruments. First, we cut the fingertips off the gloves and insert the trocar, which is tied and fixed. Then, the outer ring of the wound retractor is covered with the hand-made glove port. A CO₂ pipe is connected to the 10-mm port for the pneumoperitoneum. The flexible videoscope (Olympus, Tokyo, Japan), long articulated Endo-Rotator laparoscopic

instrument (Covidien, Mansfield, MA, USA), a suction-hook bovie (Endopath Probe Plus II Pistol Grip handle, Ethicon, Bridgewater, NJ, USA) and 5- and 10-mm Hem-o-lok clips (Weck Closure Systems, Research Triangle Park, NC, USA) are used in the KSM (Fig. 1).

Patient and instrument positioning

The patients are placed in a supine position with both arms in extension, in a 15°–30° reverse Trendelenburg position, and with the right side tilted upward. The operator stands on the left side of the patient and the scopist stands below the operator. A 10- to 20-mm transumbilical incision is made and the 3-channel hand-made port is inserted. When the laparoscopic instrument is inserted, the operator's right hand controls the grasper for traction of the gallbladder and the left hand controls the dissector, scissors, and suction-hook Bovie for major procedures involving dissection, division, and ligation. The laparoscopic instrument is held with the hands crossed at the transumbilical incision, creating a triangular working area in the intraabdominal cavity. To secure adequate range of instrumental movement, the left hand should be located below the right hand instrument. Both instruments should be located on the left side of the telescope in the transumbilical incision to avoid conflict between the instruments.

Surgical technique

The operator uses the grasper in the right hand for cephalad traction on the fundus of the gallbladder in a supero-lateral direction. Then, the cystic duct and porta hepatis are exposed (gallbladder traction). If the cystic duct and porta hepatis are identified, the operator needs to establish the critical view of safety. The operator uses the grasper in the right hand to push the infundibulum of the gallbladder infero-laterally, and the dissector and suction-hook Bovie in the left hand to dissect the hepatocystic triangle boundary. If the gallbladder neck is

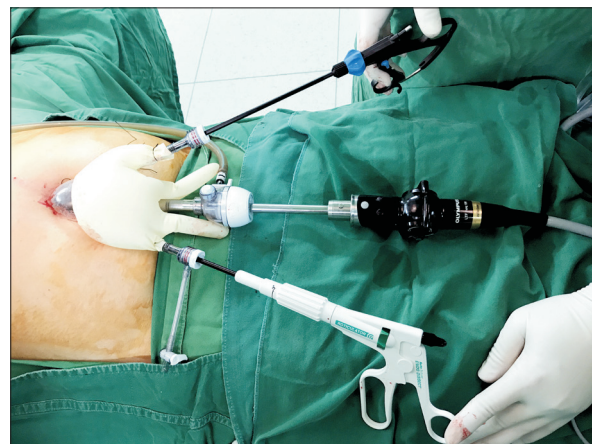

Fig. 1. Hand-made working port for Konyang Standard Method.

dissected free of the liver surface, a "window" is created in the hepatocystic triangle crossed by the cystic duct and artery (dissection of the hepatocystic triangle). If the cystic duct and artery are fully dissected, they are ligated and resected by using 5- or 10-mm Hem-o-lok clips with the left hand of the operator (division of cystic artery and duct). After resection of the cystic artery and duct, the gallbladder is pulled cephalad using the grasper in the right hand. The connective tissues between the gallbladder bed and hepatic surface are dissected with electrocautery in the left hand (dissection of the gallbladder bed) [10].

Modified KSM

The KSM encountered some difficulty because of limited working range of the laparoscopic instrument in the hepatocystic triangle. Especially, in a patient with a large and heavy liver, it is difficult to widen the view of the subhepatic area. Therefore, we introduced a 4-channel, hand-made glove port by adding one more 5-mm port for a snake retractor to raise the under surface of the liver around the hepatocystic triangle. The added snake retractor allowed wider exposure of the hepatocystic triangle, and improved the working range of the laparoscopic instrument. We called this the mKSM (Figs. 2, 3).

Commercially modified KSM

The mKSM is in standard use for SILC in Konyang University Hospital. Recently, we introduced a commercial 4-channel product port (Glove port, A-type, Nelis, Seoul, Korea) for simplicity (Fig. 4).

RESULTS

Clinicopathologic characteristics

Among 1,005 patients who underwent SILC, the age range

was 16–88 years and the median age was 52 years. There were 459 male patients (45.7%) and 549 female patients (54.3%). Of 246 patients with a history of previous abdominal surgery, 22 patients had upper abdominal surgery and 224 patients had lower abdominal surgery. Among the 1,005 patients, 928 (92.3%) had a body mass index < 30 kg/m² and 925 (92.0%) had an American Society of Anesthesiologists physical status classification < III. The preoperative percutaneous transhepatic gallbladder drainage insertion rate was 12.0% (121 patients). The clinicopathologic information of the 1,005 patients is shown in Table 1.

Operative and postoperative outcomes

Mean operative time was 53.6 ± 19.2 minutes and blood loss was 18 ± 40 mL. Average postoperative hospital stay was 2.6 days. Among 1,005 cases, 24 (2.4%) needed insertion of an

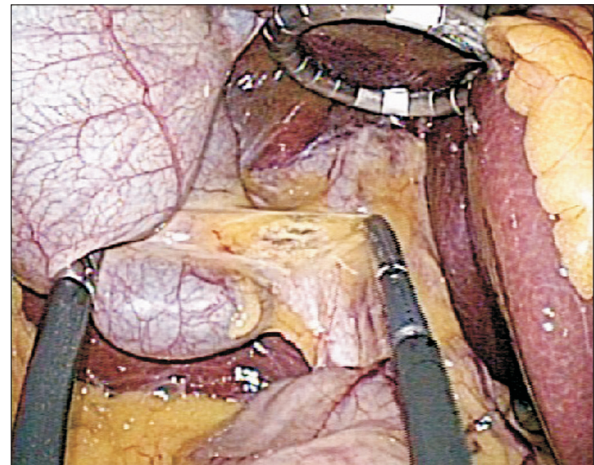


Fig. 3. View after snake retractor apply.

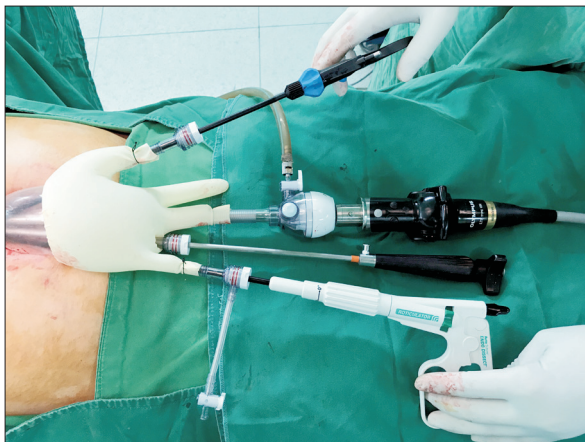


Fig. 2. Hand-made working port for modified Konyang Standard Method.

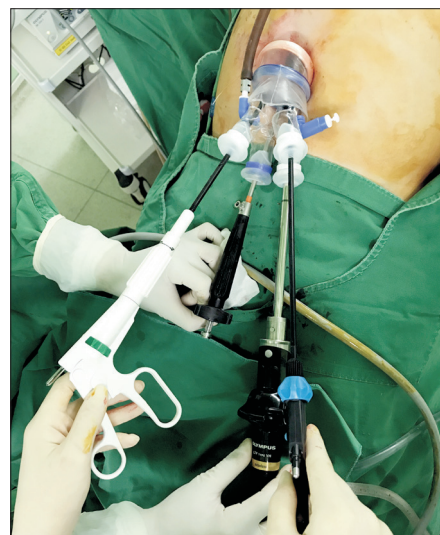

Fig. 4. Commercial glove port for commercially modified Konyang Standard Method.

additional port. In 16 cases, gallbladder bed bleeding was controlled by laparoscopic suture ligation; 3 cases required dissection of intraabdominal adhesions, 3 required retraction of a

heavy liver, 2 sustained a bile duct injury, and 1 had a duodenal injury treated with laparoscopic suture repair. In postoperative pathologic findings, 137 patients (13.6%) were diagnosed with acute cholecystitis or empyema and 868 (86.4%) were diagnosed with chronic or other benign diseases. A Jackson-Pratt drain tube was inserted in 18 cases (1.8%) and placed in the subhepatic area (Table 2).

Table 1. Patient clinical and demographic characteristics (n = 1,005)

| Variable | Value |
|--------------------------------------|---------------|
| Age (yr) | 51.91 ± 14.68 |
| Sex | |
| Male | 459 (45.7) |
| Female | 546 (54.3) |
| Body mass index (kg/m ²) | 24.76 ± 3.51 |
| <30 | 928 (92.3) |
| ≥30 | 77 (7.7) |
| Prior abdominal surgery | |
| Upper | 22 (2.2) |
| Lower | 224 (22.3) |
| ASA PS classification | |
| <III | 925 (92.0) |
| ≥III | 80 (8.0) |
| Preoperative PTGBD | 121 (12.0) |

Values are expressed as mean ± standard deviation or number (%). ASA PS, American Society of Anesthesiologists physical status; PTGBD, percutaneous transhepatic gallbladder drainage.

Comparisons between KSM, mKSM, and C-mKSM

The KSM for SILC has undergone development for the past

Table 2. Overall operative outcomes for patients who underwent SILC (n = 1,005)

| Variable | Value |
|----------------------------------|---------------|
| Operative time (min) | 53.59 ± 19.16 |
| Blood loss (mL) | 18.14 ± 39.57 |
| Postoperative hospital day | 2.66 ± 2.068 |
| Drain insertion | 18 (1.8) |
| Additional port insertion | 24 (2.4) |
| Pathology | |
| Acute cholecystitis and empyema | 137 (13.6) |
| Chronic choelcystitis and others | 868 (86.4) |

Values are expressed as mean ± standard deviation or number (%).

Table 3. Comparison of variables between patients who underwent KSM, mKSM, and C-mKSM

| Variable | KSM (n = 323) | mKSM (n = 645) | C-mKSM (n = 37) | P-value |
|--------------------------------------|---------------|----------------|-----------------|---------|
| Age (yr) | 51.71 ± 13.77 | 52.02 ± 15.21 | 51.62 ± 13.16 | 0.942 |
| Sex | | | | 0.573 |
| Male | 142 (44.0) | 302 (46.8) | 15 (40.5) | |
| Female | 181 (56.0) | 343 (53.2) | 22 (59.5) | |
| Body mass index (kg/m ²) | 24.79 ± 3.64 | 24.76 ± 3.44 | 24.46 ± 3.54 | 0.860 |
| <30 | 295 (91.3) | 598 (92.7) | 35 (94.6) | 0.652 |
| ≥30 | 28 (8.7) | 47 (7.3) | 2 (5.4) | |
| Prior abdominal surgery | | | | 0.160 |
| Upper | 9 (2.8) | 13 (2.0) | 0 (0) | |
| Lower | 83 (25.7) | 132 (20.5) | 9 (24.3) | |
| ASA PS classification | | | | 0.815 |
| <III | 298 (92.3) | 592 (91.8) | 35 (94.6) | |
| ≥III | 25 (7.7) | 53 (8.2) | 2 (5.4) | |
| Preoperative PTGBD | 31 (9.6) | 90 (14.0) | 0 (0) | 0.010 |
| Operative time (min) | 51.67 ± 20.06 | 55.30 ± 18.73 | 40.54 ± 10.19 | <0.001 |
| Blood loss (mL) | 24.64 ± 54.08 | 15.64 ± 30.65 | 4.94 ± 5.87 | <0.001 |
| Postoperative hospital days (day) | 2.90 ± 3.03 | 2.56 ± 1.41 | 2.38 ± 0.76 | 0.051 |
| Drain insertion | 3 (0.9) | 15 (2.3) | 0 (0) | 0.214 |
| Additional port insertion | 8 (2.5) | 16 (2.5) | 0 (0) | 0.639 |
| Pathology | | | | 0.003 |
| Acute & empyema | 28 (8.7) | 105 (16.3) | 4 (10.8) | |
| Chronic & others | 295 (91.3) | 540 (83.7) | 33 (89.2) | |

Values are expressed as mean ± standard deviation or number (%).

KSM, Konyang Standard Method; mKSM, modified KSM; C-mKSM, commercially modified KSM; ASA PS, American Society of Anesthesiologists physical status; PTGBD, percutaneous transhepatic gallbladder drainage.

Evaluation was performed using analysis of variance and the chi-square test with Fischer exact test. Significance was considered 2-sided for a P-value < 0.05.

6 years. There was no significant difference in preoperative clinicopathologic characteristics between patients undergoing these procedures. However, postoperative outcomes were improved and operative time was shortened. There was a significant difference in operative time in a comparison between the KSM, mKSM, and C-mKSM approaches (51.7 ± 13.8 minutes vs. 55.3 ± 15.2 minutes vs. 40.5 ± 13.2 minutes, respectively, $P < 0.001$), as well as in blood loss (24.6 ± 54.1 mL vs. 15.6 ± 30.7 mL vs. 4.9 ± 5.9 mL, $P < 0.001$) and mean postoperative hospital stay (2.9 ± 3.0 days vs. 2.6 ± 1.4 days vs. 2.4 ± 0.8 days, $P = 0.051$). There was no significant difference in drain insertion (3 cases [0.9%] vs. 15 cases [2.3%] vs. 0 cases, [0%], $P = 0.214$) and additional port insertion (8 cases [2.5%] vs. 16 cases [2.5%] vs. 0 cases [0%], $P = 0.639$). This improvement is shown in Table 3, which compare KSM, mKSM, and C-mKSM.

Postoperative complications

Postoperative complications were reported in 23 cases (2.3%). All complications were Clavien-Dindo classification grade I–V. Minor complications included 12 wound infections, 3 bilomas, and 3 wound or intraabdominal abscesses. Major complications included 2 biliary duct injuries treated with laparoscopic primary suture repair with T-tube insertion, 2 incisional hernias (followed after 6, 12 months), 1 duodenal perforation, and 1 small bowel injury. There was no significant difference between KSM and mKSM ($P = 0.608$). There were no postoperative complications with the C-mKSM procedure (Table 4).

Table 4. Postoperative complications

| Clavien-Dindo classification | KSM (n = 323) | mKSM (n = 645) | P-value |
|------------------------------|---------------|----------------|---------|
| Grade I | | | |
| Wound infection | 4 | 8 | |
| Grade II | | | |
| Biloma | 0 | 3 | |
| Grade III a | | | |
| Wound abscess | 0 | 1 | |
| Intra-abdominal abscess | 0 | 1 | |
| Grade III b | | | |
| Bile duct injury | 1 | 1 | |
| Incisional hernia | 1 | 1 | |
| Duodenal perforation | 1 | 0 | |
| Small bowel injury | 0 | 1 | |
| Grade IV | 0 | 0 | |
| Grade V | 0 | 0 | |
| Total, n (%) | 7 (2.2) | 16 (2.5) | 0.608 |

Analysis was performed using the chi-square test with Fischer exact test.

KSM, Konyang Standard Method; mKSM, modified KSM.

DISCUSSION

Laparoscopic cholecystectomy is considered the gold standard for gallbladder disease, and minimally invasive surgery is preferred due to less postoperative pain and better cosmesis than in an open procedure. Thus, many surgeons have attempted to reduce the number of ports and size of the incisions [3-5]. Since Navarra et al. performed the first SILC in 1997, many studies have reported its feasibility and safety, but, there are still no standard methods for SILC [8,11,12].

When Navarra et al. [8] first reported SILC, the procedure required two 10-mm trocars and 3 transabdominal holding sutures to elevate the gallbladder. Since then, many surgeons have introduced various techniques and instruments. Piskun and Rajpal [13] reported a method using two 5-mm trocars with 2 holding sutures in 1999. This method requires 2 trans-umbilical fascia incisions to insert the trocars. Thus, these used a single incision for skin but more than a single fascia incision. Podolsky et al. [14] reported a method using three 5-mm trocars and a rigid grasper through a single incision without percutaneous traction sutures. However, this method also used a separate fascial opening. Recently, Ceci et al. [15] reported using a commercial port with 3 working channel. In the KSM, we use a hand-made port, which has several advantages. It can be flexibly applied to many different situations: addition of a working port channel, and adjustment for umbilical wound size and use of bulky instruments such as a 10-mm Hem-o-lok clip. Moreover, a hand-made port offers a wide axis and space for instruments movement. However, the hand-made port is time-consuming to create during an operation. Accordingly, we began to use a commercial port in the KSM procedure (C-mKSM).

In the SILC procedure, liver retraction is needed to expose Calot triangle. Cuesta et al. [16] proposed a procedure using percutaneous Kirschner wires to expose Calot triangle. Tacchino et al. [17] directly performed SILC with 3 trocars through a single umbilical incision and used 2 holding sutures to suspend the gallbladder for exposure of Calot triangle. Since then, there have been ongoing attempts to perform SILC with minimal invasive hybrid procedure [18,19]. In the mKSM, we used a snake retractor to expose Calot triangle without suture elevation of the gallbladder or liver. This has the benefit of minimally invasive surgery and avoids gallbladder and liver injury from suture technique. Moreover, using a snake retractor enables flexible and immediate response in operative technique. This reduced conflict between laparoscopic instruments and offered a comfortable working range.

We used the Clavien-Dindo criteria to classify the complications of laparoscopic cholecystectomy. Minor complications included 12 wound infections, 3 bilomas, and 3 wound or intra-abdominal abscesses. Major complications included 2 biliary duct injuries treated with laparoscopic primary suture

repair with T-tube insertion, 2 incisional hernias, 1 duodenal perforation, and 1 small bowel injury. There was no significant difference in complications between KSM and mKSM ($P = 0.608$). Biliary tract injury in laparoscopic cholecystectomy is the most severe complication, occurring in about 1% of cases and is reported to occur about 2.5 to 4 times more often than in open cholecystectomy. The Roux-en-Y hepaticojejunostomy procedure is reported to be successful when total resection of the bile duct and primary repair or T-tube insertion can be performed at the time of partial dissection [20-23]. Joseph et al. [24] reported a higher bile duct injury rate of 0.72% associated with SILC, even though most procedures were performed for nonacute cholecystitis. Moreover, many studies reported that SILC is not recommended in acute cholecystitis, because of technical difficulty and risk of complications [24-26]. Our study only

had 1 case of biliary tract injury in KSM (0.3%) and 1 in mKSM (0.15%), and both were treated with laparoscopic primary suture repair. In addition, we performed SILC in 137 cases of acute cholecystitis, comprising 13.6% of all SILC patients, without significant complications.

In conclusion, we described the evolution of the KSM for SILC. The findings suggest that the modified KSM using a 4-channel single port and snake retractor may be the safest and least invasive method for SILC.

CONFLICTS OF INTEREST

No potential conflict of interest relevant to this article was reported.

REFERENCES

- Begos DG, Modlin IM. Laparoscopic cholecystectomy: from gimmick to gold standard. *J Clin Gastroenterol* 1994;19: 325-30.
- Csikesz NG, Singla A, Murphy MM, Tseng JF, Shah SA. Surgeon volume metrics in laparoscopic cholecystectomy. *Dig Dis Sci* 2010;55:2398-405.
- Soper NJ, Stockmann PT, Dunnegan DL, Ashley SW. Laparoscopic cholecystectomy. The new 'gold standard'? *Arch Surg* 1992; 127:917-21.
- Schirmer BD, Edge SB, Dix J, Hyser MJ, Hanks JB, Jones RS. Laparoscopic cholecystectomy. Treatment of choice for symptomatic cholelithiasis. *Ann Surg* 1991;213: 665-76.
- Wilson RG, Macintyre IM, Nixon SJ, Saunders JH, Varma JS, King PM. Laparoscopic cholecystectomy as a safe and effective treatment for severe acute cholecystitis. *BMJ* 1992;305:394-6.
- Muhe E. Long-term follow-up after laparoscopic cholecystectomy. *Endoscopy* 1992; 24:754-8.
- Podolsky ER, Curcillo PG 2nd. Reduced-port surgery: preservation of the critical view in single-port-access cholecystectomy. *Surg Endosc* 2010;24:3038-43.
- Navarra G, Pozza E, Occhionorelli S, Carcoforo P, Donini I. One-wound laparoscopic cholecystectomy. *Br J Surg* 1997; 84:695.
- Hodgett SE, Hernandez JM, Morton CA, Ross SB, Albrink M, Rosemurgy AS. Laparoendoscopic single site (LESS) cholecystectomy. *J Gastrointest Surg* 2009;13: 188-92.
- Son JI, Choi IS, Moon JI, Ra YM, Lee SE, Choi WJ, et al. Single incision laparoscopic cholecystectomy using Konyang Standard Method. *Ann Surg Treat Res* 2014;86:177-83.
- Edwards C, Bradshaw A, Ahearne P, Dematos P, Humble T, Johnson R, et al. Single-incision laparoscopic cholecystectomy is feasible: initial experience with 80 cases. *Surg Endosc* 2010;24:2241-7.
- Rivas H, Varela E, Scott D. Single-incision laparoscopic cholecystectomy: initial evaluation of a large series of patients. *Surg Endosc* 2010;24:1403-12.
- Piskun G, Rajpal S. Transumbilical laparoscopic cholecystectomy utilizes no incisions outside the umbilicus. *J Laparoendosc Adv Surg Tech A* 1999;9:361-4.
- Podolsky ER, Mouhlas A, Wu AS, Poor AE, Curcillo PG 2nd. Single Port Access (SPA) laparoscopic ventral hernia repair: initial report of 30 cases. *Surg Endosc* 2010;24: 1557-61.
- Ceci F, Di Grazia C, Cipriani B, Nicodemi S, Corelli S, Pecchia M, et al. Cholecystectomy by single incision laparoscopic surgery (SILS): early experience and technique standardization. *G Chir* 2012;33: 280-4.
- Cuesta MA, Berends F, Veenhof AA. The "invisible cholecystectomy": a transumbilical laparoscopic operation without a scar. *Surg Endosc* 2008;22:1211-3.
- Tacchino R, Greco F, Matera D. Single-incision laparoscopic cholecystectomy: surgery without a visible scar. *Surg Endosc* 2009;23:896-9.
- Palanivelu C, Rajan PS, Rangarajan M, Parthasarathi R, Senthilnathan P, Praveenraj P. Transumbilical flexible endoscopic cholecystectomy in humans: first feasibility study using a hybrid technique. *Endoscopy* 2008;40:428-31.
- Zhu JF, Hu H, Ma YZ, Xu MZ, Li F. Transumbilical endoscopic surgery: a preliminary clinical report. *Surg Endosc* 2009; 23:813-7.
- Mathisen O, Soreide O, Bergan A. Laparoscopic cholecystectomy: bile duct and vascular injuries: management and outcome. *Scand J Gastroenterol* 2002;37: 476-81.

21. Melton GB, Lillemoe KD, Cameron JL, Sauter PA, Coleman J, Yeo CJ. Major bile duct injuries associated with laparoscopic cholecystectomy: effect of surgical repair on quality of life. *Ann Surg* 2002;235:888-95.
22. Stewart L, Way LW. Bile duct injuries during laparoscopic cholecystectomy. Factors that influence the results of treatment. *Arch Surg* 1995;130:1123-8.
23. Strasberg SM, Hertl M, Soper NJ. An analysis of the problem of biliary injury during laparoscopic cholecystectomy. *J Am Coll Surg* 1995;180:101-25.
24. Joseph M, Phillips MR, Farrell TM, Rupp CC. Single incision laparoscopic cholecystectomy is associated with a higher bile duct injury rate: a review and a word of caution. *Ann Surg* 2012;256:1-6.
25. Antoniou SA, Pointner R, Granderath FA. Single-incision laparoscopic cholecystectomy: a systematic review. *Surg Endosc* 2011;25:367-77.
26. Pisanu A, Reccia I, Porceddu G, Uccheddu A. Meta-analysis of prospective randomized studies comparing single-incision laparoscopic cholecystectomy (SILC) and conventional multiport laparoscopic cholecystectomy (CMLC). *J Gastrointest Surg* 2012;16:1790-801.