

Original article

Suture pull-through insertion of graft donor in Descemet stripping automated endothelial keratoplasty: Results of 4-year follow-up



Vincenzo Sarnicola ^{a,*}, Chiara Millacci ^b, Enrica Sarnicola ^c, Caterina Sarnicola ^d,
 Francesco Sabatino ^e, Andrew Ruggiero ^f

^a Ambulatorio di Chirurgia Oculare Santa Lucia, Grosseto, Italy

^b Department of Ophthalmology, Misericordia Hospital, Grosseto, Italy

^c Department of Ophthalmology, Università degli Studi di Siena, Siena, Italy

^d Department of Ophthalmology, Università degli Studi di Ferrara, Ferrara, Italy

^e Department of Ophthalmology, Università Campus Bio-Medico di Roma, Rome, Italy

^f Department of Civil and Mechanical Engineering, DiMSAT, Università di Cassino, Cassino, Italy

ARTICLE INFO

Article history:

Received 15 June 2015

Received in revised form

6 July 2015

Accepted 13 July 2015

Available online 28 August 2015

Keywords:

Descemet stripping automated endothelial
 keratoplasty
 endothelial cell loss
 suture pull-through donor insertion

ABSTRACT

Purpose: To report our clinical experience and 4-year follow-up results of Descemet stripping automated endothelial keratoplasty (DSAEK) with the suture pull-through insertion technique.

Methods: This is a retrospective study of 195 eyes in which a posterior lamellar keratoplasty was performed between 2007 and 2011. The insertion of a folded donor lenticule was performed with a double-armed 10-0 suture using a straight transchamber needle and half-circle needle. Endothelial cell density was measured annually up to 4 years after the surgery, and cell loss was calculated based on the median preoperative donor endothelial cell density. Postoperative complications, primary graft failure, pupillary block, and dislocation of the donor tissue were assessed.

Results: All patients underwent uncomplicated DSAEK. Data were available for 195 eyes (100%) at 1 year, 186 eyes (95.3%) at 2 years, 176 eyes (90.2%) at 3 years, and 160 eyes (82%) at 4 years. Median preoperative donor endothelial cell density was 2688 cells/mm² [interquartile range (IQR) 207.5 cells/mm²], which decreased by 27% at 1 year (1956 cells/mm², IQR 264.8 cells/mm²), 31% at 2 years (1855 cells/mm², IQR 320.5 cells/mm²), 35% at 3 years (1756.5 cells/mm², IQR 306.5 cells/mm²), and 36% at 4 years (1709.5 cells/mm², IQR 288.0 cells/mm²). Nine patients (4.6%) had a dislocation of donor tissue; all were successfully reattached with a second air injection. Only three eyes (1.5%) developed graft failure. Pupillary block was present in 15 eyes (7.7%).

Conclusion: DSAEK with suture pull-through insertion of donor graft represents a simplified and safe technique that has endothelial cell loss comparable with other techniques and low rates of intraoperative and postoperative complications.

Copyright © 2015, The Ophthalmologic Society of Taiwan. Published by Elsevier Taiwan LLC. All rights reserved.

1. Introduction

Endothelial keratoplasty is a surgical procedure used to treat endothelial dysfunction, leaving the recipient's anterior cornea intact.^{1–3} Many studies have shown that endothelial keratoplasty offers numerous advantages compared with full-thickness corneal

transplant, including faster visual rehabilitation, better postoperative refractive outcomes, refractive stability, and less complications.^{3–7} The Descemet stripping automated endothelial keratoplasty (DSAEK) technique is widely performed by corneal surgeons, however, many variations of the technique have been developed in an attempt to improve the results and to reduce the possible complications, such as donor dislocation, primary graft failure, and pupillary block.^{5,8,9}

The critical aspect of this procedure is the correct positioning of the graft while avoiding, as much as possible, iatrogenic endothelial damage of the donor graft. One variation of the technique requires

Conflicts of interest: All contributing authors declare no conflicts of interest.

* Corresponding author. Ambulatorio di Chirurgia Oculare Santa Lucia, Via Mazzini 60, 58100 Grosseto, Italy.

E-mail address: v.sarnicola@hotmail.it (V. Sarnicola).

insertion of the donor graft through a scleral incision while placing the disk on a spoon-shaped glide covered with viscoelastic material to protect the donor endothelium.^{1,8,10,11} Another technique involves folding the lenticule and placing the folded tissue with noncompressing forceps into a small (≤ 5 mm) corneal or scleral incision.^{12,13}

In addition, some surgeons have proposed the use of an intraocular lens cartridge in which the graft is rolled into a compact shape to avoid compressive forces that occur from folding.^{14,15}

In a previous study, we described a new technique developed in our center to introduce the donor tissue into the recipient eye using a double-armed 10-0 polypropylene, nonabsorbable suture, with a straight transchamber needle and half-circle needle (polypropylene, blue monofilament, PAIR PAK; Alcon Surgical, Milan, Italy).¹⁶

In this study, we report our clinical experience and 4-year follow-up results of DSAEK with the suture pull-through insertion technique.

2. Materials and methods

DSAEK was performed in 195 eyes of 168 patients between 2007 and 2011 at Misericordia Hospital. Preoperative diagnoses included Fuchs endothelial dystrophy, pseudophakic bullous keratopathy, and failed penetrating graft. All surgeries were performed by one surgeon (V.S.). Each patient read and signed an informed consent document. The study was conducted in accordance with the tenets of the Helsinki Declaration.

We obtained the pre-cut tissue for all patients from the Italian Eye Bank of Mestre, Venice, Italy, and the tissues were dissected at their eye bank. The average thickness and diameter of the tissue obtained were 150 μm and 10 mm, respectively. The tissues were preserved in Edinburgh University Solution of Lime-C (EUSOL-C) solution.

The surgical technique was described previously.^{13,16} We decided to use a donor disk that was most suitable for the size of the recipient cornea. Thereafter, we used donor disks that ranged from 7.75 mm to 8.5 mm in diameter. A bent needle Cystotome was used to perform descemetorhexis. A reverse Sinsky hook was used to peel the Descemet membrane from the posterior stromal surface. Using a corneal blade (dual bevel 4.1-mm angled implant knife; Alcon Surgical), a 4.1-mm clear corneal incision was made

(Fig. 1). The Descemet membrane and the endothelium were removed from the anterior chamber using toothless forceps.

The donor tissue was brought into the operative field, and a corneal punch (corneal trephine program; Newtech, Florence, Italy) was used to cut the lenticule and separate it from the anterior flap. A small amount of viscoelastic material (HEALON; Bausch and Lomb, Florence, Italy) was placed on the endothelial surface. The donor tissue was folded into an asymmetric 60/40 taco shape with the endothelial side inward to ensure that the endothelial layer remained protected (Figs. 2A and 2B). Once the donor graft was folded, the half-circle needle of a double-armed 10-0 polypropylene, nonabsorbable suture was passed through the apex of the folded graft. The suture was passed superficially through the stroma at the distal end of the donor tissue, avoiding the endothelium. The suture end was tied to itself to create a loop (Figs. 3A and 3B), and the small needle was cut off and discarded. We bent the straight transchamber needle to 120° and passed it through the 4.1-mm corneal wound in the recipient, across the anterior chamber, and out of the opposite limbus, if possible through the pre-placed stab incision at the 6 o'clock position (Fig. 4A).

An irrigation and aspiration cannula tip was placed in the anterior chamber, and extensive irrigation and aspiration with balanced salt solution (BSS) was performed to remove all the viscoelastic material. To insert the donor tissue, we used a smooth forceps to grasp the suture that was passed through the cornea at

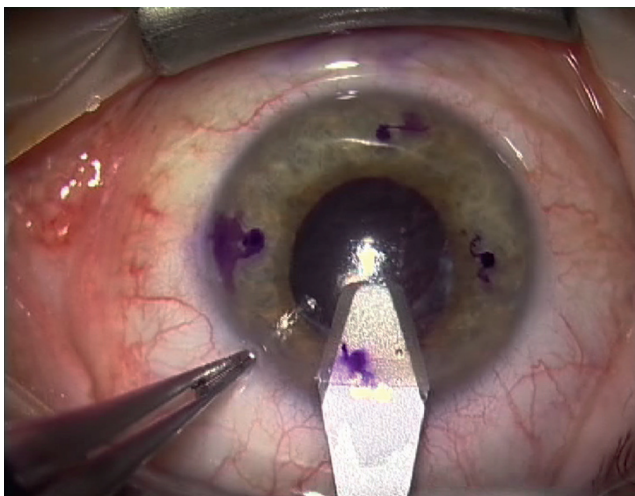


Fig. 1. Clear corneal incision using a 4.1-mm corneal knife.

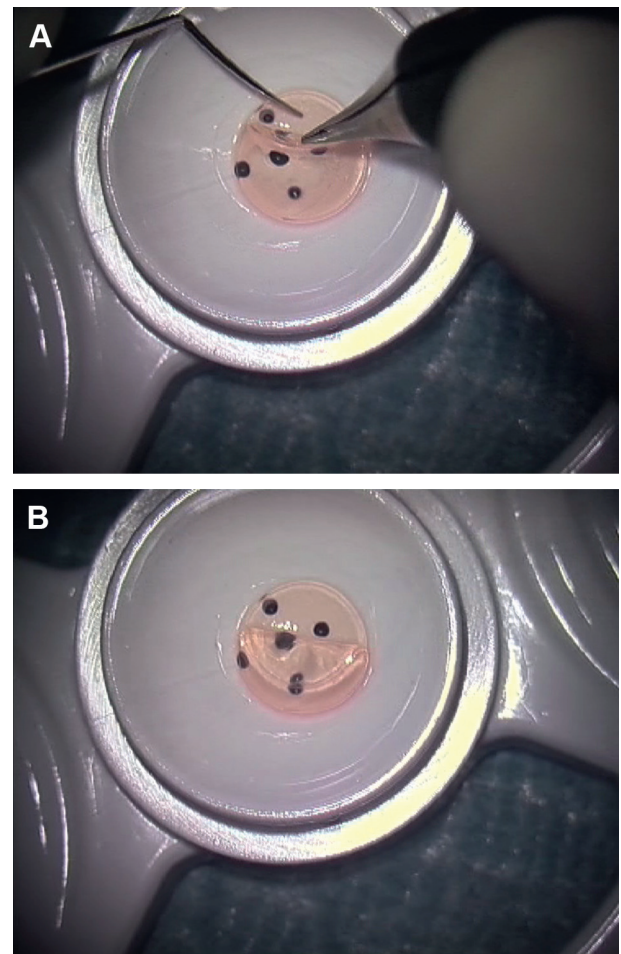


Fig. 2. (A) Fold of the donor lenticule after protecting the endothelial surface with a small amount of ophthalmic viscoelastic material. (B) Asymmetric 60/40 taco shape of the donor lenticule.

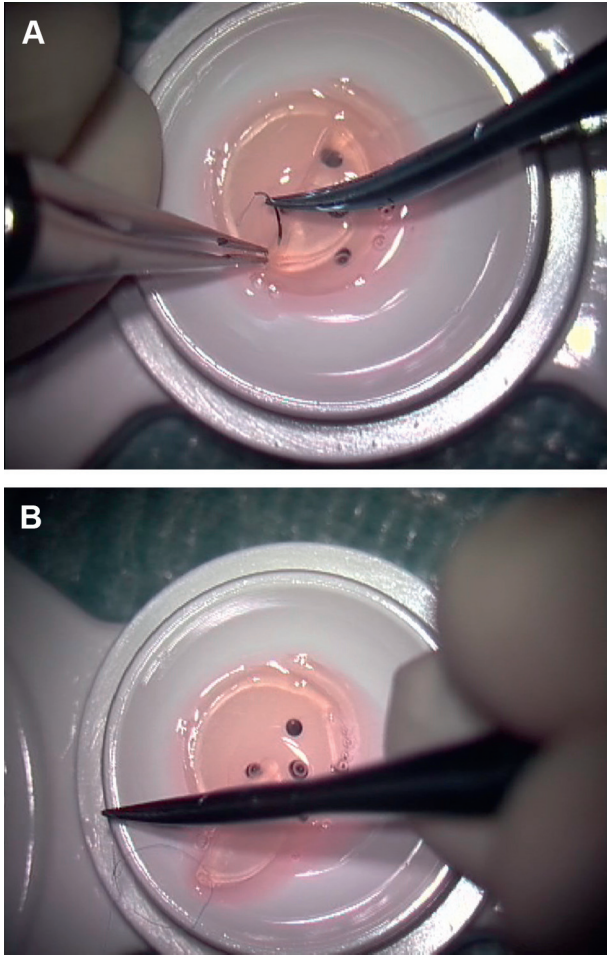


Fig. 3. (A) Half-circle needle passed through the stromal face of the fold of the so-called taco. (B) Suture tied to create a loop large enough to facilitate its cutting after insertion.

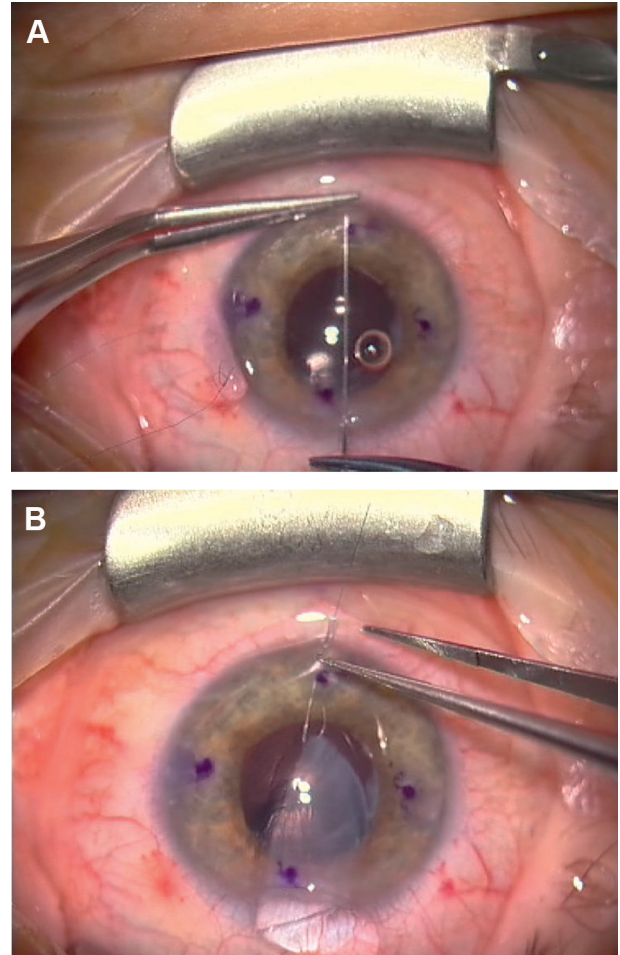


Fig. 4. (A) Straight needle passed through the 12 o'clock limbal incision exiting at the 6 o'clock limbus. (B) Donor lenticule inserted through the 4.1-mm corneal incision into the anterior chamber.

the 6 o'clock position to drag the donor tissue into the anterior chamber (Fig. 4B). A 10-0 nylon suture was then used to close the 4.1-mm corneal incision. BSS was then gently injected into the anterior chamber through the side paracentesis to unfold the donor tissue and deepen the anterior chamber (Fig. 5). Air was injected into the anterior chamber to replace the BSS and attach the donor tissue with the recipient cornea. If the donor disk was not perfectly centered, a reverse Sinsky hook was used to position the donor tissue. Using a spatula, we compressed the central epithelial surface of the recipient cornea from the center toward the periphery to squeeze out all fluids from the donor–recipient interface. Once the donor tissue was centered and adherent to the recipient cornea, the double-armed suture was cut and removed using a smooth forceps. An air–BSS exchange was performed, and an air bubble (as big as possible) was left in the anterior chamber to promote donor tissue adherence (Fig. 6).

The patients were instructed to lie in the supine position. They were examined using a slit lamp every 2 hours to ensure that the air bubble was above the lower pupillary border to prevent pupillary block.

The progress of patients was followed for 4 years. Central endothelial counts were measured using a corneal confocal microscope (ConfoScan 3; Nidek, Padova, Italy) annually up to 4 years after the surgery.

2.1. Statistical analysis

Data were tested against the null hypothesis that they are normally distributed. Two normality tests were used (chi-square and Kolmogorov–Smirnov), and both rejected the null hypothesis

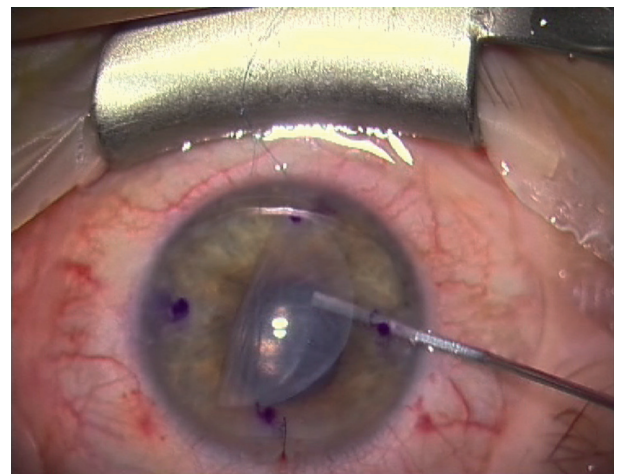


Fig. 5. Opening of donor lenticule with a gentle irrigation of balanced salt solution irrigation.

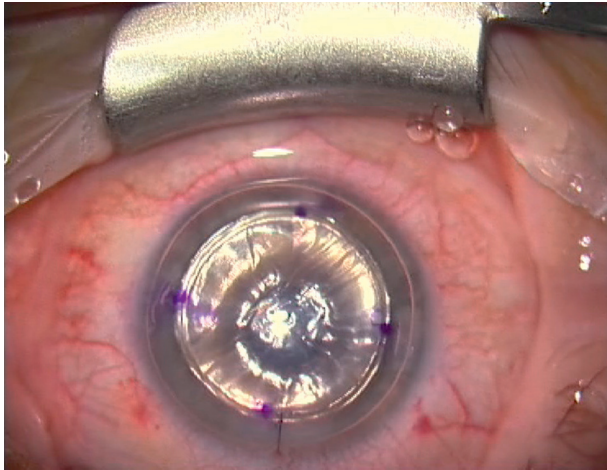


Fig. 6. Air injection into the anterior chamber to facilitate donor tissue adhesion.

($p < 0.01$). Thus, statistical methods for comparing means of two or more groups based on the normality assumption, such as t test and analysis of variance, could not be used. Instead, procedures derived for nonparametric and semiparametric models were applied. These are often called “robust procedures” because they are dependent only on very weak assumptions.

Data are represented by box plots introduced by Tukey.¹⁷ This is a useful and widely used graphical technique to explore and compare data of different groups.

The confidence interval of the median is calculated based on the first and third quartiles, following McGill et al,¹⁸ and it is displayed by a notch. The width of a notch is computed, and box plots whose notches do not overlap have different medians at the 5% significance level.

3. Results

The 195 eyes in this retrospective, nonrandomized series were from 168 patients with a mean age at surgery of 68 ± 10 years (range 31–90 years). Ninety (46%) of the eyes were from male patients, and 105 (54%) were from female patients. In total, 137 (70.2%) eyes required DSAEK surgery owing to Fuchs dystrophy, 49 eyes (25.1%) owing to pseudophakic bullous keratopathy, and nine eyes (4.6%) for failed penetrating graft.

None of the patients had any intraoperative complications. No patients needed conversion to penetrating keratoplasty (PK).

Of the 195 eyes enrolled into this study, 195 eyes (100%) were available for examination at 1 year, 186 eyes (95.3%) at 2 years, 176 eyes (90.2%) at 3 years, and 160 eyes (82%) at 4 years. The loss of data was due to the fact that many patients were from other regions or were too ill to return for follow-up.

The median preoperative donor endothelial cell density was 2688 cells/mm² with an interquartile range (IQR) of 207.5 cells/mm². Endothelial cell density decreased to 1956 cells/mm² (IQR

264.8 cells/mm²) at 1 year postoperatively, representing a 27% cell loss (Table 1). From 1 year to 2 years, the endothelial cell density changed significantly with an additional 4% cell loss (31% overall loss) to 1855 cells/mm² (IQR 320.5 cells/mm²). From 2 years to 3 years, the endothelial cell density decreased by another 4% (35% overall loss) to 1756.5 cells/mm² (IQR 306.5 cells/mm²). At 4 years of follow up, there had been a 36% loss of endothelial cells (1709.5 cells/mm², IQR 288.0 cells/mm²). The notches of the box plots indicate that all medians are significantly different from each other ($p < 0.05$), except for Years 3 and 4, for which the notches overlap (Fig. 7).

We had three cases (1.5%) of graft failures. In the first case, the patient was glaucomatous, used three kinds of eye drops, underwent cataract surgery 1 year after DSAEK, and he poorly complied with therapy for Chandler syndrome. The second case had recurrent rejection episodes. The third case developed a herpetic endotheliitis, which was initially misdiagnosed. The patient had no history of previous herpetic disease. The diagnosis was confirmed by polymerase chain reaction from the replaced tissue. Regrafting was necessary in all three cases.

There were nine cases (4.6%) of donor detachment that needed anterior-chamber air bubble injection on postoperative Day 1. The air injection was done in a minor surgery room under an operating microscope with a 30-gauge cannula. Air was left in place, and the patient was asked to lie in the supine position. With the rebubbling, we achieved total resolution of graft dislocation and reduction of corneal edema.

Pupillary block was present in 15 eyes (7.7%), however, in all cases, it was possible to resolve the block by evacuating air from a previously placed paracentesis site with a spatula in front of a slit lamp. The amount of air evacuated was just sufficient to resolve the blockage while retaining enough air in the anterior chamber to prevent the dislocation of the graft. The patient was then asked to maintain a supine position.

Discussion

DSAEK is an evolving technique that has reduced or eliminated many problems related to PK, such as the risks associated with open-sky surgery, high postoperative astigmatism, wound dehiscence, vascularization, and graft rejection. However, the factors that limit the success of this surgery seem to be an increased rate of endothelial cell loss (ECL) and a high rate of graft dislocations.^{6,7,19}

In this study, we tested a method of inserting the donor lenticule using a traction suture. The advantages of our method include not crushing the lenticule with forceps, lower insertion trauma, and easier unfolding. Moreover, our technique does not require an anterior-chamber-maintainer device, peripheral iridectomy, or superficial corneal stab incisions; in our experience, this has facilitated intraoperative maneuvers and reduced complications in the postoperative period.

One of the most critical aspects of the DSAEK procedure is the insertion of the donor lenticule into the anterior chamber through a small incision. Lee et al⁶ reviewed 34 articles about DSAEK and

Table 1
Summary of endothelial cell density (cells/mm²) after DSAEK.

	Preoperative	Postoperative			
		1 y	2 y	3 y	4 y
Median of endothelial cell density (cells/mm ²)	2688 (n = 177)	1956 (n = 177)	1855 (n = 177)	1756.5 (n = 177)	1709.5 (n = 177)
IQR (cells/mm ²)	207.5	264.8	320.5	306.5	288.0
Relative cell loss	—	27%	31%	35%	36%

DSAEK = Descemet stripping automated endothelial keratoplasty; IQR = interquartile range.

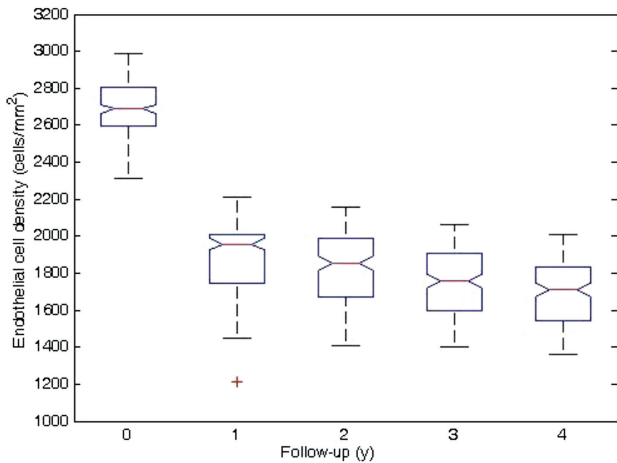


Fig. 7. Box plot of endothelial cell density over the 4-year follow-up period. On each box, the inner line is the median and the edges of the box are the 25th and 75th percentiles (also called first and third quartiles and indicated as q1 and q3, respectively). The whiskers extend to the most extreme data points not considered outliers, and outliers are plotted individually using a plus sign (+). The area between the first and third quartile is the interquartile range and it gives a measure of statistical dispersion of the data. The whisker length, w , has been set to 1.5, corresponding to approximately $\pm 2.7\sigma$ and 99.3% coverage if the data are normally distributed. Points are drawn as outliers if they are larger than $q3 + w(q3 - q1)$ or smaller than $q1 - w(q3 - q1)$.

outlined an average ECL of 37% at 6 months and 42% at 12 months, using a variety of insertion techniques. Ang et al²⁰ compared the endothelial cell damage using two DSAEK insertion techniques, and showed that the ECL was greater using the Sheets glide technique (29.5% at 1 year; 35.7% at 2 years) compared with the EndoGlide insertion technique (16.3% at 1 year; 23.8% at 2 years). No significant differences in terms of ECL were found by Wendel et al²¹ between the bifold forceps insertion technique (42.5% at 1 year) and the cartridge injector suture pull-through insertion technique (51.4% at 1 year). By contrast, Foster et al²² found that the use of an injector device has a decreased ECL compared with a trifold forceps technique.

A comparison between DSAEK outcomes and PK from a Cornea Donor Study showed a higher ECL with DSAEK at 1 year post-transplantation.²³ By contrast, Lee et al,⁶ upon reviewing 34 articles about DSAEK, noted that ECL with DSAEK seems higher than PK at 6 months, but equivalent to PK at 12 months. A 3-year postoperative outcomes comparison between DSAEK and PK from the Cornea Donor Study has also been realized. This study showed an ECL comparable between the two groups, and that a 5-mm DSAEK incision width was associated with significant cell loss compared with the 3.2-mm incision.²⁴ Nevertheless, the Cornea Donor Study reported an overall cell loss of 69% (donors aged 12–65 years) and 75% (donors aged 66–75 years) at 5 years after PK.²⁵

In our study, we noted a 27% cell loss 1 year after the surgery, mostly comparable with the data for the other technique. As shown in Fig. 7, the endothelial cell density decreased over time, achieving a 31% cell loss at 2 years and a 35% cell loss at 3 years, with statistically significant decreases. The ECL tended to stabilize, however, and at 4 years after the surgery, the decrease of 36% was not significantly different from the 3-year value.

Another point worth mentioning is that 98.4% of all the corneas (192 eyes) in our series were clear after 4 years, demonstrating that the limiting factor is not the absolute number of endothelial cells but the functionality of the residual cellular pump.

Other limitations of DSAEK are the high rate of donor dislocation and the risk of pupillary block. The American Academy of Ophthalmology report⁶ highlighted the posterior graft dislocation

as the most common complication while performing DSAEK (mean 14%, range 0–82%). Consequently, various techniques have been devised to minimize these complications. For example, to avoid donor dislocation, Gorovoy⁵ devised a technique in which an air bubble that fills the entire anterior chamber is placed at the end of surgery, leaving the bubble in place for 1 hour. The air is then partially evacuated through a previously placed paracentesis site, while the patient is positioned in front of a slit lamp. The dislocation rate in this series of 16 patients was 25%; pupillary block was not assessed in this study. Koenig and Covert²⁶ reported a dislocation rate of 35% in their series of 26 eyes undergoing DSAEK using a 4.2-mm access incision for insertion of an 8.5-mm donor disk, with approximately half of the air bubble removed at the end of surgery. They used a temporal intraoperative peripheral iridectomy with a case of pupillary block.

Price and Price⁹ modified their original technique using fenestration incisions in addition to corneal surface massage to remove the interface fluid before the end of surgery. The rate of dislocation was reduced from 50% in their first 10 cases without using these maneuvers to 10.5% (21/200) when combining these two modifications. Terry et al²⁷ advocated a technique of peripheral recipient bed scraping to promote donor adherence leaving a residual supportive air bubble, which was freely mobile and ≤ 9 mm in diameter. They had a 1.5% dislocation rate in their series of 200 consecutive cases, without a single case of pupillary block.

In our study, we had a low rate of dislocation (4.6%) over 4 years. This low rate was likely due to several factors. First, we performed a manual dissection of the Descemet membrane from the posterior stromal surface with a reverse Sinsky hook. This would create a rough surface with exposed stromal fibrils that aid the donor attachment, as described by Terry et al.²⁷ In addition, attachment of the donor disk is favored by the introduction of as much air as possible into the anterior chamber at the end of surgery (Fig. 8).

The presence of air in the anterior chamber increased the risk of pupillary block, which occurred in 15 eyes (7.7%). However, in all 15 cases the pupillary block was resolved by evacuating air from a previously placed paracentesis site with a spatula in front of a slit lamp. For resolution of such blocks, it is important that the patient is monitored every 2 hours during the 1st day after the surgery.

During the insertion, we did not use an anterior-chamber maintainer because the corneal incision of 4.1 mm is sufficient to prevent the collapse of the anterior chamber. This represents another advantage of our proposed technique, reducing the incidence of intraoperative complications and graft dislocation.

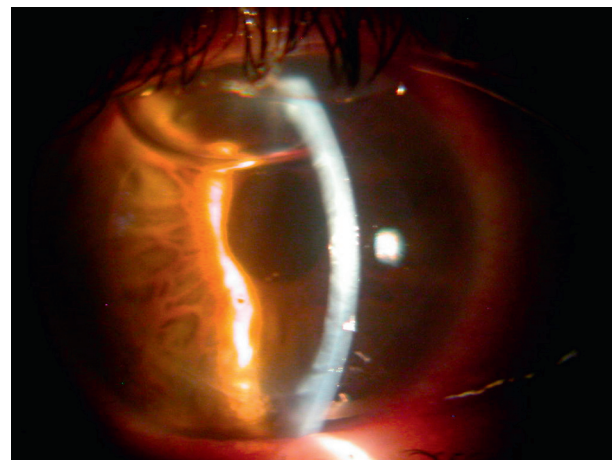


Fig. 8. Day 1 postoperative slit-lamp photograph showing injection of air into the anterior chamber at the 12 o'clock incision and the complete adherence of donor lenticule.

In conclusion, DSAEK is a more appropriate procedure to replace diseased or damaged endothelium, rather than performing a full-thickness corneal transplant. In this series, we introduced the donor tissue using a double-armed suture. This procedure represents a simplified and safe technique that provides ECL comparable with other techniques described previously. Suture pull-through insertion of the graft donor in DSAEK has several advantages, including lower rates of intraoperative and postoperative complications, a shorter learning curve, and contained costs. However, long-term follow up is necessary to confirm these encouraging data.

References

- Melles GR, Eggink FA, Lander F, et al. A surgical technique for posterior lamellar keratoplasty. *Cornea*. 1998;17:618–626.
- Terry MA, Ousley PJ. Deep lamellar endothelial keratoplasty in the first United States patients: early clinical results. *Cornea*. 2001;20:239–243.
- Melles GR, Wijdh RH, Nieuwendaal CP. A technique to excise the Descemet membrane from a recipient cornea (descemetorhexis). *Cornea*. 2004;23:286–288.
- Price MO, Price Jr FW. Descemet's stripping with endothelial keratoplasty: comparative outcomes with microkeratome-dissected and manually dissected donor tissue. *Ophthalmology*. 2006;113:1936–1942.
- Gorovoy MS. Descemet-stripping automated endothelial keratoplasty. *Cornea*. 2006;25:886–889.
- Lee WB, Jacobs DS, Musch DC, Kaufman SC, Reinhart WJ, Shtein RM. Descemet's stripping endothelial keratoplasty: safety and outcomes: a report by the American Academy of Ophthalmology. *Ophthalmology*. 2009;116:1818–1830.
- Bahar I, Kaiserman I, McAllum P, Slomovic A, Rootman D. Comparison of posterior lamellar keratoplasty techniques to penetrating keratoplasty. *Ophthalmology*. 2008;115:1525–1533.
- Melles GR, Lander F, Rietveld FJ. Transplantation of Descemet's membrane carrying viable endothelium through a small scleral incision. *Cornea*. 2002;21:415–418.
- Price Jr FW, Price MO. Descemet's stripping with endothelial keratoplasty in 50 eyes: a refractive neutral corneal transplant. *J Refract Surg*. 2005;21:339–345.
- Melles GR, Lander F, van Dooren BT, Pels E, Beekhuis WH. Preliminary clinical results of posterior lamellar keratoplasty through a sclerocorneal pocket incision. *Ophthalmology*. 2000;107:1850–1856.
- Mehta JS, Por YM, Beuerman RW, Tan DT. Glide insertion technique for donor cornea lenticule during Descemet's stripping automated endothelial keratoplasty. *J Cataract Refract Surg*. 2007;33:1846–1850.
- Melles GR, Lander F, Nieuwendaal C. Sutureless, posterior lamellar keratoplasty: a case report of a modified technique. *Cornea*. 2002;21:325–327.
- Melles GR, Remeijer L, Geerards A, Beekhuis WH. The future of lamellar keratoplasty. *Curr Opin Ophthalmol*. 1999;10:253–259.
- Kuo AN, Harvey TM, Afshari NA. Novel delivery method to reduce endothelial injury in descemet stripping automated endothelial keratoplasty. *Am J Ophthalmol*. 2008;145:91–96.
- Macaluso C. Closed-chamber pulling-injection system for donor graft insertion in endothelial keratoplasty. *J Cataract Refract Surg*. 2008;34:353–356.
- Sarnicola V, Toro P. Descemet-stripping automated endothelial keratoplasty by using suture for donor insertion. *Cornea*. 2008;27:825–829.
- Tukey JW. *Exploratory Data Analysis*. Reading, MA: Addison-Wesley; 1977.
- McGill R, Tukey JW, Larsen WA. Variations of box plots. *Am Stat*. 1978;32:12–16.
- Mearza AA, Qureshi MA, Rostron CK. Experience and 12-month results of descemet-stripping endothelial keratoplasty (DSEK) with a small-incision technique. *Cornea*. 2007;26:279–283.
- Ang M, Saroj L, Htoon HM, Kiew S, Mehta JS, Tan D. Comparison of a donor insertion device to sheets glide in Descemet stripping endothelial keratoplasty: 3-year outcomes. *Am J Ophthalmol*. 2014;157:1163–1169.
- Wendel LJ, Goins KM, Sutphin JE, Wagoner MD. Comparison of bifold forceps and cartridge injector suture pull-through insertion techniques for Descemet stripping automated endothelial keratoplasty. *Cornea*. 2011;30:273–276.
- Foster JB, Swan KR, Vasan RA, Greven MA, Walter KA. Small-incision Descemet stripping automated endothelial keratoplasty: a comparison of small-incision tissue injector and forceps techniques. *Cornea*. 2012;31:42–47.
- Price MO, Gorovoy M, Benetz BA, et al. Descemet's stripping automated endothelial keratoplasty outcomes compared with penetrating keratoplasty from the Cornea Donor Study. *Ophthalmology*. 2010;117:438–444.
- Price MO, Gorovoy M, Price Jr FW, Benetz BA, Menegay HJ, Lass JH. Descemet's stripping automated endothelial keratoplasty: three-year graft and endothelial cell survival compared with penetrating keratoplasty. *Ophthalmology*. 2013;120:246–251.
- Cornea Donor Study Investigator Group, Gal RL, Dontchev M, et al. The effect of donor age on corneal transplantation outcome results of the cornea donor study. *Ophthalmology*. 2008;115:620–626.
- Koenig SB, Covert DJ. Early results of small-incision Descemet's stripping and automated endothelial keratoplasty. *Ophthalmology*. 2007;114:221–226.
- Terry MA, Shamie N, Chen ES, Hoar KL, Friend DJ. Endothelial keratoplasty a simplified technique to minimize graft dislocation, iatrogenic graft failure, and upillary block. *Ophthalmology*. 2008;115:1179–1186.