

## A novel technique of pulmonary artery banding by means of radiofrequency ablation: An experimental study in rabbits

*Radyofrekans ablasyon yoluyla yeni bir pulmoner arter bant tekniği:  
Tavşanlarda deneysel bir çalışma*

Fahrettin Uysal<sup>1</sup>, Tuğberk Akça<sup>1</sup>, Abdüsselam Genç<sup>1</sup>, Zehra Avcı Küpeli<sup>4</sup>, Erencan Özfırat<sup>3</sup>,  
Uygur Canatan<sup>3</sup>, Berfin Uysal<sup>5</sup>, Işık Şenkaya Sığnak<sup>2</sup>

*Institution where the research was done:*  
Uludağ University Faculty of Medicine, Bursa, Türkiye

### *Author Affiliations:*

<sup>1</sup>Department of Pediatric Cardiology, Uludağ University Faculty of Medicine, Bursa, Türkiye

<sup>2</sup>Department of Cardiovascular Surgery, Uludağ University Faculty of Medicine, Bursa, Türkiye

<sup>3</sup>Department of General Surgery, Uludağ University Faculty of Veterinary Medicine, Bursa, Türkiye

<sup>4</sup>Department of Pathology, Uludağ University Faculty of Veterinary Medicine, Bursa, Türkiye

<sup>5</sup>Department of Pediatric Nephrology, Bursa University of Health Sciences, Bursa City Hospital, Bursa, Türkiye

### **ABSTRACT**

**Background:** The aim of this study was to evaluate the efficacy and feasibility of a novel method of narrowing pulmonary arteries with catheter angiography using radiofrequency energy in rabbits.

**Methods:** A total of nine New Zealand white rabbits weighing 3.0 to 4.2 kg each were utilized in this experimental study. After the location of pulmonary artery was confirmed by echocardiography and angiography, radiofrequency energy was applied by starting with 5 W energy for the first time and increasing by 5 W, if there was no rupture to a maximum of 20 W. Multiple applications of radiofrequency energy with different durations were performed at different levels of the pulmonary artery. Eight weeks later, surviving rabbits were sacrificed. The pulmonary arteries were removed for histological investigation.

**Results:** Five rabbits remained alive after the experiment. There was a significant correlation between radiofrequency power and the degree of vessel thickness change in the pulmonary artery. The endothelial integrity of the tunica intima was impaired in all groups and the diameter of vessel was thickened by an average of 3.5 times.

**Conclusion:** The narrowing of the pulmonary artery using radiofrequency energy was successfully performed in a small sample size of experimental animals in this study.

**Keywords:** Catheter angiography, pulmonary artery banding, radiofrequency energy.

### **ÖZ**

**Amaç:** Bu çalışmada tavşanlarda radyofrekans kullanılarak kateter anjiyografi ile pulmoner arterlerin daraltılmasına ilişkin yeni bir yöntemin etkinliği ve uygulanabilirliği değerlendirildi.

**Çalışma planı:** Bu deneysel çalışmada, her biri 3.0 ila 4.2 kg ağırlıkta toplam dokuz Yeni Zelanda beyaz tavşanı kullanıldı. Pulmoner arterin yeri ekokardiyografi ve anjiyografi ile tespit edildikten sonra, ilk seferinde 5 W enerji ile başlanılarak ve rüptür yoksa maksimum 20 W olacak şekilde 5'er W artırılarak radyofrekans enerjisi uygulandı. Farklı sürelerde pulmoner arterin farklı seviyelerine birden fazla radyofrekans enerji uygulaması yapıldı. Sekiz hafta sonra sağ kalan tavşanlar sakrifiye edildi. Histolojik inceleme için pulmoner arterler çıkarıldı.

**Bulgular:** Deney sonrasında beş tavşan sağ kaldı. Radyofrekans gücü ve pulmoner arterde damar kalınlığında görülen değişiklik derecesi arasında anlamlı bir ilişki saptandı. Tunika intimanın endotelial bütünlüğü tüm gruplarda bozuldu ve damar çapı ortalama 3.5 kat kalınlaştı.

**Sonuç:** Bu çalışmada küçük bir deneysel hayvan örneklemini üzerinde radyofrekans enerjisi ile pulmoner arter başarılı bir şekilde daraltıldı.

**Anahtar sözcükler:** Kateter anjiyografi, pulmoner arter bantlama, radyofrekans enerjisi.

*Received:* September 24, 2021 *Accepted:* February 25, 2022 *Published online:* July 29, 2022

**Correspondence:** Fahrettin Uysal, MD, Uludağ Üniversitesi Tıp Fakültesi, Çocuk Kardiyoloji Bilim Dalı, 16059 Nilüfer, Bursa, Türkiye.

Tel: +90 224 - 295 04 12 e-mail: fahrettinuysal@uludag.edu.tr

### **Cite this article as:**

Uysal F, Akça T, Genç A, Avcı Küpeli Z, Özfırat E, Canatan U, et al. A novel technique of pulmonary artery banding by means of radiofrequency ablation: An experimental study in rabbits. Turk Gogus Kalp Dama 2022;30(3):327-333

©2022 All right reserved by the Turkish Society of Cardiovascular Surgery.

This is an open access article under the terms of the Creative Commons Attribution-NonCommercial License, which permits use, distribution and reproduction in any medium, provided the original work is properly cited and is not used for commercial purposes (<http://creativecommons.org/licenses/by-nc/4.0/>).

Pulmonary artery banding (PAB) operation was first applied in 1951 by Muller and Danimann,<sup>[1]</sup> and has been performed for many years, particularly in cases of congenital heart disease with increased pulmonary blood flow. The most prevalent clinical scenario has been to restrict pulmonary blood flow in patients with pulmonary hypercirculation caused by massive left-to-right shunts. Due to surgical technique advancements and improvements in postoperative care in recent years, this palliative procedure has been mostly replaced by the primary repair procedure. However, the classic surgical approach is also utilized in individuals who are candidates for anatomic biventricular repair and have a morphological right ventricle in the systemic circulation.<sup>[2]</sup>

Pulmonary artery banding in corrected congenital transposition of the great arteries is used not only to restrain the sub-pulmonary left ventricle, but also as an early preventative therapy in neonates to prevent severe tricuspid regurgitation associated with the morphological (RV) in the systemic position.<sup>[3,4]</sup> Furthermore, PAB has been shown to improve left ventricle and mitral valve function in young children with left ventricle dilated cardiomyopathy.<sup>[5]</sup>

In the present study, we developed a novel method of narrowing pulmonary arteries with catheter angiography using radiofrequency (RF) energy in rabbits and aimed to evaluate the efficacy and feasibility of this novel method.

## MATERIALS AND METHODS

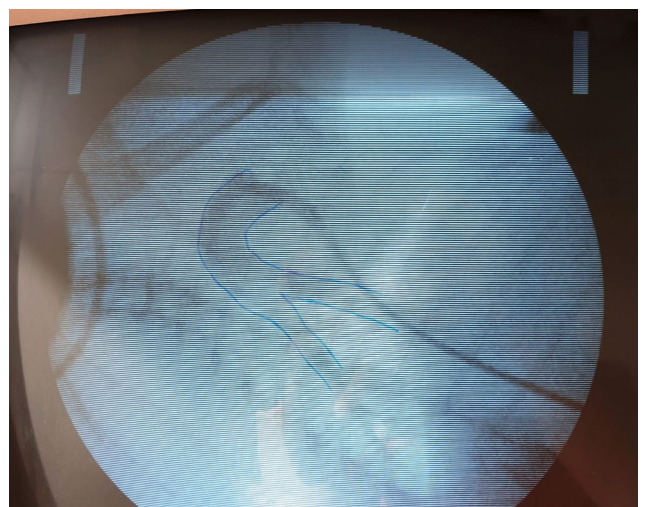
In this study, nine (5 male, 4 female) New Zealand white rabbits weighing 3.0 to 4.2 kg each were utilized in this experiment (median weight: 3.24 kg). All rabbits were randomly numbered from one to nine.

Intramuscular injections of 50 mg/kg ketamine hydrochloride and 5 mg/kg xylazine hydrochloride were used to anesthetize the rabbits. Intravenous prophylactic ceftriaxone (20 mg/kg) was given to all rabbits before the procedure. Clippers were used to shave the rabbits' anterior neck and back hair. After attaching the grounding pad of an RF generator (ATAKR Plus Generator, Medtronic® Inc., Minneapolis, MN, USA) to each rabbit's back, they were placed in a dorsal recumbent position. Echocardiography with CW Doppler (Philips HP Sonos 5500®, Hewlett-Packard, Co., Andover, MA, USA) was administered before the procedure to determine the transpulmonary gradient. After injecting 2 to 3 mL of 2% lidocaine, a 2-cm vertical midline incision in the right ventral femoral region was made. After the right femoral vein was exposed with the cut-down technique, a 7-Fr introducer

sheath (Cordis Avanti®, Johnson & Johnson, New Jersey, USA) was placed into the vein with the assistance of a C-arm fluoroscopy device. Before RF energy was applied, a diagnostic angiogram of the pulmonary artery and its branches was performed using a 5-Fr diagnostic (N.I.H. Cordis®, Johnson & Johnson, New Jersey, USA) catheter. A contrast agent (Omnipaque 300®, Nycomed Imaging AS, Oslo, Norway) was employed at a dose of 3 mL/kg, and the location of the pulmonary valve was determined.

The 7-Fr RF ablation catheter (Marinr Medtronic® Inc., Minneapolis, MN, USA) was, then, placed 1.5 to 2-cm above the pulmonary valve and connected to the generator (Figure 1). After the location was confirmed by echocardiography, RF energy was applied by starting with 5 Watts (W) energy for the first time and increasing by 5 W, if there was no rupture to a maximum of 20 W. In each rabbit, multiple applications of unipolar RF energy with different durations were performed at different levels of the pulmonary artery. Power, temperature, and duration of provided energy were recorded. The duration of the delivered energy was adjusted by the system and automatically stopped when the surrounding tissue impedance increased by more than 50%. The trial was discontinued after the vessel (main pulmonary artery) ruptured. The degree of stenosis in the pulmonary artery was measured during the procedure using CW Doppler. After RF application was completed, the sheath was removed, the femoral vein was sutured, and subcutaneous tissue and skin were sutured in a sterile manner.

Eight weeks later, surviving rabbits were sacrificed with high-dose propofol. The pulmonary arteries



**Figure 1.** The positioning of ablation catheter.

**Table 1. Pulmonary artery velocities and vessel thickness before and after radiofrequency energy applications**

	RFp (W)	Duration (sec)	Temp (°C)	PAVb (m/sec)	PAVa (m/sec)	NVT (µm)	VTRL (µm)	Increase (%)
Rabbit#1	3-3	60-60	50	0.85	2.9	173.94	433.40	149.16
Rabbit#2	20-15	30-120	50	0.67	2.4	98.18	437.24	345.34
Rabbit#7	15-20	90-90	50	0.67	1.42	175.92	1017.79	478.55
Rabbit#8	12-8-10	90-90-120	50	0.73	1.46	239.91	662.88	176.30
Rabbit#9	11-8-15	150-150-150	60	0.65	1.17	167.60	718.08	328.44

RFp: Radiofrequency energy power; PAVa: Pulmonary artery velocity after procedure; PAVb: Pulmonary artery velocity before procedure; NVT: Normal vessel thickness; VTRL: Vessel thickness with RF lesion.

were removed for histological investigation, and the surrounding tissue was macroscopically examined for heat damage. Histopathological examinations were conducted using hematoxylin and eosin stains.

In the histopathological examination, normal vessel thickness (NVT) and vessel diameters in the localization where the RF lesion was given (VTRL) were measured as µm. The percent change (%) was calculated with the formula  $(VTRL - NVT) \times 100 / NVT$ .

### Statistical analysis

Statistical analysis was performed using the IBM SPSS version 24.0 software (IBM Corp., Armonk, NY, USA). Descriptive data were expressed in mean ± standard deviation (SD) or number and frequency. The Pearson’s correlation analysis was used to evaluate the relationship between two continuous variables. A *p* value of <0.05 was considered statistically significant.

## RESULTS

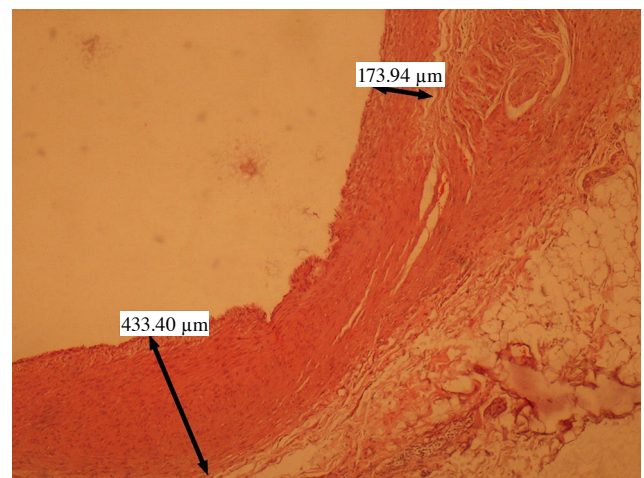
Five rabbits remained alive after the experimental operation. Rabbits #4 and #5 died as a result of abdominal perforation while introducing the sheath. These rabbits did not receive any RF energy. Pericardial tamponade occurred in Rabbit #3 during the third RF lesion with 15 W/60 sec/50°C. Pericardiocentesis was performed promptly under echocardiography guidance, and the rabbit was resuscitated successfully. However, the subject died one day after the procedure. Rabbit #6 had anesthesia-induced respiratory arrest after two successful RF applications and no hemopericardium or rupture was observed in this rabbit on postmortem examination.

Prior to RF application, angiography and color Doppler imaging revealed no pulmonary artery stenosis in any of the rabbits. All results are shown in Table 1.

Rabbit #1: RF application was performed two times with a maximum of 3 W and 50°C (total time: 120 sec). Pulmonary artery CW Doppler velocity was measured as 0.85 and 2.9 m/sec before and immediately after RF application, respectively. Histopathology revealed endothelial irregularity and increased tunica media thickness (Figure 2).

Rabbit #2: RF application was given twice at a maximum power of 20 W and 30 sec and 15 W and 120 sec with a temperature of 50°C (total time; 150 sec). Pulmonary artery velocity increased to 2.4 m/sec, and there was significant intimal hypertrophy in the histopathological examination (Figure 3).

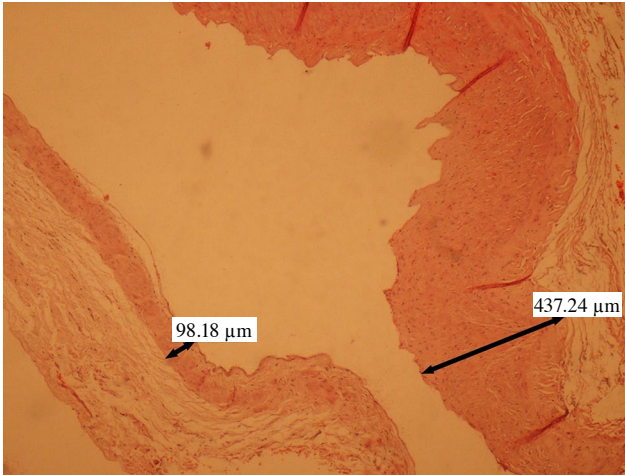
Rabbit #7: RF energy was applied successfully twice: once at a maximum power of 15 W for 90 sec, and once at a maximum power of 20 W for 90 sec at a temperature of 50°C (total time: 180 sec). The pulmonary artery velocity was initially measured at 0.67 m/sec and was calculated to be 1.42 m/sec at the



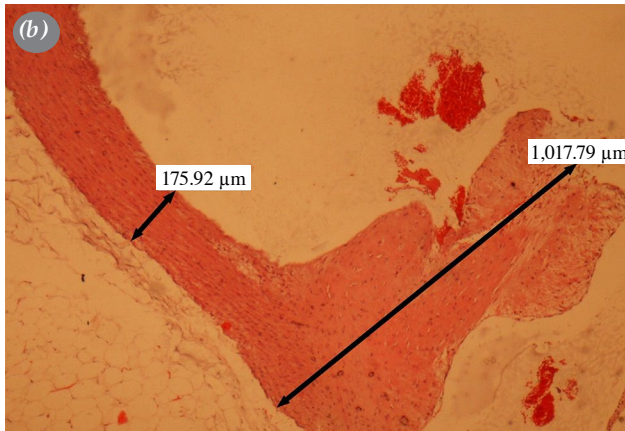
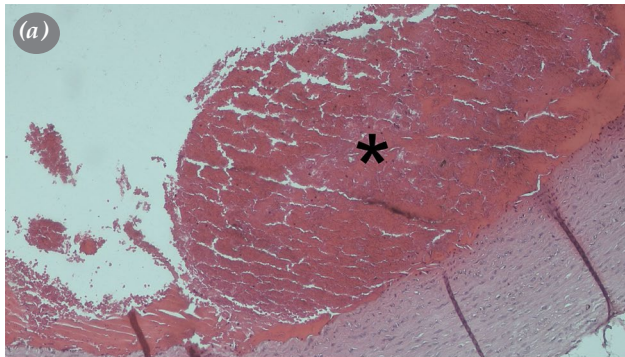
**Figure 2.** Endothelial irregularity and increased tunica media thickness was seen in Rabbit#1 histopathology.



end of the treatment. The thickness of the normal and RF applied vessel were 175.92  $\mu\text{m}$  and 1017.79  $\mu\text{m}$ , respectively. A red-orange homogeneous thrombus



**Figure 3.** Histopathological examination revealed significant intimal hypertrophy in Rabbit #2.




**Figure 4.** Histopathology of pulmonary artery in Rabbit #7; the thickness of the normal and RF applied vessel were 175.92  $\mu\text{m}$  and 1017.79  $\mu\text{m}$ , respectively (a), red-orange homogeneous thrombus formation was observed which adhered to the vessel endothelium (b).

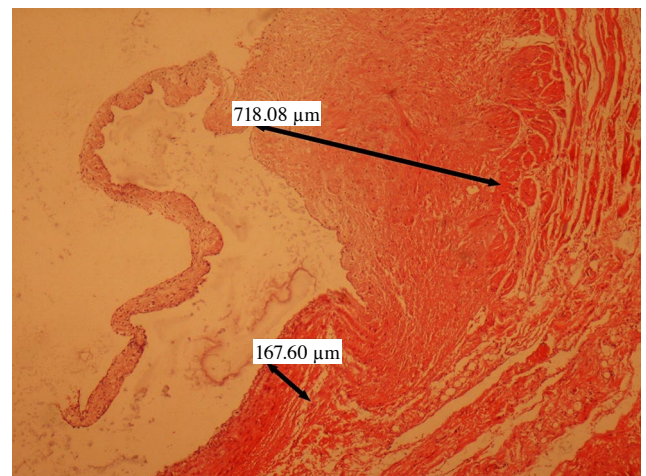
formation was observed in one area of the vessel lumen, which adhered to the vessel endothelium (Figure 4a, b).

Rabbit #8: RF energy was applied three times for a total of 300 sec. The RF energy had a power of 12, 8, and 10 W with periods of 90, 90, and 120 sec, respectively. Pulmonary artery velocity increased to 1.46 m/sec after three RF applications. Histopathological sections revealed compromised endothelial integrity and significant medial layer hypertrophy (Figure 5).

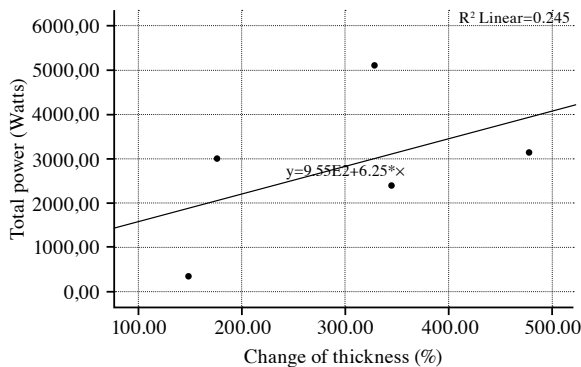
Rabbit #9: RF energy of 11, 8, and 15 W was applied to the pulmonary artery at intervals of 150-150-150 sec with a total duration of 450 sec and



**Figure 5.** Histopathological sections revealed compromised endothelial integrity and significant medial layer hypertrophy in Rabbit #8.



**Figure 6.** Microscopy of the pulmonary artery revealed significant thickness of the tunica media as well as bleeding and edema in Rabbit #9.



**Figure 7.** Positive correlation between radiofrequency energy power and the degree of vessel thickness change in the pulmonary artery.

a temperature of 60°C. Following the procedure, the pulmonary artery CW Doppler velocity increased from 0.65 to 1.17 m/sec. Microscopy of the pulmonary artery revealed significant thickness of the tunica media, as well as bleeding and edema (Figure 6).

There was a significant correlation between RF power and the degree of vessel thickness change in the pulmonary artery ( $p=0.02$ ) (Figure 7).

In histopathology, the endothelial integrity of the tunica intima was impaired in the RF lesion in all groups, and that there were myocyte and fibrocyte irregularities, as well as necrotic areas in the tunica adventitia. In most cases, edema in the tunica adventitia was observed. When the areas affected by the RF performed lesion were compared to other healthy areas, they were thickened by an average of 3.5 times.

## DISCUSSION

Although PAB operations are less common these days, they are still applied in complex congenital heart disease cases with increased pulmonary blood flow and single ventricle physiology, particularly in newborns and infants in whom primary repair is not possible. It is also performed in novel indications like dilated cardiomyopathy.<sup>[6]</sup> Although technically straightforward, PAB has high mortality and morbidity rates even at the most experienced facilities.<sup>[7-9]</sup> Complications with PAB include erosion and migration of the pulmonary band, which results in insufficient stenosis of the pulmonary artery; distal migration, leading to distortion and stenosis of the branch pulmonary arteries and impingement on the pulmonary valve apparatus.<sup>[10]</sup> Additionally, the concept of staged surgical operations in complex congenital heart diseases dramatically increases

patients' cumulative surgical risk. The endoluminal pulmonary artery band procedure was described as a result of these difficulties.<sup>[11]</sup> The pulmonary artery is restricted internally in this technique to prevent the band from being displaced, and the patient also benefits from the fact that it may be dilated with catheter angiography. Although the endoluminal band approach has been proven to have lower mortality and morbidity, the usage of cardiopulmonary bypass (CPB) has a substantial drawback.

Radiofrequency radiation is the most often utilized energy source in cardiac catheterization ablation treatments, and it has been effectively utilized in children for many years as a conventional way to treat practically all types of supraventricular tachycardia and certain kinds of ventricular tachycardia.<sup>[12]</sup> The main goal of this operation is to effectively erode the essential tissue that causes tachycardia and stop it without causing damage to the surrounding tissue. Ablation causes irreversible damage by raising the temperature over 50°C and causing coagulation necrosis in the targeted tissue. The amount of damage to the target tissue is related to the quantity of energy delivered and the degree of contact between the catheter and the tissue. The current density at the electrode tip (related to the amount of energy delivered and the electrode surface area), the electrode-myocardial contact, the catheter tip direction, the applied energy time, and the temperature reached at the electrode tip are the most critical determinants of ablation damage.<sup>[13]</sup> Only the tissue in direct contact with the electrode tip is strongly affected by heat owing to resistance with this energy, while conductive heat transfer causes the majority of the lesion to proceed slowly. Thermal continuity is a condition in which ablation lesions continue to proliferate even after RF energy is turned off.<sup>[14]</sup> *In vivo* and *ex vivo* investigations have shown that lesions formed with bipolar ablation are deeper, smaller, and more likely to attain transmural than lesions created with normal unipolar ablation or consecutive unipolar ablation at nearby sites surrounding the region of interest.<sup>[15]</sup> Considering that it would not be appropriate to use such a powerful mode in a small subject such as a rabbit, we applied standard unipolar RF ablation in our study.

Pulmonary valvotomy application using RF energy has been successfully applied for years in pulmonary atresia cases.<sup>[16]</sup> Likewise, the treatment of venous varicose veins using the RF energy method has been used quite frequently in recent years.<sup>[17]</sup> A rabbit model of artery stenosis was effectively described using

endovascular RF radiation in one study.<sup>[18]</sup> In this study, the appropriate energy dose to create more than 50% stenosis was found to be 24 to 26 W for 1.5 min for the aorta, while this value was calculated as 6 W for 1 min for the carotid artery. Histopathological examination showed necrosis of the intima and media smooth muscle layer. The RF Mariner Medtronic® catheter has been widely used for years for ablation in the treatment of arrhythmia; however, it was used for a new purpose for the first time in this study and in this sense this study is unique.

In our study, it was hypothesized that it would be possible to narrow the pulmonary artery using a RF energy source without surgery. A total of nine rabbits were included in the experiment. During femoral vein access, two rabbits had sheath-related abdominal perforation, and RF energy could not be administered to them. These rabbits weighed 3 kg, and perforation was assumed to have happened due to the thick sheath diameter. It was thought that this problem would be eliminated with the lower sheath sizes. Another rabbit received RF energy for the third time at 15 W, and hemopericardium occurred after 150 sec. The rabbit was resuscitated successfully, and the hemopericardium was self-limited, but it died one day later. In the other rabbit that died during the procedure, respiratory depression due to anesthesia occurred after RF energy with 3 W was administered for 60 sec. Although these two rabbits were given RF energy, they were not included in the research due to a lack of follow-up data.

In the current study, velocities were calculated for all rabbits before and after RF. However, it is very difficult to measure the velocity with echocardiography in rabbits and is affected by many factors. The most important of these is the heart rate in rabbits. While normal heart rates were above 150/min, these values were above 200/min in most rabbits due to the effect of ketamine during the procedure. Therefore, changes in vessel diameters were noted and compared as a more precise data rather than transpulmonary gradient.

The remaining five rabbits in the trial were monitored for eight weeks before being sacrificed, and histological investigations were conducted. It was found that the RF energy power and the thickness of the vessel sections in these rabbits had a positive significant correlation. Histopathological examination revealed intimal proliferation, tunica media thickening, and endothelial irregularities. Thrombus formation was detected in Rabbit #7 with the greatest increase in vessel thickness. The second RF energy was given

with 20 W and 90 sec in this rabbit, and this lesion was considered to be the most effective. We considered that the maximum effect could be obtained by administering 20 W for at least 90 sec. Nonetheless, additional studies are required with more experimental animals to standardize the power and duration of RF energy.

Another important issue in this study is that RF energy was given to the pulmonary artery accompanied by fluoroscopy and completely incidentally. As a result, the RF lesion in the vessel could not be generated in a circular pattern. This problem was supposed to be readily avoidable using three-dimensional (3D) mapping technologies, which are now widely utilized in the treatment of arrhythmia. Using these mapping technologies, RF energy-given areas could be marked, and a circular and more controlled lesion could be created with a good contact (for example with ThermoCool® SmartTouch® catheter, Biosense Webster, Irvine, CA, USA), establishing a model like the pulmonary band method. More experimental studies using 3D mapping methods are needed to prove this hypothesis.

There are some limitations to this study. The number of subjects in the study was not enough to make a definite comment. Echocardiographic evaluation in rabbits was very difficult due to thorax anatomy and velocity measurements could not be determined clearly due to very fast heart rates during catheter angiography. Therefore, further investigation with a larger population is required to confirm our results and the broader applicability. If the main pulmonary artery can be constricted circularly by standardized RF energy using 3D mapping systems, then the following conditions may result: The transcatheter pulmonary band technique may be developed experimentally for the first time as an alternative to the open surgical method, which is a frequently used method in complex congenital heart diseases, and its use in humans can be discussed in the future. The CPB effect used in pulmonary band operation may be eliminated. The cumulative risk of mortality and morbidity caused by staged surgery, which is frequently used in complex congenital heart diseases, may be reduced. The extremely high mortality rate of open heart surgery can be reduced in patients with low birth weight or whose general condition is very poor to tolerate the operation, where complete correction is not possible immediately, and who have a high risk of pulmonary hypertension. The risk of band migration, which is an important morbidity of pulmonary band operations, can be eliminated. The risk of deterioration of the

pulmonary artery structure, which occurs over time as a result of PAB operation and which is sometimes important enough to prevent the final surgery of patients, can be minimized.

In conclusion, the narrowing of the pulmonary artery using radiofrequency energy instead of the surgical pulmonary banding procedure was performed in a small sample size of experimental animals in this study. Based on our study results, this technique should be standardized in future studies with three-dimensional mapping systems in future experimental animals.

**Ethics Committee Approval:** The experiment in this study was conducted in compliance with our institute's animal care and experimentation rules, which were reviewed and approved by the Institutional Animal Care and Use Committee.

**Data Sharing Statement:** The data that support the findings of this study are available from the corresponding author upon reasonable request.

**Author Contributions:** Idea/concept: F.U., T.A., A.G.; Design: F.U., T.A., A.G.; Control/supervision: F.U.; Data collection and/or processing: A.G., I.S.S.; Analysis and/or interpretation: E.Ö., T.A.; Literature review: U.G., B.U., A.G.; Writing the article: F.U., T.A., A.G.; Critical review: Z.A.K.; References and fundings: Z.A.K.; Materials; B.U., U.C., T.A.

**Conflict of Interest:** The authors declared no conflicts of interest with respect to the authorship and/or publication of this article.

**Funding:** The authors received no financial support for the research and/or authorship of this article.

## REFERENCES

1. Muller WH Jr, Danimann JF Jr. The treatment of certain congenital malformations of the heart by the creation of pulmonic stenosis to reduce pulmonary hypertension and excessive pulmonary blood flow; a preliminary report. *Surg Gynecol Obstet* 1952;95:213-9.
2. Winlaw DS, McGuirk SP, Balmer C, Langley SM, Griselli M, Stümper O, et al. Intention-to-treat analysis of pulmonary artery banding in conditions with a morphological right ventricle in the systemic circulation with a view to anatomic biventricular repair. *Circulation* 2005;111:405-11.
3. Murtuza B, Barron DJ, Stumper O, Stickley J, Eaton D, Jones TJ, et al. Anatomic repair for congenitally corrected transposition of the great arteries: A single-institution 19-year experience. *J Thorac Cardiovasc Surg* 2011;142:1348-57.e1.
4. Metton O, Gaudin R, Ou P, Gerelli S, Mussa S, Sidi D, et al. Early prophylactic pulmonary artery banding in isolated congenitally corrected transposition of the great arteries. *Eur J Cardiothorac Surg* 2010;38:728-34.
5. Schranz D, Rupp S, Müller M, Schmidt D, Bauer A, Valeske K, et al. Pulmonary artery banding in infants and young children with left ventricular dilated cardiomyopathy: A novel therapeutic strategy before heart transplantation. *J Heart Lung Transplant* 2013;32:475-81.
6. Schranz D, Recla S, Malcic I, Kerst G, Mini N, Akintuerk H. Pulmonary artery banding in dilative cardiomyopathy of young children: Review and protocol based on the current knowledge. *Transl Pediatr* 2019;8:151-60.
7. Alsoufi B, Manlihot C, Ehrlich A, Oster M, Kogon B, Mahle WT, et al. Results of palliation with an initial pulmonary artery band in patients with single ventricle associated with unrestricted pulmonary blood flow. *J Thorac Cardiovasc Surg* 2015;149:213-20.
8. Ereğ E, Yağınbaş YK, Türkekul Y, Oztarhan K, Colakoğlu A, Saygılı A, et al. Pulmoner arter bant ameliyatı ve sonrasında biventriküler ve üniventriküler tamir sonuçları. *Anadolu Kardiyol Derg* 2009;9:215-22.
9. Hoseinikhah H, Moeinipour A, Zarifian A, Sheikh Andalibi M, Moeinipour Y, Abbassi Teshnisi M, et al. Indications, results and mortality of pulmonary artery banding procedure: A brief review and five-year experiences. *International Journal of Pediatrics* 2016;4:1733-44.
10. Puga FJ. Appropriate palliative intervention for infants with double inlet ventricle and tricuspid atresia with discordant ventriculoarterial connection: Role of pulmonary artery banding. *J Am Coll Cardiol* 1990;16:1465-6.
11. Locker C, Dearani JA, O'Leary PW, Puga FJ. Endoluminal pulmonary artery banding: Technique, applications and results. *Ann Thorac Surg* 2008;86:588-95.
12. Sandhu A, Nguyen DT. Forging ahead: Update on radiofrequency ablation technology and techniques. *J Cardiovasc Electrophysiol* 2020;31:360-9.
13. Haines DE. The biophysics of radiofrequency catheter ablation in the heart: The importance of temperature monitoring. *Pacing Clin Electrophysiol* 1993;16:586-91.
14. Nath S, DiMarco JP, Haines DE. Basic aspects of radiofrequency catheter ablation. *J Cardiovasc Electrophysiol* 1994;5:863-76.
15. Gizurarson S, Spears D, Sivagangabalan G, Farid T, Ha AC, Massé S, et al. Bipolar ablation for deep intra-myocardial circuits: Human ex vivo development and in vivo experience. *Europace* 2014;16:1684-8.
16. Brown SC, Cools B, Boshoff D, Heying R, Eyskens B, Gewillig M. Radiofrequency perforation of the pulmonary valve: An efficient low cost solution. *Acta Cardiol* 2017;72:419-24.
17. Gohel MS, Davies AH. Radiofrequency ablation for uncomplicated varicose veins. *Phlebology* 2009;24 Suppl 1:42-9.
18. Lazoura O, Zacharoulis D, Kanavou T, Rountas C, Katsimboulas M, Tzovaras G, et al. A novel experimental animal model of arterial stenosis based on endovascular radiofrequency energy application. *J Invest Surg* 2011;24:123-8.