

CASE REPORT

High-flux hemodialysis after administering high-dose methotrexate in a patient with posttransplant lymphoproliferative disease and impaired renal function

Alexander Reshetnik¹, Christian Scheurig-Muenkler², Markus van der Giet¹ & Markus Tölle¹

¹Department of Nephrology, Charité – Universitaetsmedizin Berlin, Campus Benjamin Franklin, Hindenburgdamm 30, 12203 Berlin, Germany

²Department of Radiology, Charité – Universitaetsmedizin Berlin, Campus Benjamin Franklin, Hindenburgdamm 30, 12203 Berlin, Germany

Correspondence

Alexander Reshetnik, Department of Nephrology, Charite - Universitaetsmedizin Berlin, Campus Benjamin Franklin, Hindenburgdamm 30, 12203 Berlin, Germany. Tel.: + 49 30 450 514 552; Fax: + 49 30 450 514 951; E-mail: alexander.reshetnik@charite.de

Funding Information

No sources of funding were declared for this study.

Received: 3 October 2014; Revised: 31

March 2015; Accepted: 30 April 2015

Clinical Case Reports 2015; 3(11): 932–936

doi: 10.1002/ccr3.302

Key Clinical Message

A young patient develops cerebral posttransplant lymphoproliferative disorder. Despite concurrent significantly impaired transplant kidney function use of add-on high-flux hemodialysis for additional clearance made the administration of high-dose methotrexate feasible in this patient without occurrence of acute chronic kidney failure and significant hematological toxicity.

Keywords

high-dose methotrexate, high-flux hemodialysis, posttransplant lymphoproliferative disorders.

Introduction

Posttransplant lymphoproliferative disorders (PTLD) are among the most dangerous and potentially fatal complications after transplantation. With the cumulative incidence of 1–3% in the first five years after renal transplantation, they are among the most common malignancies complicating solid organ transplantation [1]. PTLD are lymphoid and/or plasmatic proliferations, which develop under the condition of continuous immunosuppression and consequently decreased T-cell surveillance and are in most cases related to an Epstein-Barr virus infection [2]. The management of PTLD varies significantly according to the type and site of the presenting disease, ranging from reducing immunosuppression to administration of rituximab, chemotherapy or radiotherapy, or a combination of all of these.

The prevalence of PTLD in central nervous system (CNS) is 2–7% [3], thus CNS is an uncommon site of PTLD, particularly when appearing as a first manifestation

site, and its diagnosis and treatment are difficult [4]. The administration of high-dose methotrexate (HDMTX) is an established therapy for patients with primary central nervous system lymphoma [5]. There is also evidence showing the effectiveness of HDMTX in transplanted patients with PTLD [6]. HDMTX can be administered safely in patients with normal renal function inducing vigorous hydration and alkalization of the urine as well as the use of leukovorine rescue to prevent a potentially lethal MTX toxicity [7]. Renal excretion is the main way of MTX clearance [8], thus, an impaired kidney function delays the excretion of MTX resulting in a marked increase in toxicity, in particular, bone marrow toxicity, which could be fatal for the patient. This consideration limits the use of HDMTX in patients with an impaired kidney function. In our case report, we describe the successful use of high-flux hemodialysis (HFHD) for add-on clearance of MTX after administering HDMTX to a patient with a cerebral manifestation of PTLD and a preexisting impaired function of a renal transplant.

Case Presentation

A 26-year-old male patient (height: 180 cm; weight: 74 kg) was admitted to the local hospital in March 2013 because of a new-onset headache and blurred vision. He received a kidney transplant in 1997 because of an end-stage kidney disease of unknown origin since 1989. Immunosuppression on admission consisted of mycophenolate sodium 720 mg bid and methylprednisolone 4 mg qd. The estimated glomerular filtration rate (eGFR) was 35.9 mL/min/1.73 qm according to CKD-EPI equation with a proteinuria of 117 mg/d, corresponding to chronic kidney transplant disease stage 3bA1 according to KDIGO classification. The reasons for established chronic transplant nephropathy were status post vascular rejection 1997 and chronic calcineurin-inhibitor toxicity. Several contrast-enhancing intracerebral lesions with perifocal edema were seen on cranial CT- and MRI scans. A methylprednisolone therapy was stopped and dexamethasone was administered to reduce the brain edema. The patient was transmitted to the university department of Nephrology and, after an initial evaluation, to the department of Neurosurgery for confirming the diagnosis of suspected brain lymphoma through a brain biopsy. Histologically, the diagnosis of cerebral PTLD (diffuse large B-cell lymphoma positive for Epstein-Barr virus) was established. No additional manifestations of lymphoma were evident in a CT scan of the thorax, abdomen sonography, and bone marrow biopsy. After an initial chemotherapy regime (five cycles high-dose cytarabin [3 g/qm] und Rituximab [375 mg/qm] intravenous), an MRI scan confirmed complete remission of PTLD. However, the impairment of the transplant function aggravated (eGFR 25.4 mL/min/1.73 qm, CKD-EPI equation). In August–September 2013 cytomegalovirus (CMV) reactivated and pneumocystis jirovecii pneumonia occurred, so the chemotherapy was changed to Rituximab only in higher dose (500 mg/qm) and the patient received antiviral and antibiotic therapy. The dose of mycophenolate sodium was tapered to 360 mg bid because of sustained leukopenia and infections.

In December 2013 generalized seizure occurred. The cerebral MRI scan demonstrated the recurrence of PTLD. The patient received intravenous HDMTX (4 g/m²)/Leukovorine (30 mg/m²), and Rituximab (500 mg/m²) under vigorous hydration. The baseline kidney transplant function was still markedly reduced without any evidence of acute kidney injury and thus the HDMTX therapy was administered under supportive HFHD. Dialysis procedures started 24 h after administration of HDMTX until MTX-level in serum was no longer measurable. No acute kidney failure occurred after discontinuing dialysis. A nadir of leucocytes of 1.11/nL occurred 10 days after

HDMTX-use but did not require administration of granulocytes colony-stimulating factor. On the thirteenth day after the administration of the chemotherapy the patient developed severe CMV- and E.coli pneumonia with consecutive sepsis and acute kidney transplant failure requiring transmission to an intensive care unit and invasive ventilation. The sepsis was successfully managed with discontinuation of mycophenolate sodium and administering of antiviral and antibiotic therapy. The follow up cerebral MRI scan (January 2014) showed only a small regredience of PTLD and because of the life-threatening septic event after chemotherapy the only remaining opportunity of cerebral radiation was offered to the patient. Unfortunately, no relevant response of the disease occurred after application of elected radiotherapy.

Methods

The data collection of dialysis parameters, MTX-level measurements and details on MTX administration were performed according to the proposed methodology from the guidelines for reporting case studies on extracorporeal treatments in poisonings [9].

All dialysis procedures were performed with a Gambro machine AK 200 with high-flux dialyser (Polyflux 170H) and dialysate SelectBag One AX 450 G (potassium 4 mmol/L, calcium 1.50 mmol/L, glucose 1.0 g/L) from Gambro®, Stockholm, Sweden. The dialysate flow was 500 mL/min and the blood flow was 250 mL/min. Unfractionated heparin was used as anticoagulation substance for dialysis sessions. Overall, four dialysis sessions were performed each lasting four hours. The first dialysis session was conducted 24 h after administration of HDMTX, the second after 36 h, the third after 48 h, and the fourth after 72 h.

Measurements of MTX-level were introduced in serum with fluorescence polarization immunoassay on the TDx analyser (Fa. Abbott).

Discussion

In this report, we demonstrated a case of successful HDMTX use without development of severe bone marrow toxicity and acute kidney failure in a patient with an impaired kidney function, using a supportive HDHF (Figure 1).

MTX toxicity is an important issue and often limits therapy possibilities of this drug. Renal impairment appears to be one of the most important risk factors for MTX toxicity giving already low-dose MTX [10]. More than 90% of MTX are cleared by the kidneys through glomerular filtration and proximal tubular secretion. Thus, impaired kidney function causes sustained elevated

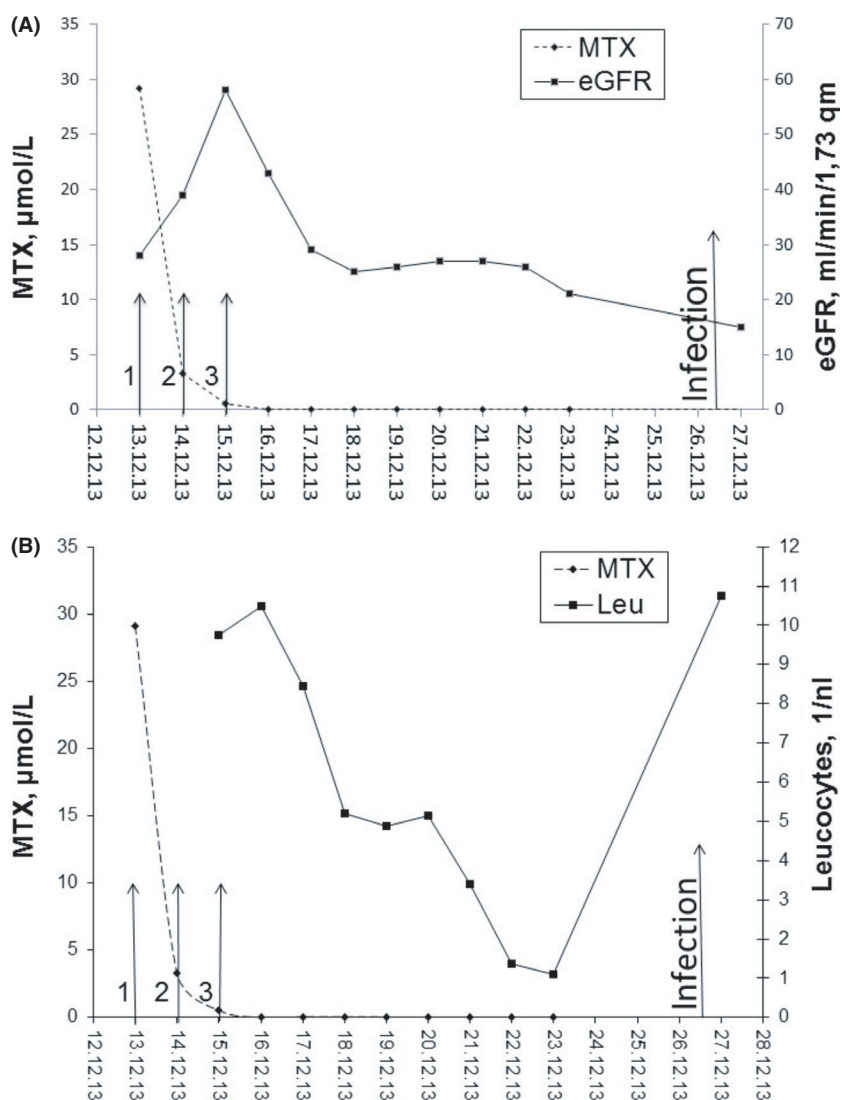


Figure 1. (A) Changes in methotrexate (MTX) level and leucocytes (Leu) and (B) changes in MTX level and estimated glomerular filtration rate (eGFR) during high-flux haemodialysis sessions (HD); High-dosis MTX was administered on 12 December 2013; 1- first HD session; 2- second and third HD session; 3- fourth HD session.

plasma MTX concentrations, which in turn may lead to increased hematological toxicity. MTX can also lead to an acute renal dysfunction, which is believed to be mediated through the precipitation of MTX and its metabolites in the renal tubules or by a direct toxicity of MTX on the renal tubules [11]. Consequently, the therapy with HDMTX has traditionally been avoided or used with great caution in patients with impaired renal function. Our patient suffered a recurrence of his PTLD after a first modality of the chemotherapy, so the switch to HDMTX therapy was necessary despite the sustained impaired kidney function, given that HDMTX is an established therapy of central nervous system lymphoma with studies demonstrating its superiority over radiation

or chemotherapy regimes without HDMTX [12]. In order to prevent MTX toxicity in the patient with significantly impaired baseline kidney function HFHD was arranged for add-on MTX elimination in addition to vigorous hydration and alkalinization of the urine and leucovorin rescue.

MTX is a small molecule (454 kd) and thus dialysis-based methods would be feasible for MTX clearance. However, approximately 50% of MTX is protein bound and the substance has a large distribution volume [11, 13], making dialysis a possible but not a perfect method to clear MTX. Nevertheless, a successful elimination of MTX was described for different modalities of renal replacement therapy such as hemodialysis, hemodiafiltration, Charcoal hemoperfusion/hemofiltration with majority of evidence

favoring HFHD [13, 14]. To our knowledge, there are only several case reports describing the successful use of HFHD for MTX elimination, including, thus far, either patients with preliminary normal kidney function and acute kidney failure following HDMTX use and requiring dialysis or patients with end-stage renal disease already on dialysis [15–18].

We noted a successful elimination of MTX after only several dialysis sessions in our patient without a significant rebound of MTX level after the dialysis was finished. Though the measured MTX-levels at 24, 48, and 72 h were highly predictive for greater risk of nephrotoxicity [13], no changes in the estimated glomerular filtration rate occurred after termination of the dialysis (Figure 1). With the support of HFHD, the hematological toxicities were limited: the level of leucocytes dropped to 1.1/nL but the patient did not require any granulocyte colony-stimulating factor; preexisting anemia did not impair significantly, and no changes in the number of thrombocytes occurred. The infection developed could be caused through a leucopenia. It is noteworthy that our patient had already a preexisting CMV-colonization and had developed frequent relapses of CMV-activation in the past, so he was at a high risk of a new CMV reactivation. Substantial additional risk factors such as posttransplant immunosuppressive therapy, impaired kidney function, and rituximab could also have contributed to the development of the infection.

This case is unique as we used HDMTX in a patient with a preliminary significantly impaired kidney function but not on dialysis for the first time and showed a feasibility of administering HDMTX in such patients using add-on HFHD for MTX clearance without any major hematological toxicity and without an onset of an acute on chronic kidney failure. This case underpins the limited evidence of a successful elimination of MTX with HFHD, though the administration of HDMTX did not achieve a remission of PTLD in this particular patient. We used HDMTX as an *ultima ratio*, as it was the last chemotherapy option for the recurrent PTLD. As demonstrated in our report, an administration of HDMTX is also possible in a transplant kidney with already preliminary impaired function. However, it should be considered that such patients have other comorbidities, which limit their tolerance of an aggressive therapy. The question about the right time to start the dialysis after HDMTX administration and appropriate duration of dialysis sessions is still not answered conclusively and requires further research.

Acknowledgments

None.

Conflicts of interest

The authors declare no conflict of interest.

The results presented in this paper have not been published previously in whole or part, except in abstract format.

References

1. Adami, J., H. Gabel, B. Lindelof, et al. 2003. Cancer risk following organ transplantation: a nationwide cohort study in Sweden. *Br. J. Cancer* 89:1221–1227.
2. Hanto, D. W. 1995. Classification of Epstein-Barr virus-associated posttransplant lymphoproliferative diseases: implications for understanding their pathogenesis and developing rational treatment strategies. *Annu. Rev. Med.* 46:381–394.
3. Castellano-Sanchez, A. A., S. Li, J. Qian, et al. 2004. Primary central nervous system posttransplant lymphoproliferative disorders. *Am. J. Clin. Pathol.* 121:246–253.
4. Cavaliere, R., G. Petroni, M. B. Lopes, et al. 2010. Primary central nervous system post-transplantation lymphoproliferative disorder: an International Primary Central Nervous System Lymphoma Collaborative Group Report. *Cancer* 116:863–870.
5. National Comprehensive Cancer Center Guidelines 4/18/2006-last update, NCCN practice guidelines in oncology: non-immunosuppressed primary CNS lymphoma.
6. Taj, M. M., B. Messahel, J. Mycroft, et al. 2008. Efficacy and tolerability of high-dose methotrexate in central nervous system positive or relapsed lymphoproliferative disease following liver transplant in children. *Br. J. Haematol.* 140:191–196.
7. Bleyer, W. A. 1977. Methotrexate: clinical pharmacology, current status and therapeutic guidelines. *Cancer Treat. Rev.* 4:87–101.
8. Bleyer, W. A. 1978. The clinical pharmacology of methotrexate: new applications of an old drug. *Cancer* 41:36–51.
9. Lavergne, V., G. Ouellet, J. Bouchard, et al. 2014. Guidelines for reporting case studies on extracorporeal treatments in poisonings: methodology. *Semin. Dial.* 27:407–414.
10. Gutierrez-Urena, S., J. F. Molina, C. O. Garcia, et al. 1996. Pancytopenia secondary to methotrexate therapy in rheumatoid arthritis. *Arthritis Rheum.* 39:272–276.
11. Widemann, B. C., and P. C. Adamson. 2006. Understanding and managing methotrexate nephrotoxicity. *Oncologist* 11:694–703.
12. Ferreri, A. J., M. Reni, F. Pasini, et al. 2002. A multicenter study of treatment of primary CNS lymphoma. *Neurology* 58:1513–1520.

13. Kumar, N., and A. C. Shirali. 2014. What is the best therapy for toxicity in the setting of methotrexate-associated acute kidney injury: high-flux hemodialysis or carboxypeptidase G2? *Semin. Dial.* 27:226–228.
14. Widemann, B. C., F. M. Balis, B. Kempf-Bielack, et al. 2004. High-dose methotrexate-induced nephrotoxicity in patients with osteosarcoma. *Cancer* 100:2222–2232.
15. Wall, S. M., M. J. Johansen, D. A. Molony, et al. 1996. Effective clearance of methotrexate using high-flux hemodialysis membranes. *Am. J. Kidney Dis.* 28:846–854.
16. Saland, J. M., P. J. Leavey, R. O. Bash, et al. 2002. Effective removal of methotrexate by high-flux hemodialysis. *Pediatr. Nephrol.* 17:825–829.
17. Murashima, M., J. Adamski, M. C. Milone, et al. 2009. Methotrexate clearance by high-flux hemodialysis and peritoneal dialysis: a case report. *Am. J. Kidney Dis.* 53:871–874.
18. Mutsando, H., M. Fahim, D. S. Gill, et al. 2012. High dose methotrexate and extended hours high-flux hemodialysis for the treatment of primary central nervous system lymphoma in a patient with end stage renal disease. *Am J Blood Res* 2:66–70.

Supporting Information

Additional Supporting Information may be found in the online version of this article:

Data S1. Concurrent diseases and co-medication of patient at the presentation on March 2013.