



Original article

Excursion of bone-patella tendon-bone grafts during the flexion–extension movement in anterior cruciate ligament reconstruction: Comparison between isometric and anatomic reconstruction techniques

Yasuhiro Take^{a,b,c,*}, Tatsuo Mae^c, Ken Nakata^{a,c}, Shigeto Nakagawa^b, Yuta Tachibana^c,
Konsei Shino^b

^a *Medicine for Sports and Performing Arts, Department of Health and Sport Sciences, Osaka University Graduate School of Medicine, Osaka, Japan*

^b *Sports Orthopaedic Centre, Yukioka Hospital, Osaka, Japan*

^c *Department of Orthopaedic Surgery, Osaka University Graduate School of Medicine, Osaka, Japan*

Received 25 September 2014; revised 6 January 2015; accepted 27 March 2015

Available online 2 May 2015

Abstract

Background/objective: The purpose of this study was to elucidate the biomechanical differences between anterior cruciate ligament (ACL) grafts reconstructed by isometric and anatomic reconstruction techniques, based on their length changes.

Methods: One hundred and thirty-three knees with primary ACL reconstruction using the bone-patellar tendon-bone (BTB) graft were retrospectively identified. Twenty-two knees and 111 knees underwent isometric round tunnel (IRT) ACL reconstruction and anatomic rectangular tunnel (ART) ACL reconstruction, respectively.

Results: After femoral-side fixation of the graft in the surgery, the length change of the graft from 120° flexion to full extension was measured by using an isometric positioner at the tibial side. Both reconstructive techniques showed little length change from 120° to ~20° of flexion, followed by elongation of the graft, until full extension. The amount of length change of the grafts was 1.0 ± 0.7 mm with the IRT technique, and 3.4 ± 0.9 mm with the ART technique. These findings were significantly different, based on the Mann–Whitney *U* test ($p < 0.001$).

Conclusion: The native ACL has an intrinsic length change of 3–6 mm, and therefore the ART technique may more closely replicate the biomechanical function of the native ACL.

Copyright © 2015, Asia Pacific Knee, Arthroscopy and Sports Medicine Society. Published by Elsevier (Singapore) Pte Ltd. This is an open access article under the CC BY-NC-ND license (<http://creativecommons.org/licenses/by-nc-nd/4.0/>).

Keywords: anterior cruciate ligament reconstruction; biomechanics; isometric; length change

Introduction

Anterior cruciate ligament (ACL) reconstruction is a common surgery to restore knee stability after the rupture of the ACL. A wide variety of surgical techniques have been developed with regard to graft selection, tunnel position, graft fixation, etc. The allograft and autogenous graft are both selectable. However, the hamstring tendon, quadriceps tendon,

and bone-patellar tendon-bone (BTB) graft are available for the autogenous graft. The BTB graft especially has the advantage of bone-to-bone healing in the tunnel.¹

The graft used to be placed in an isometric fashion,² based on the findings that isometric graft placement resulted in good anterior stability within 1 mm.³ In this isometric reconstruction technique, the femoral socket was key in ensuring graft isometry. Previous studies revealed the anterior–superior border of the anatomical ACL footprint as the isometric point^{4–6}; however, after overdrilling a guide pin that was inserted at the point, the tunnel aperture occupied mostly the outside of the footprint. Thus, these grafts, which were least

* Corresponding author. Department of Orthopaedic Surgery, Osaka University Graduate School of Medicine, 2-2 Yamada-oka, Suita-city, Osaka, 565-0871, Japan.

E-mail address: yasuhiro-take@umin.ac.jp (Y. Take).

anatomical and nonphysiological, resulted in several problems such as impingement against the intercondylar notch/wall or the posterior cruciate ligament,^{7–9} and poor control in rotational stability because of vertical graft orientation.^{10–12}

Several recent studies on the anatomy of the ACL revealed the location of the true anatomical ACL footprint.^{13–15} After these findings, techniques on ACL reconstruction have changed toward an anatomy-oriented approach.^{16–20} Anatomic ACL reconstruction have clinically shown favourable outcomes.^{21–23} However, there is one concern in anatomic reconstruction: anatomically-reconstructed grafts may be exposed to excessive tensile stress during knee motion because of their reduced isometricity. In fact, studies using image analysis show that the theoretical length change of anatomically-reconstructed grafts was 3–6 mm.^{24,25} In a clinical setting, Yonetani et al²⁶ compared the length change of the grafts of the isometric bi-socket technique and the length change of the low socket—two tunnel technique, which were performed during the transitional period from isometric to truly anatomic ACL reconstruction. Yonetani et al²⁶ found no significant difference in the length change between the two techniques, although the low socket—two tunnel technique showed a slightly greater length change. Therefore, increased concern for the grafts in anatomic reconstruction has remained unsolved.

Based on these facts, the length change of the grafts reconstructed by the current truly anatomical technique should be clarified to better understand the limitations and the potential for more improvements of the current reconstruction techniques. For this reason, this study compared the length change of the BTB grafts in two reconstruction techniques: (1) the isometric round tunnel (IRT) technique and (2) the anatomical rectangular tunnel (ART) technique. In the IRT technique, a femoral tunnel is created in a so-called isometric point in the conventional round shape. In the ART technique, tunnels are rectangular and created within the anatomical femoral and tibial footprints.^{18,20} Our working hypothesis was that the length change of the grafts would be greater in the ART technique than in the IRT technique.

Materials and methods

Patients

One hundred and thirty-three knees that had undergone primary ACL reconstruction with BTB autogenous graft from 1996 to 2009 were retrospectively identified as the study subject. There were 107 males and 26 females, and their mean age was 21.5 years. At the ACL reconstruction, 63 patients had a lateral meniscal tear and 39 patients had a medial meniscal tear. Among patients with a lateral meniscal tear, 17 knees underwent meniscectomy and 46 knees underwent a meniscal repair. Among patients with a medial meniscal tear, 11 knees underwent meniscectomy and 28 knees underwent a meniscal repair.

With regard to the technique of ACL reconstruction, the IRT technique was performed between 1996 and 2001 on 22 knees, and the ART technique was performed after 2002 on 111 knees (Table 1). The mean age, male/female ratio, or

meniscal intervention was not significantly different between the two groups.

Isometric round tunnel ACL reconstruction

After debriding the torn ACL remnants to provide clear visibility, a 2.4-mm guide pin was inserted from the medial tibial cortex to the centre of the anatomical ACL footprint with a tibial drill guide system (Smith & Nephew Inc., Endoscopy Division, Andover, MA, USA). The guide pin was overdrilled using a 10-mm cannulated drill. A 2.4-mm guide pin was thereafter inserted through the tibial tunnel at the 1-o'clock or 11-o'clock position (i.e., the so-called isometric point located at the superoanterior border of the anatomical ACL footprint and on the lateral wall of the intercondylar notch). The pin was overdrilled with a 9- or 10-mm cannulated reamer to 25 mm in depth, and further overdrilled to the anterolateral femoral cortex with a 4.5-mm drill bit to create a socket 25 mm deep.

A 10-mm-wide BTB graft was harvested from the central portion of the patellar tendon with 15-mm-long bone plugs on both ends. The graft, which included the bone plugs on both ends, was folded longitudinally. Two No. 3 braided polyester sutures were passed through the tibial bone plug and the EndoButton fixation device (Smith & Nephew Inc., Endoscopy Division), and were tied according to the length of the femoral tunnel. On the other side of the graft, two No. 3 braided polyester sutures were also passed through the bone—tendon junction. The graft was passed from the tibial tunnel to the femoral socket, and fixed with the EndoButton device at the femoral side. To evaluate notch impingement, the graft was arthroscopically investigated for any interference by the notch roof during the flexion-extension motion of the knee. There was no notch impingement on the graft in any patient; therefore, notchplasty was not performed.

Anatomic rectangular tunnel ACL reconstruction

The ART technique is precisely described in published articles.^{18,20} In brief, after removing the ACL remnant, two 2.4-mm guide pins were inserted in parallel at a 5-mm distance at the anatomical femoral ACL footprint through the far anteromedial portal with the knee in deep flexion, and overdrilled with a 5-mm cannulated reamer. A 5 mm × 10 mm

Table 1
Demographic data of the patients.

	IRT technique	ART technique
Patients	22	111
Mean age, y	23.7 (14–45)	21.1 (13.9–44.4)
Sex ratio, male/female	20/2	87/24
MMX	4	7
MMR	4	24
LMX	2	15
LMR	9	37

Data are presented as *n* or *n* (range) unless otherwise indicated.

ART = anterior cruciate ligament; IRT = isometric round tunnel; LMR = lateral meniscal repair; LMX = lateral meniscectomy; MMR = medial meniscal repair; MMX = medial meniscectomy.

rectangular femoral socket was then created by dilating two drill holes to a 25-mm depth by using a specific dilator (Smith & Nephew Inc., Endoscopy Division).

To create a tibial tunnel, two guide pins were inserted in parallel along the medial tibial spine at a 5-mm distance by using the aforementioned tibial drill guide system. It was then overdrilled with a 5-mm canulated reamer. A 5 mm × 10 mm rectangular socket was created by dilating two drill holes using the outside-in dilator (Smith & Nephew Inc., Endoscopy Division).

A 10-mm wide BTB graft was harvested from the patellar tendon with 15-mm long bone plugs on both ends. The bone plugs were shaped into a cuboid shape (5 mm thick × 10 mm wide × 15 mm long) for the rectangular socket and tunnel. Two No. 2 strong sutures (Ultrasilk; Smith & Nephew Inc., Endoscopy Division) were sutured through the bone-tendon junction and the bone plug harvested from the tibial side. On the other side of the graft, one No. 2 strong suture was passed through the bone–tendon junction, whereas one No. 2 strong suture and one No. 3 polyester suture were passed through the bone plug. The graft was finally passed from the tibial tunnel to the femoral socket, and fixed with a 6 mm × 20 mm interference screw (Softsilk; Smith & Nephew Inc., Endoscopy Division) at the femoral side while adjusting the bone-tendon junction to the aperture of femoral socket.

Measurement of length change

The length change of the graft was measured using an isometric positioner (Smith & Nephew Inc., Endoscopy Division) in all patients before fixing the grafts at the tibial side because this measurement was our routine practice. A 5-mL plastic syringe was placed between the extra-articular aperture of the tibial tunnel and the isometric positioner to fix its position over the tibia. One pair of No. 3 polyester sutures on the tibial end of the graft was attached to the isometric positioner through the syringe (Fig. 1). The change in the graft length was then measured while the knee was extended from 120° of flexion to full extension. Great care was taken not to apply any anterior drawer or rotational stress during the measurement. The amount and the pattern²⁷ of the length change of the graft were recorded.

Statistical analysis

The Mann–Whitney *U* test was performed for statistical comparison between the IRT and ART techniques in the length changes of the grafts. For the patient demographics (Table 1), the Student *t* test was performed for the age and Fisher's exact test was performed for the male/female ratio and meniscal interventions. A *p* value < 0.05 was considered significant.

Results

All grafts, regardless of whether the IRT or ART technique was performed, showed an over-the-top pattern,²⁷ which was characterised by little length change from 120° to ~20° of flexion followed by elongation of the graft until full extension.

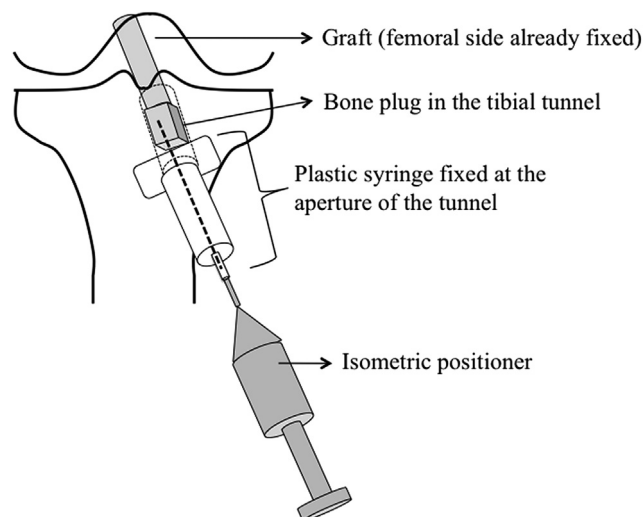


Fig. 1. Illustrative schema that represents the measurement of length change of an anterior cruciate ligament graft. The dotted line from the bone plug through the tunnel and the plastic syringe to the isometric positioner indicates the suture used to measure the length change of the graft.

The mean length change of the grafts in total was 1.0 ± 0.7 mm in the IRT technique, and 3.4 ± 0.9 mm in the ART technique (Fig. 2). There was a significant difference in length change between the two techniques ($p < 0.001$).

Discussion

Anterior cruciate ligament grafts are desired to mimic the morphology and biomechanical behaviour of the native ACL. The native ACL is non-isometric because it has a length change of ≤ 1.0 -mm when the knee is extended from 90° to 30°, and a length change of 3.1-mm when the knee is extended from 30° to 0°, as Markolf et al²⁸ reports. Image analyses show that the distance between the femoral and tibial anatomical ACL footprint increases as much as 5.5 mm from 135° of knee flexion to full extension,²⁴ and 3–6 mm from 100° of the knee flexion to full extension.²⁵ Of these studies, we considered the Markolf et al²⁸ study the best for the purpose of comparison with our result because it directly measured the length change of the

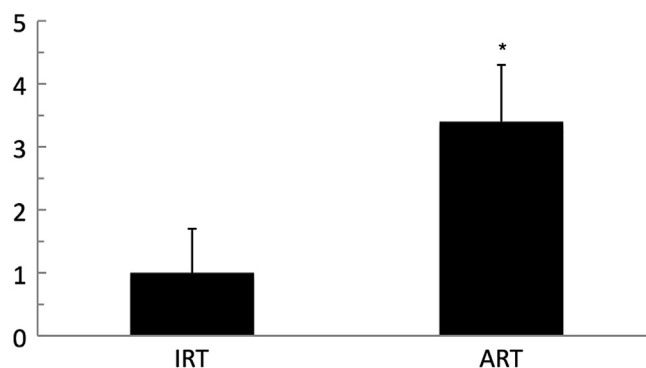


Fig. 2. The mean length change of the anterior cruciate ligament (ACL) grafts in the isometric round tunnel (IRT) technique and the anatomic rectangular tunnel (ART) technique. The length change in the ACL grafts is significantly larger in the ART technique than in the IRT technique. * $p < 0.001$.

native ACL. In the latter two studies,^{24,25} the distance between the femoral and tibial ACL insertions may not be directly proportional to the length change because the graft may become lax at some point. In addition, measurement of the length change may be affected by the friction and the creep of the graft. The ART technique showed a mean increase of 3.4 mm in the graft length when the graft approached extension in this study; therefore, a graft reconstructed by this technique may more closely replicate the biomechanical function of the native ACL, compared to the IRT technique.

Isometric grafting techniques such as the IRT technique were very popular in the past decade because of the isometric grafting concept that the isometrically-placed graft would be protected from stretch-out failure within the normal knee motion.³ In fact, several biomechanical studies investigated the true or ideal isometric position for the femoral tunnel using a wire or a suture,^{27,29–31} as well as the BTB graft,^{3,5,6} and some studies actually identified the ideal isometric position that could acquire a length change of ≤ 1 mm in the graft around the superior and anterior border of the anatomical ACL footprint.^{4–6} The IRT technique in this study also acquired a length change of 1.0 mm, which complied with the concept of an isometric graft placement. However, such less anatomical nonphysiological grafts showed impingement against the intercondylar notch/wall or the posterior cruciate ligament,^{7–9} and poor control in rotational stability because of the vertical graft orientation.^{10–12} Based on these findings and the findings of recent anatomical studies on the ACL,^{13–15} reconstruction techniques have changed toward more anatomy-oriented techniques.^{17–20,32}

Our results raised one concern regarding graft tension after anatomic ACL reconstruction. Fleming et al³³ report that the *in situ* force of the graft increased as the graft elongated. The length change of the grafts was greater in the ART technique than in the IRT technique; therefore, grafts in the ART technique could be exposed to more tensile stress by range-of-motion exercise in the early postoperative period. The re-rupture rate of anatomic double-bundle hamstring ACL grafts is clinically 4.7%,³⁴ and the re-rupture rate of BTB ACL grafts that were performed during the isometry-oriented era is 4.3%,³⁵ which seem to be comparable outcomes. However, the re-rupture rate varies significantly by age and activity³⁴; therefore, it should not be used as an indicator of graft overload and subsequent graft failure. To minimise the excessive load to the grafts in the ART technique, the initial tension for the graft should be set as low as possible. As for the anatomic double-bundle ACL reconstruction with hamstring tendon, 20 N of initial tension yielded good clinical outcomes.²³ The initial tension of 20 N in this study was based on a previous study focusing on the laxity-match pretension.³⁶ Laxity-match pretension was defined as the initial tension necessary to restore normal anteroposterior laxity,^{28,37} which was reported as 7.3 N for the anatomic double-bundle ACL reconstruction, and as 25.8 N for isometric bi-socket ACL reconstruction³⁶ at 20° on average. This difference could be reasonably explained in that the more horizontal orientation of the anatomic ACL graft could more effectively control the anterior tibial force.

Thus, the initial tension in the ART technique could be set sufficiently low to avoid overstress.

There were some limitations in our study. First, the study was not randomised, and there was a large difference in the number of patients between the two groups. This difference is primarily because the study retrospectively compared two surgical techniques that were performed at distinct time periods. Randomisation (i.e., performing the IRT technique randomly) is not acceptable because we believe that anatomic reconstruction should be more favourable to restore normal knee kinematics, compared to isometric reconstruction. Second, different fixation devices were used between the two techniques. The interference screw in the ART technique enabled rigid fixation of the bone plug just at the aperture in the socket, whereas the fixation obtained by the pullout suture and EndoButton on the femoral cortex in the IRT technique was less rigid. Taking into account that cortical fixation with the pullout suture and the button allowed more graft displacement, compared to the interference screw,³⁸ the length change could be estimated lower if the interference screw had been used in IRT technique. Thus, the difference between the fixation devices had little effect on our results. Third, in the present study, only the length change of the graft was measured under constant tension with the spring inside the isometer. It is very difficult to measure the tension to the graft after its fixation in a clinical setting; therefore, no direct tension measurement of the graft was performed. However, in our opinion, measuring the length change of the graft in the current study has clearly shown a biomechanical difference between the two techniques.

In conclusion, the length change of the grafts in the ART technique showed a mean elongation of 3.4 mm from 120° of flexion to extension, and was significantly greater than the length change of 1.0 mm in the IRT technique.

Conflicts of interest

Konsei Shino is a consultant for Smith & Nephew Endoscopy. Other authors declare no conflicts of interest.

References

1. Bilko TE, Paulos LE, Feagin JA, Lambert KL, Cunningham HR. Current trends in repair and rehabilitation of complete (acute) anterior cruciate ligament injuries. Analysis of 1984 questionnaire completed by ACL Study Group. *Am J Sports Med.* 1986;14:143–147.
2. Amis A, Zavras T. Isometricity and graft placement during anterior cruciate ligament reconstruction. *Knee.* 1995;2:5–17.
3. O'Meara PM, O'Brien WR, Henning CE. Anterior cruciate ligament reconstruction stability with continuous passive motion. The role of isometric graft placement. *Clin Orthop Relat Res.* 1992;277:201–209.
4. Sidles JA, Larson RV, Garbini JL, Downey DJ, Matsen FA. Ligament length relationships in the moving knee. *J Orthop Res.* 1988;6:593–610.
5. Cooper DE, Urrea L, Small J. Factors affecting isometry of endoscopic anterior cruciate ligament reconstruction: the effect of guide offset and rotation. *Arthroscopy.* 1998;14:164–170.
6. Cooper DE, Small J, Urrea L. Factors affecting graft excursion patterns in endoscopic anterior cruciate ligament reconstruction. *Knee Surg Sports Traumatol Arthrosc.* 1998;6(Suppl. 1):S20–S24.

7. Simmons R, Howell SM, Hull ML. Effect of the angle of the femoral and tibial tunnels in the coronal plane and incremental excision of the posterior cruciate ligament on tension of an anterior cruciate ligament graft: an *in vitro* study. *J Bone Joint Surg Am.* 2003;85-A:1018–1029.
8. Howell SM, Taylor MA. Failure of reconstruction of the anterior cruciate ligament due to impingement by the intercondylar roof. *J Bone Joint Surg Am.* 1993;75:1044–1055.
9. Toritsuka Y, Shino K, Horibe S, et al. Second-look arthroscopy of anterior cruciate ligament grafts with multi-stranded hamstring tendons. *Arthroscopy.* 2004;20:287–293.
10. Loh JC, Fukuda Y, Tsuda E, Steadman RJ, Fu FH, Woo SLY. Knee stability and graft function following anterior cruciate ligament reconstruction: comparison between 11 o'clock and 10 o'clock femoral tunnel placement. 2002 Richard O'Connor Award paper. *Arthroscopy.* 2003;19:297–304.
11. Woo SL-Y, Kanamori A, Zeminski J, Yagi M, Papageorgiou C, Fu FH. The effectiveness of reconstruction of the anterior cruciate ligament with hamstrings and patellar tendon. A cadaveric study comparing anterior tibial and rotational loads. *J Bone Joint Surg Am.* 2002;84-A:907–914.
12. Scopp JM, Jasper LE, Belkoff SM, Moorman CT. The effect of oblique femoral tunnel placement on rotational constraint of the knee reconstructed using patellar tendon autografts. *Arthroscopy.* 2004;20:294–299.
13. Ferretti M, Ekdahl M, Shen W, Fu FH. Osseous landmarks of the femoral attachment of the anterior cruciate ligament: an anatomic study. *Arthroscopy.* 2007;23:1218–1225.
14. Iwahashi T, Shino K, Nakata K, et al. Direct anterior cruciate ligament insertion to the femur assessed by histology and 3-dimensional volume-rendered computed tomography. *Arthroscopy.* 2010;26(9 Suppl.):S13–S20.
15. Shino K, Suzuki T, Iwahashi T, et al. The resident's ridge as an arthroscopic landmark for anatomical femoral tunnel drilling in ACL reconstruction. *Knee Surg Sports Traumatol Arthrosc.* 2010;18:1164–1168.
16. Musahl V, Plakseychuk A, VanScyoc A, et al. Varying femoral tunnels between the anatomical footprint and isometric positions: effect on kinematics of the anterior cruciate ligament-reconstructed knee. *Am J Sports Med.* 2005;33:712–718.
17. Yasuda K, Kondo E, Ichiyama H, et al. Anatomic reconstruction of the anteromedial and posterolateral bundles of the anterior cruciate ligament using hamstring tendon grafts. *Arthroscopy.* 2004;20:1015–1025.
18. Shino K, Nakata K, Nakamura N, Toritsuka Y, Nakagawa S, Horibe S. Anatomically oriented anterior cruciate ligament reconstruction with a bone-patellar tendon-bone graft via rectangular socket and tunnel: a snug-fit and impingement-free grafting technique. *Arthroscopy.* 2005;21:1402.
19. Shino K, Nakata K, Nakamura N, Mae T, Ohtsubo H, Iwahashi T, et al. Anatomic anterior cruciate ligament reconstruction using two double-looped hamstring tendon grafts via twin femoral and triple tibial tunnels. *Oper Tech Orthop.* 2005;15:130–134.
20. Shino K, Nakata K, Nakamura N, et al. Rectangular tunnel double-bundle anterior cruciate ligament reconstruction with bone-patellar tendon-bone graft to mimic natural fiber arrangement. *Arthroscopy.* 2008;24:1178–1183.
21. Muneta T, Koga H, Morito T, Yagishita K, Sekiya I. A retrospective study of the midterm outcome of two-bundle anterior cruciate ligament reconstruction using quadrupled semitendinosus tendon in comparison with one-bundle reconstruction. *Arthroscopy.* 2006;22:252–258.
22. Yasuda K, Kondo E, Ichiyama H, Tanabe Y, Tohyama H. Clinical evaluation of anatomic double-bundle anterior cruciate ligament reconstruction procedure using hamstring tendon grafts: comparisons among 3 different procedures. *Arthroscopy.* 2006;22:240–251.
23. Mae T, Shino K, Matsumoto N, et al. Anatomic double-bundle anterior cruciate ligament reconstruction using hamstring tendons with minimally required initial tension. *Arthroscopy.* 2010;26:1289–1295.
24. Yoo Y-S, Jeong W-S, Shetty NS, Ingham SJM, Smolinski P, Fu F. Changes in ACL length at different knee flexion angles: an *in vivo* biomechanical study. *Knee Surg Sports Traumatol Arthrosc.* 2010;18:292–297.
25. Iwahashi T, Shino K, Nakata K, et al. Assessment of the “functional length” of the three bundles of the anterior cruciate ligament. *Knee Surg Sports Traumatol Arthrosc.* 2008;16:167–174.
26. Yonetani Y, Toritsuka Y, Yamada Y, Iwahashi T, Yoshikawa H, Shino K. Graft length changes in the bi-socket anterior cruciate ligament reconstruction: comparison between isometric and anatomic femoral tunnel placement. *Arthroscopy.* 2005;21:1317–1322.
27. Odensten M, Gillquist J. Functional anatomy of the anterior cruciate ligament and a rationale for reconstruction. *J Bone Joint Surg Am.* 1985;67:257–262.
28. Markolf KL, Burchfield DM, Shapiro MM, Davis BR, Finerman GA, Slauterbeck JL. Biomechanical consequences of replacement of the anterior cruciate ligament with a patellar ligament allograft. Part I: insertion of the graft and anterior-posterior testing. *J Bone Joint Surg Am.* 1996;78:1720–1727.
29. Amis AA, Dawkins GP. Functional anatomy of the anterior cruciate ligament. Fibre bundle actions related to ligament replacements and injuries. *J Bone Joint Surg Br.* 1991;73:260–267.
30. Zavras TD, Race A, Bull AM, Amis AA. A comparative study of “isometric” points for anterior cruciate ligament graft attachment. *Knee Surg Sports Traumatol Arthrosc.* 2001;9:28–33.
31. Sapega AA, Moyer RA, Schneck C, Komalahiranya N. Testing for isometry during reconstruction of the anterior cruciate ligament. Anatomical and biomechanical considerations. *J Bone Joint Surg Am.* 1990;72:259–267.
32. Bedi A, Altchek DW. The “footprint” anterior cruciate ligament technique: an anatomic approach to anterior cruciate ligament reconstruction. *Arthroscopy.* 2009;25:1128–1138.
33. Fleming B, Beynon BD, Johnson RJ, McLeod WD, Pope MH. Isometric versus tension measurements. A comparison for the reconstruction of the anterior cruciate ligament. *Am J Sports Med.* 1993;21:82–88.
34. Mae T, Shino K, Matsumoto N, Yoneda K, Yoshikawa H, Nakata K. Risk factors for ipsilateral graft rupture or contralateral anterior cruciate ligament tear after anatomic double-bundle reconstruction. *Asia Pac J Sports Med Arthrosc Rehabil Technol.* 2014;1:90–95.
35. Shelbourne KD, Gray T, Haro M. Incidence of subsequent injury to either knee within 5 years after anterior cruciate ligament reconstruction with patellar tendon autograft. *Am J Sports Med.* 2009;37:246–251.
36. Mae T, Shino K, Matsumoto N, Hamada M, Yoneda M, Nakata K. Anatomical two-bundle versus Rosenberg's isometric bi-socket ACL reconstruction: a biomechanical comparison in laxity match pretension. *Knee Surg Sports Traumatol Arthrosc.* 2007;15:328–334.
37. Markolf KL, Burchfield DM, Shapiro MM, Cha CW, Finerman GA, Slauterbeck JL. Biomechanical consequences of replacement of the anterior cruciate ligament with a patellar ligament allograft. Part II: forces in the graft compared with forces in the intact ligament. *J Bone Joint Surg Am.* 1996;78:1728–1734.
38. Brown CH, Wilson DR, Hecker AT, Ferragamo M. Graft-bone motion and tensile properties of hamstring and patellar tendon anterior cruciate ligament femoral graft fixation under cyclic loading. *Arthroscopy.* 2004;20:922–935.