



Elucidating neuroanatomical alterations in the at risk mental state and first episode psychosis: A combined voxel-based morphometry and voxel-based cortical thickness study

Stefania Benetti ^{a,*}, William Pettersson-Yeo ^a, Chloe Hutton ^b, Marco Catani ^c, Steve CR Williams ^d, Paul Allen ^a, Lana M Kambaitz-Illankovic ^{a,e}, Philip McGuire ^a, Andrea Mechelli ^a

^a Department of Psychosis Studies, King's College London, Institute of Psychiatry, De Crespigny Park, London, SE5 8AF, UK

^b Wellcome Trust Centre for Neuroimaging, UCL Institute of Neurology, University College London, 12 Queen Square, London WC1N 3BG, UK

^c Department of Forensic and Neurodevelopmental Science, King's College London, Institute of Psychiatry, De Crespigny Park, London, SE5 8AF, UK

^d Department of Neuroimaging, Centre for Neuroimaging Sciences, Institute of Psychiatry, King's College London, De Crespigny Park, London, SE5 8AF, UK

^e Department of Psychiatry, Ludwig-Maximilians University, Nussbaumstr. 7, 80336 Munich, Germany

ARTICLE INFO

Article history:

Received 13 November 2012

Received in revised form 16 August 2013

Accepted 21 August 2013

Available online 29 September 2013

Keywords:

First Episode Psychosis

At Risk Mental State

VBM

Cortical thickness

Imaging

ABSTRACT

Previous studies have reported alterations in grey matter volume and cortical thickness in individuals at high risk of developing psychosis and patients in the early stages of the disorder. Because these studies have typically focused on either grey matter volume or cortical thickness separately, the relationship between these two types of alterations is currently unclear. In the present investigation we used both voxel-based cortical thickness (VBCT) and voxel-based morphometry (VBM) to examine neuroanatomical differences in 21 individuals with an At Risk Mental State (ARMS) for psychosis, 26 patients with a First Episode of Psychosis (FEP) and 24 healthy controls. Statistical inferences were made at $P < 0.05$ after correction for multiple comparisons. Cortical thinning in the right superior temporal gyrus was observed in both individuals at high risk of developing psychosis and patients with a first episode of the disorder, and therefore is likely to represent a marker of vulnerability. In contrast, the right posterior cingulate cortex showed cortical thinning in FEP patients relative to individuals at high risk, and therefore appears to be implicated in the onset of the disease. These neuroanatomical differences were expressed in terms of cortical thickness but not in terms of grey matter volume, and therefore may reflect specific cortical atrophy as opposed to variations in sulcal and gyral morphology.

© 2013 The Authors. Published by Elsevier B.V. Open access under [CC BY-NC-SA license](http://creativecommons.org/licenses/by-nc-sa/4.0/).

1. Introduction

There is increasing interest in the investigation of neuroanatomical alterations in clinically healthy individuals at high risk for psychosis and patients in the early stages of the disorder, in order to develop potential biomarkers for early diagnosis. The vast majority of the studies have examined neuroanatomical alterations by measuring grey matter volume (GMV) using voxel-based morphometry (VBM) (Kubicki et al., 2002; Pantelis et al., 2003; Narr et al., 2005; Borgwardt et al., 2007b; Borgwardt et al., 2008; Meisenzahl et al., 2008; Witthaus et al., 2009; Mechelli et al., 2011); in addition, a smaller number of studies have measured cortical thickness (CT) using a cortical surface-based approach (Wiegand et al., 2004; Fornito et al., 2008; Schultz et al., 2010; Ziermans

et al., 2010; Jung et al., 2011). With regard to patients in the early stages of psychosis, consistent GMV and CT alterations have been reported in medial and lateral temporal regions and, to a lesser extent, dorso-lateral prefrontal and cingulate regions (Kubicki et al., 2002; Wiegand et al., 2004; Narr et al., 2005; Fornito et al., 2008; Witthaus et al., 2009; Schultz et al., 2010; Bodnar et al., 2011; Jung et al., 2011). With regard to individuals at high risk of developing the disorder, GMV and CT alterations have been reported in frontal, cingulate and temporal regions (Borgwardt et al., 2007b; Witthaus et al., 2009; Ziermans et al., 2010; Jung et al., 2011).

The studies published so far have typically focused on either grey matter volume or cortical thickness separately; however these two measurements reflect complementary aspects of neuroanatomy and may provide different sensitivity depending on the pathophysiological process under investigation. More specifically, the analysis of cortical thickness targets the presence of specific cortical atrophy, whereas the analysis of grey matter volume returns a mixed measure which depends on local cortical thickness as well as cortical folding and gyrification (i.e. cortical surface area) (Hutton et al., 2008). Thus, when used in combination, GMV and CT measurements provide more comprehensive information about the underlying pathophysiological changes.

* Corresponding author at: Department of Psychosis Studies, PO Box 67, Institute of Psychiatry, King's College London, De Crespigny Park, London SE5 8AF, UK. Tel.: +44 207 848 0284; fax: +44 207 848 0967.

E-mail address: stefania.benetti@kcl.ac.uk (S. Benetti).

At present, only two studies have examined both GMV and CT in the early phases of psychosis (Voets et al., 2008; Takayanagi et al., 2011); these have reported discrepant findings as to whether GMV and CT alterations are expressed in similar or different areas. More specifically, Takayanagi et al. (2011) observed reduced CT and GMV in prefrontal and temporal regions in patients with a first episode of psychosis (Takayanagi et al., 2011). In contrast, Voets and colleagues showed widespread but focally distinct patterns of CT and GMV alterations in adolescents with early-onset schizophrenia (Voets et al., 2008). Moreover, to the best of our knowledge, no previous study has examined both aspects of neuroanatomy in both patients with a first episode of psychosis (FEP) and individuals at high risk of developing the disorder.

In the present study we therefore employed both voxel-based CT (VBCT; Hutton et al., 2008) and voxel-based morphometry (VBM; Ashburner and Friston, 2000) to investigate neuroanatomical alterations in patients with a first episode of psychosis (FEP) and individuals with an at risk mental state (ARMS) for psychosis relative to healthy controls. These two analytical techniques were chosen because they use the same pre-processing and registration procedures and allow the identification of voxel-level GMV and CT alterations within the same volumetric space, thereby minimizing any potential confounding methodological differences (Hutton et al., 2009; Nagy et al., 2011). Our main aim was to examine whether GMV and CT alterations precede the clinical manifestation of psychosis and therefore represent neuroanatomical markers of vulnerability to this disorder. We hypothesized that (1) both individuals with an ARMS and FEP patients would present with common cortical alterations in a network of interest comprising frontal, temporal and cingulate regions and (2) FEP patients would show more pronounced alterations compared to ARMS individuals in

these regions. Our secondary aim was to examine whether VBM and VBCT would reveal distinct or similar alterations within our network of interest. We expected that the two techniques would reveal focally distinct GMV and CT effects, reflecting different underlying pathophysiological processes.

2. Methods

2.1. Participants

The study was approved by the local Research Ethics Committee. Participants gave written informed consent after a full description of the aims and design of the study. The following exclusion criteria applied to all participants: (i) a history of neurological disorders; (ii) head trauma resulting in loss of consciousness for over 1 h; (iii) evidence of substance abuse and dependence disorder according to the DSM-IV criteria and (iv) suspected or confirmed pregnancy. All but one subject in each group were right-handed, while English was the first and native language of all the participants in this study.

2.1.1. First episode psychosis (FEP) group

Twenty-six subjects were recruited from early intervention services within the South London and Maudsley National Health Trust. All individuals presented for the first time to the local psychiatric services and met ICD-10 criteria schizophreniform psychosis (WHO, 1992). One patient only was medication naive while the remaining had been treated for a mean of 155 days at chlorpromazine equivalent mean dose of 242 mg/day. See Table 1 for the demographic characteristics of this sample.

Table 1
Demographic and clinical characteristics of the 70 participants.

	Healthy controls (n = 23)	At risk mental state (n = 21)	First episode psychosis (n = 26)	Statistics
Age (s.d.)	24.2 (4.2)	22.14 (3.3) ^a	26.08 (5.63) ^a	$F = 4.227 p = 0.019$
Male/female	12 M:11 F	9 M:12 F	18 M:8 F	$\chi^2 = 2.60, n.s.$
Premorbid IQ (s.d.)	108.8 (10.13)	101.5 (13.5)	101.81 (11.2)	$F = 2.924 p = 0.06$
Antipsychotic medication	23 N	2 M:19 N	24 M:2 N ^b	$\chi^2 = 54.32 p = 0.001$
Total intracranial volume cm ³ (s.d.)	1537 (187)	1538(190)	1520(148)	$F = 0.78, n.s.$
<i>Psychopathology scores, mean (s.d.)</i>				
PANSS total	NA	52.57 (9.0)	54.69 (14.5)	$t = -0.55, n.s.$
PANSS positive	NA	12.89 (3.6)	13.42 (5.2)	$t = -0.378, n.s.$
PANSS negative	NA	14 (4.08)	13.96 (4.9)	$t = 0.028, n.s.$
PANSS hallucinations	NA	2.73 (1.3)	1.92 (1.23)	$t = 2.09 p = 0.043$
PANSS delusions	NA	2.68 (1.62)	3.00 (1.62)	$t = -0.723, n.s.$
CAARMS total	NA	39.47(15.63)	NA	
<i>CAARMS intake criteria for ARMS</i>				
Global functioning and trait markers, No. (%) of subjects		2 (9.5)		
Attenuated psychotic symptoms, No. (%)		19 (90.5)		
Brief limited intermittent psychotic symptoms, No. (%)		2 (9.5)		
<i>Clinical outcome for ARMS (24 months)</i>				
Individuals with finished follow-up, No. (%)		9 (42.8)		
With transition, No. (%)		0		
Without transition, No. (%)		9(42.8)		
Drops-out/Unfinished follow-up, No. (%)		12(57.2)		
<i>Clinical outcome for FEP (12 months)</i>				
Schizophrenia/ongoing psychosis, No.			12 (46.1)	
Remission/stable mental state, No.			13 (50)	
Schizoaffective disorder, No.			0	
Mood disorder, No.			0	
Drops-out, No.			1 (3.9)	

Abbreviations: PANSS, Positive and Negative Syndrome Scale; CAARMS, Comprehensive Assessment of At Risk Mental State; No., number.

^a ARMS versus FEP.

^b Healthy controls versus FEP.

2.1.2. At Risk Mental State (ARMS) group

Twenty-one individuals meeting the Personal Assessment and Crisis Evaluation (PACE) criteria for the ARMS (Yung et al., 1998) on the basis of the Comprehensive Assessment for the ARMS (CAARMS; Yung et al., 2003a) were recruited through the Outreach and Support in South London (OASIS) service. Two ARMS participants only had been treated with antipsychotic medication (at chlorpromazine equivalent mean dose of 76.68 mg/day over the 18 months prior the MRI scan) while the remaining 17 subjects were medication naive. See Table 1 for the demographic characteristics of this sample.

2.1.3. Controls

Twenty-four healthy volunteers were recruited by advertisement from the local community. Additional exclusion criteria included (i) a current or past history of psychiatric illness, and (ii) the presence of psychosis in first-degree relatives. See Table 1 for the demographic characteristics of this sample.

2.2. Clinical assessment

The Positive and Negative Syndrome Scale (PANSS; Kay et al., 1987) was used to assess the presence and severity of symptoms in the clinical groups on the day of scanning while the Prodromal Questionnaire (Loewy et al., 2005) was used to confirm the absence of any psychotic syndromes in healthy volunteers. The general premorbid intellectual function was estimated using the reading subtest of the Wide Range Achievement (WRAT-R; Jastak and Wilkinson, 1984). The clinical characteristics for the three groups are reported in Table 1.

2.3. MRI analysis

2.3.1. MRI data acquisition

T1-weighted images were acquired on a 3.0 T GE Signa system (GE Medical Systems, Milwaukee), at the Maudsley Hospital, London, using a fast Spoiled Gradient Recalled (FSPGR) in Steady State sequence. Image acquisition parameters were: 1.1 mm thick coronal slices, TR/TE/TI = 28.32/7.08/450 ms, 20° flip angle and field of view 21 cm. For each subject, 196 coronal partitions were acquired with an image matrix of 256 × 256 (Read × Phase) providing whole-brain anatomical data with an anisotropic spatial resolution of 1.09 × 1.09 × 1.1 mm³.

2.3.2. MRI data processing

The unified segmentation procedure (Ashburner and Friston, 2005) implemented in SPM8 (<http://www.fil.ion.ucl.ac.uk/spm>) was used to segment all the images into grey matter (GM), white matter (WM) and cerebrospinal fluid (CSF) partitions.

2.3.2.1. Creation of voxel-based grey matter volume maps. A fast diffeomorphic image registration algorithm (DARTEL) was used to warp the GM partitions into a new study-specific reference space with an isotropic spatial resolution of 1.5 mm³ (Ashburner and Friston, 1997, 2009; Ashburner, 2007). The warped GM partitions were then affine transformed into the MNI space. An additional 'modulation' step (Good et al., 2001) was used to scale the GM probability values by the Jacobian determinants of the deformations to ensure that the total amount of grey matter in each voxel was conserved after the registration. As a final step the GM probability maps were smoothed using a 6 mm FWHM Gaussian kernel.

2.3.2.2. Creation of voxel-based cortical thickness maps. A voxel-based Laplacian method (Jones et al., 2000; Hutton et al., 2008) was used to create a VBCT map for each subject using the GM, WM and CSF partitions created in the segmentation step. The resulting VBCT maps contained CT values within voxels identified as GM and zeros outside the cortex and were saved in the native space of the input images (1 mm³ resolution). Each VBCT map was warped into the new DARTEL reference space

by applying the corresponding subject specific deformation field and resampled to an isotropic voxel size of 1.5 mm³. The warped images were then scaled by the Jacobian determinant of the deformation and smoothed with a 6 mm Gaussian kernel. The same warps, modulation and smoothing were also applied to a binary mask created from each original VBCT map. Subsequently the warped, scaled and smoothed VBCT maps were divided by the corresponding warped, scaled, and smoothed mask. The effect of this procedure was to project the Gaussian smoothing kernel applied to the warped images, into the native space of the subject while preserving the CT value over a region the size of the smoothing kernel.

2.3.3. Statistical analysis

The statistical analysis focused on a bilateral network of interest which included regions reported to show alterations of grey matter density or CT in individuals with an ARMS and patients with FEP in previous studies (Wiegand et al., 2004; Narr et al., 2005; Fornito et al., 2008; Schultz et al., 2010; Ziermans et al., 2010; Jung et al., 2011). These regions included the (1) inferior frontal gyrus (IFG), (2) middle frontal gyrus (MFG), (3) anterior and posterior cingulate cortex (ACC and PCC), (4) superior temporal gyrus (STG), (5) middle temporal gyrus (MTG) and (6) parahippocampal cortex (PHC). Using the automated anatomical labelling (AAL) system as implemented in PickAtlas toolbox (www.nitrc.org/projects/wfu_pickatlas), we constructed a mask that comprised of all these regions (total volume: 61,107 voxels). Two voxel-wise Analyses of Covariance (ANCOVAs) were performed on the GMV and CT separately; for each independent ANCOVA the GMV or the CT was entered as the dependent variable and the experimental groups as the independent and between-subject variable. The total intracranial volume (TIV) was calculated for each subject by summing together the voxel values of the original GM, WM and CSF tissue partitions. Age, gender and TIV were included as covariates of no interest to explain variance associated with these potentially confounding effects. We identified regions that showed cortical alterations in both ARMS and FEP relative to healthy controls by comparing the combined ARMS and FEP group against controls and inclusively masking (at $P < 0.001$) the results with the individual comparisons between the ARMS group and controls and between the FEP group and controls. This procedure allowed us to identify those significant voxels in the main contrast (i.e. ARMS and FEP groups against controls) that were also significant in each of the two individual contrasts specified as mask (i.e. ARMS group against controls and FEP group against controls respectively).

Statistical inferences were made at $P < 0.05$ after Family-Wise Error (FWE) correction for multiple comparisons. When significant differences were not detected, we tested for the presence of trends for completeness

Table 2

Brain regions showing significant cortical thinning and grey matter volume reductions in ARMS and FEP individuals compared to healthy controls, and in FEP compared to ARMS individuals.

Region		Cluster size (K)	Z	MNI coordinates		
				x	y	z
<i>Cortical thickness (effects significant at $P < 0.05$ corrected)</i>						
Controls > ARMS & FEP						
Superior temporal gyrus	R	88	4.47	43	-27	9
ARMS > FEP						
Posterior cingulate	R	68	4.70	4	-42	21
<i>Grey matter volume (trends significant at $P < 0.001$ uncorrected)</i>						
Controls > ARMS & FEP						
Parahippocampus	R	84	4.19	24	-15	-31
Middle frontal gyrus	L	99	4.19	-38	25	33
Anterior cingulate	R	72	4.14	3	46	8
ARMS > FEP						
Middle temporal gyrus	L	11	3.32	-66	-21	0
Superior temporal gyrus	R	15	3.30	48	-15	-9

R, right; L, left.

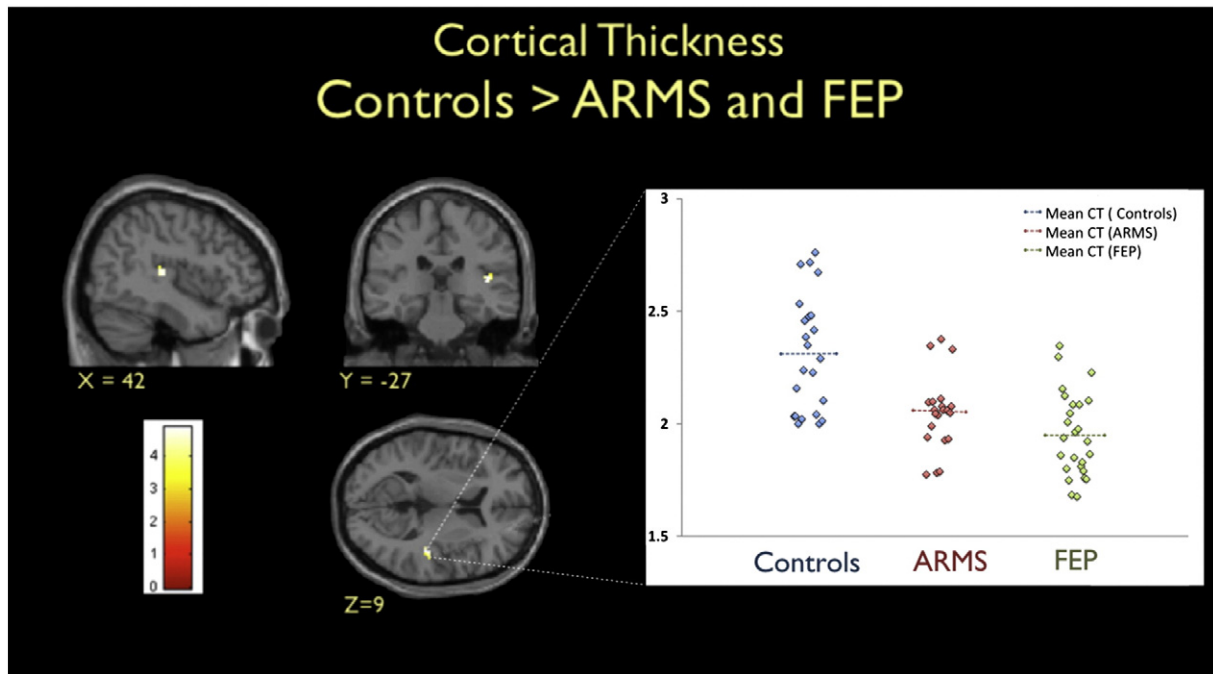


Fig. 1. Left. Brain regions showing cortical thinning in both ARMS and FEP participants compared to healthy controls ($P < 0.001$ uncorrected, for display purposes). T-scores are shown in the coloured bar. Right. Cortical thickness (CT) estimates in the right superior temporal cortex are shown for the three groups with the dashed lines indicating group CT means. Cortical thickness is measured in terms of mm between the inner and outer surfaces of grey matter.

by lowering the statistical threshold to $P < 0.001$ (uncorrected). However our discussion focuses on those differences that were significant after correction for multiple comparisons.

3. Results

3.1. Voxel-wise differences in cortical thickness

Compared to healthy controls, individuals with an ARMS and FEP patients showed thinner cortex in the right STG (BA 42) ($P < 0.05$,

corrected; Table 2; Fig. 1). In contrast, there were no regions with thicker cortex in the two clinical groups compared to the control group. When the ARMS and FEP groups were compared, the latter showed reduced CT in the right PCC ($P < 0.05$, corrected; Fig. 2; Table 2); in contrast, no areas showed an effect in the opposite direction.

3.2. Voxel-wise differences in grey matter volume

There were no regions showing grey matter increases in the two clinical groups compared to healthy controls. At a lower statistical

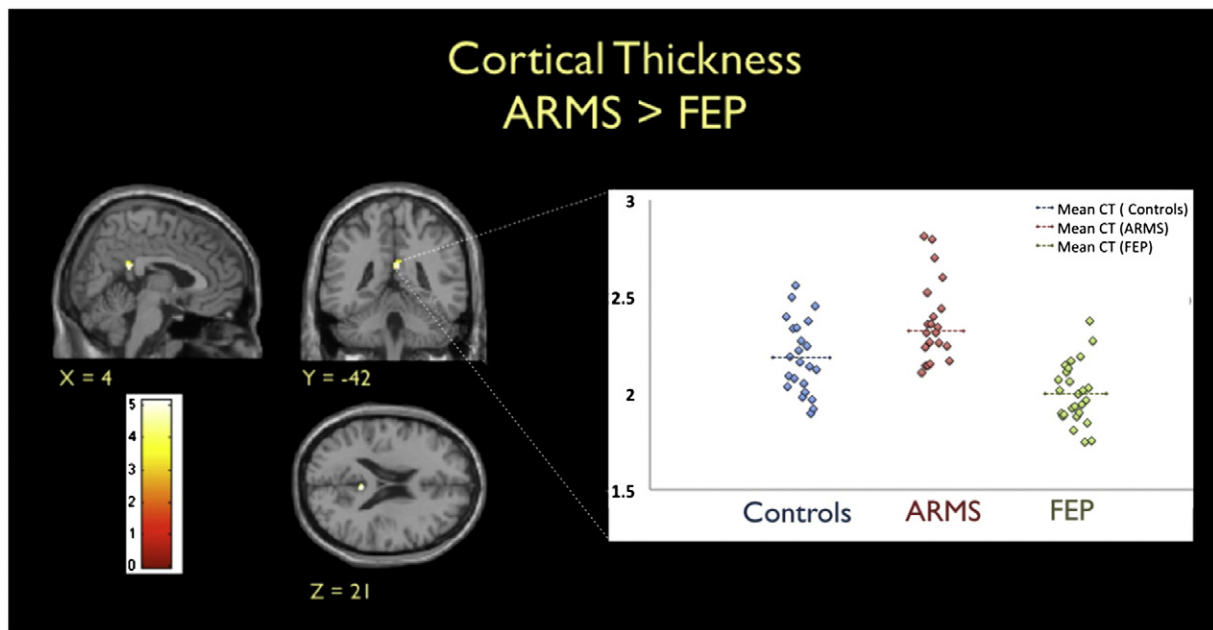


Fig. 2. Left. Brain regions showing cortical thinning in FEP patients compared to ARMS participants ($P < 0.001$ uncorrected, for display purposes). T-scores are shown in the coloured map. Right. Cortical thickness (CT) estimates in the right posterior cingulate cortex are shown for the three groups with the dashed lines indicating group CT means. Cortical thickness is measured in terms of mm between the inner and outer surfaces of grey matter.

Table 3

Correlations between cortical thickness measurements, clinical characteristics, medication indices and age ($P < 0.05$, two tailed).

	FEP & ARMS		FEP		ARMS		FEP	
	R STG (CT)	R PCC (CT)	R STG (CT)	R PCC (CT)	R STG (CT)	R PCC (CT)	R STG (CT)	R PCC (CT)
	(43 – 27 9)	(43 – 27 9)	(43 – 27 9)	(43 – 27 9)	(43 – 27 9)	(43 – 27 9)	(4 – 42 21)	(4 – 42 21)
	<i>r</i>	<i>P</i>	<i>r</i>	<i>P</i>	<i>r</i>	<i>P</i>	<i>r</i>	<i>P</i>
PANSS positive	-.016	.918	-.148	.471	.206	.370	-.117	.570
PANSS negative	-.156	.294	-.125	.544	-.255	.264	-.258	.203
PANSS total	-.033	.827	-.064	.758	.036	.877	-.172	.402
PANSS hallucinations	-.095	.524	-.380	.056	-.020	.931	-.146	.477
PANSS delusions	-.051	.734	-.125	.544	.123	.595	-.155	.450
Mean CPZ	-	-	-.087	.672	-	-	.246	.225
Cumulative CPZ	-	-	.107	.604	-	-	.339	.091
Mean age	.095	.524	.239	.240	.004	.986	.214	.237

R STG, right Superior Temporal Gyrus; R PCC, right posterior cingulate cortex; CT, cortical thickness; ARMS, ARMS group; FEP, FEP group; FEP & ARMS, FEP and ARMS groups combined; PANSS, Positive And Negative Syndrome Scale; CPZ, chlorpromazine equivalent dose.

threshold of $P < 0.001$ (corrected), we detected trends for significant grey matter reduction common to both ARMS and FEP subjects relative to healthy controls in three brain regions (Table 2). When FEP patients were compared to ARMS individuals, again no significant GMV differences were observed in either direction. At a lower statistical threshold of $P < 0.001$ (uncorrected) we detected a trend for decreased grey matter in the left MTG and in the right STG in the FEP compared to the ARMS group (Table 2). The two regions showing significant effects for CT, i.e. the right STG and PCC, did not show similar effects for GMV even when lowering the statistical threshold to $P < 0.05$ (uncorrected).

3.3. Correlations analyses

In order to better characterize the above findings, Pearson's correlation coefficients were used to examine whether CT values in the right STG and right PCC were associated with PANSS scores, age or cumulative and mean doses of antipsychotic medication. A total of 28 correlation analyses were performed and no significant associations were detected ($P < 0.05$, two tailed; Table 3).

4. Discussion

The present study used two complementary analytical techniques for assessing voxel-based GMV (Ashburner and Friston, 2000) and voxel-based CT (Hutton et al., 2008) in individuals at high risk of psychosis and patients with FEP. We hypothesized that ARMS and FEP patients would present with common reductions within a network of interest comprising frontal, temporal and cingulate regions. This hypothesis was confirmed only in part, since both ARMS and FEP groups showed significant cortical thinning in the right STG ($P < 0.05$, FWE corrected) but only trends for GMV decreases in the right ACC, right PHC and left MFG ($P < 0.001$, uncorrected). A previous study had reported reduced CT in the right STG of patients with FEP relative to healthy controls (Gutierrez-Galve et al., 2010). Our investigation replicates this finding and furthermore indicates that reduced CT in this region may be best explained in terms of enhanced vulnerability rather than the onset of the disorder. The cortical thinning of the right STG observed in the ARMS and FEP groups could be mediated by genetic influences on brain development, consistent with the observation that CT is highly heritable (Panizzon et al., 2009; Winkler et al., 2010), or alternatively it could be the result of adverse life events, consistent with growing evidence of experience-dependent neuroplasticity in the human brain (Heim et al., 2013). All the ARMS participants included in this study had an elevated risk of developing full-blown psychosis, because they had presented with attenuated psychotic symptoms or brief limited intermittent psychotic symptoms within 3 months

before study inclusion (Ruhmann et al., 2003; Hafner et al., 2004). In contrast, all FEP participants met ICD-10 criteria schizophreniform psychosis.

We also hypothesized that FEP patients would show more pronounced alterations compared to ARMS individuals within our network of interest; consistent with this hypothesis, we found a significant CT reduction in the FEP relative to the ARMS group in the right PCC. Thus cortical thinning in this region appears to be associated with the onset of the disorder rather than vulnerability. A previous study reported that, when using a conservative statistical threshold of $P < 0.05$ (FWE-corrected), the only region to show a significant GMV reduction in patients with FEP relative to individuals at ultra high risk for psychosis was the middle/posterior cingulate (Witthaus et al., 2009). Our investigation expands the results of this earlier study by indicating that differences between ARMS and FEP in the PCC are likely to reflect specific cortical atrophy as opposed to variations in sulcal and gyral morphology. This conclusion is supported by a recent investigation that found widespread cortical thinning in patients with chronic schizophrenia relative to individuals at ultra high risk for the disorder in a distributed network which included the right PCC (Jung et al., 2011).

Our final hypothesis was that VBM and VBCT would reveal focally distinct GMV and CT alterations, reflecting different underlying pathophysiological processes. This hypothesis was confirmed in part, since VBCT revealed specific cortical atrophy in the right STG (in the FEP and ARMS groups relative to the control group) and the right PCC (in the FEP relative to the ARMS group), whereas VBM only detected trends for GMV decreases in the right ACC, left MFG and left PHC. No differences in GMV were detected in the right STG and right PCC even when lowering the statistical threshold to $P < 0.05$ (uncorrected). One possible hypothesis is that progressive cortical atrophy in ARMS and FEP individuals might reflect an abnormal acceleration of cortical developmental processes (Thompson et al., 2001; Jung et al., 2011). This would be consistent with the recent observation of progressive cortical thinning in the left MTG of adolescents at high risk of psychosis over time in the absence of significant differences in GMV (Ziermans et al., 2010). In order to elucidate the above hypothesis, we evaluated whether there was a significant negative correlation between CT values and age in the right STG of ARMS and FEP participants; however, we found no evidence of such an association ($p < 0.05$). Future longitudinal studies with larger sample sizes would be needed to better evaluate the hypothesis of abnormal acceleration of cortical developmental processes in these clinical groups.

This study has three main limitations. First, the number of ARMS and FEP participants included in this investigation was relatively small ($n = 21$ and $n = 26$ respectively). However, previous studies showing significant differences in these populations included samples of comparable size (Kubicki et al., 2002; Wiegand et al., 2004; Borgwardt et al., 2007a; Witthaus et al., 2009). Furthermore, a recent analysis of effect size in classical inference has suggested that, in order to optimize the sensitivity to large effects while minimizing the risk of detecting trivial effects, the optimum sample size for a study is 16 (Friston, 2012). Nevertheless, a larger ARMS sample would have permitted to better elucidate neuroanatomical alterations associated with different levels of vulnerability to psychosis. Secondly, the present study was not designed as a longitudinal investigation and therefore we cannot provide definite information as to the rate of transition to psychosis in our ARMS group. In contrast to transition rates previously reported (Yung et al., 2003b; Olsen and Rosenbaum, 2006), none of the ARMS participants completing the 24 months follow-up (9 out of 21) made transition to a full-blown psychosis. This inconsistency might be due to the small and unrepresentative sample of ARMS who completed the follow-up, the impact of clinical treatment provided by early intervention services as well as the duration of the follow-up period. For instance, it has been recently proposed that longer follow-up periods are associated with higher risk of transition (Fusar-Poli et al., 2012) and that 33% of converters have prodromal phases lasting longer

than 6 years (Schultze-Lutter et al., 2007). Thirdly, the FEP patients included in the present work had been exposed to antipsychotic medication for a period of time falling within the range for which effects of medication have been previously described (Dazzan et al., 2005; Girgis et al., 2006; Leung et al., 2011). Although these effects have mainly been detected in striato-limbic regions it is not possible to exclude that antipsychotic effects on brain structure had already occurred in these FEP patients. Nevertheless, it is unlikely that the alteration in the right STG observed both in the ARMS and FEP groups was driven by the impact of medication, since only two subjects with an ARMS had been medicated; furthermore, we found no evidence that cortical thickness in the right STG and right PCC was associated with antipsychotic medication.

In conclusion, cortical thinning in the right STG was present in both individuals at high risk of developing psychosis and patients with a first episode of the disorder, and therefore is likely to represent a marker of vulnerability. In contrast, the cingulate cortex showed cortical thinning in FEP patients relative to individuals at high risk, and therefore appears to be implicated in the onset of the disease. These neuroanatomical differences were expressed in terms of cortical thickness but not in terms of grey matter volume, and therefore may reflect specific cortical atrophy as opposed to variations in sulcal and gyral morphology.

Role of the funding source

The project was funded by a Project Grant from the Wellcome Trust (WT085390/Z/08/Z).

Contributors

SB contributed to the design of the study, collected the subjects, organized the acquisition of data, analyzed the data, wrote the manuscript and revised it for publication. WPY contributed to the acquisition, organisation and analysis of the data and provided comments on the manuscript. CH contributed to the statistic analyses of the data and provided comments on the manuscript and revised it for publication. LMKI contributed to the acquisition of data and provided comments on the manuscript. SCRW contributed to the acquisition of data. MC,PA,PM provided comments on the manuscript. AM designed the study, contributed to the interpretation of the data, provided comments on the manuscript and revised it for publication.

Conflict of Interest

The authors of 'Elucidating neuroanatomical alterations in the At Risk Mental State and First Episode Psychosis: a combined voxel-based morphometry and voxel-based cortical thickness study' declare no financial relationships with any organization that might have an interest in the submitted work and no other relationships or activities that could appear to have influenced the submitted work.

Acknowledgments

The authors would like to thank the NIHR Biomedical Research Centre for Mental Health at the South London and Maudsley NHS Foundation Trust for its continued support of our translational research objectives.

References

Ashburner, J., 2007. A fast diffeomorphic image registration algorithm. *NeuroImage* 38 (1), 95–113.

Ashburner, J., Friston, K.J., 1997. Multimodal image coregistration and partitioning—a unified framework. *NeuroImage* 6 (3), 209–217.

Ashburner, J., Friston, K.J., 2000. Voxel-based morphometry—the methods. *NeuroImage* 11 (6 Pt 1), 805–821.

Ashburner, J., Friston, K.J., 2005. Unified segmentation. *NeuroImage* 26 (3), 839–851.

Ashburner, J., Friston, K.J., 2009. Computing average shaped tissue probability templates. *NeuroImage* 45 (2), 333–341.

Bodnar, M., Harvey, P.O., Malla, A.K., Joobar, R., Lepage, M., 2011. The parahippocampal gyrus as a neural marker of early remission in first-episode psychosis: a voxel-based morphometry study. *Clin. Schizophr. Relat. Psychoses* 4 (4), 217–228.

Borgwardt, S.J., McGuire, P.K., Aston, J., Berger, G., Dazzan, P., Gschwandtner, U., Pfluger, M., D'Souza, M., Radue, E.W., Riecher-Rossler, A., 2007a. Structural brain abnormalities in individuals with an at-risk mental state who later develop psychosis. *Br. J. Psychiatry Suppl.* 51, s69–s75.

Borgwardt, S.J., Riecher-Rossler, A., Dazzan, P., Chitnis, X., Aston, J., Drewe, M., Gschwandtner, U., Haller, S., Pfluger, M., Rechsteiner, E., D'Souza, M., Stieglitz, R.D., Radu, E.W., McGuire, P.K., 2007b. Regional gray matter volume abnormalities in the at risk mental state. *Biol. Psychiatry* 61 (10), 1148–1156.

Borgwardt, S.J., McGuire, P.K., Aston, J., Gschwandtner, U., Pfluger, M.O., Stieglitz, R.D., Radue, E.W., Riecher-Rossler, A., 2008. Reductions in frontal, temporal and

parietal volume associated with the onset of psychosis. *Schizophr. Res.* 106 (2–3), 108–114.

Dazzan, P., Morgan, K.D., Orr, K., Hutchinson, G., Chitnis, X., Suckling, J., Fearon, P., McGuire, P.K., Mallett, R.M., Jones, P.B., Leff, J., Murray, R.M., 2005. Different effects of typical and atypical antipsychotics on grey matter in first episode psychosis: the AESOP study. *Neuropsychopharmacology* 30 (4), 765–774.

Fornito, A., Yucel, M., Wood, S.J., Adamson, C., Velakoulis, D., Saling, M.M., McGorry, P.D., Pantelis, C., 2008. Surface-based morphometry of the anterior cingulate cortex in first episode schizophrenia. *Hum. Brain Mapp.* 29 (4), 478–489.

Friston, K.J., 2012. Ten ironic rules for non-statistical reviewers. *NeuroImage* 61 (4), 1300–1310.

Fusar-Poli, P., Bonoldi, I., Yung, A.R., Borgwardt, S., Kempton, M.J., Valmaggia, L., Barale, F., Caverzasi, E., McGuire, P., 2012. Predicting psychosis: meta-analysis of transition outcomes in individuals at high clinical risk. *Arch. Gen. Psychiatry* 69 (3), 220–229.

Girgis, R.R., Diwadkar, V.A., Nutche, J.J., Sweeney, J.A., Keshavan, M.S., Hardan, A.Y., 2006. Risperidone in first-episode psychosis: a longitudinal, exploratory voxel-based morphometric study. *Schizophr. Res.* 82 (1), 89–94.

Good, C.D., Johnsrude, I.S., Ashburner, J., Henson, R.N., Friston, K.J., Frackowiak, R.S., 2001. A voxel-based morphometric study of ageing in 465 normal adult human brains. *NeuroImage* 14 (1 Pt 1), 21–36.

Gutierrez-Galve, L., Wheeler-Kingshott, C.A., Altmann, D.R., Price, G., Chu, E.M., Leeson, V.C., Lobo, A., Barker, G.J., Barnes, T.R., Joyce, E.M., Ron, M.A., 2010. Changes in the frontotemporal cortex and cognitive correlates in first-episode psychosis. *Biol. Psychiatry* 68 (1), 51–60.

Hafner, H., Maurer, K., Ruhrmann, S., Bechdolf, A., Klosterkötter, J., Wagner, M., Maier, W., Bottlender, R., Moller, H.J., Gaebel, W., Wolwer, W., 2004. Early detection and secondary prevention of psychosis: facts and visions. *Eur. Arch. Psychiatry Clin. Neurosci.* 254 (2), 117–128.

Heim, C.M., Mayberg, H.S., Mletzko, T., Nemeroff, C.B., Pruessner, J.C., 2013. Decreased cortical representation of genital somatosensory field after childhood sexual abuse. *Am. J. Psychiatry* 170 (6), 616–623.

Hutton, C., De Vita, E., Ashburner, J., Deichmann, R., Turner, R., 2008. Voxel-based cortical thickness measurements in MRI. *NeuroImage* 40 (4), 1701–1710.

Hutton, C., Draganski, B., Ashburner, J., Weiskopf, N., 2009. A comparison between voxel-based cortical thickness and voxel-based morphometry in normal aging. *NeuroImage* 48 (2), 371–380.

Jastak, S., Wilkinson, G.S., 1984. *The Wide Range Achievement Test - Revised: WRAT-R*. Jastak Associates, Wilmington, DE.

Jones, S.E., Buchbinder, B.R., Aharon, I., 2000. Three-dimensional mapping of cortical thickness using Laplace's equation. *Hum. Brain Mapp.* 11 (1), 12–32.

Jung, W.H., Kim, J.S., Jang, J.H., Choi, J.S., Jung, M.H., Park, J.Y., Han, J.Y., Choi, C.H., Kang, D.H., Chung, C.K., Kwon, J.S., 2011. Cortical thickness reduction in individuals at ultra-high-risk for psychosis. *Schizophr. Bull.* 37 (4), 839–849.

Kay, S.R., Fiszbein, A., Opler, L.A., 1987. The positive and negative syndrome scale (PANSS) for schizophrenia. *Schizophr. Bull.* 13 (2), 261–276.

Kubicki, M., Shenton, M.E., Salisbury, D.F., Hirayasu, Y., Kasai, K., Kikinis, R., Jolesz, F.A., McCarley, R.W., 2002. Voxel-based morphometric analysis of gray matter in first episode schizophrenia. *NeuroImage* 17 (4), 1711–1719.

Leung, M., Cheung, C., Yu, K., Yip, B., Sham, P., Li, Q., Chua, S., McAlonan, G., 2011. Gray matter in first-episode schizophrenia before and after antipsychotic drug treatment. *Anatomical likelihood estimation meta-analyses with sample size weighting*. *Schizophr. Bull.* 37 (1), 199–211.

Loewy, R.L., Bearden, C.E., Johnson, J.K., Raine, A., Cannon, T.D., 2005. The prodromal questionnaire (PQ): preliminary validation of a self-report screening measure for prodromal and psychotic syndromes. *Schizophr. Res.* 79 (1), 117–125.

Mechelli, A., Riecher-Rossler, A., Meisenzahl, E.M., Tognin, S., Wood, S.J., Borgwardt, S.J., Koutsouleris, N., Yung, A.R., Stone, J.M., Phillips, L.J., McGorry, P.D., Valli, I., Velakoulis, D., Woolley, J., Pantelis, C., McGuire, P., 2011. Neuroanatomical abnormalities that predate the onset of psychosis: a multicenter study. *Arch. Gen. Psychiatry* 68 (5), 489–495.

Meisenzahl, E.M., Koutsouleris, N., Gaser, C., Bottlender, R., Schmitt, G.J., McGuire, P., Decker, P., Burgermeister, B., Born, C., Reiser, M., Moller, H.J., 2008. Structural brain alterations in subjects at high-risk of psychosis: a voxel-based morphometric study. *Schizophr. Res.* 102 (1–3), 150–162.

Nagy, Z., Lagercrantz, H., Hutton, C., 2011. Effects of preterm birth on cortical thickness measured in adolescence. *Cereb. Cortex* 21 (2), 300–306.

Narr, K.L., Bilder, R.M., Toga, A.W., Woods, R.P., Rex, D.E., Szeszko, P.R., Robinson, D., Sevy, S., Gunduz-Bruce, H., Wang, Y.P., DeLuca, H., Thompson, P.M., 2005. Mapping cortical thickness and gray matter concentration in first episode schizophrenia. *Cereb. Cortex* 15 (6), 708–719.

Olsen, K.A., Rosenbaum, B., 2006. Prospective investigations of the prodromal state of schizophrenia: a review of studies. *Acta Psychiatr. Scand.* 113 (4), 247–272.

Panizzon, M.S., Fennema-Notestine, C., Eyler, L.T., Jernigan, T.L., Prom-Wormley, E., Neale, M., Jacobson, K., Lyons, M.J., Grant, M.D., Franz, C.E., Xian, H., Tsuang, M., Fischl, B., Seidman, L., Dale, A., Kremen, W.S., 2009. Distinct genetic influences on cortical surface area and cortical thickness. *Cereb. Cortex* 19 (11), 2728–2735.

Pantelis, C., Velakoulis, D., McGorry, P.D., Wood, S.J., Suckling, J., Phillips, L.J., Yung, A.R., Bullmore, E.T., Brewer, W., Soulsby, B., Desmond, P., McGuire, P.K., 2003. Neuroanatomical abnormalities before and after onset of psychosis: a cross-sectional and longitudinal MRI comparison. *Lancet* 361 (9354), 281–288.

Ruhrmann, S., Schultze-Lutter, F., Klosterkötter, J., 2003. Early detection and intervention in the initial prodromal phase of schizophrenia. *Pharmacopsychiatry* 36 (Suppl. 3), S162–S167.

Schultz, C.C., Koch, K., Wagner, G., Roebel, M., Schachtzabel, C., Gaser, C., Nenadic, I., Reichenbach, J.R., Sauer, H., Schlosser, R.G., 2010. Reduced cortical thickness in first episode schizophrenia. *Schizophr. Res.* 116 (2–3), 204–209.

- Schultze-Lutter, F., Ruhrmann, S., Pickler, H., von Reventlow, H.G., Brockhaus-Dumke, A., Klosterkotter, J., 2007. Basic symptoms in early psychotic and depressive disorders. *Br. J. Psychiatry Suppl.* 51, s31–s37.
- Takayanagi, Y., Takahashi, T., Orikabe, L., Mozue, Y., Kawasaki, Y., Nakamura, K., Sato, Y., Itokawa, M., Yamasue, H., Kasai, K., Kurachi, M., Okazaki, Y., Suzuki, M., 2011. Classification of first-episode schizophrenia patients and healthy subjects by automated MRI measures of regional brain volume and cortical thickness. *PLoS One* 6 (6), e21047.
- Thompson, P.M., Vidal, C., Giedd, J.N., Gochman, P., Blumenthal, J., Nicolson, R., Toga, A.W., Rapoport, J.L., 2001. Mapping adolescent brain change reveals dynamic wave of accelerated gray matter loss in very early-onset schizophrenia. *Proc. Natl. Acad. Sci. U. S. A.* 98 (20), 11650–11655.
- Voets, N.L., Hough, M.G., Douaud, G., Matthews, P.M., James, A., Winmill, L., Webster, P., Smith, S., 2008. Evidence for abnormalities of cortical development in adolescent-onset schizophrenia. *NeuroImage* 43 (4), 665–675.
- WHO- World Health Organization, 1992. *The ICD-10 Classification of Mental and Behavioural Disorders: Clinical Description and Diagnostic Guidelines*. Geneva.
- Wiegand, L.C., Warfield, S.K., Levitt, J.J., Hirayasu, Y., Salisbury, D.F., Heckers, S., Dickey, C.C., Kikinis, R., Jolesz, F.A., McCarley, R.W., Shenton, M.E., 2004. Prefrontal cortical thickness in first-episode psychosis: a magnetic resonance imaging study. *Biol. Psychiatry* 55 (2), 131–140.
- Winkler, A.M., Kochunov, P., Blangero, J., Almasy, L., Zilles, K., Fox, P.T., Duggirala, R., Glahn, D.C., 2010. Cortical thickness or grey matter volume? The importance of selecting the phenotype for imaging genetics studies. *NeuroImage* 53 (3), 1135–1146.
- Witthaus, H., Kaufmann, C., Bohner, G., Ozgurdal, S., Gudlowski, Y., Gallinat, J., Ruhrmann, S., Brune, M., Heinz, A., Klingebiel, R., Juckel, G., 2009. Gray matter abnormalities in subjects at ultra-high risk for schizophrenia and first-episode schizophrenic patients compared to healthy controls. *Psychiatry Res.* 173 (3), 163–169.
- Yung, A.R., Phillips, L.J., McGorry, P.D., McFarlane, C.A., Francey, S., Harrigan, S., Patton, G.C., Jackson, H.J., 1998. Prediction of psychosis. A step towards indicated prevention of schizophrenia. *Br. J. Psychiatry Suppl.* 172 (33), 14–20.
- Yung, A.R., Organ, B.A., Harris, M.G., 2003a. Management of early psychosis in a generic adult mental health service. *Aust. N. Z. J. Psychiatry* 37 (4), 429–436.
- Yung, A.R., Phillips, L.J., Yuen, H.P., Francey, S.M., McFarlane, C.A., Hallgren, M., McGorry, P.D., 2003b. Psychosis prediction: 12-month follow up of a high-risk ("prodromal") group. *Schizophr. Res.* 60 (1), 21–32.
- Ziermans, T.B., Schothorst, P.F., Schnack, H.G., Koolschijn, P.C., Kahn, R.S., van Engeland, H., Durston, S., 2010. Progressive structural brain changes during development of psychosis. *Schizophr. Bull.* 38 (3), 519–530.