

# Perimedullary arteriovenous fistulas of the craniovertebral junction: A systematic review

## ABSTRACT

Perimedullary arteriovenous fistulas (PMAVFs) are uncommon vascular malformations, and they rarely occur at the level of the craniovertebral junction (CVJ). The therapeutic management is challenging and can include observation alone, endovascular occlusion, or surgical exclusion, depending on both patient and malformation characteristics. A systematic literature search was conducted using MEDLINE, Scopus, and Google Scholar databases, searching for the following combined MeSH terms: (*perimedullary arteriovenous fistula OR dural arteriovenous shunt*) AND (*craniocervical junction OR craniovertebral junction*). We also present an emblematic case of PMAVF at the level of the craniovertebral junction associated to a venous pseudoaneurysm. A total of 31 published studies were identified; 10 were rejected from our review because they did not match our inclusion criteria. Our case was not included in the systematic review. We selected 21 studies for this systematic review with a total of 58 patients, including 20 females (34.5%) and 38 males (65.5%), with a female/male ratio of 1:1.9. Thirty-nine out of 58 patients underwent surgical treatment (67.2%), 15 out of 58 patients were treated with endovascular approach (25.8%), 3 out of 58 patients underwent combined treatment (5.2%), and only 1 patient was managed conservatively (1.7%). An improved outcome was reported in 94.8% of cases (55 out of 58 patients), whereas 3 out of 58 patients (5.2%) were moderately disabled after surgery and endovascular treatment. In literature, hemorrhagic presentation is reported as the most common onset (subarachnoid hemorrhage in 63% and intramedullary hemorrhage in 10%), frequently caused either by venous dilation, due to an ascending drainage pathway into an intracranial vein, or by the higher venous flow rates that can be associated with intracranial drainage. Hiramatsu and Sato stated that arterial feeders from the anterior spinal artery (ASA) and aneurysmal dilations are associated with hemorrhagic presentation. In agreement with the classification by Hiramatsu, we defined the PMAVF of the CVJ as a vascular lesion fed by the radiculomeningeal arteries from the vertebral artery and the spinal pial arteries from the ASA and/or lateral spinal artery. Considering the anatomical characteristics, we referred to our patient as affected by PMAVF, even if it was difficult to precisely localize the arteriovenous shunts because of the complex angioarchitecture of the fine feeding arteries and draining veins, but we presumed that the shunt was located in the point of major difference in vessel size between the feeding arteries and draining veins. PMAVFs of CVJ are rare pathologies of challenging management. The best diagnostic workup and treatment are still controversial: more studies are needed to compare different therapeutic strategies concerning both long-term occlusion rates and outcomes.

**Keywords:** Aneurysm, angiography, arteriovenous fistula, craniovertebral junction, perimedullary, subarachnoid hemorrhage

**GIUSEPPE EMMANUELE UMANA<sup>1</sup>, GIANLUCA SCALIA<sup>2</sup>, BIPIN CHAURASIA<sup>3</sup>, MARCO FRICIA<sup>1</sup>, MAURIZIO PASSANISI<sup>1</sup>, FRANCESCA GRAZIANO<sup>2,4</sup>, GIOVANNI FEDERICO NICOLETTI<sup>2</sup>, SALVATORE CICERO<sup>1</sup>**

<sup>1</sup>Department of Neurosurgery, Trauma Center, Gamma Knife Center, Cannizzaro Hospital, <sup>2</sup>Neurosurgery Unit, Highly Specialized Hospital and of National Importance "Garibaldi", Catania, Italy, <sup>4</sup>Experimental Biomedicine and Clinical Neurosciences, School of Medicine, Postgraduate Residency Program in Neurological Surgery, Neurosurgical Clinic, University Hospital "Policlinico P. Giaccone", Palermo, Italy, <sup>3</sup>Department of Neurosurgery, Bangabandhu Sheikh Mujib Medical University, Dhaka, Bangladesh

**Address for correspondence:** Dr. Giuseppe Emmanuele Umana, Department of Neurosurgery, Trauma Center, Gamma Knife Center, Cannizzaro Hospital, Via Messina, 829, Catania 95126, Italy. E-mail: [umana.nch@gmail.com](mailto:umana.nch@gmail.com)

**Submitted:** 03-Jul-20


**Accepted:** 22-Jul-20

**Published:** 14-Aug-20

This is an open access journal, and articles are distributed under the terms of the Creative Commons Attribution-NonCommercial-ShareAlike 4.0 License, which allows others to remix, tweak, and build upon the work non-commercially, as long as appropriate credit is given and the new creations are licensed under the identical terms.

**For reprints contact:** [WKHLRPMedknow\\_reprints@wolterskluwer.com](mailto:WKHLRPMedknow_reprints@wolterskluwer.com)

**How to cite this article:** Umana GE, Scalia G, Chaurasia B, Fricia M, Passanisi M, Graziano F, *et al.* Perimedullary arteriovenous fistulas of the craniovertebral junction: A systematic review. *J Craniovert Jun Spine* 2020;11:157-62.

Access this article online	
<b>Website:</b> <a href="http://www.jcvjs.com">www.jcvjs.com</a>	<b>Quick Response Code</b> 
<b>DOI:</b> <a href="https://doi.org/10.4103/jcvjs.JCVJS_106_20">10.4103/jcvjs.JCVJS_106_20</a>	

## INTRODUCTION

Perimedullary arteriovenous fistulas (PMAVFs) of the craniovertebral junction (CVJ) represent <1% of all cranial or spinal arteriovenous fistulas (AVFs)<sup>[1-3]</sup> and are classified as type 5 AVFs according to Hiramatsu *et al.*<sup>[4]</sup> PMAVFs may present clinically either with acute neurological deficits due to subarachnoid or intramedullary hemorrhage, or with progressive myelopathy caused by venous congestion;<sup>[5,6]</sup> a differential diagnosis must be made with spinal thoracolumbar AVFs, whose main presentation is myelopathy.<sup>[7,8]</sup> Therapeutic management includes options such as observation alone, endovascular occlusion, surgical exclusion, or a combination of these two last techniques, depending on patient-specific and lesion-specific characteristics. Observation carries the risk of rebleeding, surgical treatment presents challenges related to the operative approach, and endovascular treatment presents several technical limitations due to vessels' size and risk of medullary ischemia. We present a rare case of a patient affected by ruptured PMAVF of CVJ associated to a venous pseudoaneurysm, providing new insights into the diagnosis and management of this rare entity.

## MATERIALS AND METHODS

### Study selection

A systematic review of the literature was conducted using MEDLINE, Cochrane, and EBSCO databases using the following combined MeSH terms: (*perimedullary arteriovenous fistula OR dural arteriovenous shunt*) and (*craniocervical junction OR craniovertebral junction*). This search was limited to studies published in English. The PRISMA flow diagram of our search is available in Figure 1. Eligibility criteria were limited by the nature of the existing literature on PMAVFs, which consists of case series, case reports, and only one multicentric study. A definition of PMAVF has been reported only in 2017;<sup>[3]</sup> all previous papers were meticulously analyzed to define the anatomical features of every AVF. All papers reporting PMAVFs not located at the CVJ were not included in this review. The reference list of all the articles included in this review was examined searching for additional papers.

### Data extraction

All included papers were meticulously reviewed and analyzed for their study design, methodology, and patient characteristics. All patients' data were recorded when available, including age, sex, clinical presentation, interval between onset of symptoms and diagnosis, treatment options (surgery or endovascular), and outcome.

Descriptive statistics are reported, including means and proportions. No formal statistical comparisons were

performed due to small sample size and insufficient power to detect differences between groups.

## RESULTS

A total of 31 published studies from 1996 to 2019 were identified through our search and additional reference evaluation. After detailed examination, ten were rejected from our review, as they were written in other languages or AVFs were not at the level of the CVJ. Our case was not included in the systematic review. Patients data are reported in Table 1.<sup>[4,9-28]</sup> We selected 21 studies for this systematic review, with a total of 58 patients, including 20 females (34.5%) and 38 males (65.5%), with a female/male ratio of 1:1.9. Patients presented a mean age of 55.9 years, ranging from 38 to 82 years. The presentation with subarachnoid hemorrhage (SAH) occurred in 45 out of 58 patients (77.6%), whereas 11 out of 58 patients (18.9%) presented with sensory and/or motor dysfunction; 2 out of 58 cases (3.4%) were incidental findings. In 35 out of 58 patients (60.3%), the onset was acute. In 9 out of 58 patients (15.5%), the mean interval between the presentation of symptoms and diagnosis was 12.3 months, ranging between 0.5 and 48 months; in 13 out of 58 patients (22.4%), this time interval was not reported. Thirty-nine out of 58 patients underwent surgical treatment (67.2%), whereas 15 out of 58 patients were treated with the endovascular procedure only (25.8%); 3 out of 58 patients were treated with combined surgical and endovascular approach (5.2%); only one patient was managed conservatively (1.7%). An improved outcome was reported in 94.8% of cases (55 out of 58 patients), whereas 3 out of 58 patients (5.2%) were moderately disabled after treatment.

### Case presentation

#### Medical history and clinical examination

A 73-year-old woman with a history of osteoporosis presented to our institution with sudden headache, vomiting, and rigor nuchalis associated to dysesthesia of the upper limbs.

#### Imaging

Brain angio-computed tomography (CT) scan demonstrated diffuse SAH (Fisher grade 3) [Figure 2], as well as magnetic resonance angiography revealed the presence of a PMAVF associated to a venous pseudoaneurysm at C1–C2 level [Figure 3]. Subsequent digital subtraction angiography (DSA) confirmed a PMAVF of the CVJ, responsible for the recent SAH; the PMAVF was located in the right paramedian position, posterior to the middle third of the odontoid process with caudal extension up to C2–C3, with maximum dimensions on the sagittal plane of about 1.2 cm [Figure 4]. Cranially to the PMAVF, there was evidence of venous pseudoaneurysm. The PMAVF had arterial feeders from both hypertrophic anterior spinal arteries,

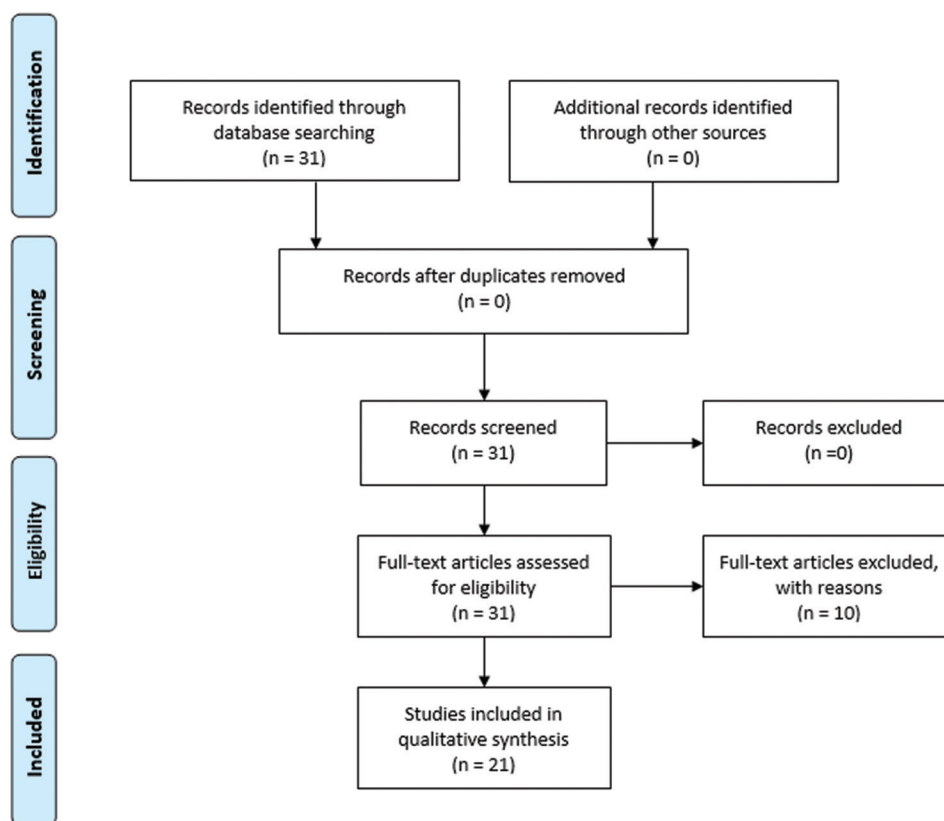


Figure 1: PRISMA flow diagram reports the decision algorithm for the selection of the studies of the systematic review

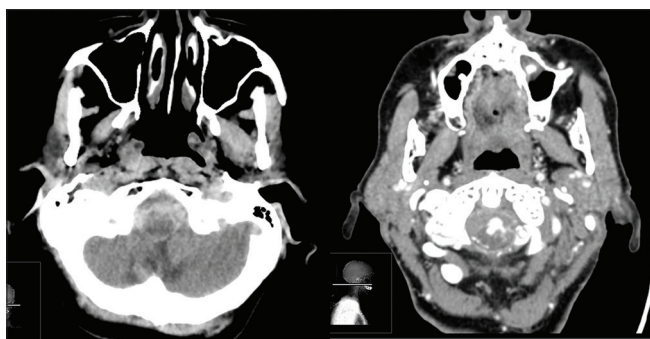


Figure 2: Brain computed tomography scan demonstrated diffuse subarachnoid hemorrhage (Fisher grade 3) (left) and computed tomography angiography documented the presence of a vascular malformation of the craniovertebral junction (right)

originating from the intracranial portion and from cervical radicular branches – which stemmed at the right C3–C4 and left C2 level, of greater caliber and flow to the left – of both vertebral arteries (VAs); the main venous drainage, dilated, was at the level of the basal venous plexus, with drainage in both inferior petrous sinuses and at the level of the left posterior cervical paravertebral plexus, also markedly dilated.

### Management

After a multidisciplinary discussion, we decided to perform surgical treatment of the PMAVF because no navigable

afferent vessels allowed the exclusion of the shunt point during the endovascular procedure. However, the patient refused the treatment, probably due both to progressive clinical improvement and to the high surgical risks explained during informed consent. She improved to complete recovery, CT scan revealing progressive reabsorption of the SAH. After 9-month follow-up, the PMAVF is stable in serial DSA and angio-CT scans, and the patient is in good clinical conditions.

### DISCUSSION

Historically, PMAVFs were considered congenital.<sup>[17]</sup> Anteriorly located shunts represent an atypical feature.<sup>[29]</sup> PMAVFs present direct shunts between the vessels at the level of the pia mater, superficially to the spinal cord, and they can be located anteriorly or anterolaterally to the spinal cord.<sup>[15,30,29]</sup> Lawton *et al.*<sup>[31]</sup> suggested that angiogenesis could be induced by venous hypertension, responsible for the development of AVFs in experimental models. Sato *et al.*<sup>[17]</sup> hypothesized that venous hypertension can cause venous hypoxia, which induces additional pial shunts in patients with AVFs of the craniovertebral junction. According to Hassler *et al.*,<sup>[32]</sup> venous drainage close to the nerve root sleeve could worsen a sump effect. Moreover, blood supply to the radiculomedullary arteries may be near the origin of the

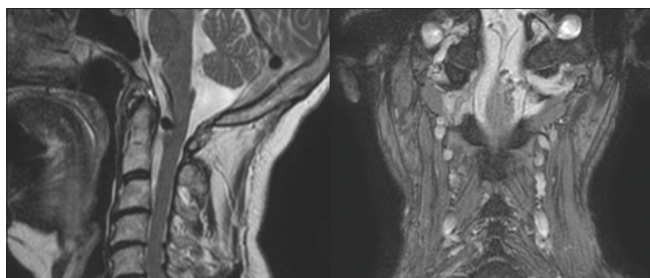
**Table 1: Systematic review of demographic, symptoms, interval time to diagnosis, treatment, and outcome data of patients affected by perimedullary arteriovenous fistulas of the craniovertebral junction reported in the literature to date**

Authors and year	Number of patients	Age (years)	Sex	Symptoms	Time to diagnosis	Treatment	Outcome
Hiramatsu <i>et al.</i> 2018 <sup>[4]</sup>	6	Mean 67	4 males, 2 females	SAH symptoms	Not reported	4 endovascular treatments, 2 surgeries	Improved
Mascalchi <i>et al.</i> 1996 <sup>[9]</sup>	2	69, 53	Male	Lower limb paresthesias, urinary retention, progressive gait disturbance	4 years, 2 years	Surgery (clipped and excised); endovascular treatment (injection of glue)	Both improved
Kinouchi <i>et al.</i> 1998 <sup>[10]</sup>	10	63, 65, 44, 52, 70, 68, 50, 61, 60, 45	7 males, 3 females	2 incidental, 1 back pain, bowel and bladder disturbance, sensory disturbances, trigeminal nerve disturbance, quadriparesis, and respiratory disturbance, 7 SAH symptoms	Not reported, 1 year, 7 acute onset	Surgery	Improved
Kuwayama <i>et al.</i> 1999 <sup>[11]</sup>	3	73, 52, 52	2 males, 1 female	SAH symptoms	Acute onset	1 conservative, 1 endovascular treatment, 1 surgery	Moderately disabled
Yoshida <i>et al.</i> 1999 <sup>[12]</sup>	1	68	Male	Lower limb motor and sensory disturbances	6 months	Surgery	Improved
Asakawa <i>et al.</i> 2002 <sup>[13]</sup>	1	64	Male	Lower limb weakness, dyspnea	2 weeks	Embolization + surgical exclusion	Improved
Lv <i>et al.</i> 2011 <sup>[14]</sup>	4	73, 66, 51, 40	3 males, 1 female	SAH symptoms	Acute onset	Endovascular treatment	Improved
Ohba <i>et al.</i> 2011 <sup>[15]</sup>	1	55	Male	SAH symptoms	Acute onset	Surgery	Improved
Kulwin <i>et al.</i> 2012 <sup>[16]</sup>	2	44, 54	Female	Altered mental status, right hemiparesis; left hemiparesis and diplopia	Acute onset	Surgery	Improved
Sato <i>et al.</i> 2013 <sup>[17]</sup>	9	59, 82, 78, 62, 64, 62, 60, 64, 66	5 males, 4 females	SAH symptoms	Acute onset	Surgery	Improved
Gilard <i>et al.</i> 2013 <sup>[18]</sup>	1	59	Female	SAH symptoms	Acute onset	Surgery	Improved
Kasliwal <i>et al.</i> 2015 <sup>[19]</sup>	1	59	Female	SAH symptoms	Acute onset	Surgery	Improved
Jeon <i>et al.</i> 2015 <sup>[20]</sup>	1	73	Male	Progressive weakness of both lower extremities	10 months	Endovascular treatment + surgery	Improved
Pop <i>et al.</i> 2015 <sup>[21]</sup>	1	38	Male	Paraparesis and acute urinary retention, generalized tonic-clonic seizures	28 days	Endovascular treatment	Improved
Ogita <i>et al.</i> 2016 <sup>[22]</sup>	1	58	Male	SAH symptoms	9 months	Surgery	Improved
Kawasaki <i>et al.</i> 2016 <sup>[23]</sup>	1	73	Female	Headache and left hemiparesis	Acute onset	Conservative	Improved
Enokizono <i>et al.</i> 2017 <sup>[24]</sup>	1	50	Female	Neck pain and urination difficulty, paralysis, and numbness of all four extremities	1 month	Clipping	Improved
Fujimoto <i>et al.</i> 2018 <sup>[25]</sup>	6	69, 79, 76, 64, 68, 46	4 males, 2 females	SAH symptoms	Not reported	5 surgeries, 1 endovascular treatment	Improved
Kanemaru <i>et al.</i> 2019 <sup>[26]</sup>	4	67, 76, 45, 53	3 males, 1 female	SAH symptoms	Acute onset	Surgery	Improved
Sato <i>et al.</i> 2019 <sup>[27]</sup>	1	69	Male	SAH symptoms	Acute onset	Endovascular treatment + surgery	Improved
Yoshida <i>et al.</i> 2019 <sup>[28]</sup>	1	65	Male	SAH symptoms	Acute onset	Endovascular treatment	Improved

SAH - Subarachnoid hemorrhage

venous drainage.<sup>[15,33]</sup> In literature, hemorrhagic presentation is reported as the most common onset (SAH in 63% and intramedullary hemorrhage in 10%),<sup>[1,6,34]</sup> frequently caused either by venous dilation, due to an ascending drainage pathway into an intracranial vein,<sup>[6,10,35-37]</sup> or by the higher

venous flow rates that can be associated with intracranial drainage.<sup>[10,38]</sup> For Hiramatsu *et al.*<sup>[3]</sup> and Sato *et al.*,<sup>[17]</sup> arterial feeders from the anterior spinal artery (ASA) and aneurysmal dilations are associated with hemorrhagic presentation.<sup>[1,17]</sup> However, there is controversy about the definition of PMAVFs

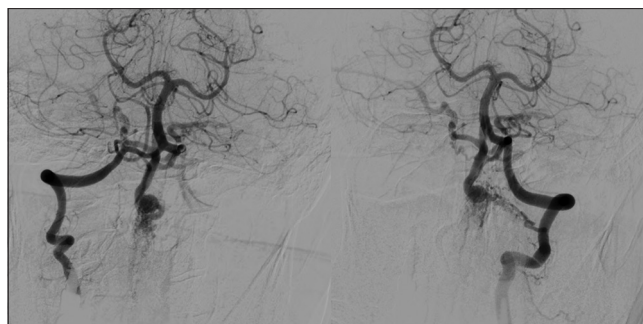


**Figure 3: Magnetic resonance angiography revealed the presence of a perimedullary arteriovenous fistula associated to a venous pseudoaneurysm at C1–C2 level**

of the CVJ because of the angiographic complexity of these lesions. In agreement with the classification by Hiramatsu *et al.*,<sup>[3]</sup> we defined the PMAVF of the CVJ as a vascular lesion fed by the radiculomeningeal arteries from the VA and the spinal pial arteries from the ASA and/or lateral spinal artery. These AVFs are direct arteriovenous shunts that link both radiculomeningeal and pial feeders with the intramural or epidural vein at the same fistulous point. Considering the anatomical characteristics, we referred to our patient as affected by PMAVF, even if it was difficult to precisely localize the arteriovenous shunts because of the complex angioarchitecture of the fine feeding arteries and draining veins, but we presumed that the shunt was located in the point of major difference in vessel size between the feeding arteries and draining veins. PMAVFs are characterized by small, tortuous feeding arteries and arteries originating from the VA, which may present an acute angle that can be technically challenging for endovascular treatment.<sup>[17,39]</sup> A safer treatment is represented by surgical disconnection by clipping and/or coagulating the fistula, in cases with a small shunt fistula, small tortuous feeding arteries, or a dominant pial arteriovenous shunt. Based on the reported case, also conservative treatment can play a role and could be reserved to elderly and/or fragile patients. Therefore, a careful endovascular examination is mandatory for accurate diagnosis and proper treatment of patients suspected of having a PMAVF of the CVJ.

## CONCLUSIONS

We presented one emblematic patient, affected by rare PMAVF of the CVJ that refused treatment, but serial radiological follow-up demonstrated the stability of the lesion with good clinical performance. Thus, the present paper focused on a peculiar subtype of AVF of the CVJ that presented controversies both for radiological diagnosis and treatment indications. Therefore, we suggest a combined endovascular and neurosurgical approach to treat this type of patients, as it is possible to obtain the best postoperative outcome.



**Figure 4: DSA showing craniovertebral junction perimedullary arteriovenous fistula. Cranially to the perimedullary arteriovenous fistula, there was evidence of venous pseudoaneurysm; the perimedullary arteriovenous fistula had arterial feeders from both hypertrophic anterior spinal arteries, originating from the intracranial portion and from cervical radicular branches – which stemmed at the right C3–C4 and left C2 level, of greater caliber and flow to the left – of both vertebral arteries; the main venous drainage, dilated, was at the level of the basal venous plexus, with drainage in both inferior petrous sinuses and at the level of the left posterior cervical paravertebral plexus, also markedly dilated**

## Financial support and sponsorship

Nil.

## Conflicts of interest

There are no conflicts of interest.

## REFERENCES

1. Kuwayama N, Endo S, Kubo M, Sakai N. Present status in the treatment of dural arteriovenous fistulas in Japan. *Jpn J Neurosurg (Tokyo)* 2011;20:12-9.
2. Reinges MH, Thron A, Mull M, Huffmann BC, Gilsbach JM. Dural arteriovenous fistulae at the foramen magnum. *J Neurosurg* 2001;248:197-203.
3. Hiramatsu M, Sugiu K, Ishiguro T, Kiyosue H, Sato K, Takai K, *et al.* Angioarchitecture of arteriovenous fistulas at the craniocervical junction: A multicenter cohort study of 54 patients. *J Neurosurg* 2018;128:1839-49.
4. Hiramatsu M, Sugiu K, Ishiguro T, Kiyosue H, Sato K, Takai K, *et al.* Angioarchitecture of arteriovenous fistulas at the craniovertebral junction: A multicenter cohort study of 54 patients. *J Neurosurg* 2018;128:1839-49.
5. Endo T, Shimizu H, Sato K, Niizuma K, Kondo R, Matsumoto Y, *et al.* Cervical perimedullary arteriovenous shunts: A study of 22 consecutive cases with a focus on angioarchitecture and surgical approaches. *Neurosurgery* 2014;75:238-49.
6. Wang JY, Molenda J, Bydon A, Colby GP, Coon AL, Tamargo RJ, *et al.* Natural history and treatment of craniovertebral junction dural arteriovenous fistulas. *J Clin Neurosci* 2015;22:1701-7.
7. Klopffer HB, Surdell DL, Thorell WE. Type I spinal dural arteriovenous fistulas: Historical review and illustrative case. *Neurosurg Focus* 2009;26:E3.
8. Krings T, Geibprasert S. Spinal dural arteriovenous fistulas. *AJNR Am J Neuroradiol* 2009;30:639-48.
9. Mascacchi M, Scazzari F, Prosetti D, Ferrito G, Salvi F, Quilici N. Dural arteriovenous fistula at the craniocervical junction with perimedullary venous drainage. *AJNR Am J Neuroradiol* 1996;17:1137-41.
10. Kinouchi H, Mizoi K, Takahashi A, Nagamine Y, Kosu K, Yoshimoto T. Dural arteriovenous shunts at the craniocervical junction.

- J Neurosurg 1998;89:755-61.
11. Kuwayama N, Kubo M, Nishijima M, Horie Y, Endo S, Takaku A. Treatment of intracranial (dural) arteriovenous fistulas in unusual locations. *Interv Neuroradiol* 1999;5 Suppl 1:115-20.
  12. Yoshida S, Oda Y, Kawakami Y, Sato S. Progressive myelopathy caused by dural arteriovenous fistula at the craniocervical junction—case report. *Neurol Med Chir (Tokyo)* 1999;39:376-9.
  13. Asakawa H, Yanaka K, Fujita K, Marushima A, Anno I, Nose T. Intracranial dural arteriovenous fistula showing diffuse MR enhancement of the spinal cord: Case report and review of the literature. *Surg Neurol* 2002;58:251-7.
  14. Lv X, Yang X, Li Y, Jiang C, Wu Z. Dural arteriovenous fistula with spinal perimedullary venous drainage. *Neurol India*. 2011;59:899-902.
  15. Ohba S, Onozuka S, Horiguchi T, Kawase T, Yoshida K. Perimedullary arteriovenous fistula at the craniocervical junction-Case report. *Neurol Med Chir (Tokyo)* 2011;51:299-301.
  16. Kulwin C, Bohnstedt BN, Scott JA, Cohen-Gadol A. Dural arteriovenous fistulas presenting with brainstem dysfunction: Diagnosis and surgical treatment. *Neurosurg Focus* 2012;32:E10.
  17. Sato K, Endo T, Niizuma K, Fujimura M, Inoue T, Shimizu H, et al. Concurrent dural and perimedullary arteriovenous fistulas at the craniocervical junction: Case series with special reference to angioarchitecture. *J Neurosurg* 2013;118:451-9.
  18. Gilard V, Curey S, Tollard E, Proust F. Coincidental vascular anomalies at the foramen magnum: Dural arteriovenous fistula and high flow aneurysm on perimedullary fistula. *Neurochirurgie* 2013;59:210-3.
  19. Kasliwal MK, Moftakhar R, O'Toole JE, Lopes DK. High cervical spinal subdural hemorrhage as a harbinger of craniocervical arteriovenous fistula: An unusual clinical presentation. *Spine J* 2015;15:e13-7.
  20. Jeon JP, Cho YD, Kim CH, Han MH. Complex spinal arteriovenous fistula of the craniocervical junction with pial and dural shunts combined with contralateral dural arteriovenous fistula. *Interv Neuroradiol* 2015;21:733-7.
  21. Pop R, Manisor M, Aloraini Z, Chibarro S, Proust F, Quenardelle V, et al. Foramen magnum dural arteriovenous fistula presenting with epilepsy. *Interv Neuroradiol* 2015;21:724-7.
  22. Ogita S, Endo T, Inoue T, Sato K, Endo H, Tominaga T. Traumatic spinal perimedullary arteriovenous fistula induced by a cervical glass stab injury. *World Neurosurg*. 2016;96:610. e9-610.e13.
  23. Kawasaki T, Fukuda H, Kurosaki Y, Handa A, Chin M, Yamagata S. Acute compressive myelopathy caused by spinal subarachnoid hemorrhage: A combined effect of asymptomatic cervical spondylosis. *World Neurosurg* 2016;95:619.e1-000.
  24. Enokizono M, Sato N, Morikawa M, Kimura Y, Sugiyama A, Maekawa T, et al. "Black butterfly" sign on T2\*-weighted and susceptibility-weighted imaging: A novel finding of chronic venous congestion of the brain stem and spinal cord associated with dural arteriovenous fistulas. *J Neurol Sci* 2017;379:64-8.
  25. Fujimoto S, Takai K, Nakatomi H, Kin T, Saito N. Three-dimensional angioarchitecture and microsurgical treatment of arteriovenous fistulas at the craniocervical junction. *J Clin Neurosci* 2018;53:140-6.
  26. Kanemaru K, Yoshioka H, Hashimoto K, Murayama H, Ogiwara M, Yagi T, et al. Efficacy of intraarterial fluorescence video angiography in surgery for dural and perimedullary arteriovenous fistula at craniocervical junction. *World Neurosurg* 2019;126:e573-e579.
  27. Sato H, Wada H, Noro S, Saga T, Kamada K. Subarachnoid hemorrhage with concurrent dural and perimedullary arteriovenous fistulas at craniocervical junction: Case report and literature review. *World Neurosurg* 2019;127:331-4.
  28. Yoshida K, Sato S, Inoue T, Ryu B, Shima S, Mochizuki T, et al. Transvenous embolization for craniocervical junction epidural arteriovenous fistula with a pial feeder aneurysm. *Interv Neuroradiol* 2020;26:170-7.
  29. Onda K, Yoshida Y, Watanabe K, Arai H, Okada H, Terada T. High cervical arteriovenous fistulas fed by dural and spinal arteries and draining into a single medullary vein: Report of 3 cases. *J Neurosurg Spine* 2014;20:256-64.
  30. Wen HT, Rhoton AL Jr, Katsuta T, de Oliveira E. Microsurgical anatomy of the transcondylar, supracondylar, and paracondylar extensions of the far-lateral approach. *J Neurosurg* 1997;87:555-85.
  31. Lawton MT, Jacobowitz R, Spetzler RF. Redefined role of angiogenesis in the pathogenesis of dural arteriovenous malformations. *J Neurosurg* 1997;87:267-74.
  32. Hassler W, Thron A, Grote EH. Hemodynamics of spinal dural arteriovenous fistulas. An intraoperative study. *J Neurosurg* 1989;70:360-70.
  33. Garcia-Monaco R, Rodesch G, Terbrugge K, Burrows P, Lasjaunias P. Multifocal dural arteriovenous shunts in children. *Childs Nerv Syst* 1991;7:425-31.
  34. Takai K, Kin T, Oyama H, Iijima A, Shojima M, Nishido H, et al. The use of 3D computer graphics in the diagnosis and treatment of spinal vascular malformations. *J Neurosurg Spine* 2011;15:654-9.
  35. Aviv RI, Shad A, Tomlinson G, Niemann D, Teddy PJ, Molyneux AJ, et al. Cervical dural arteriovenous fistulae manifesting as subarachnoid hemorrhage: Report of two cases and literature review. *AJNR Am J Neuroradiol* 2004;25:854-8.
  36. Kai Y, Hamada J, Morioka M, Yano S, Mizuno T, Kuratsu J. Arteriovenous fistulas at the cervicomedullary junction presenting with subarachnoid hemorrhage: Six case reports with special reference to the angiographic pattern of venous drainage. *AJNR Am J Neuroradiol* 2005;26:1949-54.
  37. Zhao J, Xu F, Ren J, Manjila S, Bambakidis NC. Dural arteriovenous fistulas at the craniovertebral junction: A systematic review. *J Neurointerv Surg* 2016;8:684-3.
  38. Kim DJ, Willinsky R, Geibprasert S, Krings T, Wallace C, Gentili F, et al. Angiographic characteristics and treatment of cervical spinal dural arteriovenous shunts. *AJNR Am J Neuroradiol* 2010;31:1512-15.
  39. Mitsushashi Y, Aurboonyawat T, Pereira VM, Geibprasert S, Toulgoat F, Ozanne A, et al. Dural arteriovenous fistulas draining into the petrosal vein or bridging vein of the medulla: Possible homologs of spinal dural arteriovenous fistulas. *Clinical article. J Neurosurg* 2009;111:889-99.