


*Case Report*

# Resolution of venous pressure gradient in a patient with idiopathic intracranial hypertension after ventriculoperitoneal shunt placement: A proof of secondary cerebral sinovenous stenosis

Thomas Buell<sup>1</sup>, Dale Ding<sup>2</sup>, Daniel Raper<sup>3</sup>, Ching-Jen Chen<sup>4</sup>, Zaid Aljuboory<sup>5</sup>, Davis Taylor<sup>4</sup>, Tony Wang<sup>6</sup>, Natasha Ironside<sup>4</sup>, Robert Starke<sup>7</sup>, Kenneth Liu<sup>8</sup>

<sup>1</sup>Department of Neurosurgery, Duke University, Durham, North Carolina, <sup>2</sup>Department of Neurological Surgery, University of Louisville School of Medicine, Louisville, Kentucky, <sup>3</sup>Department of Neurosurgery, Baylor College of Medicine, Houston, Texas, <sup>4</sup>Department of Neurosurgery, University of Virginia, Charlottesville, Virginia, <sup>5</sup>Department of Neurosurgery, University of Louisville, Louisville, Kentucky, <sup>6</sup>Department of Neurosurgery, University of California Los Angeles, Los Angeles, California, <sup>7</sup>Department of Neurosurgery, University of Miami Health System, Miami, Florida, <sup>8</sup>Department of Neurosurgery, University of Southern California, Los Angeles, California, United States.

E-mail: Thomas Buell - thomas.buell@duke.edu; Dale Ding - dale.ding@ulp.org; Daniel Raper - daniel.raper@bcm.edu; Ching-Jen Chen - cc5hx@virginia.edu; \*Zaid Aljuboory - zaid.aljuboory@yahoo.com; Davis Taylor - dt4aa@virginia.edu; Tony Wang - trwang@mednet.ucla.edu; Natasha Ironside - ni8vb@virginia.edu; Robert Starke - rstarke@med.miami.edu; Kenneth Liu - kenneth.c.liu@gmail.com



**\*Corresponding author:**

Zaid Aljuboory,  
Department of Neurosurgery,  
University of Louisville, 220  
Abraham Flexner Way Ste.  
1500, Louisville - 40202,  
Kentucky, United States.  
[zaid.aljuboory@yahoo.com](mailto:zaid.aljuboory@yahoo.com)

Received : 03 October 2020  
Accepted : 25 December 2020  
Published : 13 January 2021

DOI  
10.25259/SNI\_700\_2020

**Quick Response Code:**



## ABSTRACT

**Background:** The relationship between idiopathic intracranial hypertension (IIH) and cerebral sinovenous stenosis (CSS) remains unclear. The effects of cerebrospinal fluid (CSF) diversion on venous sinus physiology have not been rigorously investigated. We describe the effect of ventriculoperitoneal shunt (VPS) placement on sinovenous pressures in the setting of IIH and CSS.

**Case Description:** A patient in their 30 s presented with headache and transient visual obscurations for few months and was diagnosed with IIH. Catheter cerebral venography showed focal stenosis of the right transverse sinus (TS) with a trans-stenosis pressure gradient (TSG) of 20 mmHg. The patient was treated with VPS. During the procedure, we performed a real-time measurement of ventricular CSF and cerebral sinovenous pressures. VPS selectively reduced the TS pressure and abolished the preoperative TS-TSG within 20 min of CSF diversion without altering the sigmoid sinus (SS) pressure. Our findings suggest that CSS can be an epiphenomenon, rather than the primary etiology in some patients with IIH.

**Conclusion:** IIH is a challenging condition, in certain patients the radiographic stenosis and trans-stenosis gradient were an epiphenomenon because of the increased intracranial pressure that resulted in reversible TS-SS stenosis.

**Keywords:** Headache, Idiopathic intracranial hypertension, Venous sinus stenosis

## INTRODUCTION

Cerebral sinovenous stenosis (CSS) is present in the majority of patients with idiopathic intracranial hypertension (IIH).<sup>[5,10,14]</sup> It is unclear whether CSS is a primary causative etiology

This is an open-access article distributed under the terms of the Creative Commons Attribution-Non Commercial-Share Alike 4.0 License, which allows others to remix, tweak, and build upon the work non-commercially, as long as the author is credited and the new creations are licensed under the identical terms.

©2020 Published by Scientific Scholar on behalf of Surgical Neurology International

of IIH or secondary to elevated intracranial pressure (ICP) which compresses the venous sinus wall resulting in focal stenosis.<sup>[1,6,7,16]</sup> Prior studies have demonstrated radiologic resolution of transverse sinus (TS) stenosis after cerebrospinal fluid (CSF) diversion, which suggests that CSS is a secondary phenomenon in some cases of IIH.<sup>[8,9,11]</sup> Permanent CSF diversion is the mainstay of therapy for IIH.<sup>[3,8,9,11]</sup> However, despite the radiographic characterization of CSS reversibility after CSF diversion, its effects on venous physiology have not been rigorously investigated.<sup>[8,9,11]</sup> Therefore, in this study, we analyzed the physiologic effects of CSF diversion on cerebral sinovenous pressures in real-time.

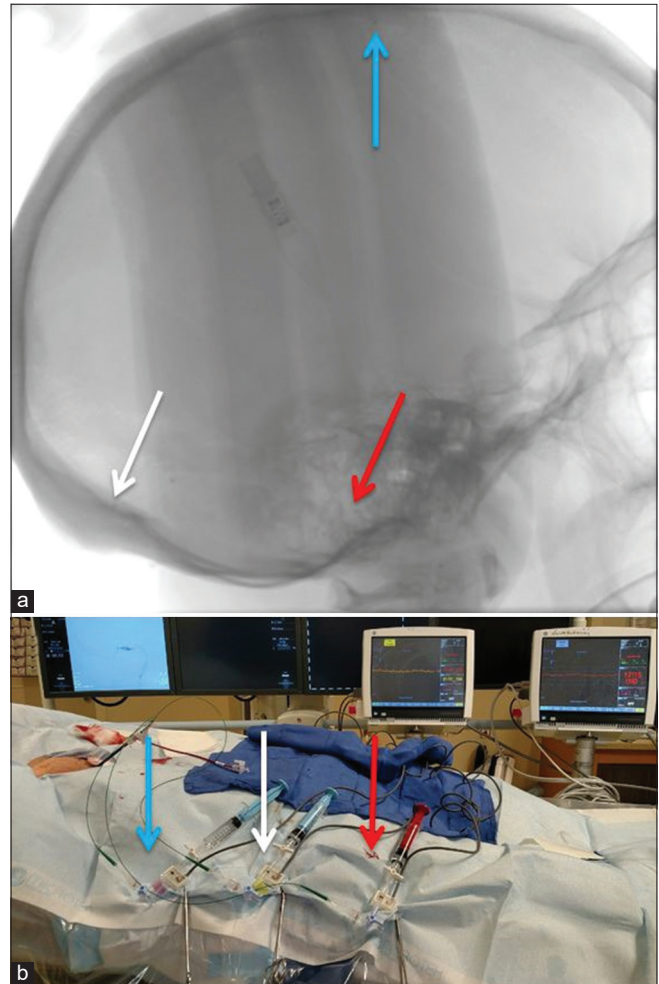
## CASE DESCRIPTION

A 32-year-old morbidly obese (body mass index 43.3 kg/m<sup>2</sup>) female presented with a 6-month history of headaches, pulse-synchronous tinnitus, and transient visual obscurations; she was diagnosed with IIH because of elevated ICP (>25 cm H<sub>2</sub>O) and the presence of bilateral papilledema. A trial of acetazolamide provided some improvement, but the patient did not tolerate the medication due to paresthesia. Brain MRV demonstrated a hypoplastic left TS and a dominant right TS with >50% stenosis. Furthermore, catheter cerebral venography showed severe stenosis of the dominant right TS, and venous manometry identified a trans-stenosis pressure gradient (TSG) of 20 mmHg. After a discussion of various treatment options, including ventriculoperitoneal shunt (VPS) placement and venous sinus stenting (VSS), the patient elected to proceed with VPS.

### Technique for concurrent VPS placement and sinovenous pressure monitoring

The patient was brought to a hybrid operating room with the capability to perform intraoperative biplane digital subtraction angiography. After induction of general anesthesia, the procedure was performed with the patient in a supine position with the head rotated to the left. As detailed in prior publications,<sup>[12,13]</sup> right common femoral venous access was obtained and a shuttle guiding catheter was advanced into the right jugular bulb. Next, three microcatheters were navigated through the shuttle and positioned in the S3 segment of the superior sagittal sinus (SSS), right TS, and right sigmoid sinus (SS); [Figure 1]. The microcatheters were each connected to a pressure transducer in preparation for intraoperative pressure recording.

The distal portion of the VPS was performed in a standard fashion. Through a right frontal burr hole, CT-guided frameless stereotactic neuronavigation (Stealth Station® S7, Medtronic, Minneapolis, MN) was used to place a



**Figure 1:** A lateral fluoroscopic image was taken that shows the final position of the three microcatheters (a). The microcatheters were each connected to pressure transducers in preparation for intraoperative recording (b), (blue arrow [SSS], white arrow [TS], and red arrow [SS]).

ventricular catheter into the right frontal horn. Then, the ventricular catheter was connected to a pressure transducer, a pre-shunt ventricular CSF and venous sinus pressures were recorded for 5 min. The ventricular catheter was then connected to the distal portion of the shunt, and after confirming distal CSF flow the distal catheter was placed into the peritoneal cavity. A post-shunt venous sinus pressure measurements were continuously recorded for approximately 20 min at 10-s intervals. No significant changes were made in the administered anesthetic agent (sevoflurane) during this time.<sup>[13]</sup> The CSF pulse wave is comprised three main components: P1 (percussion wave), P2 (tidal or compliance wave), and P3 (dicrotic wave).<sup>[4,15]</sup> We defined similar waveform peaks for the venous waveform observed in the intracranial dural venous sinuses: P1 and P2. Intraoperative video recordings of all pressure waveforms were analyzed for amplitude changes of the P1 and P2 waves.

### Statistical analysis

The data were averaged every minute to generate scatter and line plots. A Student's t-test was used for pairwise comparison of the ventricular CSF and venous sinus pressures before and after CSF drainage. Furthermore, Pearson's correlations were computed for the ventricular CSF and venous sinus pressures. We used a significance level of  $P < 0.05$ .

### Baseline ventricular CSF, venous sinus pressures, and waveform morphologies

The mean ventricular CSF, SSS, TS, TS-SS trans-stenosis gradient, and SS pressures were  $38.5 \pm 3.2$  mmHg,  $36.4 \pm 2.3$  mmHg,  $34.2 \pm 2.3$  mmHg,  $19 \pm 1.8$  mmHg, and  $15.3 \pm 0.7$  mmHg, respectively [Figure 2]. The pre-drainage ventricular CSF, SSS, and TS pressure waveform morphologies appeared similar to a higher amplitude of P2 compared to P1 [Figure 3a and b], while the SS pressure waveform had a different morphology [Figure 3c].

### Ventricular CSF, venous sinus pressures, and waveform morphologies during CSF drainage

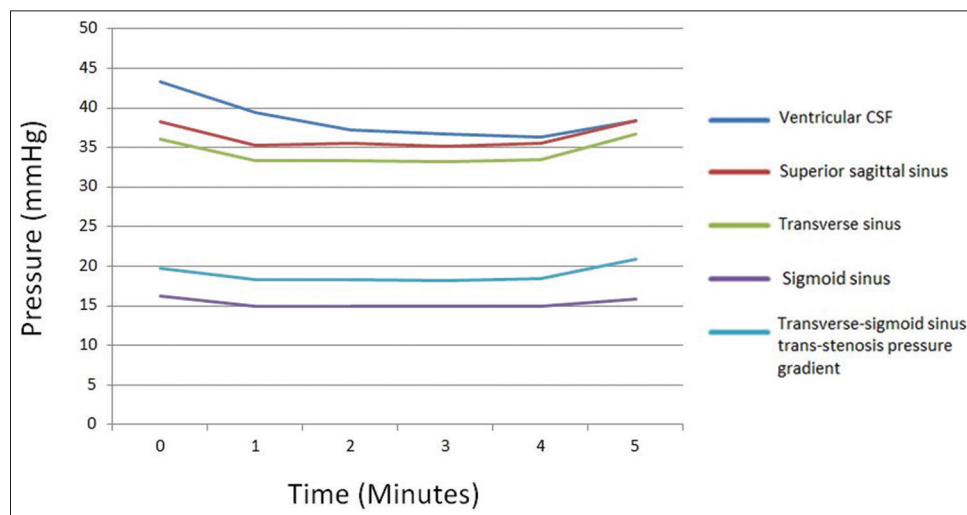
The TS-SS trans-stenosis gradient, SSS, and TS pressures negatively correlated with the duration of CSF drainage ( $r = -0.96$ ,  $P < 0.001$ ), SSS ( $r = -0.96$ ,  $P < 0.001$ ), and TS ( $r = -0.96$ ,  $P < 0.001$ ), respectively [Figure 4]. There was a significant, but relatively weaker, negative correlation between SS pressures and CSF drainage ( $r = -0.54$ ,  $P = 0.012$ ). The venous pressure recordings during the past 5 min of CSF drainage was significantly lower than the baseline (pre-drainage) pressures, SSS ( $20.3 \pm 1.3$  vs.  $36.2 \pm 2.1$  mmHg;  $P < 0.001$ ), TS ( $18.9 \pm 1.3$  vs.  $34.2 \pm 2.3$  mmHg;  $P < 0.001$ ), and TS-SS trans-stenosis

gradient ( $3.8 \pm 1.5$  vs.  $18.9 \pm 1.8$  mmHg;  $P < 0.001$ ). Notably, this change was not observed in SS pressure recordings ( $15.1 \pm 0.9$  vs.  $15.3 \pm 0.7$  mmHg;  $P = 0.405$ ).

The SSS and TS waveform morphologies had characteristic changes as ventricular CSF diversion progressed [Figure 5]. Initially, the amplitude of P2 was greater than P1, but after 3 min of CSF drainage, the P2 amplitude began to decrease. At the 4 min post-drainage time point, the P2 and P1 amplitudes were approximately equivalent in the TS and SSS. At the 5 min post-drainage time point, the P2 amplitude decreased below the P1 amplitude in both the SSS and TS, which persisted throughout the remainder of the recording.

### DISCUSSION

The conventional treatment of medically refractory IIH is predominantly CSF diversion. However, this modality can be complicated by the patients' body habitus, slit-like ventricles, and high rates of shunt failure.<sup>[2]</sup> Endovascular treatment with VSS has recently emerged as an effective alternative to CSF diversion in patients with IIH and CSS with trans-stenosis gradient of ( $\geq 8$  mmHg).<sup>[12]</sup> There are no clear cut guidelines on choosing between these two treatment modalities because of the ambiguity surrounding the pathophysiology of IIH. In this report, we aimed at evaluating the nature of CSS and its relation to IIH. The ability to distinguish a primary CSS that results in IIH from CSS that is secondary to increased ICP can help in refining the existing treatment paradigms. Previous investigations of the nature of CSS in IIH have used static radiographic and/or pressure measurements that were performed after CSF diversion.<sup>[8,9,11]</sup> Whereas, in this report, we evaluated the dynamics of the intracranial venous

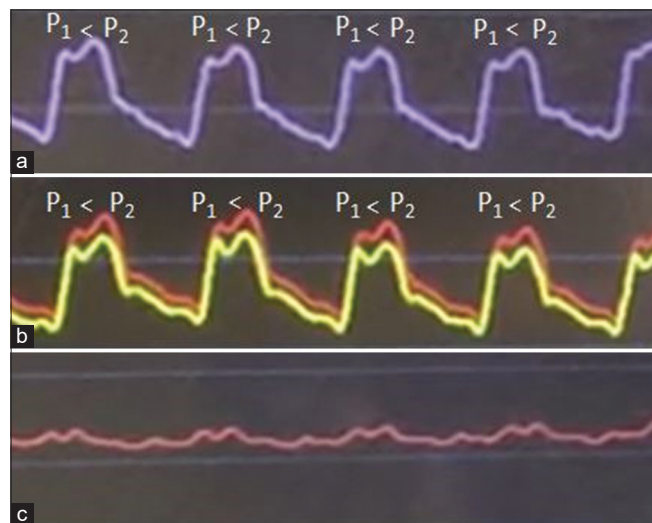


**Figure 2:** A graph that shows the baseline ventricular cerebrospinal fluid (CSF) and venous sinus pressures before ventricular CSF diversion, over a period of 5 min.



and CSF pressures before, during, and after CSF drainage in real-time.

Our findings demonstrate the existence of dynamic interaction between intracranial CSF volume and the

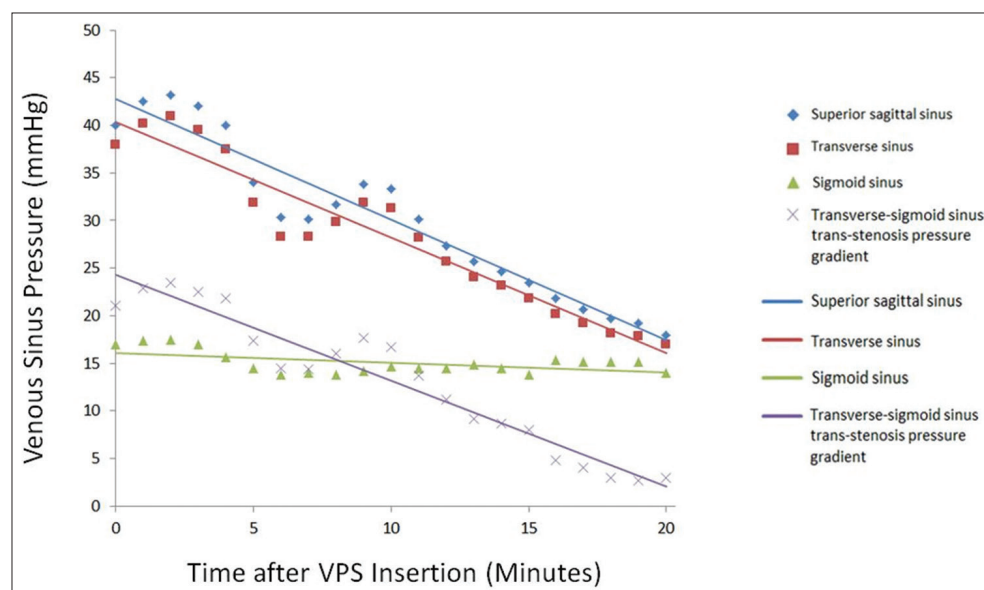


**Figure 3:** A graph that shows the ventricular cerebrospinal fluid (CSF) pressure with the P1 (percussion wave) and P2 (tidal or compliance wave) indicated (a). Similar waveform peaks are observed in pressure measurements taken in the intracranial dural venous sinuses (b). Intraoperative video recording of superior sagittal sinus (red) and transverse sinus (yellow) pressure waveforms, demonstrates morphologic similarity to ventricular CSF waveform, with P2 amplitude higher than P1. Intraoperative video recording of sigmoid sinus waveform (c) demonstrating morphologic distinction from the supratentorial venous waveforms.

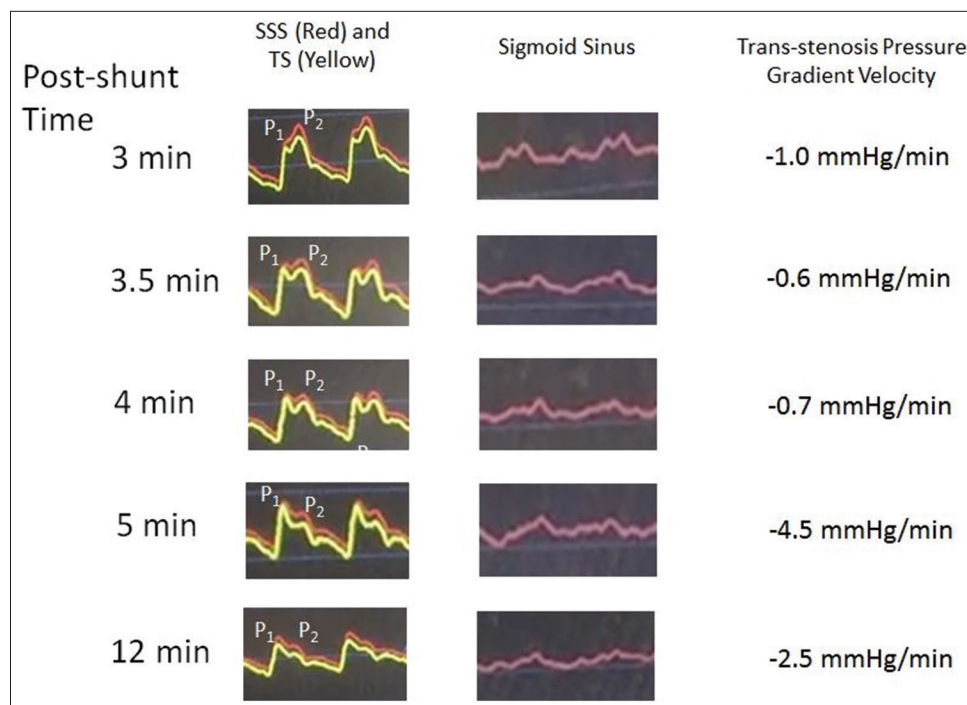
pressures within the venous sinuses. Wherein CSF drainage led to a progressive decrease in the venous pressure of the SSS and TS and eventually abolished the TS-SS trans-stenosis gradient (19–4 mmHg,  $P < 0.001$ ) at the 20 min time point. Notably, the CSF drainage did not affect the pressure in SS. These results suggest that the radiographic stenosis and trans-stenosis gradient were an epiphenomenon because of the increased ICP that resulted in reversible TS-SS stenosis. This secondary CSS can lead to a further increase in ICP which creates a vicious cycle where the increase in ICP leads to worsened CSS and higher venous pressure.

As for the waveform, the higher amplitude of P2 before CSF drainage indicates lower brain compliance secondary to increased ICP. The P2 wave amplitude starts to decline after 3 min of CSF drainage and becomes equal to the P1 wave after 4 min, and then becomes lower than P1 after 5 min which indicates an increase in brain compliance. This pattern can vary depending on the baseline ICP and the rate of CSF drainage.

The generalizability of our findings is limited by the observational nature of the study and sample size; therefore, future studies are warranted to expand on our findings. However, this report has shown crucial findings that can lead the way to resolve the enigma of IIH. Finally, it is important to acknowledge that primary and secondary CSS can coexist and contribute to the overall development of IIH which adds further complexity to the pathophysiology of this condition.



**Figure 4:** A line graph that shows the intracranial venous sinus pressures over time, during cerebrospinal fluid drainage. A ventricular catheter was inserted, and superior sagittal sinus, transverse sinus (TS), and sigmoid sinus (SS) pressures, as well as the TS-SS trans-stenosis pressure gradient were recorded for the initial 20 min.



**Figure 5:** A graph that shows the change in appearance of venous sinus pressure waveforms after ventricular drainage, over time. Immediately after placement of ventricular catheter and initiation of ventricular drainage, P2 amplitude remained greater than P1. After 3 min of cerebrospinal fluid (CSF) diversion, P2 amplitude began to decrease. At 3.5 min post-shunt, the P2 and P1 amplitudes were roughly equivalent in the transverse sinus (TS). However, P2 amplitude was still higher than P1 in the superior sagittal sinus (SSS). At 4 min post-shunt, P2 and P1 amplitudes appeared equivalent in the SSS. After 5 min of CSF diversion, P2 amplitude began to decrease below P1 in both the SSS and TS.

## CONCLUSION

By performing intraoperative venous manometry during VPS placement in an IIH patient with CSS and an associated TSG, we offer direct evidence that abnormalities of cerebral sinovenous physiology can be reversed with CSF diversion. Our findings indicate that, in some patients with IIH, the development of CSS and a TSG is an epiphenomenon of pathologically elevated ICP, rather than a primary etiology of this disease process. Although further studies are necessary, this preliminary data suggest that IIH patients with secondary CSS can be successfully treated with CSF shunting.

## Declaration of patient consent

Patient's consent not required as patients identity is not disclosed or compromised.

## Financial support and sponsorship

Nil.

## Conflicts of interest

There are no conflicts of interest.

## REFERENCES

1. Baryshnik DB, Farb RI. Changes in the appearance of venous sinuses after treatment of disordered intracranial pressure. *Neurology* 2004;62:1445-6.
2. Brune AJ, Girgla T, Trobe JD. Complications of ventriculoperitoneal shunt for idiopathic intracranial hypertension: A single-institution study of 32 patients. *J Neuroophthalmol*. 2020 Mar 24. Epub ahead of print.
3. Bynke G, Zemack G, Bynke H, Romner B. Ventriculoperitoneal shunting for idiopathic intracranial hypertension. *Neurology* 2004;63:1314-6.
4. Cardoso ER, Rowan JO, Galbraith S. Analysis of the cerebrospinal fluid pulse wave in intracranial pressure. *J Neurosurg* 1983;59:817-21.
5. Farb RI, Vanek I, Scott JN, Mikulis DJ, Willinsky RA, Tomlinson G, et al. Idiopathic intracranial hypertension: The prevalence and morphology of sinovenous stenosis. *Neurology* 2003;60:1418-24.
6. Higgins JN, Cousins C, Owler BK, Sarkies N, Pickard JD. Idiopathic intracranial hypertension: 12 Cases treated by venous sinus stenting. *J Neurol Neurosurg Psychiatry* 2003;74:1662-6.
7. Higgins JN, Owler BK, Cousins C, Pickard JD. Venous sinus stenting for refractory benign intracranial hypertension. *Lancet* 2002;359:228-30.
8. Higgins JN, Pickard JD. Lateral sinus stenoses in idiopathic intracranial hypertension resolving after CSF diversion.

- Neurology 2004;62:1907-8.
9. Horev A, Hallevy H, Plakht Y, Shorer Z, Wirguin I, Shelef I. Changes in cerebral venous sinuses diameter after lumbar puncture in idiopathic intracranial hypertension: A prospective MRI study. *J Neuroimaging* 2013;23:375-8.
10. King JO, Mitchell PJ, Thomson KR, Tress BM. Cerebral venography and manometry in idiopathic intracranial hypertension. *Neurology* 1995;45:2224-8.
11. King JO, Mitchell PJ, Thomson KR, Tress BM. Manometry combined with cervical puncture in idiopathic intracranial hypertension. *Neurology* 2002;58:26-30.
12. Liu KC, Starke RM, Durst CR, Wang TR, Ding D, Crowley RW, *et al.* Venous sinus stenting for reduction of intracranial pressure in IIH: A prospective pilot study. *J Neurosurg* 2017;127:1126-33.
13. Raper DM, Buell TJ, Chen CJ, Ding D, Starke RM, Liu KC. Intracranial venous pressures under conscious sedation and general anesthesia. *J Neurointerv Surg* 2017;9:986-9.
14. Riggeal BD, Bruce BB, Saindane AM, Ridha MA, Kelly LP, Newman NJ, *et al.* Clinical course of idiopathic intracranial hypertension with transverse sinus stenosis. *Neurology* 2013;80:289-95.
15. Robertson CS, Narayan RK, Contant CF, Grossman RG, Gokaslan ZL, Pahwa R, *et al.* Clinical experience with a continuous monitor of intracranial compliance. *J Neurosurg* 1989;71:673-80.
16. Rohr A, Dorner L, Stingele R, Buhl R, Alfke K, Jansen O. Reversibility of venous sinus obstruction in idiopathic intracranial hypertension. *AJNR Am J Neuroradiol* 2007;28:656-9.

**How to cite this article:** Buell T, Ding D, Raper D, Chen CJ, Aljuboori Z, Taylor D, *et al.* Resolution of venous pressure gradient in a patient with idiopathic intracranial hypertension after ventriculoperitoneal shunt placement: A proof of secondary cerebral sinovenous stenosis. *Surg Neurol Int* 2021;12:14.