

# An unusual masquerade of community acquired pneumonia: Left-side unilateral pulmonary edema

Akashdeep Singh, Gupreet Singh Wander<sup>1</sup>

Departments of Pulmonary and Critical Care Medicine, and <sup>1</sup>Cardiology, Dayanand Medical College and Hospital, Ludhiana, Punjab, India

## ABSTRACT

The diagnosis of pneumonia is clinical, based on the history of lower respiratory tract symptoms, physical, and/or radiographic signs of consolidation. Several diseases such as congestive heart failure, pulmonary embolism, and chemical pneumonitis may present with similar symptoms, signs, and chest radiographs, thus delaying the definitive diagnosis and initiation of appropriate treatment. Unilateral pulmonary edema (UPE) is a rare clinical entity that is often misdiagnosed at first as a focal lung disease. We have presented an unusual case of left-sided UPE in a 76-year-old man who developed acute heart failure resulting from dietary and pharmacological noncompliance. The patient was successfully managed with decongestive therapy and non-invasive mechanical ventilation.

**KEY WORDS:** Consolidation, pneumonia, pulmonary edema, respiratory failure

**Address for correspondence:** Dr. Akashdeep Singh, Department of Pulmonary and Critical Care Medicine, Dayanand Medical College and Hospital, Ludhiana, Punjab, India. E-mail: drsinghakashdeep@gmail.com

## INTRODUCTION

Pulmonary edema is usually bilateral, but unilateral pulmonary edema (UPE) can also be seen in clinical practice. UPE can masquerade pneumonia, as it may present with similar clinical and radiological findings. Furthermore, UPE may represent a diagnostic challenge to the physician and is considered in the differential diagnosis after treatment failure. This misdiagnosis can result in inappropriate management, unnecessary cost, and the respective risks related to the untreated potentially life-threatening condition. Discrimination between UPE and pneumonia is difficult at times and involves careful analysis of history, physical findings, and specific diagnostic tests like B-type natriuretic peptide (BNP), procalcitonin (PCT), and echocardiography. Most cases of UPE reported in the English literature have been on the right side. Here, we have described the case of a 76-year-old man who developed acute left-sided UPE resulting from

dietary and pharmacological noncompliance. The patient was successfully managed with decongestive therapy and non-invasive mechanical ventilation.

## CASE REPORT

A 76-year-old man, a known case of dilated cardiomyopathy, presented to the Emergency Department with severe breathlessness and cough productive of blood stained sputum of 2 days duration. His compliance with diet and medication was poor.

At admission, he was orthopnic, had an RR of 40 bpm, BP of 140/100 mmHg, HR of 110/min, and body temperature of 37.2°C. His neck veins were full, and there was pedal edema. Respiratory system examination revealed impaired percussion note and fine crackles in the entire left hemithorax. Cardiac auscultation revealed S3 gallop and a high-pitched, holosystolic murmur at apex radiating to the left axilla.

Laboratory investigations revealed a TLC of 14000/ $\mu$ L with 75% neutrophils. Chest radiograph showed left-sided airspace disease with cardiomegaly [Figure 1] and electrocardiogram showed LBBB. His creatinine 1.4 mg/dL, sodium 140 mEq/L, potassium 4.0 mEq/L, B-natriuretic peptide 1200 pg/mL, creatine kinase isoenzyme MB 6.1 ng/mL, and troponin I 0.14 ng/mL.

### Access this article online

#### Quick Response Code:

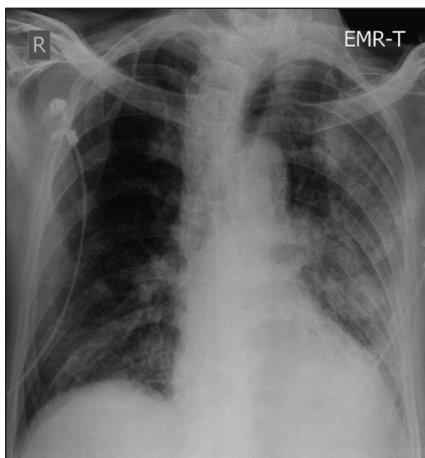


#### Website:

www.lungindia.com

#### DOI:

10.4103/0970-2113.120617



**Figure 1:** Chest radiograph showed left-sided patchy airspace disease with cardiomegaly

Differential diagnosis of pneumonia versus UPE was kept. He was started on oxygen, diuretics, low molecular weight heparin, GTN infusion, anti-platelets, statins, intravenous antibiotics (cefepime and azithromycin), and non-invasive mechanical ventilation. Echocardiography done revealed a reduced global left-ventricular ejection fraction (LVEF 35%), and a large eccentric mitral regurgitation jet reaching the left pulmonary veins. His serial CRP and PCT were low. His cultures (sputum and blood) did not grow any organism, and therefore antibiotic were discontinued on day 4. With decongestive therapy, there was significant clinico-radiological improvement. Repeat chest radiography done after 48 h of admission showed significant resolution of the unilateral opacities [Figure 2]. The patient was discharged uneventfully on day 5 of hospitalization, and presently he is on a regular follow-up with the Cardiology Department.

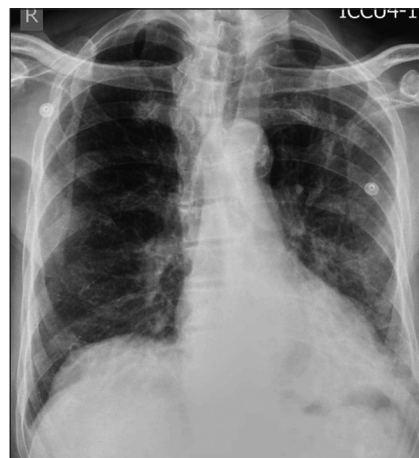## DISCUSSION

Acute cardiogenic pulmonary edema is a life-threatening condition with high mortality. Clinically, it is characterized by rapid onset of dyspnea, tachypnea, tachycardia, and severe hypoxemia. The radiological hallmark of cardiogenic pulmonary edema is bilateral symmetrical opacities in the perihilar area resulting in the classic “butterfly shadow” or “bat’s wing” appearance.

UPE is a rare clinical entity that presents diagnostic challenges and is often misdiagnosed at first for pneumonia, aspiration, or alveolar hemorrhage.

Cardiogenic UPE is a rare clinical entity occurring in about 2% cases of congestive heart failure.<sup>[1]</sup> UPE has been reported after congestive heart failure,<sup>[2]</sup> mitral valve insufficiency,<sup>[3]</sup> and fluid overload from various causes.<sup>[4,5]</sup>

Unilateral oedema with ipsilateral pathology has been reported with prolonged lateral decubitus position,<sup>[6]</sup> rapid thoracentesis,<sup>[7]</sup> after acute upper airway obstruction,<sup>[8]</sup>



**Figure 2:** Chest radiograph done 48 h after decongestive therapy shows resolution of the opacities

pulmonary contusion,<sup>[9]</sup> talc pleurodesis,<sup>[10]</sup> pulmonary vein occlusion,<sup>[11]</sup> and congenital or surgical systemic to pulmonary shunt (e.g., Blalock-Taussig shunt).<sup>[12]</sup>

Unilateral oedema with perfusion abnormality in the contralateral lung occur with unilateral pulmonary embolism,<sup>[13]</sup> unilateral hypoplasia of pulmonary artery,<sup>[14]</sup> Swyer-James syndrome, and unilateral emphysema/bullae. However, severe MR (organic or functional MR) is the main cause of UPE.<sup>[1]</sup>

Most cases of UPE associated with heart failure affect the right lung. In a study by Attias *et al.*, UPE was right-sided in 89% of cases and left-sided UPE was infrequent, representing only 0.2% of all cardiogenic pulmonary edema cases.<sup>[1]</sup> Left-sided UPE as a consequence of mitral regurgitation is rare. Tomcsanyi *et al.*, reported a case of left-sided UPE due to an eccentric mitral regurgitation, which complicates an inferior acute myocardial infarction.<sup>[15]</sup>

UPE is often misdiagnosed at first for other causes of unilateral alveolar and interstitial infiltrates, especially pneumonia, resulting in delay in initiating optimal treatment. Choi *et al.*, demonstrated an average delay of 4–5 days in initiating appropriate treatment of CHF in patients with cardiogenic UPE.<sup>[16]</sup> Furthermore, patients with UPE have a higher risk of mortality, 6.9-fold higher, than patients with bilateral pulmonary edema, and delay in adequate treatment of UPE may be one explanation for this increased mortality.<sup>[1]</sup>

BNP is of great help in differentiating between acute pulmonary edema of cardiogenic or non-cardiogenic origin. The possibility of heart failure is very low when BNP levels are <100 pg/ml (negative predictive value 90%), while the possibility of heart failure is very high when BNP levels are >500 pg/ml (positive predictive value 90%).<sup>[17]</sup>

In our case, the patient was diagnosed to have left-sided pulmonary edema, despite the unilateral pulmonary

infiltrate on the basis of absence of fever, organic MR, negative cultures, high level of B-natriuretic peptide, and low PCT and CRP levels. The indexed case had very rapid disappearance of left-sided opacities, following optimal and aggressive treatment of congestive heart failure.

UPE is an uncommon presentation of cardiogenic pulmonary edema. Asymmetrical opacities on a chest skiagram usually have a respiratory cause, but UPE must be kept in mind, especially in patients with compatible clinical presentation. Early and aggressive treatment should be initiated promptly to avert bad prognosis.

## REFERENCES

1. Attias D, Mansencal N, Auvert B, Vieillard-Baron A, Delos A, Lacombe P, *et al.* Prevalence, characteristics, and outcomes of patients presenting with cardiogenic unilateral pulmonary edema. *Circulation* 2010;122:1109-15.
2. Nitzan O, Saliba WR, Goldstein LH, Elias MS. Unilateral pulmonary edema: A rare presentation of congestive heart failure. *Am J Med Sci* 2004;327:362-4.
3. Legriel S, Tremey B, Mentec H. Unilateral pulmonary edema related to massive mitral insufficiency. *Am J Emerg Med* 2006;24:372.
4. Di Benedetto C, Brunner W, Kuhn M. Unilateral pulmonary edema in a dialysis patient with massive fluid overload and mitral valve insufficiency. *Praxis (Bern 1994)* 2003;92:1265-8.
5. Balogun SA, Balogun RA. Acute unilateral pulmonary edema from dietary salt and water load: a case report and review of the literature. *Conn Med* 2001;65:653-6.
6. Modi M, Shah V, Modi P. Unilateral dependant pulmonary edema during laparoscopic donor nephrectomy: report of three cases. *Indian J Anaesth* 2009;53:475-7.
7. Murat A, Arslan A, Balci AE. Re-expansion pulmonary edema. *Acta Radiol* 2004;45:431-3.
8. Peixoto AJ. Asymmetric negative pressure pulmonary edema after acute upper airway obstruction. *Rev Bras Anesthesiol* 2002;52:335-43.
9. Agarwal R, Aggarwal AN, Gupta D. Other causes of unilateral pulmonary edema. *Am J Emerg Med* 2007;25:129-31.
10. Scalzetti EM. Unilateral pulmonary edema after talc pleurodesis. *J Thorac Imaging* 2001;16:99-102.
11. Routsis C, Charitos C, Rontogianni D, Daniil Z, Zakynthinos E. Unilateral pulmonary edema due to pulmonary venous obstruction from fibrosing mediastinitis. *Int J Cardiol* 2006;108:418-21.
12. Webb WR. Pulmonary edema, the acute respiratory distress syndrome and radiology in the intensive care unit. In: Webb WR, Higgins CB, editors. *Thoracic imaging: Pulmonary and cardiovascular radiology*. 2<sup>nd</sup> ed. Philadelphia: Lippincott Williams and Wilkins; 2011. p. 348-74.
13. Zegdi R, Dürleman N, Achouh P, Boussaud V, Guillemain R, Amrein C, *et al.* Unilateral pulmonary edema after pulmonary embolism in a bilateral lung transplant patient. *Ann Thorac Surg* 2007;84:2086-8.
14. Maskatia SA, Feinstein JA, Newman B, Hanley FL, Roth SJ. Pulmonary reperfusion injury after the unifocalization procedure for tetralogy of Fallot, pulmonary atresia, and major aortopulmonary collateral arteries. *J Thorac Cardiovasc Surg* 2012;144:184-9.
15. Tomcsanyi J, Arabadzisz H, Bozsik B. Images in cardiology: Left sided unilateral pulmonary oedema. *Heart* 2005;91:1157.
16. Choi HS, Choi H, Han S, Kim HS, Lee C, Kim YY, *et al.* Pulmonary edema during pregnancy: Unilateral presentation is not rare. *Circ J* 2002;66:623-6.
17. Morrison LK, Harrison A, Krishnaswamy P, Kazanegra R, Clopton P, Maisel A. Utility of a rapid B-natriuretic peptide (BNP) assay in differentiating congestive heart failure from lung disease in patients presenting with dyspnea. *J Am Coll Cardiol* 2002;39:202-9.

**How to cite this article:** Singh A, Wander GS. An unusual masquerade of community acquired pneumonia: Left-side unilateral pulmonary edema. *Lung India* 2013;30:344-6.

**Source of Support:** Nil, **Conflict of Interest:** None declared.