

Single Case – General Neurology

Colocalization of Tau but Not β -Amyloid with Cortical Superficial Siderosis in a Case with Probable CAA

Matthias Brendel^a Cihan Catak^b Leonie Beyer^a Jennifer Linn^c
Hannes Wahl^c Daniel Janowitz^b Axel Rominger^{a, d} Marianne Patt^e
Henryk Barthel^e Osama Sabri^e Peter Bartenstein^a
Frank Arne Wollenweber^{b, f}

^aDepartment of Nuclear Medicine, University Hospital of Munich, Ludwig-Maximilians-Universität (LMU), Munich, Germany; ^bInstitute for Stroke and Dementia Research, University Hospital of Munich, Ludwig-Maximilians-Universität (LMU), Munich, Germany; ^cInstitut und Poliklinik für Neuroradiologie, Universitätsklinikum Carl Gustav Carus, Dresden, Germany; ^dDepartment of Nuclear Medicine, Inselspital, Bern University Hospital, University of Bern, Bern, Switzerland; ^eDepartment of Nuclear Medicine, University Hospital of Leipzig, Leipzig, Germany; ^fDepartment of Neurology, Helios Dr. Horst Schmidt hospital, Wiesbaden, Germany

Keywords

Cortical superficial siderosis · Tau imaging · Amyloid imaging · Cerebral amyloid angiopathy

Abstract

Cortical superficial siderosis (cSS) is a common feature in patients with cerebral amyloid angiopathy (CAA). The correlation between β -amyloid and/or tau pathology and the occurrence of cSS is unclear. We report on an 80-year-old male patient who was diagnosed with probable CAA according to modified Boston criteria and underwent longitudinal magnetic resonance imaging, amyloid positron emission tomography (PET), and additional tau PET imaging. Amyloid deposition presented predominantly in the contralateral hemisphere not affected by cSS. In contrast, tau deposition was predominantly overlapping with brain regions affected by cSS. Amyloid deposition was not different in the vicinity of cSS whereas tau depositions were

elevated in the vicinity of CSS-affected regions compared to non-cSS-affected brain regions. This case of probable CAA suggests that cSS may be associated with a locally elevated tau pathology but not with increased fibrillary amyloid deposition.

© 2020 The Author(s)
Published by S. Karger AG, Basel

Introduction

Cerebral amyloid angiopathy (CAA) is a vascular disease with the neuropathological evidence of β -amyloid (A β) deposition in the walls of the cortical and leptomeningeal vessels [1]. The clinical presentation includes intracerebral macrohemorrhages and cerebral microbleeds [2]. Cortical superficial siderosis (cSS) occurs in the majority of patients with histopathologically proven CAA [3]. The regional interrelation between A β and/or tau depositions and the presence of cSS is not yet understood.

Case Report/Presentation

We report on an 80-year-old male patient who suffered a cryptogenic ischemic stroke in the right cerebellum in April 2012. The patient was included in the longitudinal Determinants of Dementia after Stroke (DEDEMAS) study [4] and underwent serial standardized magnetic resonance imaging (MRI) in combination with ¹⁸F-florbetaben [5] A β positron emission tomography (PET) at 6 months according to the study protocol (NCT01334749). Amyloid PET at baseline demonstrated mild positivity. At the follow-up visit in 2015 the patient demonstrated an incident mild cognitive impairment diagnosed by Petersen criteria [6] and an incident focal cSS. A diagnostic lumbar puncture revealed reduced A β levels (A β ₄₂ = 279 pg/mL), a reduced A β _{42/40} ratio (3.8%), and a normal total tau level (378 pg/mL) in CSF.

The follow-up MRI in 2017 showed a progression of cSS from focal to disseminated and twelve incident cerebral microbleeds restricted to lobar regions in the right hemisphere. Hence, a diagnosis of probable CAA according to modified Boston criteria [2] was made. All cSS-affected sulci were segmented using ITK-Snap for analysis as previously described [7]. The patient further underwent a follow-up A β PET and ¹⁸F-PI2620 tau PET [8] in 2017/2018.

Follow-up A β PET 6 years from baseline demonstrated a tremendous increase of fibrillar amyloid deposition predominantly in the contralateral left hemisphere not affected by cSS (Fig. 1a). In contrast, tau deposition was predominantly localized to the right hemisphere partly overlapping with brain regions affected by cSS. This was also reflected by plotting asymmetry of tau PET against A β PET (Fig. 1b, c) demonstrating an opposite dominance of amyloid and tau deposition. We further performed a segmental analysis of single brain regions affected by cSS (Fig. 2a) and found that amyloid deposition was not different in the vicinity of cSS compared to other compartments (Fig. 2b). In contrast, tau depositions were elevated in the vicinity of cSS-affected regions compared to non-cSS-affected brain regions (Fig. 2b).

Discussion/Conclusion

Previous literature has suggested that cSS represents a more severe stage of CAA [9] and is associated with amyloid positivity in patients with probable CAA [10]. However, to the best of our knowledge, there is no data available analyzing the distribution of cSS in association with local amyloid positivity and there is no data at all on cSS and tau pathology. Now, our

observations raise the possibility that cSS in probable CAA may be associated with a locally elevated tau pathology but not with increased fibrillar amyloid deposition measured by A β PET. However, this hypothesis needs to be proven by clinical studies including histology sampling.

Acknowledgments

¹⁸F-florbetaben and ¹⁸F-PI-2620 tracer supply was kindly supported by Life Molecular Imaging GmbH (Berlin, Germany).

Statement of Ethics

The patient gave informed written consent for amyloid and tau imaging. Approval for data analysis was obtained by the local ethics committee (IRB approval No. 19-022).

Disclosure Statement

The authors have no conflicts of interest to declare. M.B. has received speaker honoraria from GE healthcare and LMI and is an advisor of LMI. All other authors have nothing to disclose.

Author Contributions

Matthias Brendel: conception, design, MRI and PET analyses, manuscript preparation, and writing of first draft. Cihan Catak: conception, design, analyses, manuscript preparation, and writing of first draft. Leonie Beyer: data acquisition, PET analyses, review and critique, and manuscript drafting. Jennifer Linn and Hannes Wahl: review and critique, MRI analyses, and manuscript drafting. Daniel Janowitz: review and critique, and manuscript drafting. Axel Rominger, Henryk Barthel, and Osama Sabri: review and critique, PET analyses, and manuscript drafting. Peter Bartenstein: review and critique, PET analyses, and manuscript drafting. Marianne Patt: review and critique, radiochemistry, and manuscript drafting. Frank Arne Wollenweber: conception, design, manuscript preparation, and review and critique.

References

- 1 Vinters HV. Cerebral amyloid angiopathy. A critical review. *Stroke*. 1987 Mar-Apr;18(2):311–24.
- 2 Smith EE, Greenberg SM. Clinical diagnosis of cerebral amyloid angiopathy: validation of the Boston criteria. *Curr Atheroscler Rep*. 2003 Jul;5(4):260–6.
- 3 Linn J, Halpin A, Demaerel P, Ruhland J, Giese AD, Dichgans M, et al. Prevalence of superficial siderosis in patients with cerebral amyloid angiopathy. *Neurology*. 2010 Apr;74(17):1346–50.
- 4 Wollenweber FA, Zietemann V, Rominger A, Opherck C, Bayer-Karpinska A, Gschwendtner A, et al. The Determinants of Dementia After Stroke (DEDEMAS) Study: protocol and pilot data. *Int J Stroke*. 2014 Apr;9(3):387–92.
- 5 Sabri O, Sabbagh MN, Seibyl J, Barthel H, Akatsu H, Ouchi Y, et al.; Florbetaben Phase 3 Study Group. Florbetaben PET imaging to detect amyloid beta plaques in Alzheimer's disease: phase 3 study. *Alzheimers Dement*. 2015 Aug;11(8):964–74.

- 6 Petersen RC. Mild cognitive impairment as a diagnostic entity. *J Intern Med*. 2004 Sep;256(3):183–94.
- 7 Yushkevich PA, Piven J, Hazlett HC, Smith RG, Ho S, Gee JC, et al. User-guided 3D active contour segmentation of anatomical structures: significantly improved efficiency and reliability. *Neuroimage*. 2006 Jul;31(3):1116–28.
- 8 Kroth H, Oden F, Molette J, Schieferstein H, Capotosti F, Mueller A, et al. Discovery and preclinical characterization of [18F]PI-2620, a next-generation tau PET tracer for the assessment of tau pathology in Alzheimer's disease and other tauopathies. *Eur J Nucl Med Mol Imaging*. 2019 Sep;46(10):2178–89.
- 9 Wollenweber FA, Opherk C, Zedde M, Catak C, Malik R, Duering M, et al. Prognostic relevance of cortical superficial siderosis in cerebral amyloid angiopathy. *Neurology*. 2019 Feb;92(8):e792–801.
- 10 Jang H, Jang YK, Kim HJ, Werring DJ, Lee JS, Choe YS, et al. Clinical significance of amyloid β positivity in patients with probable cerebral amyloid angiopathy markers. *Eur J Nucl Med Mol Imaging*. 2019 Jun;46(6):1287–98.

Matthias Brendel and Cihan Catak contributed equally to this work as first authors

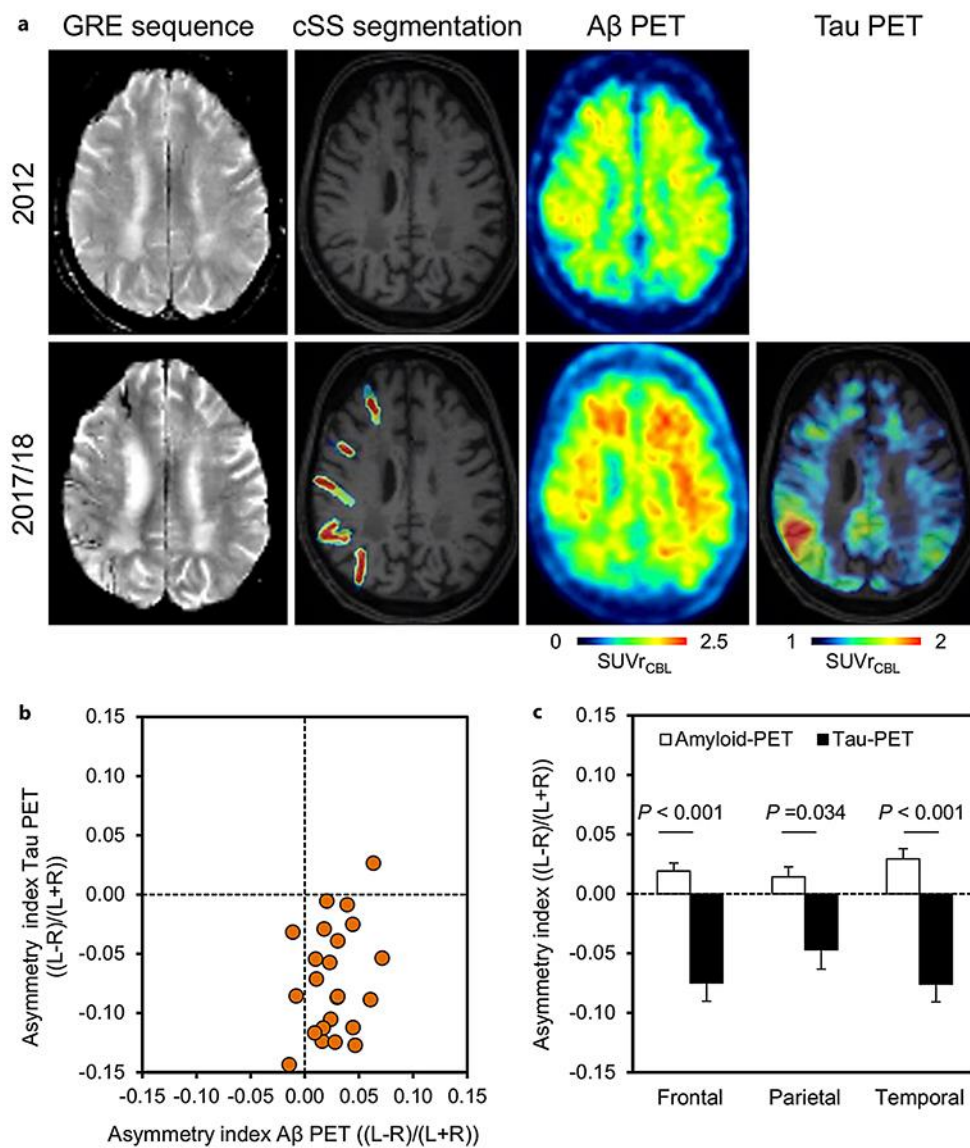


Fig. 1. Comparison of asymmetries between cSS, β -amyloid (A β) and tau. **a** Axial slices show progression of cSS and amyloid positivity between 2012 and 2017/2018 by MRI and PET imaging and tau distribution by PET in 2018. **b** Scatter plot of asymmetry in A β PET (2018) in comparison to asymmetry in tau PET for all 23 cortical regions (frontal, parietal, temporal) defined by the Hammers atlas. Asymmetry indices demonstrate predominant tau positivity in the cSS-affected right hemisphere and predominant A β positivity in the non-cSS-affected left hemisphere. **c** Statistical comparison of frontal, parietal, and temporal asymmetry indices (AI = (L-R)/(L+R)) between A β PET and tau PET. *p* values were derived from a paired Student's *t* test. ^{18}F -florbetaben A β and ^{18}F -PI-2620 tau PET were acquired from 90 to 110 min p.i. and from 30 to 60 min p.i., respectively, and each summed to a single static frame. PET values were calculated as standardized uptake value ratios with the cerebellar gray matter (CBL) as a reference region after transformation in the MNI space. cSS segmentation and tau PET images are projected onto the patient's 3D T1W sequence. PMOD 3.5 (Basel, Switzerland) was used for all image analysis operations.

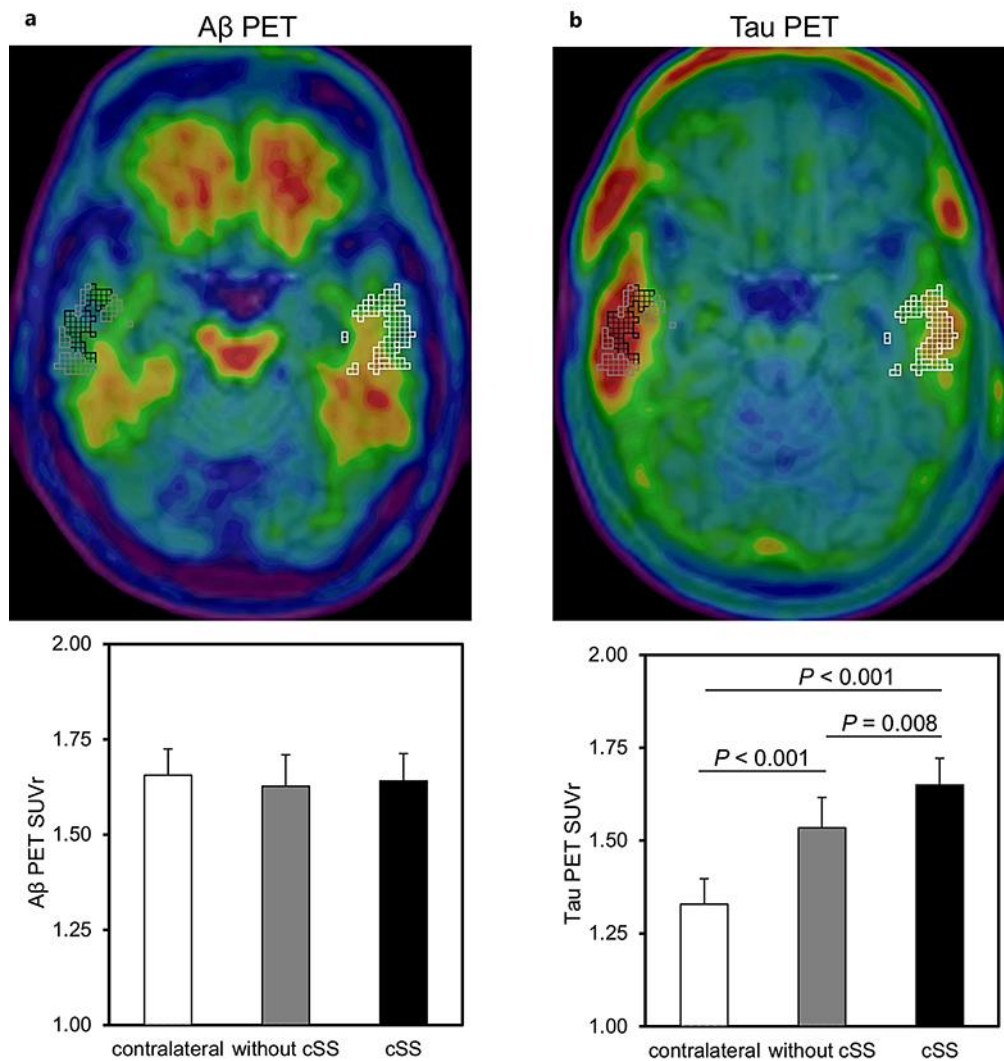


Fig. 2. Segmental analysis based on cSS. **a** Axial images illustrate delineation of a right temporal cSS area and the definition of cSS-positive (black), cSS-negative (gray), and contralateral segments (white) of the anterolateral inferior temporal lobe, illustrated in PET image data upon the patient's T1 MPRAGE MRI. **b** Comparison of PET quantification by standardized uptake value ratios (SUVr) in segmented contralateral (white), cSS-negative (gray), and cSS-positive (black) regional values for A β PET and tau PET. A total of 17 cortical regions (defined by the Hammers atlas) affected by cSS were included in the analysis. *p* values were derived from an unpaired Student's *t* test. A filter of 5.0 mm was used prior to definition of cSS-positive voxels to account for the lower PET resolution in comparison to that of MRI.