

# Development of a Vision-assisted Manometry Catheter for High-resolution Esophageal Manometry

Hee Man Kim

Department of Internal Medicine, Yonsei University Wonju College of Medicine, Wonju, Gangwon-do, Korea

High-resolution esophageal manometry is becoming a standard diagnostic method for esophageal motility disorders. High-resolution manometry catheters are inserted blindly, which sometimes results in coiling in the esophagus and failure to cross the crural diaphragm in patients with large hiatal hernias. The newly developed manometry catheter described in this report has an optical module in front of the catheter that provides forward images during insertion and prevents coiling and malplacement of the catheter. This case report describes the composition of a new manometry catheter with an optical module and shows that the new catheter functions well in both in vitro and in vivo settings. The new manometry catheter will help guide the right way and prevent coiling in the esophagus.

(J Neurogastroenterol Motil 2016;22:149-152)

## Key Words

Catheters; Esophagus; Manometry; Stomach; Vision

## Introduction

High-resolution esophageal manometry has become a standard diagnostic method for esophageal motility disorders.<sup>1</sup> The catheter used for high-resolution esophageal manometry has closely spaced pressure sensors in order to precisely measure intraluminal pressure of the esophagus and provides high-resolution results.<sup>1,2</sup> High-resolution esophageal manometry catheters are divided into two types according to the pressure measurement method: water-perfused and solid-state catheters. Usually, the esophageal manometry catheter is inserted through nose into the esophagus and proximal stomach without visual confirmation using a push method that relies on

operator experience and sense of touch. Therefore, the catheter has the potential to coil in the esophagus.<sup>3</sup> In addition, the catheter may not traverse the diaphragm in some patients with large hernias.<sup>4</sup>

To resolve these problems of the high-resolution manometry catheter, the author developed a new manometry catheter, the vision-assisted esophageal manometry catheter (Patent number: 10-2013-0162084), with an optical module that enables direct frontal visualization when inserting the catheter through the nose. Because of the visual capability, this new catheter may prevent coiling in the esophagus and malplacement during diagnostic studies. This case report is intended to introduce the new esophageal manometry catheter combined with an optical module.

Received: March 18, 2015 Revised: April 29, 2015 Accepted: May 15, 2015

© This is an Open Access article distributed under the terms of the Creative Commons Attribution Non-Commercial License (<http://creativecommons.org/licenses/by-nc/4.0>) which permits unrestricted non-commercial use, distribution, and reproduction in any medium, provided the original work is properly cited.

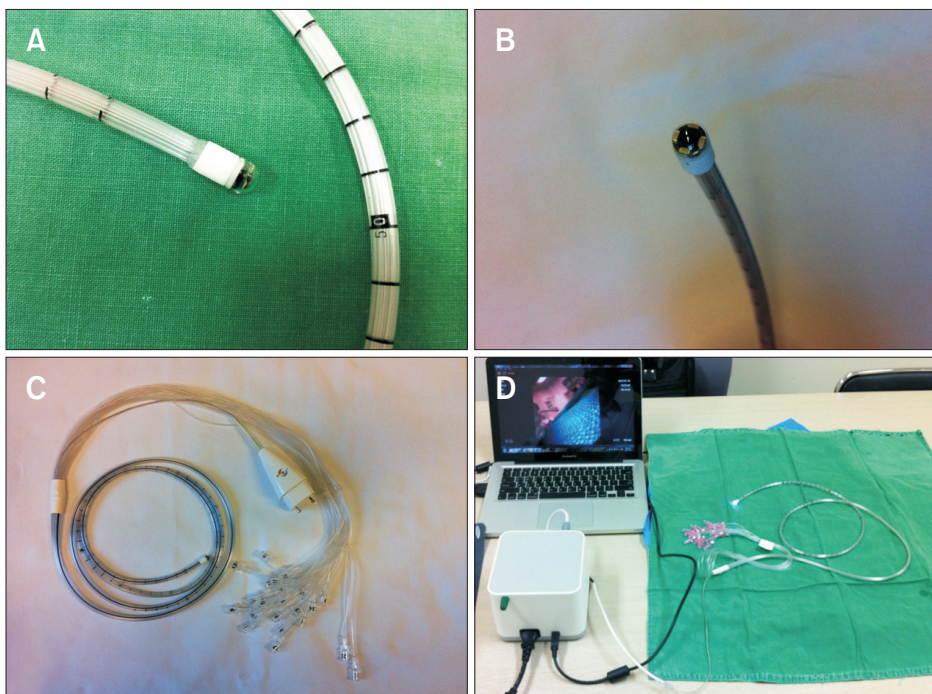
\*Correspondence: Hee Man Kim, MD, PhD

Department of Internal Medicine, Yonsei University Wonju College of Medicine, 20 Ilsan-ro, Wonju, Gangwon-do 26426, Korea  
Tel: +82-33-741-1229, Fax: +82-33-741-1228, E-mail: [loverkorea2009@gmail.com](mailto:loverkorea2009@gmail.com)

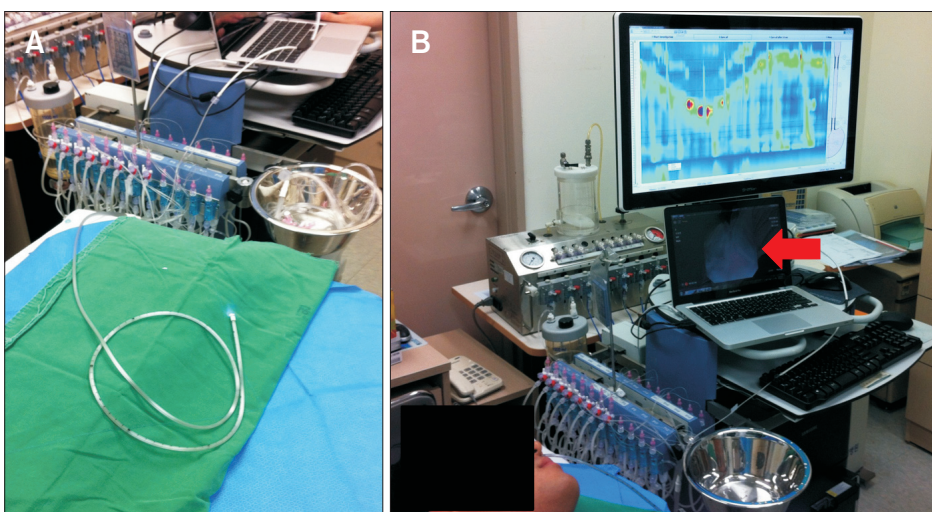
## Case Report

The new vision-assisted catheter for high-resolution esophageal manometry is composed of two parts: a water-perfused catheter and an optical module. The water-perfused catheter is a commercial product with 24 pressure channels for high-resolution esophageal manometry (MMS G-90510; Mui Scientific, Mississauga, Canada) (Fig. 1A). The optical module has the same design as the

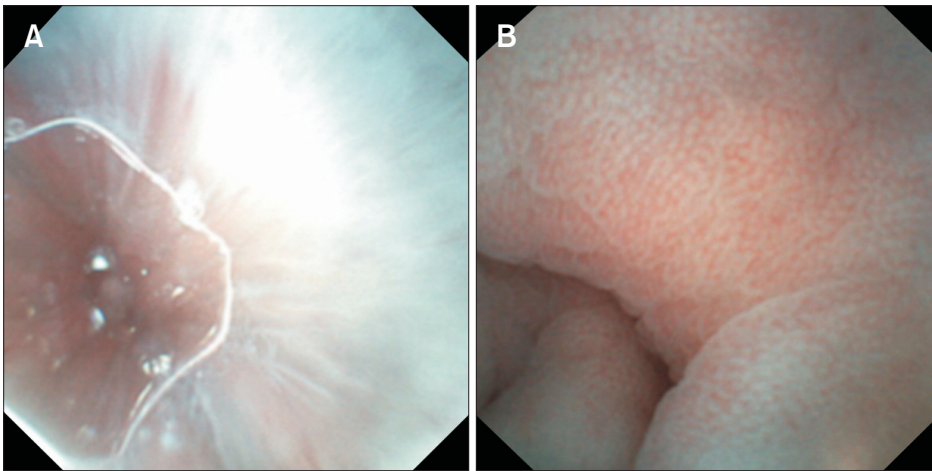
EG scan (IntroMedic, Seoul, Korea), a portable and single-use endoscope developed by Si Young Song (Yonsei University College of Medicine, Seoul, Korea) and IntroMedic Company (Fig. 1B).<sup>3</sup> The optical module is composed of a complementary metal–oxide–semiconductor (CMOS) and transfers images as electrical signals to a monitor on a laptop computer.<sup>5</sup> The optical module is fixed to the tip of the water-perfused catheter. The water-perfused catheter and optical module were combined by the IntroMedic Company engineering department. The esophageal manometry machine



**Figure 1.** Vision-assisted water-perfused manometry catheter. (A) Water-perfused catheter combined with an optical module. (B) Optical module from EG scan. (C) The combined catheter. (D) System of the vision-assisted water-perfused manometry catheter.



**Figure 2.** Vision-assisted water-perfused manometry system. (A) The combined system of high-resolution esophageal manometry and a new vision-assisted catheter. (B) In vivo test. The red arrow indicates a monitor showing images obtained from optical module.



**Figure 3.** Images from the optical module. (A) Esophagus. (B) Stomach.

model was a Solar GI HRM (MMS, Enschede, The Netherlands).

In an *in vitro* test, the Solar GI HRM and new catheter with the attached monitor worked well without mutual interaction (Fig. 2). *In vivo* testing was performed on a healthy volunteer. The new vision-assisted manometry catheter was inserted into the nose by an experienced operator. During insertion, the operator clearly viewed the lumen of the nose, nasopharynx, oropharynx, esophagus, esophagogastric junction, and stomach through the monitor connected to the optic module located on the tip of the catheter (Fig. 3). The new catheter tip was placed into stomach below the esophagogastric junction.

## Discussion

This case report introduces a newly developed catheter for high-resolution esophageal manometry that also provides images of the upper gastrointestinal tract. This report shows an early stage clinical trial to determine the clinical utility of this new catheter.

High-resolution esophageal manometry has become a standard diagnostic test for esophageal motility disorders that cannot be diagnosed with conventional manometry. However, several complications related to the esophageal manometry catheter have been reported. In a study of patients with large hiatal hernias, the manometry catheter did not pass through the crural diaphragm in 49% of patients.<sup>4</sup> Endoscopic catheter placement was used as a solution for this problem, but the success rate was less than 50%, and the manometry catheter frequently coiled in the hernia even after being guided into the distal stomach.<sup>4</sup> The coiled catheter shows a mirror image, or “butterfly,” on high-resolution esophageal manometry.<sup>3</sup> The new catheter assists the operator with safe insertion of ideal and

precise catheter placement while preventing coiling in the esophagus. The vision-assisted manometry catheter is an alternative to endoscopic placement. Also, when the vision-assisted manometry catheter coils into a hernia, it can be identified in real-time.

In addition, the optical module shows the esophageal lumen, although the image has low quality compared with that of conventional electronic upper GI endoscopy. If the patient does not undergo esophagogastroduodenoscopy (EGD), the optical module is an alternative to conventional esophagoscopy to screen for esophageal lesions such as esophageal cancer. It can also visualize contraction of specific portions of the esophagus during swallowing. Similarly, the combination of vision and manometry has been attempted previously. Kawai et al<sup>6</sup> reported that transnasal ultrathin EGD and simultaneous esophageal manometry are useful in the evaluation of esophageal peristaltic function. However, the manometry catheter used in that study was inserted through the scope and only evaluated the area in front of the scope. Therefore, the authors used it for the diagnosis of gastroesophageal reflux disease rather than evaluating esophageal motility disorders. Yuksel et al<sup>7</sup> and Ates et al<sup>8</sup> combined a new impedance catheter and conventional EGD. The impedance catheter was inserted through the scope and had the same diagnostic limitations as those in the study by Kawai et al.<sup>6</sup> Those 2 studies used conventional EGD to view the esophagus and inserted the new catheters through the scope, with neither functioning as a technique for whole esophageal manometry or impedance.<sup>6-8</sup>

The new vision-assisted catheter has several limitations. The optic module has no function for lens cleaning or air inflation, which is important for clear vision. The optic module also has low resolution (Fig. 3). These problems will be resolved in an improved product developed in the future.

In summary, this case report described a new manometry cath-

eter composed of a water-perfused catheter and an optical module. The proposed catheter can be safely inserted and exactly placed. These findings suggest that this new catheter can be used in future situations requiring visual conformation of catheter placement.

**Financial support:** None.

**Conflicts of interest:** None.

## References

---

1. Conklin JL. Evaluation of esophageal motor function with high-resolution manometry. *J Neurogastroenterol Motil* 2013;19:281-294.
2. Rohof WO, Boeckxstaens GE, Hirsch DP. High-resolution esophageal pressure topography is superior to conventional sleeve manometry for the detection of transient lower esophageal sphincter relaxations associated with a reflux event. *Neurogastroenterol Motil* 2011;23:427-432.
3. Zia J, Rubenstein JH. Image of the month: “butterfly” effect, or mirror image, caused by a coiled esophageal manometry catheter. *Am J Gastroenterol* 2013;108:1556.
4. Roman S, Kahrilas PJ, Kia L, Luger D, Soper N, Pandolfino JE. Effects of large hiatal hernias on esophageal peristalsis. *Arch Surg* 2012;147:352-357.
5. Cho JH, Kim HM, Lee S, et al. A pilot study of single-use endoscopy in screening acute gastrointestinal bleeding. *World J Gastroenterol* 2013;19:103-107.
6. Kawai T, Yamagishi T, Yagi K, et al. Impact of transnasal ultrathin esophagogastroduodenoscopy (UT-EGD) in the evaluation of esophageal peristaltic function. *J Gastroenterol Hepatol* 2008;23(suppl 2):S181-S185.
7. Yuksel ES, Higginbotham T, Slaughter JC, et al. Use of direct, endoscopic-guided measurements of mucosal impedance in diagnosis of gastroesophageal reflux disease. *Clin Gastroenterol Hepatol* 2012;10:1110-1116.
8. Ates F, Yuksel ES, Higginbotham T, et al. Mucosal impedance discriminates GERD from non-GERD conditions. *Gastroenterology* 2015;148:334-343.