

CASE REPORT

A case of mesenteric panniculitis associated with metastatic poorly differentiated cancer of unknown primary site

Chaozer Er^{1,*}, Vanessa Hwee Ting Tey², Navin Kuthiah¹ and Veeraraghavan M. Aravamudan¹

¹Department of General Medicine, Woodlands Health Campus, 2 Yishun Central 2, Singapore, and ²Ministry of Health Holdings, 1 Maritime Square, 099253, Singapore

*Correspondence address. Department of General Medicine, Woodlands Health Campus, 2 Yishun Central 2, Singapore. Tel: +65-93843993; Email: erchaozer@gmail.com

Abstract

Mesenteric panniculitis is the inflammation of intestinal mesentery. It may be associated with malignancy. We present a case of mesenteric panniculitis that manifested as unresolved fever which subsequently was found to be due to poorly differentiated metastatic carcinoma.

INTRODUCTION

Mesenteric panniculitis refers to acute or chronic and non-specific inflammation of the adipose tissue of the intestinal mesentery [1]. It is a rare condition that is usually suspected based on typical computed tomography (CT) scan findings [1]. Its presence has been associated with a higher incidence of malignancy. Here, we describe a case of mesenteric panniculitis associated with metastatic poorly differentiated cancer of unknown primary site.

CASE PRESENTATION

A 64-year-old Eurasian gentleman with past medical history of chronic obstructive pulmonary disease (COPD), diabetes mellitus (DM), benign prostatic hyperplasia (BPH), delusional disorder and dementia presented to us with four days of diarrhoea and fever. His physical examination was unremarkable. Haemodynamic status was stable upon presentation.

Initial investigation (Table 1) revealed microcytic anaemia: haemoglobin 4.5 g/dl (13.6–16.6 g/dl), mean corpuscular volume 82 fL (86.7–102.3 fL), hyponatraemia: sodium 127 mmol/l (135–145 mmol/l), deranged liver enzymes: alkaline phosphatase 297 U/l (45–122 U/l), gamma glutamyl transpeptidase 116 U/l (11–50 U/l), high C-reactive protein: CRP 211.3 mg/l (1–5 mg/l) and right apical scarring on chest X-ray.

Empirical antibiotic ceftriaxone and metronidazole were initiated to treat as bacterial gastroenteritis. Packed cell transfusion and intravenous hydration were also given. Iron panel was checked (Table 1): ferritin 1079 ng/ml, iron saturation 9% (15–50%). This was more in keeping with inflammation rather than absolute iron deficiency. Peripheral blood smear showed microcytic, hypochromic red blood cells with anisocytosis. No haemolysis was seen. His haemoglobin (Hb) remained stable at the range of 8–9 g/dL after 2 units of packed cell transfusion. Gastroenterologist was consulted and outpatient gastrointestinal scopes were arranged.

Received: December 28, 2018. Revised: February 22, 2019. Accepted: March 2, 2019

© The Author(s) 2019. Published by Oxford University Press.

This is an Open Access article distributed under the terms of the Creative Commons Attribution Non-Commercial License (<http://creativecommons.org/licenses/by-nc/4.0/>), which permits non-commercial re-use, distribution, and reproduction in any medium, provided the original work is properly cited. For commercial re-use, please contact journals.permissions@oup.com

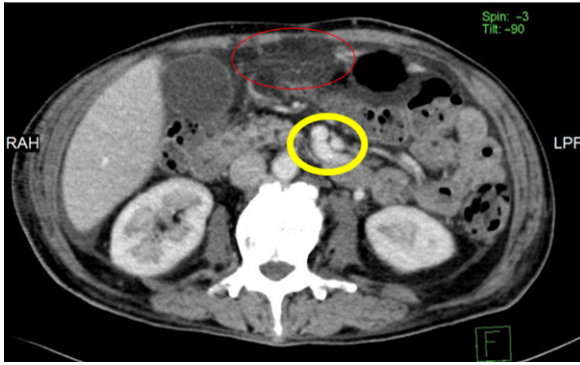


Figure 1: Axial CT image from upper abdomen showing stranding in the omentum (red circle) and in central mesentery (yellow circle).

The blood culture subsequently was reported as negative. He remained febrile after 3 days of antibiotic despite the diarrhoea has resolved. Urinalysis was unremarkable. Computed tomography of abdomen and pelvis (CTAP) was done to investigate the persistent fever. It showed mesenteric fat stranding which may represent mesenteric panniculitis (Fig. 1). No other foci of infection was evident. Computed tomography pulmonary angiogram (CTPA) showed some emphysematous changes but no pulmonary embolism. HIV and viral hepatitis serology were negative. A bone marrow examination was then performed. The marrow aspirate showed mildly hypocellular marrow fragments with quantitatively adequate and normal haemopoiesis. There was increased number of plasma cells (~6%). No other abnormal cellular infiltrate or intra-medullary micro-organisms was seen. A myeloma panel was sent.

Infectious disease consult was made at this point of time. In view of anaemia, diarrhoea, deranged liver enzymes and unexplained fever, anti-tuberculosis treatment consisted of isoniazid, rifampicin, pyrazinamide and ethambutol was initiated as empirical treatment of tuberculosis (TB) of gut and liver. The inflammatory markers and fever did not improve after 1 week of TB treatment. The bone marrow trephine biopsy report was out at this point of time. It was reported as metastatic poorly differentiated carcinoma. Myeloma panel that was sent earlier turned out negative. Tumour markers including prostate specific antigen and alpha fetoprotein were not raised. Carcinoembryonic antigen (CEA) was mildly raised (Table 1). As CEA is associated with lung and thyroid cancers, a computed tomography (CT) of neck and chest was done. It showed hepatic heterogeneity with multiple ill-defined hypodense areas, left adrenal nodule suspicious of metastasis and new small perihepatic ascites and omental nodular fat stranding.

Our patient had poor understanding of his condition due to his dementia. The only next of kin was his partner. After discussing with the oncologist, palliative team and patient's partner, goal of care was decided to be palliative and best supportive care. Patient was transferred to a hospice. He passed away 2 months after admission.

DISCUSSION

Mesenteric panniculitis's pathogenesis is unclear [2]. Postulated mechanisms include previous abdominal surgery, trauma, infection, ischaemia, autoimmune process, malignancy, obesity and type 2 diabetes mellitus [1, 2, 3]. Its prevalence is 0.16–2.5% of patients undergoing abdominal computed tomography (CT) for

Table 1: Showing relevant investigation

Investigation	Result	Reference
White blood cell (WBC)	$9.36 \times 10^9/l$	3.37–8.38
Haemoglobin	4.5 g/dl	13.3–16.6
Platelet	$498 \times 10^9/l$	172–378
Sodium	127 mmol/l	135–145
Potassium	4 mmol/l	3.5–5
Creatinine	55 umol/l	59–104
Urea	2.9 mmol/l	2.8–7.6
Albumin	34 g/l	35–50
Globulin	49 g/l	23–39
Bilirubin	16 umol/l	3–21
Alanine aminotransferase (ALT)	30 U/l	10–44
Aspartate aminotransferase (AST)	30 U/l	10–44
Alkaline phosphatase (ALP)	297 U/l	45–122
Gamma glutamyl transpeptidase (GGT)	116 U/l	11–50
C reactive protein (CRP)	211 mg/l	1–5
Erythrocyte sedimentation rate (ESR)	>120 mm/hr	1–16
Folate	16 nmol/l	7–37
Vitamin B12	855 pmol/l	145–569
Ferritin	1079 ng/ml	20–300
Transferrin saturation	9%	15–50%
Transferrin	102 mg/dl	200–360
Prostate specific antigen (PSA)	1.97 ug/l	0–4
Carbohydrate Ag 19-9	1.2 U/ml	<34
Alpha faetoprotein (AFP)	1.8 ug/l	0–7
Carcinoembryonic antigen (CEA)	10.8 ug/l	0–4.6
Peripheral blood smear	Majority of the erythrocytes are slightly microcytic and slightly hypochromic with slight anisocytosis. WBCs are normal in number with no immature WBCs seen. No abnormal cells seen. No toxic granulation. Platelets are slightly increased in number.	
HIV serology	Negative	
Hepatitis C antibody	Negative	
Hepatitis B surface antigen	Negative	
Blood culture	No growth	
Urine culture	No growth	
Bone marrow aspirate tuberculosis culture	No growth	

Continued

Table 1: Continued

Investigation	Result	Reference
Bone marrow aspirate mycobacterium PCR	Negative	
Bone marrow aspirate acid fast bacilli stain	Negative	
Chest X- ray	Mild scarring of the right apex is noted. No focus of consolidation is noted. No pleural effusion is present. The cardiac size is normal.	
CT Abdomen/pelvis	Diffuse mild mesenteric fat stranding may represent underlying panniculitis. Changes of small airway disease in the imaged lungs. Bilateral small pleural effusions.	
CT pulmonary angiogram	No acute pulmonary thromboembolism as per concern. Emphysematous changes noted in bilateral upper lobes as mentioned. Small bilateral pleural effusions with lower lobe atelectatic changes.	
CT of neck and thorax	Emphysema and bilateral pleural effusions. Minimal nodularity in the right pleural effusion is nonspecific. A few tiny pulmonary nodules. Left adrenal nodule is suspicious for metastasis. There is heterogeneity of the liver with multiple ill-defined hypodense areas. New small perihepatic ascites and omental nodular fat stranding.	
Bone marrow aspirate	Mildly hypocellular marrow fragments (for patient's age). Erythropoiesis is quantitatively adequate and shows normal maturation. Granulopoiesis is quantitatively adequate and shows normal maturation. Megakaryopoiesis is quantitatively adequate and shows essentially normal maturation (occasional hypolobulated megakaryocytes seen). There is some increase in the number of plasma cells (~6%), with a few showing irregular cytoplasm and occasional bi-/tri-nucleated forms seen. No other abnormal cellular infiltrate or any intra-medullary micro-organisms seen in this aspirate.	

Continued

Table 1: Continued

Investigation	Result	Reference
Bone marrow trephine histology	Iron stores are increased (4/6); no ring sideroblasts seen. The histological features are in keeping with metastatic carcinoma, poorly differentiated. The bone marrow trephine shows a focus of tumour cells arranged in solid sheets. The tumour cells exhibit hyperchromatic and pleomorphic nuclei, and moderate amount of amphophilic cytoplasm. Neither glandular nor squamous differentiation is seen. Scattered plasma cells are found in the surrounding tissue. Immunohistochemical study shows that the tumour cells are diffusely positive for cytokeratin (AE1/3), but negative for cytokeratin 5/6, cytokeratin 7, cytokeratin 20, prostatic specific antigen, prostatic specific acid phosphatase and thyroid transcription factor-1. Immunohistochemical staining for CD138 highlights the scattered plasma cells which show polytypic light chain.	
Bone marrow aspirate cytogenetic	Normal	
Myeloma panel	No paraprotein detected	

various reasons [3]. Definitive diagnosis requires histological examination [2–4]. Most affected patients are Caucasian males in the fifth to seventh decades of life [5].

Common presentations are abdominal pain, abdominal distension, fever, malaise, weight loss, constipation, diarrhoea, nausea and vomiting [1, 2]. 10% of patients are asymptomatic [5]. The condition is often found incidentally on a CT scan of the abdomen that is done for other purposes [3].

Complications of the disease, such as bowel obstruction, chylous ascites and mesenteric arterial or venous ischaemia [2] can occur. Fatalities due to complications of bowel obstruction have been reported, but it is largely thought to be a benign disease [5].

In terms of laboratory tests, ESR, CRP may be raised, and there may be anaemia, leukocytosis, and hypoalbuminemia [1, 2]. CT scan findings can be highly suggestive [1]. Typical radiological characteristics include the fat halo sign and pseudocapsule [5]. However, definitive diagnosis requires histological examination [2–4] to rule out differentials such as lymphoma, mesenteric carcinomatosis, carcinoid tumour, mesenteric fibromatosis, and mesenteric oedema [5].

There are no well-established trials regarding treatment of this rare condition [4, 5]. Thus, treatment is mainly for symptom

relief and to address any complications. Commonly used agents include steroids and other immunosuppressants [4]. One study found that symptomatic patients with idiopathic mesenteric panniculitis responded to treatment with antibiotics and non-steroidal anti-inflammatory drugs (NSAIDs) [3]. Patients with obstructive or compressive symptoms may require surgery [4].

Our patient's demographics, clinical presentation, laboratory and radiological findings were consistent with what is known about mesenteric panniculitis. What is interesting is that he concomitantly had metastatic malignancy of unknown primary.

Studies have shown that mesenteric panniculitis is associated with a higher incidence of concomitant malignancy [6, 7]. One retrospective study of 4758 patients with 90 identified cases of mesenteric panniculitis found that the likelihood of associated malignancy (mostly intra-abdominal malignancy) was 2.1 times higher in patients with mesenteric panniculitis [6]. Another retrospective study of 5595 cases with 143 identified cases of mesenteric panniculitis found that the risk of malignancy (especially non-Hodgkin lymphoma) was five times higher in patients with mesenteric panniculitis [7].

Larger and prospective studies are needed to establish if and how mesenteric panniculitis is related to malignancy temporally and pathogenically, as this would have implications for asymptomatic patients in whom mesenteric panniculitis is incidentally discovered.

ACKNOWLEDGEMENTS

None.

CONFLICT OF INTEREST STATEMENT

None.

FUNDING

None.

ETHICAL APPROVAL

Not required.

CONSENT

Patient's consent has been obtained.

GUARANTOR

Chaozer Er.

REFERENCES

1. Irwin CP, Lee JB, Kim A, Eme I, Schofield C, Mount G, et al. Mesenteric panniculitis presenting as fever of unknown etiology in a patient with history of abdominal surgery. *Case Rep Gastrointest Med* 2018;3. Article ID 5658039.
2. Kobayashi H, Notohara K, Otsuka T, Kobayashi Y, Ujita M, Yoshioka Y, et al. An autopsy case of mesenteric panniculitis with massive pleural effusions. *Am J Case Rep* 2018;13-20.
3. Sahina A, Artasb H, Eroglu Y, Tunc N, Demirel U, Bahcecioglu IH, et al. An Overlooked potentially treatable disorder: idiopathic mesenteric panniculitis. *Med Princ Pract* 2017;567-72.
4. Kgomomo M, Elnagar A, Mashoshoe K. Mesenteric panniculitis. *BMJ Case Rep* 2017. doi:10.1136/bcr-2017-220910.
5. Gomes DC, Quaresma L. Sclerosing mesenteritis: a benign cause of mesenteric mass lesions. *Pan Afr Med J* 2017;27:228. <http://doi.org/10.11604/pamj.2017.27.228.11542>.
6. Mahafza WS, Manzalawi KA, Gharaibeh AA. Diagnosis of mesenteric panniculitis in the multi-detector computed tomography era. Association with malignancy and surgical history. *Saudi Med J* 2017;38:1013-8. doi:10.15537/smj.2017.10.20163.
7. Scheer F, Spunar P, Wiggermann P, Wissgott C, Andresen R. Mesenteric panniculitis (MP) in CT—a predictor of malignancy? *Fortschr Röntgenstr* 2016;188:926-32.