



# The Brazilian Journal of INFECTIOUS DISEASES

[www.elsevier.com/locate/bjid](http://www.elsevier.com/locate/bjid)



## Clinical image

### Orf disease: a report of a case



Theocharis Koufakis<sup>a,\*</sup>, Periklis Katsaitis<sup>b</sup>, Ioannis Gabranis<sup>a</sup>

<sup>a</sup> Department of Internal Medicine, General Hospital of Larissa, Larissa, Greece

<sup>b</sup> Department of Dermatology, General Hospital of Larissa, Larissa, Greece

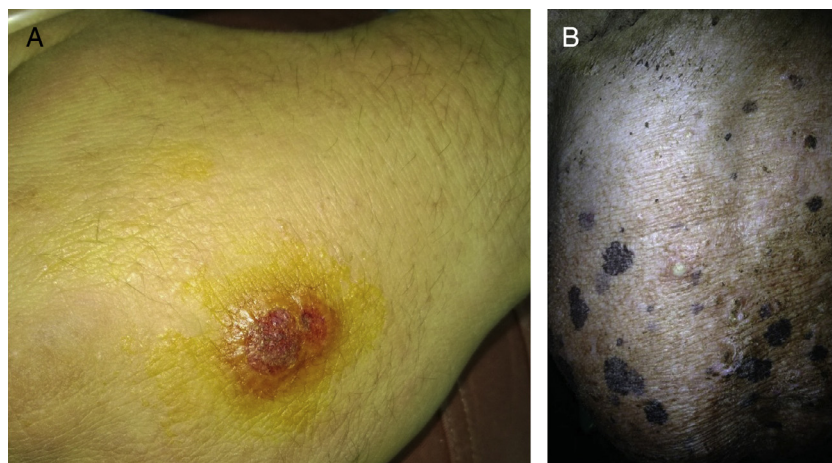
#### ARTICLE INFO

##### Article history:

Received 27 March 2014

Accepted 1 April 2014

Available online 14 May 2014



**Fig. 1 – (A) Orf lesions located at the patient's hand and (B) at the breasts of his sheep.**

A 19 year-old Caucasian male shepherd, with no relevant medical history, presented to the Emergency Department of our hospital complaining about a necrotic lesion at the dorsal surface of his left hand (Fig. 1A). He mentioned that he had noticed similar lesions located at the lips and the breasts of

his sheep (Fig. 1B). The diagnosis of Orf disease was clinically established, based on the typical presentation and the positive history of exposure. No special treatment was given to the patient, apart from local antiseptics, resulting in complete regression of the lesions within a month period. He

\* Corresponding author.

E-mail address: [thkoyfak@hotmail.com](mailto:thkoyfak@hotmail.com) (T. Koufakis).

<http://dx.doi.org/10.1016/j.bjid.2014.04.001>

1413-8670/© 2014 Elsevier Editora Ltda. Este é um artigo Open Access sob a licença de [CC BY-NC-ND](http://creativecommons.org/licenses/by-nc-nd/4.0/)

was strongly advised to wear gloves when handling his animals and practice proper hand hygiene. Orf (or Contagious Ecthyma) is a zoonotic disease, caused by a parapoxvirus and mainly affects sheep and goats,<sup>1</sup> but it can be transmitted to humans through direct contact with infected animals.<sup>2</sup> It is generally considered as a self-limited clinical entity. However, successful treatment of complicated cases with topical use of imiquimod<sup>3</sup> or cidofovir cream<sup>4</sup> has been described in the literature.

---

### Conflicts of interest

The authors declare no conflicts of interest.

### REFERENCES

---

1. Paiba GA, Thomas DR, Morgan KL, et al. Orf (contagious pustular dermatitis) in farmworkers: prevalence and risk factors in three areas of England. *Vet Rec.* 1999;145:7-11.
2. Groves RW, Wilson-Jones E, MacDonald DM. Human orf and milkers' nodule: a clinicopathologic study. *J Am Acad Dermatol.* 1991;25:706-11.
3. Erbagci Z, Erbagci I, Almila Tuncel A. Rapid improvement of human orf (ecthyma contagiosum) with topical imiquimod cream: report of four complicated cases. *J Dermatolog Treat.* 2005;16:353-6.
4. Geerinck K, Lukito G, Snoeck R, et al. A case of human orf in an immunocompromised patient treated successfully with cidofovir cream. *J Med Virol.* 2001;64:543-9.