

## CASE REPORT

### A case of lymphoproliferative disorder of NK-cells: aggressive immunophenotype but indolent behavior

Min Shi<sup>1</sup>, Natasha M. Savage<sup>2</sup>, Huda Salman<sup>3</sup> & William G. Morice<sup>1</sup>

<sup>1</sup>Division of Hematopathology, Department of Laboratory Medicine and Pathology, Mayo Clinic, 200 First Street SW, Rochester, Minnesota 55905

<sup>2</sup>Department of Pathology, Georgia Regents University, 1120 15th Street, Augusta, Georgia 30912

<sup>3</sup>Division of Hematology/Oncology, Department of Medicine, Georgia Regents University, 1120 15th Street, Augusta, Georgia 30912

#### Correspondence

Min Shi, Division of Hematopathology, Department of Laboratory Medicine and Pathology, Mayo Clinic, 200 First Street SW, Rochester, MN 55905. Tel: +507 284 9677; Fax: +507 284 5115; E-mail: Shi.Min@mayo.edu

#### Funding Information

No sources of funding were declared for this study.

Received: 1 May 2015; Revised: 31 May 2015; Accepted: 24 June 2015

*Clinical Case Reports* 2015; 3(9): 740–743

doi: 10.1002/ccr3.333

## Introduction

Among the rare group of natural killer-cell (NK-cell) malignancies, there are two which primarily involve the peripheral blood and bone marrow: aggressive NK-cell leukemia (ANKL) and chronic lymphoproliferative disorder of NK-cells (CLPDNK). ANKL is an EBV-associated tumor most prevalent among Asian young adults (median age of 42 years) [1]. It has a fulminant clinical course, presenting with fever and hepatosplenomegaly, complicated by multiple organ failure, coagulopathy and hemophagocytic syndrome, and frequently resulting in death within 2 months. In contrast, CLPDNK has no demonstrable association with EBV or racial predilection and tends to occur in older adults (median age of 60 years) [2]. Clinically, CLPDNK is similar to T-cell large granular lymphocytic leukemia with most patients incidentally found to have cytopenia(s) and/or a persistent increase in circulating mature NK-cells [3]. The clinical course is typically indolent.

Given the stark contrast in the clinical course and management of ANKL and CLPDNK, accurately discriminat-

#### Key Clinical Message

Distinguishing chronic lymphoproliferative disorder of NK-cells from aggressive NK-cell leukemia is critical because they have distinct clinical course and management. Immunophenotyping plays a key role in distinguishing these two entities, however, it could not be used as sole criteria and clinical/laboratory findings are equally important.

#### Keywords

Aggressive NK-cell leukemia, chronic lymphoproliferative disorder of NK-cells, clinical course, immunophenotype.

ing between these two entities is very important. Morphologically, the tumor cells from both diseases can be similar and indistinguishable from their normal counterpart large granular lymphocytes. Immunophenotypically, although they are cell surface CD3 (sCD3)-negative and CD2-positive, the published data regarding these rare entities suggest that they can be very different in other surface antigen expression. ANKL is thought to usually exhibit a CD56+/CD16-/CD57- phenotype [1, 4–6], whereas CLPDNK shows a CD56-/CD16+/CD57+ phenotype [7, 8]. Here, we report an unusual case of NK-cell neoplasm having an immunophenotype similar to that associated with ANKL but with clinical and laboratory features typical of the much more indolent CLPDNK.

## Case Report

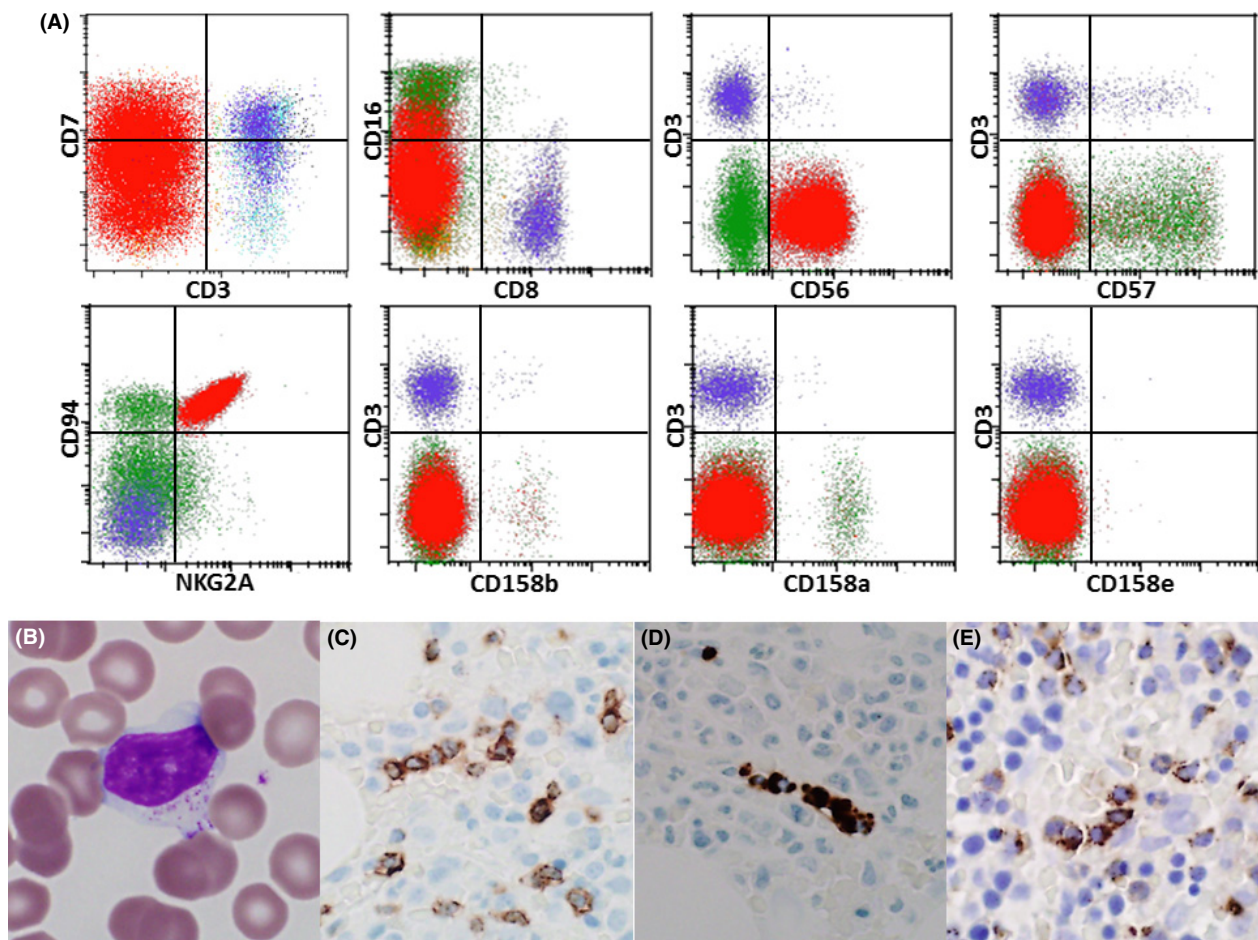
The patient is a 65-year-old Caucasian male with a 16-year history of leukopenia and neutropenia with his white blood count (WBC) varying from  $1.8 \times 10^9/L$  to  $3.5 \times 10^9/L$  and his absolute neutrophil count (ANC) ranging  $0.5 \times 10^9/L$  to  $0.7 \times 10^9/L$ . He was completely

asymptomatic, denying fevers, night sweats, or unexplained weight loss and had no documented history of neutropenic infection. At the time of his follow-up, the WBC was  $2.7 \times 10^9/L$  with neutrophils  $0.6 \times 10^9/L$  and lymphocytes  $2.1 \times 10^9/L$ , hemoglobin 9.7 g/dL and platelets  $127 \times 10^9/L$ . Ultrasound revealed an enlarged spleen ( $16.2 \times 15.8 \times 9.0$  cm) without focal masses. No hepatomegaly or lymphadenopathy was found. The patient had not received therapy for this condition.

## Pathologic Findings

The peripheral blood smear showed an increase in granular lymphocytes with bland nuclei and abundant pale-staining cytoplasm containing fine to coarse azurophilic

granules (Fig. 1B). No nuclear atypia, such as enlargement, folding, or open chromatin, was noted. Peripheral blood flow cytometric immunophenotyping revealed significantly increased NK-cells (84% of gated lymphoid events and 66% of total analyzed events) that were CD2-positive, sCD3-negative, and CD5-negative, with abnormally diminished CD7 expression (Fig. 1A). They were doubly negative for CD4 and CD8 (Fig. 1A). The neoplastic cells were CD56-positive, displayed aberrantly diminished CD16, and lacked CD57 expression (Fig. 1A). Further, they exhibited aberrantly uniform expression of CD94 and NKG2A, and a complete absence of expression of the killer cell immunoglobulin-like receptors (KIRs), CD158a, CD158b, and CD158e (Fig. 1A). Hematoxylin and eosin-stained bone marrow biopsy showed a slight



**Figure 1.** Immunophenotypic, morphologic, and immunohistochemical features of the case. (A) Immunophenotyping by flow cytometric analysis on peripheral blood showed a distinct population of surface CD3-negative NK-cells (in red) with partial loss of CD7. They were positive for CD56, and negative for CD8, CD16, and CD57. They had uniform strong expression of CD94 and NKG2A and they completely lost the expression of KIRs, such as CD158a, CD158b, and CD158e. (B) Wright-Giemsa-stained peripheral blood smear showed a population of lymphocytes with intermediate-sized reticulated chromatin and azurophilic granules in abundant amounts of pale cytoplasm (original magnification  $\times 1000$ ). (C–E) Immunohistochemical studies on the bone marrow biopsy revealed a linear (or intrasinusoidal/intravascular) distributed neoplasm cells that were positive for CD3 (C), Granzyme B (D) and TIA-1 (E).

increase in interstitial lymphocytes (10–15% of cellularity) which by immunohistochemical studies were positive for CD3 (Fig. 1C), granzyme B (Fig. 1D) and TIA-1 (Fig. 1E) and distributed in an interstitial as well as an intrasinusoidal pattern. In situ hybridization for EBV-encoded RNA (EBER) was negative and no clonal T-cell receptor gene rearrangements were detected by peripheral blood PCR studies. Cytogenetic studies revealed a normal male karyotype. In conjunction with clinical and pathological features, a diagnosis of “chronic lymphoproliferative disorder of NK cells” was rendered.

## Discussion

The diagnosis of NK-cell leukemia is challenging for practicing pathologists because NK-cells lack a singular lineage defining antigen and are phenotypically similar to normal cytotoxic T-cells. For this reason, flow cytometric immunophenotyping is a primary laboratory tool for this purpose as it allows for the accurate identification of NK-cells through combined assessment of antigens which are expressed by these cells such as CD2, CD7, CD16, and CD56, and antigens which are not expressed such as sCD3 and CD5. Furthermore, flow cytometry is also critically important for determining if the NK-cells are leukemic as making this determination rests solely on the detection of phenotypic aberrancy, as NK-cells, by definition, do not harbor uniquely rearranged antigen receptor genes to serve as a marker of clonal cellular expansion.

The power of flow cytometry to detect and define NK-cell phenotypic aberrancy has been greatly enhanced by the analysis of a group of NK-cell receptors including the

KIR antigens CD158a, CD158b, and CD158e and also CD94/NKG2A heterodimers. The utility of these assays in identifying NK-cell leukemia has been most extensively studied in CLPDNK, where distinction of the leukemic NK-cells from normal NK-cell expansion is problematic due to the indolent nature of the condition. The published literature indicates that CLPDNK is typically brightly CD16-positive and CD57-positive (majority of cases), a subset having diminished or absent expression of CD56 [7–10]. Abnormal uniform expression of a single KIR antigen, or abnormal absence of all KIR antigens, is seen in essentially all CLPDNK cases, and over one-half have abnormally uniform expression of CD94/NKG2A heterodimers [8, 10, 11]. Although these features are included in the WHO description of this provisional entity [12], there are few large studies with complete clinical phenotyping and therefore these observations are based on collectively, fewer than 200 published cases.

Aggressive NK-cell leukemia is believed to have a phenotype distinct from that of CLPDNK. Much of the previous data regarding the phenotype of ANKL are generated from immunohistochemical studies, which limits their utility in regards to comparison to flow cytometry [6]. Recently, comprehensive flow cytometric immunophenotyping studies for ANKL from a Japanese group of 22 cases [1], European group of 12 cases [4], and a Chinese group of 29 cases [5] revealed that all cases have bright CD56 expression and lack CD57 expression. The vast majority of cases do not express CD16 or CD8 [4–6], although some cases are CD16 positive [1]. However, our understanding of the disease phenotype is only based on a very small number of published cases.

**Table 1.** Clinical and pathological features of the present case, ANKCL, and CLPD-NK.

	ANKCL	Present case	CLPD-NK
Clinical characteristics			
Ethnic Predilection	Asian	Caucasian	None
Median age	42	59	60
Clinical course	Extremely aggressive	Indolent	Indolent
Hepatomegaly	Present	Absent	Absent
Splenomegaly	Present	Present	Variably Present
Peripheral blood cytology	Varies from unremarkable granular lymphocytes to cytologically malignant	Unremarkable granular lymphocytes	Unremarkable granular lymphocytes
Immunophenotype			
sCD3	–	–	–
CD8	–	–	–/+
CD16	–	–	+
CD56	+	+	–
CD57	–	–	+
KIR expression	Yes/No	No	Approximately 50% of cases
Bone marrow histology	Diffuse or subtle interstitial and intrasinusoidal infiltrate	Subtle interstitial and intrasinusoidal infiltrate	Often subtle interstitial and intrasinusoidal infiltrate
EBV-positive	Yes	No	No

Although CLDPNK and ANKL have dramatically different clinical manifestations, the paucity of data regarding the specificity of the disease phenotypes can be problematic from the laboratory standpoint, particularly in the reference laboratory setting where there may be little or no clinical information provided. Because of this, it can be difficult to render a definitive pathologic diagnosis which guides the clinical management of the case. This is illustrated by this case presented here as the leukemic NK-cells had a CD56+/CD16-/CD57-, immunophenotype putatively of ANKL. Nevertheless, the clinical, morphologic and pathogenetic (EBV status) were those of CLDPNK (Table 1), treatment of which depends on the severity of clinical symptoms and cytopenias. ANKL is highly associated with EBV infection, and thus absence of EBV should make one question the diagnosis. Given the indolent behavior and negative EBV infection, the diagnosis of chronic lymphoproliferative disorder of NK-cells was favored, despite the “aggressive” immunophenotype. Whether this will eventually evolve into an aggressive form is uncertain and long clinical follow-up is warranted. Immunophenotyping plays a key role in distinguishing ANKL from CLDPNK, however, it could not be used as sole criteria and clinical/laboratory findings are equally important.

## Conflict of Interest

None declared.

## References

- Suzuki, R., J. Suzumiya, S. Nakamura, S. Aoki, A. Notoya, S. Ozaki, et al. 2004. Aggressive natural killer-cell leukemia revisited: large granular lymphocyte leukemia of cytotoxic NK cells. *Leukemia* 18:763–770.
- Pandolfi, F., T. P. Jr Loughran, G. Starkebaum, T. Chisesi, T. Barbui, W. C. Chan, et al. 1990. Clinical course and prognosis of the lymphoproliferative disease of granular lymphocytes. A multicenter study. *Cancer* 65:341–348.
- Pouillot, E., R. Zambello, F. Leblanc, B. Barea, E. De March, M. Roussel, et al. 2014. Chronic natural killer lymphoproliferative disorders: characteristics of an international cohort of 70 patients. *Ann. Oncol.* 25: 2030–2035.
- Lima, M., A. Spinola, S. Fonseca, A. H. Santos, J. Rodrigues, L. Oliveira, et al. 2014. Aggressive mature natural killer cell neoplasms: report on a series of 12 European patients with emphasis on flow cytometry based immunophenotype and DNA content of neoplastic natural killer cells. *Leuk. Lymphoma* 56:103–112.
- Li, C., Y. Tian, J. Wang, L. Zhu, L. Huang, N. Wang, et al. 2014. Abnormal immunophenotype provides a key diagnostic marker: a report of 29 cases of de novo aggressive natural killer cell leukemia. *Transl. Res.* 163:565–577.
- Chan, J. K., V. C. Sin, K. F. Wong, C. S. Ng, W. Y. Tsang, C. H. Chan, et al. 1997. Nonnasal lymphoma expressing the natural killer cell marker CD56: a clinicopathologic study of 49 cases of an uncommon aggressive neoplasm. *Blood* 89:4501–4513.
- Morice, W. G. 2007. The immunophenotypic attributes of NK cells and NK-cell lineage lymphoproliferative disorders. *Am. J. Clin. Pathol.* 127:881–886.
- Morice, W. G., D. Jevremovic, H. Olteanu, A. Roden, G. Nowakowski, S. Kroft, et al. 2010. Chronic lymphoproliferative disorder of natural killer cells: a distinct entity with subtypes correlating with normal natural killer cell subsets. *Leukemia* 24:881–884.
- Jiang, N. G., Y. M. Jin, Q. Niu, T. T. Zeng, J. Su, H. L. Zhu. 2013. Flow cytometric immunophenotyping is of great value to diagnosis of natural killer cell neoplasms involving bone marrow and peripheral blood. *Ann. Hematol.* 92:89–96.
- Zambello, R., M. Falco, M. Della Chiesa, L. Trentin, D. Carollo, R. Castriconi, et al. 2003. Expression and function of KIR and natural cytotoxicity receptors in NK-type lymphoproliferative diseases of granular lymphocytes. *Blood* 102:1797–1805.
- Morice, W. G., P. J. Kurtin, P. J. Leibson, A. Tefferi, and C. A. Hanson. 2003. Demonstration of aberrant T-cell and natural killer-cell antigen expression in all cases of granular lymphocytic leukaemia. *Br. J. Haematol.* 120:1026–1036.
- Villamor, N. M. W. G., W. C. Chan, K. Foucar. 2008. Chronic lymphoproliferative disorders of NK cells. Pp. 274–275 in S. H. Swerdlow, E. Campo, N. L. Harris, E. J. Jaffe, S. A. Pileri, H. Stein, et al., eds. WHO classification of tumours of haematopoietic and lymphoid tissues. IARC, Lyon.