



**CASE REPORT**

# An association with hypopituitarism and 9q subtelomere deletion syndrome

Shinji Higuchi<sup>1</sup> | Masaki Takagi<sup>2,3</sup>  | Ryojun Takeda<sup>4</sup>  | Hiroshi Yoshihashi<sup>4</sup> | Satoshi Narumi<sup>2,5</sup> | Tomonobu Hasegawa<sup>2</sup>

<sup>1</sup>Department of Pediatric Endocrinology and Metabolism, Children's Medical Center, Osaka City General Hospital, Osaka, Japan

<sup>2</sup>Department of Pediatrics, Keio University School of Medicine, Tokyo, Japan

<sup>3</sup>Kojima Child Clinic, Tokyo, Japan

<sup>4</sup>Department of Medical Genetics, Tokyo Metropolitan Children's Medical Center, Tokyo, Japan

<sup>5</sup>Department of Molecular Endocrinology, National Research Institute for Child Health and Development, Tokyo, Japan

**Correspondence**

Tomonobu Hasegawa, Department of Pediatrics, Keio University School of Medicine, 35 Shinanomachi, Shinjuku-ku, Tokyo, Japan.

Email: thaseg@a6.keio.jp

**Funding information**

This study received grants from Japan Society for the Promotion of Science (Number: 16K10007); Takeda Science Foundation; Foundation for Growth Science; and The Japanese Society for Pediatric Endocrinology (Future Development Grant supported by Novo Nordisk Pharma Ltd).

**Key Clinical Message**

Hypopituitarism could have been overlooked so far in the patients with 9q subtelomere deletion syndrome (9qSTDS); thus, further investigations or reevaluation of clinical information, especially hormonal evaluations, are warranted to determine whether hypopituitarism is a rare or relatively common presentation in patients with 9qSTDS.

**KEY WORDS**

9q subtelomere deletion syndrome, array comparative genomic hybridization, central adrenal insufficiency, hypopituitarism, whole-exome sequence

## 1 | INTRODUCTION

The chromosome 9q subtelomere deletion syndrome (9qSTDS; MIM #610253), also known as Kleefstra syndrome, is one of the most common clinically recognizable

subtelomere deletion syndromes, with approximately 100 reported cases in the literature.<sup>1,2</sup> The 9qSTDS is characterized by intellectual disability, severe hypotonia with speech and gross motor delay, and characteristic facial features, including micro- or brachycephaly, hypertelorism, synophrys,

Shinji Higuchi and Masaki Takagi contributed equally to this work.

This is an open access article under the terms of the Creative Commons Attribution License, which permits use, distribution and reproduction in any medium, provided the original work is properly cited.

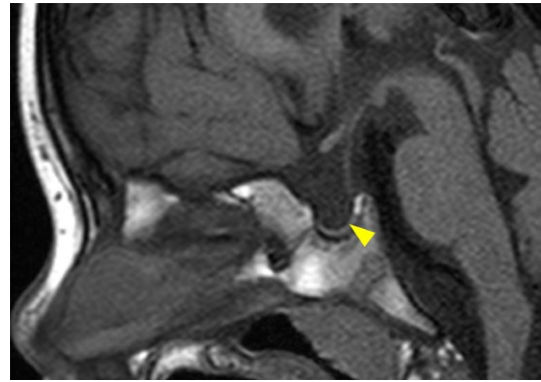
© 2018 The Authors. *Clinical Case Reports* published by John Wiley & Sons Ltd.

arched eyebrows, midface hypoplasia, a short nose with upturned nares, a protruding tongue, everted lower lip, and downturned corners of the mouth.<sup>3</sup>

In addition, congenital heart defects, epilepsy, and urogenital defects are frequently observed. To the best of our knowledge, however, hypopituitarism with 9qSTDS has not been previously reported. Here, we present the first case of definite hypopituitarism with a 9q34.3 subtelomeric deletion, thus expanding our understanding of the phenotypic features associated with 9qSTDS.

## 2 | CASE REPORT

The patient was a 7-year-old Japanese boy born at 38 weeks of gestation after an uncomplicated pregnancy and delivery. His parents were nonconsanguineous and phenotypically normal. He had no family history of pituitary dysfunction. His birth length was 51.0 cm (1.0 SD), and weight was 3.4 kg (0.9 SD). At birth, several dysmorphic features including hypertelorism, synophrys, midface hypoplasia, right preauricular pits, prominent antihelix, short philtrum, and thin upper lip with downturned corners of the mouth were observed. Echography revealed an atrial septal defect and left renal hydronephrosis. An auditory brainstem response examination revealed mild hearing impairment in both ears. The testes were undescended. Neonatal screening levels of thyroid-stimulating



**FIGURE 1** Brain magnetic resonance imaging of the patient at the age of 4 years. A hypoplastic anterior pituitary gland (arrowhead), with a visible but thin stalk, and an eutopic posterior pituitary gland are shown

hormone (TSH) and free T4 were normal. At the age of 1 year and 5 months, his height was 77.2 cm (−0.9 SD), weight was 8.35 kg (−1.8 SD), and head circumference was 44.6 cm (−1.3 SD), respectively.

He was referred to us at 4 years of age because of his short stature. His height and weight were 87.7 cm (−3.2 SD) and 10.2 kg (−2.7 SD), respectively. He showed micropenis, with a stretched penile length of 2.5 cm. Brain magnetic resonance imaging revealed an anterior pituitary hypoplasia with a visible but thin stalk, as well as an eutopic posterior pituitary gland (Figure 1). No other abnormalities in the central nervous

**TABLE 1** Endocrinological findings in the patient

	Stimulus	4 years		6 years		Reference	
		Basal	Peak	Basal	Peak	Basal	Peak
GH (ng/mL)	Arginine	0.67	→ 3.69	0.8	→ 1.5		>6
TSH (mIU/mL)	TRH	2.127	→ 31.117 <sup>a</sup>				10-35
PRL (ng/mL)	TRH	5.19	→ 72.04			1.7-15.4	Increase 2 times
ACTH (pg/mL)	CRH	16.5	→ 40.1	14.8	→ 51.4	9.8-27.3	28-130.5
Cortisol (μg/dL)	CRH	6.1	→ 17.3	5.4	→ 13.3	5-20	>20.0 or increase >10
LH (mIU/mL)	GnRH	<0.1	→ 3.42	<0.1	→ 3.83	<0.1 <sup>b</sup>	<0.10-4.29 <sup>b</sup>
FSH (mIU/mL)	GnRH	1.0	→ 13.08	1.0	→ 18.21	0.46-1.43 <sup>b</sup>	5.38-11.67 <sup>b</sup>
IGF-1 (ng/mL)		13		16		32-176 <sup>c</sup> 55-215 <sup>d</sup>	
Free T4 (ng/dL)		0.86				1.01-1.95	
Free T3 (pg/mL)		3.14				2.23-5.30	

ACTH, adrenocorticotropic hormone; CRH, corticotropin-releasing hormone; FSH, follicle-stimulating hormone; GH, growth hormone; GnRH, gonadotropin-releasing hormone; IGF, insulin-like growth factor; LH, luteinizing hormone; PRL, prolactin; TRH, thyrotropin-releasing hormone; TSH, thyroid-stimulating hormone; T3, triiodothyronine; T4, thyroxine.

The conversion factors to the SI unit are as follows: GH 1.0 (μg/L), TSH 1.0 (mIU/L), LH 1.0 (IU/L), FSH 1.0 (IU/L), testosterone, 0.035 (nmol/L), prolactin 1.0 (μg/L), ACTH 0.22 (pmol/L), cortisol 27.59 (nmol/L), IGF-I 0.131 (nmol/L), free T4 12.87 (pmol/L), and free T3, 1.54 (pmol/L).

<sup>a</sup>The peak of TSH was normal; however, prolonged increase in TSH (20.241 mIU/mL at 120 minutes after TRH administration) indicated hypothalamic hypothyroidism.

<sup>b</sup>Reference data of UK children (younger than 10 y).

<sup>c</sup>Reference data of Japanese 4-year-old boys.

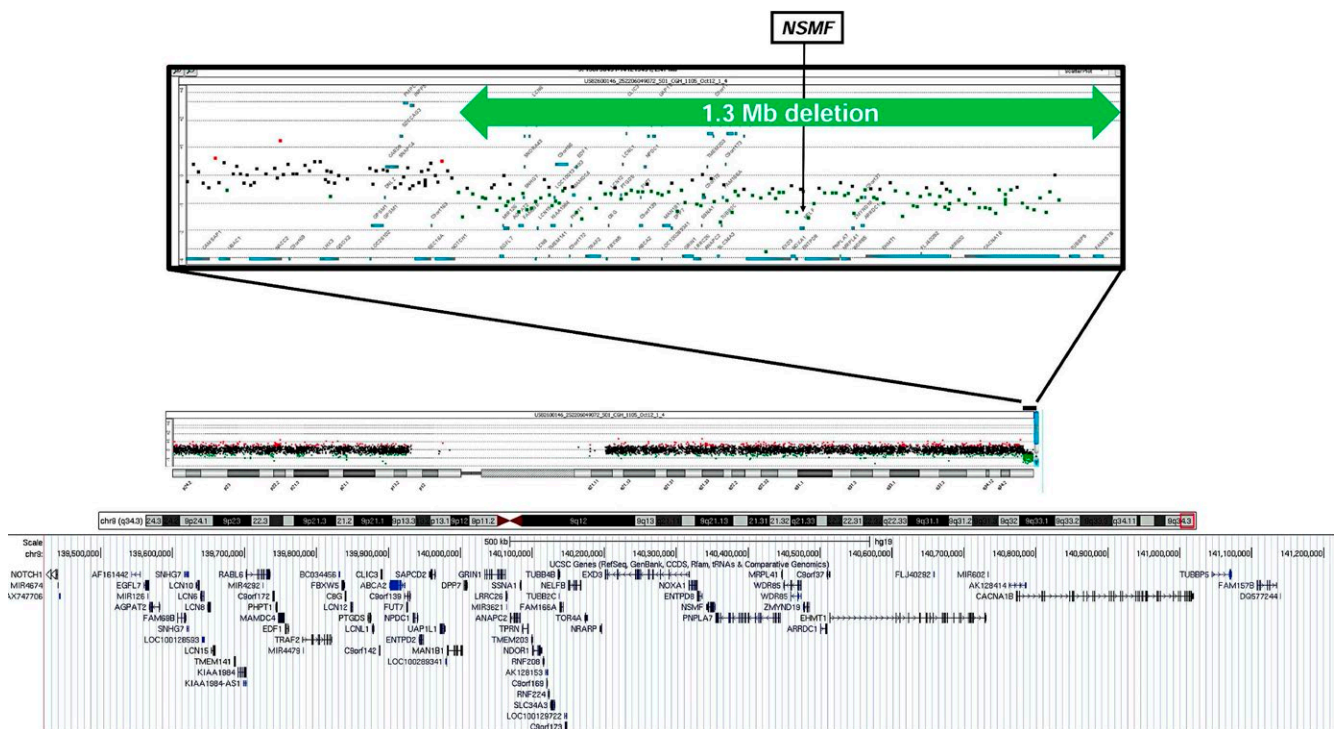
<sup>d</sup>Reference data of Japanese 6-year-old boys.

system were found. Hormonal data revealed growth hormone (GH) and TSH deficiencies (Table 1). The cortisol peak response during the corticotropin-releasing hormone (CRH) test was normal (peak cortisol = 17.3  $\mu\text{g}/\text{dL}$ , Ref > 20.0  $\mu\text{g}/\text{dL}$  or increment of 10  $\mu\text{g}/\text{dL}$ ). A replacement therapy with l-thyroxine was started. Replacement therapy with GH was refused by the parents.

At the age of 6 years and 4 months, the patient exhibited hypoglycemia without an apparent cause. The blood glucose level was 35 mg/dL when he was admitted to our hospital. Hyperinsulinism was excluded based on the analysis of critical samples (serum insulin levels were below 0.60  $\mu\text{IU}/\text{mL}$ ). We reevaluated his pituitary function by provocation tests, and an impaired cortisol response was observed during the CRH test (peak cortisol 13.3  $\mu\text{g}/\text{dL}$ ). He was then diagnosed with central adrenal insufficiency due to adrenocorticotrophic hormone (ACTH) deficiency (Table 1), and a replacement therapy with hydrocortisone was started. After starting hydrocortisone therapy, hypoglycemia has not been recorded since. At his last examination at the age of 7 years and 6 months, his height and weight were 106.0 cm (−3.2 SD) and 16.4 kg (−1.8 SD), respectively. Owing to severe psychomotor retardation, he remains wheelchair-bound and nonverbal.

Genomic DNA from the patient was subjected to array comparative genomic hybridization with the Agilent 4 × 180 K SurePrint G3 Human CGH Microarray (catalog no. G4449A; Agilent Technologies). We identified a heterozygous 1.3-Mb subtelomeric deletion at 9q34.3 (Figure 2). Multiplex ligation-dependent probe amplification (MLPA) analysis of the parents revealed that this deletion was de novo (data not shown). The list of the deleted genes is provided as Data S1.

The combination of two relatively rare conditions, 9qSTDS and hypopituitarism, led us to perform additional study: whole-exome sequence (WES) to obtain additional genetic information for the etiology of the hypopituitarism. Detailed are described in Data S3. We provide the list of variants of unknown significance (VUS) detected in WES as Data S2. The number of variants remaining after each filtering step is provided in Supplemental Table 1. No mutations were found in the currently known hypopituitarism-related genes (*POU1F1*, *PROPI*, *HESX1*, *LHX4*, *OTX2*, *SOX2*, *SOX3*, *GLI2*, *PAX6*, *IGSF1*, *GPR161*, *FGF8*, *KALI*, *PROK2R*, and *LHX3*). As one allele was lost for the region of chromosome 9q34.3 in the patient, any mutations in this region in the remained allele could be functionally null. However, we were unable to identify any pathological sequence variations in the genes located in the deleted region. Trio de novo approach using the DNAs from parents was refused.



**FIGURE 2** Result of array CGH analysis. Graphical representation of the results from the array CGH analysis (Agilent 4 × 180 K SurePrint G3 Human CGH Microarray) shows approximately 1.3-Mb deletion of the 9q subtelomere. At the proximal breakpoint (centromeric), the last present probe was A\_14\_P113317 (chr 9:139432550-139432609), while the first deleted probe was A\_16\_P02194382 (chr 9:139450604-139450661). Base pair positions were derived from the University of California Santa Cruz (UCSC) Genome Browser (available on line at: <http://genome.ucsc.edu/cgi-bin/hgGateway>), build GRCh37 (hg19)

### 3 | DISCUSSION

To the best of our knowledge, this is the first example of a patient presenting with hypopituitarism, harboring a heterozygous 1.3-Mb deletion in 9q34.3. Short stature and genital abnormalities, such as cryptorchidism and micropenis, both of which could be the results of hypopituitarism, are relatively common phenotypes in the patient with 9qSTDS: short stature in 32% and genital abnormalities in 32% of 9qSTDS patients.<sup>4</sup> No 9qSTDS cases evaluated for pituitary functions have been reported; therefore, hypopituitarism with 9qSTDS could have been overlooked so far, and further investigations or reevaluations of clinical information, especially hormonal evaluations, are warranted. It is also of note that the secretion of ACTH gradually decreased in our patient. A gradual loss of ACTH is a point of concern in some patients with congenital hypopituitarism. Therefore, we suggest careful follow-up monitoring of the hypothalamic-pituitary-adrenal function in patients with 9qSTDS and hypopituitarism as adrenal insufficiency could be lethal, even if ACTH deficiency is not apparent during the first evaluation.

The combination of two relatively rare conditions, 9qSTDS and hypopituitarism, led us to perform WES to obtain additional genetic information for hypopituitarism; however, we were unable to identify any mutations in the known causative genes for hypopituitarism or second hit mutations in genes located in the deleted region. Hypogonadotropic hypogonadism (HH), which results in micropenis and cryptorchidism, in patients with 9qSTDS could be due to a haploinsufficiency of *NSMF* (MIM # 608137). This gene is located at chr9:140342023-140353786 in the commonly deleted region, encodes a guidance molecule for olfactory axon projections, and plays a role in the neurophilic migration of luteinizing hormone-releasing hormone cells.<sup>5</sup> Several reports have shown that *NSMF* is associated with normosmic idiopathic HH and Kallmann syndrome (KS), defined by HH and anosmia/hyposmia, either singly or in combination with a mutation in another gene.<sup>6-9</sup> Recent studies have shown that variants in *FGF8*, *KALI*, and *PROKR2*, the genes responsible for KS, have been identified in a small number of hypopituitarism.<sup>10,11</sup> Haploinsufficiency of *NSMF* could partly contribute to pituitary development. Of course, the possibility that hypopituitarism and 9qSTDS are coincident, and that the patient had additional variants in unidentified genes causative for hypopituitarism, cannot be completely excluded.

In conclusion, we present the first case of definite hypopituitarism with a 9q34.3 subtelomeric deletion, thus expanding our understanding of the phenotypic features associated with 9qSTDS. However, hypopituitarism could have been overlooked so far in the patients with 9qSTDS; thus, further investigations or reevaluation of clinical information,

especially hormonal evaluations, are warranted to determine whether hypopituitarism is a rare or relatively common presentation in patients with 9qSTDS.

### ACKNOWLEDGMENTS

We thank the patient and his family for participation in this study. We also thank Kazue Kinoshita for technical assistance.

### CONFLICT OF INTEREST

The authors have nothing to declare.

### AUTHOR CONTRIBUTION

Shinji Higuchi, Masaki Takagi, and Tomonobu Hasegawa: conceived and designed the experiments. Masaki Takagi and Satoshi Narumi: performed the experiments and analyzed the data. Shinji Higuchi, Ryojun Takeda, and Hiroshi Yoshihashi: contributed reagents/materials/analysis tools. Shinji Higuchi and Masaki Takagi: wrote the manuscript.

### ORCID

Masaki Takagi  <http://orcid.org/0000-0002-5062-0609>

Ryojun Takeda  <http://orcid.org/0000-0003-1654-9463>

### REFERENCES

1. Kleefstra T, van Zelst-Stams WA, Nillesen WM, et al. Further clinical and molecular delineation of the 9q subtelomeric deletion syndrome supports a major contribution of EHMT1 haploinsufficiency to the core phenotype. *J Med Genet.* 2009;46:598-606.
2. Samango-Sprouse C, Lawson P, Sprouse C, Stapleton E, Sadeghin T, Gropman A. Expanding the phenotypic profile of Kleefstra syndrome: a female with low-average intelligence and childhood apraxia of speech. *Am J Med Genet A.* 2016;170A:1312-1316.
3. Stewart DR, Kleefstra T. The chromosome 9q subtelomere deletion syndrome. *Am J Med Genet C Semin Med Genet.* 2007;145C:383-392.
4. Willemsen MH, Vulto-van Silfhout AT, Nillesen WM, et al. Update on Kleefstra syndrome. *Mol Syndromol.* 2012;2:202-212.
5. Kramer PR, Wray S. Novel gene expressed in nasal region influences outgrowth of olfactory axons and migration of luteinizing hormone-releasing hormone (LHRH) neurons. *Genes Dev.* 2000;14:1824-1834.
6. Miura K, Acierno JS Jr, Seminara SB. Characterization of the human nasal embryonic LHRH factor gene, NELF, and a mutation screening among 65 patients with idiopathic hypogonadotropic hypogonadism (IHH). *J Hum Genet.* 2004;49:265-268.
7. Pitteloud N, Quinton R, Pearce S, et al. Digenic mutations account for variable phenotypes in idiopathic hypogonadotropic hypogonadism. *J Clin Invest.* 2007;117:457-463.

8. Tornberg J, Sykiotis GP, Keefe K, et al. Heparan sulfate 6-O-sulfotransferase 1, a gene involved in extracellular sugar modifications, is mutated in patients with idiopathic hypogonadotrophic hypogonadism. *Proc Natl Acad Sci U S A*. 2011;108:11524-11529.
9. Xu N, Kim HG, Bhagavath B, et al. Nasal embryonic LHRH factor (NELF) mutations in patients with normosmic hypogonadotropic hypogonadism and Kallmann syndrome. *Fertil Steril*. 2011;95:1613-1620.
10. Raivio T, Avbelj M, McCabe MJ, et al. Genetic overlap in Kallmann syndrome, combined pituitary hormone deficiency, and septo-optic dysplasia. *J Clin Endocrinol Metab*. 2012;97:E694-E699.
11. McCabe MJ, Hu Y, Gregory LC, et al. Novel application of luciferase assay for the in vitro functional assessment of KAL1 variants in three females with septo-optic dysplasia (SOD). *Mol Cell Endocrinol*. 2015;417:63-72.

## SUPPORTING INFORMATION

Additional supporting information may be found online in the Supporting Information section at the end of the article.

**How to cite this article:** Higuchi S, Takagi M, Takeda R, Yoshihashi H, Narumi S, Hasegawa T. An association with hypopituitarism and 9q subtelomere deletion syndrome. *Clin Case Rep*. 2018;6:2371–2375. <https://doi.org/10.1002/ccr3.1591>