



## Case report

## Chest wall reconstruction in a young man after high-velocity gunshot using a combination latissimus dorsi flaps and titanium plates: A case report

Rawand Abdulrahman Essa<sup>a,b,c,d</sup>, Sirwan Khalid Ahmed<sup>a,b,c,d,\*,\*\*</sup>, Mona Gamal Mohamed<sup>e</sup>, Dunya Hars Bapir<sup>d</sup><sup>a</sup> Department of Emergency, Rania Teaching Hospital, Rania, Sulaimani, Kurdistan-region, Iraq<sup>b</sup> Department of Cardiothoracic and Vascular Surgery, Rania Medical City Hospital, Rania, Sulaimani, Kurdistan-Region, Iraq<sup>c</sup> Department of Emergency, Rania Pediatric & Maternity Teaching Hospital, Rania, Sulaimani, Kurdistan-region, Iraq<sup>d</sup> Department of Biotechnology, Institute of Science and Modern Technology, Rojava University, Qamishlo, Syria<sup>e</sup> Department of Nursing, RAK Medical and Health Sciences University, Ras Al Khaimah, United Arab Emirates

## ARTICLE INFO

## Keywords:

Chest wall reconstruction  
Latissimus dorsi flap  
Titanium plate  
Gunshot  
Thoracic defect

## A B S T R A C T

Chest trauma, penetrating or blunt, is common in this era of road traffic accidents, terrorism, and hunting in Iraq. During the last decade, many novel surgical procedures and materials were used to reconstruct or stabilize the chest wall to improve integration, maintain the stability of the chest wall, and reduce infections. However, no precise guidelines for managing chest wall diseases are still available to date. Here, we present a 24-year-old male who underwent chest wall reconstruction using a combination of latissimus dorsi flap and titanium plates, which were to cover the chest wall after a high-velocity gunshot. This patient was in shock too, with a lung contusion and massive hemorrhage. The sucking open chest wound lead to grossly disturbed respiratory mechanics. Such patients usually die on the way due to hemodynamic instability. In this particular case, adequate resuscitation and prompt thoracotomy saved the patient's life. This case report is important because, as we already mentioned, thoracic trauma alone is the cause of death in 25% of patients, and in another 25%, it's a contributing factor in a polytrauma death. This amounts to very high mortality. Our patient received a major laceration of the left lung. Our patient had a full recovery from this life-threatening situation.

## 1. Introduction

Chest trauma, penetrating or blunt, is common in this era of road traffic accidents, terrorism, and hunting in Iraq.

Chest wall reconstruction is a challenging area of cardiothoracic and vascular surgery. During the last decade, many novel surgical procedures and materials were used to reconstruct or stabilize the chest wall to improve integration, maintain the stability of the chest wall, and reduce infections. However, no precise guidelines for managing chest wall diseases have been available to date [1]. More than 80% of chest trauma is treated without opening the chest, using IV fluids, a chest tube, oxygen therapy, blood transfusions, and aggressive physiotherapy [2].

In 1906, Tensini reported the first chest wall reconstruction by using a pedicle latissimus dorsi flap to cover an anterior chest wall defect [3]. The Latissimus dorsi flap is one of the genuinely reconstructive workhorse flaps in general. Due to its vast potential size, the ability to

integrate several types of tissue, relatively long pedicles, and robust vessels, it is probably one of the most adaptable flaps ideal for reconstruction of the chest [4]. Chest wall loss caused by trauma, infection, or oncological surgery may be reconstructed with latissimus dorsi flaps in combination with thoracoplastic procedures, Gore-tex, collagen, composite titanium, polypropylene, and synthetic bioengineered rib grafts.

The aim of this paper is to describe a 24-year-old male who underwent chest wall reconstruction using a combination of latissimus dorsi flap and titanium plates was used to cover the chest wall after a high-velocity gunshot. This report has been written in line with SCARE guidelines [5].

## 2. Case presentation

A 24-year-old male admitted to Ranya Emergency Hospital, presented with a high velocity gun shot to left hemithorax in cardiac box, 1

\* Corresponding author at: Department of Emergency, Rania Teaching Hospital, Rania 46012, Kurdistan region, Iraq.

\*\* Corresponding author at: Department of Biotechnology, Institute of Science and Modern Technology, Rojava University, Qamishlo, Syria.

E-mail address: [sirwan.ahmed1989@gmail.com](mailto:sirwan.ahmed1989@gmail.com) (S.K. Ahmed).<https://doi.org/10.1016/j.ijscr.2022.107030>

Received 20 March 2022; Received in revised form 31 March 2022; Accepted 31 March 2022

Available online 4 April 2022

2210-2612/© 2022 The Authors. Published by Elsevier Ltd on behalf of IJS Publishing Group Ltd. This is an open access article under the CC BY-NC-ND license (<http://creativecommons.org/licenses/by-nc-nd/4.0/>).

cm below the left nipple (Fig. 1). He was in shock a state, semiconscious. SPO2 was 82% with oxygen. There was bleeding per wound (multiple wounds due to the exploded container of the shells in the chest wall). Resuscitation was done for the patient; he received 4 pints of blood (B + ve), 5000 cc of normal saline, ATS, antibiotics and painkillers. A foley Catheter was inserted. Close monitoring of his vital signs and urine output has been done. Investigations: CBC, RFT, LFT Electrolytes, ECG, and the FAST was done and all of them were normal.

Subsequently, following the receipt of informed consent, the patient was transported to the Operation Theatre (OT), where he was placed under appropriate monitors. Then, in supine position, under general anaesthesia, after double lumen intubation; good disinfection with Povidone iodine has been done and the patient covered with sterilized towels. Through the wound, we just extended the wound laterally; we found that the left lower lobe was completely destructed due to multiple shells. We decided to remove a useless lobe (left lower lobectomy has been done) (Fig. 2). Then the we reconstructed 3 lost ribs (7th 8th and 9th rib) with titanium, we tightened the titanium with screws trough the ends of each rib (Video 1). Then medial part of the Latissimus dorsi muscle was taken and it was separated into 3 pieces, and we covered each titanium with each piece of the muscle (Fig. 3 & Video 2). The burned part of the skin was removed, but the nipple with a third of areolar content remained. After good hemostasis, a single chest drain was placed and the incision was sutured in layers.

The patient was put in the ICU unit for 1 day and was discharged to the ward on the 2nd day post-operatively. On 3rd day we did CXR; his left upper lobe was collapsed. A very good chest physiotherapy has been done for him but it was useless, we did Fiber Optic Bronchoscopy (FOB); there was thick secretion and a little blood in his left main bronchus. Six hours later we did another CXR; it magically responded to the scope. After 2 weeks from close follow up and good chest physiotherapy, the patient discharged home on Mucolytic, antibiotic and pain killer medications. New CXRs were performed one and six months later, and the titaniums were in place, with no hemopneumothorax (Fig. 4).

### 3. Discussion and conclusion

Chest wall reconstruction of the lung and chest wall is sometimes necessary to achieve complete recovery in the emergent phase. In selected situations, especially after extended anterolateral resections, reconstruction of the chest wall is required to provide not only protection of the organs, but also enough stability for adequate respiratory function [6]. An algorithmic approach to chest wall reconstruction begins with the assessment of the nature of the defect, taking into consideration factors such as infection and surgical intervention. The latter factors bear influence on the type of tissue required as well as whether reconstruction can be performed in a single stage or whether it is better delayed. Finally, patient factors, including lifestyle and work, as

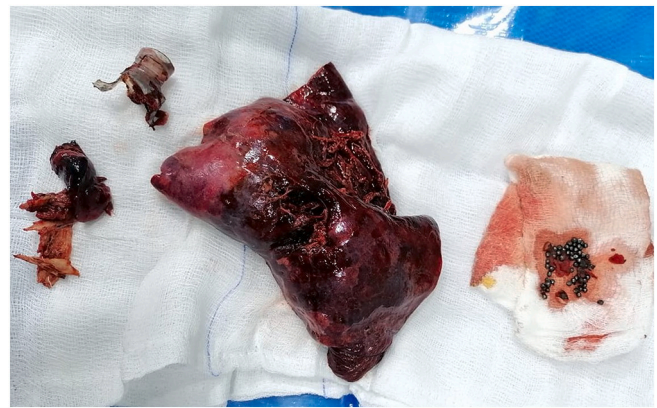

Fig. 2. Shows a removed destructed lobe of the lung with multiple shells.

well as prognosis, are considered to determine the best reconstructive option [7].

The general approach to the reconstruction of the chest wall consists of the use of alloplastic materials like meshes, sometimes reinforced with cement or titanium implants to provide enough stability [8].

If an extended local paradoxical movement of the reconstructed chest wall were to develop, it may lead to respiratory failure [8]. Generally, lesions <5 cm in size in any location may be reconstructed without the need of rigid prosthetic material [9]. In the case of an infection, the use of alloplastic material is not recommended due to the formation of bacterial biofilm on the surface of the prosthesis that is usually unreachable by antibiotics and the immune system [10].

The principles of ATLS, govern the management of chest trauma patients. The airway, breathing, and circulation are secured. Chest injuries are managed by chest drains. In cases of open pneumothorax with a chest wall defect, a chest drain does not help or restore the pulmonary dynamics. The patient needs to be shifted to the OR for control of hemorrhage, lung parenchymal repair, and chest wall reconstruction. Different methods have been used effectively to reconstruct the chest wall. The reconstructive spectrum includes skin grafting, prosthetic implants, micro vascular free tissue transfer, bone reconstruction, and vacuum assisted closure. In the past, flaps of pectoralis major, latissimus dorsi, and rectus abdominis have been used to repair chest wall defects [11].

Gunshot chest patients with huge defects, receive high-velocity, close-range, or high-caliber shots. These patients are hemodynamically very unstable due to excessive blood loss and extensive visceral injury. They rarely reach an institution where expert thoracic surgical/chest wall reconstruction expertise is available [12].

We present this unique case of emergency chest wall reconstruction in a gunshot patient. This patient was in shock too, with lung a contusion and massive hemorrhage. The sucking open chest wound lead to grossly disturbed respiratory mechanics. Such patients usually die on the way to or in the ER/OR due to hemodynamic instability. In this particular case, adequate resuscitation and prompt thoracotomy saved the patient's life.

This case report is important because, as we already mentioned, thoracic trauma alone is the cause of death in 25% of patients, and in another 25%, it's a contributing factor in a polytrauma deaths. This amounts to very high mortality. Our patient received a major laceration of the left lung. Our patient had a full recovery from this life-threatening situation.

Supplementary data to this article can be found online at <https://doi.org/10.1016/j.ijscr.2022.107030>.

### Funding

This research did not receive any specific grant from funding agencies in the public, commercial, or not-for-profit sectors.

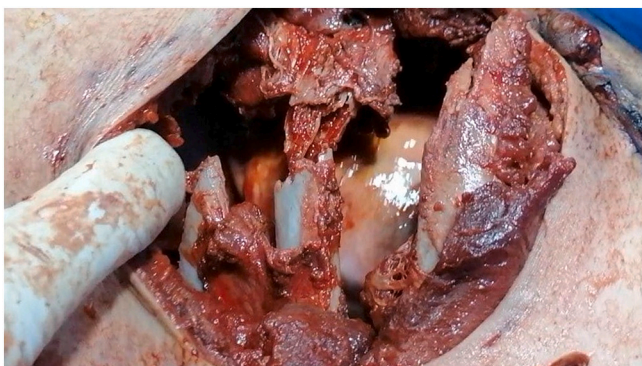


Fig. 1. Shows a big wound in the chest wall, below the left breast, with 3 big defects in the ribs.

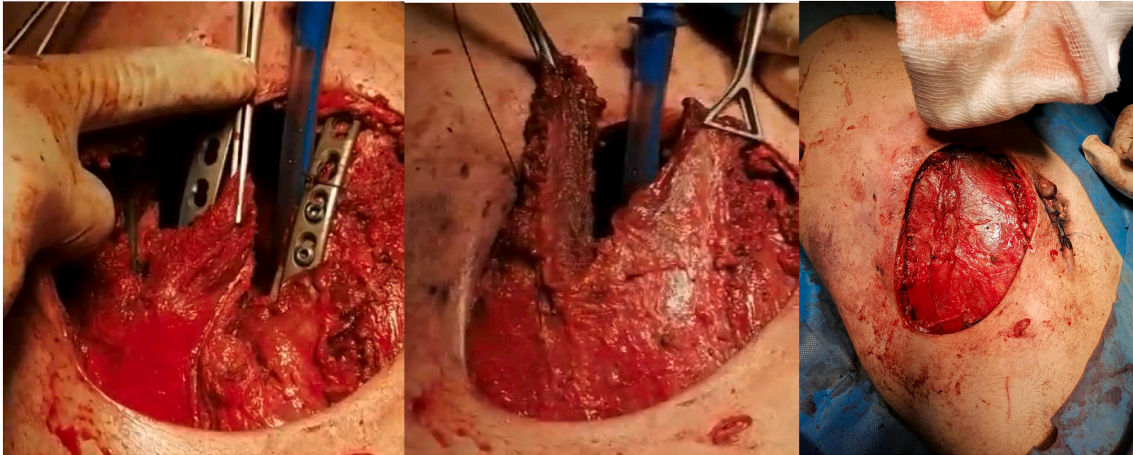


Fig. 3. Shows fixed ribs with titanium and they were covered with muscle flap.

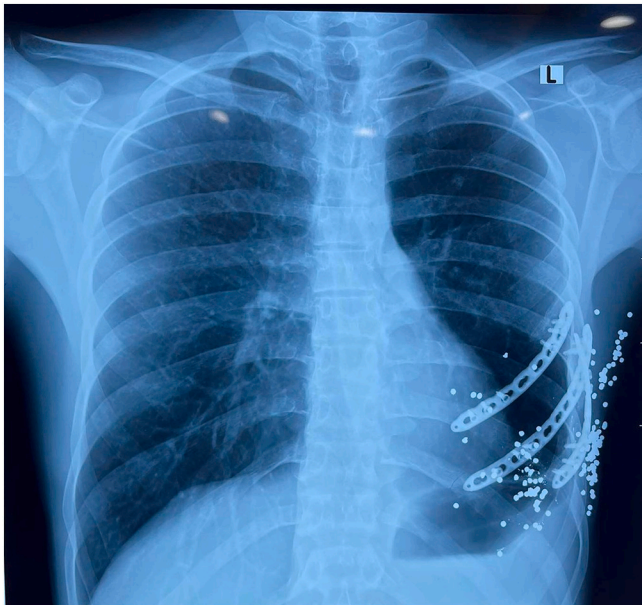


Fig. 4. The CXR after 6 months shows 3 plates and screws in the left hemithorax, with multiple shells in the chest wall.

#### Ethical approval

Approval is not necessary for case report in our locality.

#### Consent

Written informed consent was obtained from the patient for publication of this case report and accompanying images. A copy of the written consent is available for review by the Editor-in-Chief of this journal on request.

#### Registration of research studies

1. Name of the registry: NA.
2. Unique identifying number or registration ID: NA.
3. Hyperlink to your specific registration (must be publicly accessible and will be checked): NA.

#### Guarantor

Dr. Rawand Abdulrahman Essa.  
RN. Sirwan Khalid Ahmed.  
Email: [sirwan.ahmed1989@gmail.com](mailto:sirwan.ahmed1989@gmail.com)

#### Provenance and peer review

Not commissioned, externally peer-reviewed.

#### CRedit authorship contribution statement

Conception and design RAE, SKA acquisition of data RAE, SKA, analysis and interpretation of data RAE, SKA and MGM, drafting of the manuscript RAE, SKA, MGM and DHB. all authors critical revision of the manuscript for important intellectual content and approving final draft.

#### Declaration of competing interest

There is no conflict to be declared.

#### References

- [1] S. Sanna, J. Brandolini, A. Pardolesi, D. Argani, M. Mengozzi, A. Dell'Amore, P. Solli, Materials and techniques in chest wall reconstruction: a review, *J. Vis. Surg.* 3 (2017).
- [2] M. Parvez, Z.U. Malik, M.A. Ali, T. Masood, S. Muzzaffar, Management of thoracic injuries: our experience at military hospitals, *Pak.Armed Forces Med. J.* 57 (2007) 104–112.
- [3] I. Tansini, Sopra il mio nuovo processo di amputazione della mammella, *Gazz. Med. Ital.* 57 (1906) 141.
- [4] K. Bakri, S. Mardini, K.K. Evans, B.T. Carlsen, P.G. Arnold, Workhorse flaps in chest wall reconstruction: the pectoralis major, latissimus dorsi, and rectus abdominis flaps, in: *Semin Plast Surg.* Thieme Medical Publishers, 2011, p. 43.
- [5] R.A. Agha, T. Franchi, C. Sohrabi, G. Mathew, A. Kerwan, A. Thoma, A.J. Beamish, A. Noureldin, A. Rao, B. Vasudevan, The SCARE 2020 guideline: updating consensus Surgical CAsE REport (SCARE) guidelines, *Int. J. Surg.* 84 (2020) 226–230.
- [6] P. Ferraro, S. Cugno, M. Liberman, M.A. Danino, P.G. Harris, Principles of chest wall resection and reconstruction, *Thorac. Surg. Clin.* 20 (2010) 465–473.
- [7] D.T. Netscher, M.A. Baumholtz, Chest reconstruction: I. Anterior and anterolateral chest wall and wounds affecting respiratory function, *Plast. Reconstr. Surg.* 124 (2009) 240e–252e.
- [8] M. Sauerbier, S. Dittler, C. Kreutzer, Microsurgical chest wall reconstruction after oncologic resections, in: *Semin Plast Surg.* © Thieme Medical Publishers, 2011, pp. 60–69.
- [9] B. Wiegmann, S. Korossis, K. Burgwitz, C. Hirschler, S. Fischer, A. Haverich, C. Kuehn, In vitro comparison of biological and synthetic materials for skeletal chest wall reconstruction, *Ann. Thorac. Surg.* 99 (2015) 991–998.

- [10] Z.-Q. Zhao X.-Q. Zhu M.-R. Zhu Z.-G. Cai, Chest wall reconstruction of male: Latissimus dorsi kiss flap rectus, abdominis flap and titanium-mesh, *Asian J Surg.* (n.d.) S1015-9584.
- [11] D.T. Bennett, M.J. Weyant, Extended chest wall resection and reconstruction in the setting of lung cancer, *Thorac. Surg. Clin.* 24 (2014) 383–390.
- [12] M. Klinkenberg, S. Fischer, T. Kremer, F. Hernekamp, M. Lehnhardt, A. Daigeler, Comparison of anterolateral thigh, lateral arm, and parascapular free flaps with regard to donor-site morbidity and aesthetic and functional outcomes, *Plast. Reconstr. Surg.* 131 (2013) 293–302.