

**Original
Article**

Application of Right Bronchial Occlusion under Artificial Pneumothorax in the Thoracic Phase of Minimally Invasive McKeown Esophagectomy

Li Li, MD, Luo Zhao, MD, Jia He, MD, and Zhijun Han, MD

Purpose: To evaluate the feasibility and safety of single-lumen endotracheal intubation combined with right bronchial occlusion (SLET) under artificial pneumothorax in minimally invasive McKeown esophagectomy.

Methods: A total of 165 patients who underwent minimally invasive McKeown esophagectomy at Peking Union Medical College Hospital were retrospectively analyzed. In all, 48 patients received double-lumen endotracheal intubation (DLET group), and 117 patients received SLET-B (SLET-B group). Clinical data, intraoperative hemodynamics, surgical variables, and postoperative complications were analyzed and compared.

Results: Compared with the DLET group, a shorter intubation time and lower tube dislocation rate were found in the SLET-B group. In the thoracic phase, with the application of artificial pneumothorax, patients in the SLET-B group had lower partial pressure of carbon dioxide (PaCO₂) and end-tidal carbon dioxide pressure (PetCO₂) values and higher pH than those in the DLET group. Patients in the SLET-B group had shorter thoracic phase times and hospital stays and less intraoperative hemorrhage than those in the DLET group. The numbers of thoracic and bilateral recurrent laryngeal lymph nodes harvested were significantly higher in the SLET-B group.

Conclusion: SLET under artificial pneumothorax is feasible and safe in minimally invasive McKeown esophagectomy.

Keywords: single-lumen endotracheal tube, bronchial occlusion, artificial pneumothorax, minimally invasive esophagectomy, McKeown esophagectomy

Department of Thoracic Surgery, Peking Union Medical College Hospital, CAMS & PUMC, Beijing, China

Received: March 4, 2021; Accepted: May 6, 2021

Corresponding author: Zhijun Han, MD. Department of Thoracic Surgery, Peking Union Medical College Hospital, Beijing, China, 100730

Email: hanzhijun@pumch.cn



This work is licensed under a Creative Commons Attribution-NonCommercial-NoDerivatives International License.

©2021 The Editorial Committee of *Annals of Thoracic and Cardiovascular Surgery*

Introduction

Esophageal cancer is one of the most common cancers in the world.¹⁾ The pathological types are mainly divided into squamous cell carcinoma and adenocarcinoma. These two pathological types account for more than 95% of the total number of esophageal cancers. In contrast to European and American populations, in which adenocarcinoma predominates, more than 90% of esophageal cancer patients in China have squamous cell carcinoma. Esophagectomy is considered to be the best

therapeutic treatment for resectable esophageal cancer. In recent years, minimally invasive esophagectomy (MIE) has gained popularity with less trauma, morbidity, and mortality than open surgery.²⁾ In contrast to traditional double-lumen endotracheal intubation (DLET) anesthesia, single-lumen endotracheal intubation combined with right bronchial occlusion (SLET) under carbon dioxide (CO₂) artificial pneumothorax is a new type of anesthetic technology. It has less complexity of intubation, less damage to the trachea, and easier tube management. Continuous artificial pneumothorax achieves better lung collapse and surgical field exposure, which are more convenient for tumor resection and lymphadenectomy, especially for the left recurrent laryngeal nerve (RLN). This study retrospectively analyzed 165 patients who underwent minimally invasive McKeown esophagectomy at Peking Union Medical College Hospital from 2014 to 2019. We evaluated the feasibility, safety, and surgical advantages of SLET under artificial pneumothorax compared with traditional DLET.

Materials and Methods

A total of 165 patients who underwent minimally invasive McKeown esophagectomy by one major surgeon (Dr. Li) at Peking Union Medical College Hospital from 2014 to 2019 were retrospectively selected. All patients were diagnosed with esophageal cancer by gastroscopy biopsy, and the tumor location was evaluated by upper gastrointestinal angiography and enhanced computed tomography of the chest and abdomen. Distant metastases were excluded by positron emission tomography (PET) and enhanced head nuclear magnetic

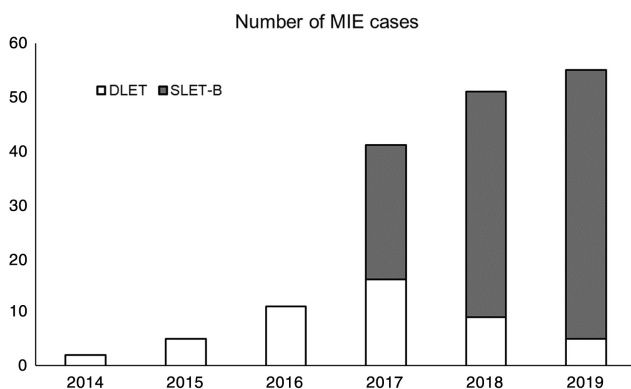


Fig. 1 Number of MIE cases in our center from 2014–2019. MIE: minimally invasive esophagectomy; SLET-B: single lumen endotracheal tube with right bronchial occlusion; DLET: double lumen endotracheal tube.

resonance imaging (MRI). In all, 48 patients received traditional DLET (the DLET group), and 117 patients received SLET under artificial pneumothorax (the SLET-B group). The DLET group included patients who underwent MIE from 2014 to 2019, but the SLET-B group included patients since 2017 (**Fig. 1**). The study was approved by the independent medical ethical committee of the Peking Union Medical College (IRB number S-1050) and all the patients signed extensive informed consents.

Anesthetic and surgical procedure

General anesthesia was adopted in all patients. In the DLET group, a left double-lumen endobronchial intubation was inserted. A fiber bronchoscope was used to confirm the tube position in the left bronchus. The patient was arranged in a left semi-prone position inclined 45°, and the tube and blocker position were confirmed again by auscultate. In the SLET-B group, a 7-Fr or 7.5-Fr single-lumen endotracheal tube was inserted. Then, a bronchial blocker was inserted into the tube lumen under the guidance of a fiber bronchoscope to block the right main bronchus. Artificial pneumothorax was created by CO₂ insufflation with a pressure of 8 mmHg. The parameters of the anesthetic machine and anesthetic drugs were the same between two groups. If the endotracheal tube was displaced, it was adjusted and fixed again by fiber bronchoscopy.

In the thoracic phase, the esophagus was mobilized, and standard lymphadenectomy was performed, especially bilateral RLN lymph nodes and subcarinal nodes. Then, the patient was turned to the supine position. The bronchial blocker was removed in the SLET-B group, and both groups resumed two-lung ventilation. Laparoscopic abdominal exploration was performed, including stomach mobilization, lymphadenectomy, and feeding jejunostomy. Afterwards, cervical anastomosis was performed through a left cervical incision. Selective cervical lymphadenectomy was performed according to the preoperative ultrasonography of suspicious metastatic cervical lymph nodes. All patients were transferred to the intensive care unit under anesthesia after the operation, and the dual-lumen endotracheal tube was replaced with a single-lumen endotracheal tube in patients in the DLET group.

Variables collection

We collected the baseline characteristics, intraoperative hemodynamics during anesthesia, surgical and post-operative characteristics in this study.

Statistical analysis

Analysis was performed using Statistical Product and Service Solutions 19.0 statistical software. The measurement data are expressed as means ($\bar{x} \pm s$) or medians (Q1, Q3). The student's t-test or nonparametric test was used to compare the means between groups according to normal distribution test (K-S test). The chi-squared test was used to compare the count data. Differences for which P values were <0.05 were considered significant.

Results

The baseline characteristics are presented in **Table 1**. A total of 48 patients were assigned to the DLET group, and 117 patients were assigned to the SLET-B group. No significant differences were observed between the two groups in age, sex, preoperative pulmonary function (forced expiratory volume in 1 second/forced vital capacity [FEV1/FVC]), American Society of Anesthesiologists (ASA) grading, tumor location, pathology, neoadjuvant therapy, postoperative staging (TNM staging according to the 2015 Union for International Cancer Control guidelines) or concomitant disease.

The patient characteristics and intraoperative hemodynamics during anesthesia are presented in **Table 2**. Characteristics including heart rate (HR), systolic blood pressure (SBP), diastolic blood pressure (DBP), blood oxygen saturation (SpO_2), peak airway pressure (Ppeak), end-tidal carbon dioxide pressure ($PetCO_2$), and arterial blood gas value (potential of hydrogen, pH; partial pressure of oxygen, PaO_2 ; partial pressure of carbon dioxide, $PaCO_2$) were collected at four time points: T0 (before anesthesia), T1 (45 minutes after the thoracic phase started), T2 (90 minutes after the thoracic phase started), and T3 (half an hour after the thoracic phase ended). Before anesthesia (T0), there were no significant differences between the two groups. In the thoracic phase (T1 and T2), patients in both groups had lower HR, SBP, DBP, and pH and higher Ppeak, $PetCO_2$, PaO_2 , and $PaCO_2$ after CO_2 insufflation. However, the SLET-B group had higher pH and lower Ppeak, $PetCO_2$, and $PaCO_2$ than the DLET group ($P < 0.05$). These parameters were alleviated after the thoracic phase (T3), and no differences were found between the two groups except arterial blood pH.

Surgical and postoperative characteristics are presented in **Table 3**. The SLET-B group had a significantly shorter intubation time and lower tube dislocation rate than the DLET group. The SLET-B group had lower tube

dislocation rate than the DLET group. The SLET-B group had less intraoperative hemorrhage, shorter thoracic phase time, shorter total hospital stay, and more harvested bilateral recurrent laryngeal and total thoracic lymph nodes than the DLET group. However, no differences were found in total operation time, intraoperative blood transfusion, conversion to thoracotomy, or postoperative complications between the two groups.

Discussion

In recent years, MIE has become the recommended treatment for resectable esophageal cancer. DLET is the most commonly used anesthetic method for thoracic surgery, and it can achieve single-lung ventilation to provide sufficient surgical field exposure. However, the shortcomings of this anesthetic method include the complicated intubation process, high incidence of tube dislocation during operation, difficulty in adjustment, and postoperative respiratory complications. Furthermore, it is difficult to access the aortopulmonary window and left RLN due to the lower tracheal mobility of the double-lumen endotracheal tube. Complications such as aorta/pulmonary artery injury and RLN paralysis may occur during lymphadenectomy.³⁾ Single-lumen endotracheal intubation combined with bronchial occlusion has the following advantages.⁴⁾ First, the application access is relatively simple. The bronchial blocker can provide an effective seal of the bronchus with minimal trauma to achieve single-lung ventilation. Furthermore, the intraoperative adjustment is simple, as the surgeon can help to adjust the position of the blocker under the direct vision of the operation. Second, single-lumen endotracheal intubation causes less damage to the airway mucosa and respiratory tract while DLET usually causes postoperative pharyngeal discomfort or pain. Third, after the thoracic phase of surgery, one only needs to remove the bronchial blocker for subsequent surgery. Patients need to be changed to a single endotracheal tube when returning to the intensive care unit after surgery, which can cause secondary injuries as well as postoperative pharyngeal discomfort. In our study, the advantages of perioperative tube management were shown by the significantly lower intubation time and intraoperative tube dislocation rate in the SLET-B group than in the DLET group. DLET needs complicated preoperative intubation and intraoperative management while fiberoptic bronchoscopy adjustment is needed, if necessary. Thus, the intubation time is longer than SLET-B. In addition, the

Table 1 Baseline characteristics

Variables	SLET-B group (N = 117)	DLET group (N = 48)	P value
Age (years)	61.84 ± 8.17	61.42 ± 9.04	0.771
Sex			0.728
Male	100	40	
Female	17	8	
FEV 1/FVC (%)	81.09 ± 7.95	80.59 ± 9.54	0.728
ASA grading			0.134
I	11	10	
II	94	34	
III	12	4	
Tumor location			0.497
Upper	22	13	
Middle	63	23	
Lower	32	12	
Pathology			0.801
Squamous cell carcinoma	106	45	
Adenocarcinoma	7	2	
Other	4	1	
Neoadjuvant therapy			0.417
No	76	36	
Chemotherapy	39	11	
Hemotherapy+radiotherapy	2	1	
Postoperative staging			0.788
I	33	17	
II	40	14	
III	37	15	
IVA	7	2	
Concomitant disease			
Hypertension	38	20	0.262
Diabetes mellitus	22	10	0.765
Cardiovascular disease	19	12	0.191
Respiratory disease	26	15	0.223
Field of lymphadenectomy			0.317
Two-field	92	41	
Three-field	25	7	

FEV 1: forced expiratory volume in 1 second; FVC: forced vital capacity; DLET: double-lumen endotracheal intubation; SLET-B: single-lumen endotracheal intubation combined with right bronchial occlusion

manipulation of the trachea while removing the nodes along the RLNs may contribute to DLET tube dislocation, especially in patients with anatomical abnormality, such as narrow A-P width of the superior mediastinum. Furthermore, adjustment of DLET is difficult during surgery.

When CO₂ is continuously insufflated into the thoracic cavity, the internal pressure of the pleural cavity changes from negative pressure to positive pressure, forming tension pneumothorax, leading to lung collapse, which achieves the purpose of surgical field exposure. Palanivelu et al. used CO₂ pneumothorax for the first

time in thoracoscopy for esophageal cancer in 2006 and found that it could reduce postoperative respiratory complications.⁵⁾ Positive pressure can make capillaries collapse and reduce bleeding. Previous studies have reported that in patients with MIE performed by experienced surgeons, two-lung ventilation during thoracic phase has better surgical variables, such as operation time and hospital stay, than one-lung ventilation.^{6,7)} The SLET-B is an improved one-lung ventilation, which is different from two-lung ventilation. Although this study does not contain direct comparison of our SLET-B + artificial pneumothorax with above-mentioned method of two-lung

Table 2 Patient characteristics and intraoperative hemodynamics during anesthesia

Variables	T0		T1		T2		T3	
	SLET-B	DLET	SLET-B	DLET	SLET-B	DLET	SLET-B	DLET
HR (bpm)	73.58 ± 12.63	74.17 ± 10.80	70.5 (62,75)	70.5 (63,77.25)	70 (62,76.5)	70 (62,75,80)	70 (62,78)	68 (62,79.5)
SBP (mmHg)	121.96 ± 16.86	120.50 ± 15.28	113.87 ± 13.16	113.79 ± 19.21	112.98 ± 13.00	116.71 ± 15.11	112.54 ± 12.14	115.25 ± 13.07
DBP (mmHg)	71.01 ± 10.54	72.04 ± 11.85	66.52 ± 9.02	63.88 ± 10.83	67.44 ± 7.86	68.43 ± 8.29	64.96 ± 7.56	64.04 ± 7.09
SpO2 (%)	100 (100,100)	100 (100,100)	100 (99.5,100)	100 (98.5,100)	100 (99,100)	100 (99,100)	100 (99,100)	100 (98,100)
Ppeak (mmHg)	21.16 ± 5.18	22.17 ± 5.98	27.14 ± 4.98*	29.65 ± 7.07	26.44 ± 5.11*	29.15 ± 6.91	20.70 ± 4.65	22.02 ± 5.90
PetCO ₂ (mmHg)	37.46 ± 3.94	36.25 ± 3.93	41 (38,45)*	43.5 (41,47)	44.74 ± 5.24*	46.67 ± 5.06	35.09 ± 4.14	36.04 ± 4.73
PH	7.39 ± 0.05	7.37 ± 0.05	7.32 (7.26,7.35)*	7.29 (7.24,7.31)	7.29 ± 0.05*	7.27 ± 0.06	7.35 ± 0.05*	7.33 ± 0.05
PaO ₂ (mmHg)	92.03 ± 7.94	91.17 ± 9.53	181.04 ± 48.45	169.73 ± 47.44	185.44 ± 47.16	188.27 ± 51.31	219.44 ± 62.38	201.72 ± 60.78
PaCO ₂ (mmHg)	39.45 ± 4.11	39.81 ± 4.40	46.2 (43.4,51.9)*	53.45 (45,57.3)	53.04 ± 6.06*	55.44 ± 7.34	42.92 ± 6.16	44.83 ± 6.14

*P < 0.05 compared between two groups

DBP: diastolic blood pressure; DLET: double-lumen endotracheal intubation; Ppeak: peak airway pressure; PaO₂: partial pressure of oxygen; PaCO₂: partial pressure of carbon dioxide; PetCO₂: end-tidal carbon dioxide pressure; SBP: systolic blood pressure; SLET-B: single-lumen endotracheal intubation combined with right bronchial occlusion; SpO₂: blood oxygen saturation

ventilation combined with artificial pneumothorax, we think SLET-B has the advantage of maintaining better surgical field created by synergetic effect of one-lung ventilation and artificial pneumothorax while excluding potential disadvantage of intubation with stiff differential endotracheal tube. In our study, intraoperative hemorrhage, thoracic phase time, and total hospital stay in the SLET-B group were less than those in the DLET group. These results indicate that compared with right lung collapse in DLET group, artificial pneumothorax can provide satisfactory surgical field exposure of the mediastinal space and facilitate the dissection of lymph node tissues, reducing intraoperative hemorrhage and the probability of accidental injury during surgery, which may contribute to fewer total hospital stay.

As it is difficult to remove the RLN nodes by placing a rigid double-lumen endotracheal tube in the main bronchus, the number of bilateral recurrent RLN nodes and the total number of thoracic lymph nodes harvested were significantly fewer in the DLET group. Bilateral RLN lymph node metastasis may be as high as 40%, and locoregional recurrence (especially lymph node recurrence) was the most common type of initial treatment failure after curative surgery among patients with esophageal cancer,⁸⁾ thus optimized lymphadenectomy can help us to acquire accurate postoperative pathological staging, which may improve the survival rate in esophageal cancer patients. Furthermore, there were fewer postoperative complications in the SLET-B group, although no significance was found.

The safety of CO₂ pneumothorax is an aspect that needs attention. First, lung collapse, low tidal volume ventilation and direct absorption of carbon dioxide may lead to hypercapnia and acidosis during surgery, which may cause potential damage to the lungs, especially in patients with poor pulmonary function. Second, hemodynamic disturbances may lead to cardiac insufficiency in high-risk patients. Furthermore, CO₂ pneumothorax may cause gas embolization in rare cases. Garg et al. considered that when oxygenation and circumfusion are sufficient, permissible hypercapnia (PHV) allows a maximum PaCO₂ of 67 mmHg and a minimum pH of 7.2 in arterial blood gas.⁹⁾ According to previous research, carbon dioxide artificial pneumothorax under low pressure (<8 mmHg) has no significant effect on respiration and circulation.¹⁰⁾ In our study, after 8 mmHg CO₂ insufflation, arterial blood gas analysis, and ventilator parameters indicated a decrease in pH and an increase in PetCO₂ and PaCO₂, suggesting acidosis and hypercapnia within

Table 3 Surgical and postoperative characteristics

Variables	SLET-B group	DLET group	P value
Intubation time (minutes)	18.28±5.00	21.33±4.63	<0.001
Tube translocation	7	8	<0.05
Total hospital stay (days)	11 (10, 14)	15 (14, 19.75)	<0.001
Thoracic phase time (minutes)	100 (75, 132.5)	135 (116.25, 168.75)	<0.001
Total operation time (minutes)	300 (270, 332.5)	315 (296.25, 348.75)	0.083
Intraoperative hemorrhage (mL)	200 (100, 200)	200 (200, 300)	<0.001
Intraoperative blood transfusion	3	2	0.585
Conversion to thoracotomy	1	1	0.512
Lymph node harvest			
Left RLN	5 (3, 10)	2 (2, 3)	<0.001
Right RLN	4 (2, 6)	2 (1.25, 3)	<0.001
Total thoracic	22 (18, 31)	16.5 (12.25, 20.5)	<0.001
Postoperative complications			
Anastomosis leak	10	6	0.436
RLN paralysis	12	8	0.252
Respiratory complications	6	5	0.216
Cardiovascular complications	5	2	0.975
Chylothorax	2	1	0.870
Postoperative mortality	1	0	0.521

RLN: recurrent laryngeal nerve

acceptable levels. After the end of artificial pneumothorax, these abnormalities were relieved, which fit the protective lung ventilation strategy. In terms of respiratory and circulatory function, HR, blood pressure, SpO₂, and other indicators were not significantly different. Furthermore, better anesthetic conditions were acquired in the SLET-B group with significantly higher pH and lower Ppeak, PetCO₂, and PaCO₂ than in the DLET group. The ventilation parameter adjustment by the anesthesiologist during the operation may contribute to the difference. Another possibility may be that SLET-B was associated with incomplete blockade of the right main bronchus and right lung could partially be participated in ventilation. Therefore, our study indicates that CO₂ artificial pneumothorax is safe under strict control of CO₂ pressure and standardized protocols.

The bronchial blocker also has limitations in the suction of airway secretions and difficulty in lung inflation, which makes its use restricted in lung surgery. With fewer airway secretions and the requirement of repeated lung collapse and inflation, the use of bronchial blockers has more advantages in esophagectomy. Another disadvantage is the inability of continuous sucking of the operative field, which may cause difficulty in the hemostatic process and increased operation time. In our study, however, the operation time and intraoperative hemorrhage in the thoracic phase were significantly shorter in the SLET-B group. Therefore, we believe that this

shortcoming can be overcome through more experience with this surgical technique.

Still, several limitations in our study are noted. First, this is a retrospective study, and although baseline characteristics were comparable, patient selection bias may exist. In addition, this study is also a historical comparison of two different techniques, our data included patients who underwent MIE from 2014 to 2019, but the SLET-B method has only been applied since 2017 (**Fig. 1**). Thus, more experience with this surgical technique may contribute to a better outcome in the SLET-B group. Furthermore, our study is the comparison of SLET-B with artificial pneumothorax and DLET without artificial pneumothorax. We cannot separate the effect of different intubation techniques and effect of pneumothorax.

Conclusion

Therefore, SLET under artificial pneumothorax is feasible and safe in MIE under strict control of CO₂ pressure and standardized protocols. It had advantages in tube management, surgical field exposure, shortened surgery time, increased efficiency of lymphadenectomy, and fewer postoperative complications.

Disclosure Statement

The authors have no conflict of interest.

References

- 1) Domper Arnal MJ, Ferrández Arenas Á, Lanás Arbeloa Á. Esophageal cancer: risk factors, screening and endoscopic treatment in Western and Eastern countries. *World J Gastroenterol* 2015; **21**: 7933–43.
- 2) Yibulayin W, Abulizi S, Lv H, et al. Minimally invasive oesophagectomy versus open esophagectomy for resectable esophageal cancer: a meta-analysis. *World J Surg Oncol* 2016; **14**: 304.
- 3) Lin M, Shen Y, Feng M, et al. Is two lung ventilation with artificial pneumothorax a better choice than one lung ventilation in minimally invasive esophagectomy? *J Thorac Dis* 2019; **11**: S707–12.
- 4) Grocott HP. Bronchial blocker use in the difficult airway patient requiring lung isolation: clarification as to what blockers are actually available. *Anesth Analg* 2018; **127**: e107.
- 5) Palanivelu C, Prakash A, Senthilkumar R, et al. Minimally invasive esophagectomy: thoracoscopic mobilization of the esophagus and mediastinal lymphadenectomy in prone position--experience of 130 patients. *J Am Coll Surg* 2006; **203**: 7–16.
- 6) Cai L, Li Y, Sun L, et al. Better perioperative outcomes in thoracoscopic-esophagectomy with two-lung ventilation in semi-prone position. *J Thorac Dis* 2017; **9**: 117–22.
- 7) Lin M, Shen Y, Wang H, et al. A comparison between two lung ventilation with CO2 artificial pneumothorax and one lung ventilation during thoracic phase of minimally invasive esophagectomy. *J Thorac Dis* 2018; **10**: 1912–8.
- 8) Ni W, Yang J, Deng W, et al. Patterns of recurrence after surgery and efficacy of salvage therapy after recurrence in patients with thoracic esophageal squamous cell carcinoma. *BMC Cancer* 2020; **20**: 144.
- 9) Garg SK. Permissive hypercapnia: Is there any upper limit? *Indian J Crit Care Med* 2014; **18**: 612–4.
- 10) Zhang Y, Duan R, Xiao X, et al. Minimally invasive esophagectomy with right bronchial occlusion under artificial pneumothorax. *Dig Surg* 2015; **32**: 77–81.