



Lateral Femoral Condyle CRATER sign of BRIK an Ancillary Sign of Lateral Patellar Dislocation

Karthikeyan P. Iyengar¹ Kanaka Durga Prasad Bhamidipaty² Rajesh Botchu³

¹Departments of Orthopedics, Southport and Ormskirk NHS trust, Southport, United Kingdom

²Departments of Radiology, GITAM Institute of Medical Sciences & Research (GIMSR), Vizag, India

³Departments of Musculoskeletal Radiology, Royal Orthopaedic Hospital, Birmingham, United Kingdom

Address for correspondence Rajesh Botchu, MRCS, FRCR, Department of Radiology, Royal Orthopaedic Hospital, Bristol Road South, Birmingham, B21 3AP (e-mail: drbrajesh@yahoo.com).

Indian J Radiol Imaging 2022;32:505–509.

Abstract

Introduction Acute lateral patellar dislocation is a common knee injury pattern. However, coincidental osseous defect may be present in normal knees.

Purpose Evaluate the characteristics of osseous bone defect and describe a new ancillary sign associated with lateral patellar dislocation.

Materials and Methods Magnetic resonance imaging (MRI) of 50 consecutive patients referred following a traumatic lateral patellar dislocation of the knee joint and 50 patients with knee pain without MR features of patellar dislocation were obtained for evaluation over a 7-year period. They were analyzed for location of bony defects in the periarticular region.

Results Of the 50 patients who underwent MRI following a reduced traumatic lateral patellar dislocation, 3 patients had an osseous “crater” of more than 2 mm in depth on the non-articular surface of the lateral femoral condyle. None of control group of patients had an osseous defect measuring more than 2 mm in depth.

Conclusion This associated finding of an osseous “crater” of more than 2 mm on the non-articular surface of the lateral femoral condyle following traumatic lateral patellar dislocation is a rare occurrence. We highlight this as an ancillary sign of lateral patellar dislocation necessitating careful evaluation (Crater sign of Bhamidipaty Rajesh Iyengar Kartik [BRIK]). The presence of lateral femoral condyle “CRATER” sign of BRIK on MRI undertaken for other reasons in the knee, in the absence of osseous edema may suggest a past episode of severe, reduced patellar dislocation.

Keywords

- ▶ knee joint
- ▶ knee injuries
- ▶ patellar dislocation
- ▶ radiology
- ▶ magnetic resonance imaging

Introduction

Acute lateral patella dislocations are a common injury pattern and may account for 2 to 3% of all knee injuries.¹ There is a natural propensity of the patella to dislocate laterally due to anatomical configuration and the biomechanical influences

on the patellofemoral joint (PFJ).² This lateral tendency is counteracted by the larger, more steeply inclined facet of the lateral femoral condyle (LFC), which extends more proximally to provide a bony buttress along with the dynamic restraint by the lower insertion of the vastus medialis (VM) on the medial border of the patella. Instability of the

published online
August 30, 2022

DOI <https://doi.org/10.1055/s-0042-1755253>.
ISSN 0971-3026.

© 2022. Indian Radiological Association. All rights reserved.
This is an open access article published by Thieme under the terms of the Creative Commons Attribution-NonDerivative-NonCommercial-License, permitting copying and reproduction so long as the original work is given appropriate credit. Contents may not be used for commercial purposes, or adapted, remixed, transformed or built upon. (<https://creativecommons.org/licenses/by-nc-nd/4.0/>)
Thieme Medical and Scientific Publishers Pvt. Ltd., A-12, 2nd Floor, Sector 2, Noida-201301 UP, India

PFJ can be due to static osseous abnormalities such as trochlear dysplasia (trochlear morphology), patella alta (higher position of patella), abnormal skeletal alignment that alter the biomechanical axis of the knee joint (e.g., increased Q-angle, genu valgum, increased internal tibial torsion) or soft tissue imbalance.³ The medial patellofemoral ligament (MPFL) complex is the most important static medial soft tissue constraint and reported to show 50 to 80% of restraint in preventing lateral patellar dislocation.^{4,5}

Tall, young adolescent females, overweight males, young athletes appear to be at a higher risk of lateral patellar dislocation.⁶ The commonest mechanism of injury for a lateral patellar dislocation is an indirect force delivered from a twisting valgus knee injury with ~10% due to direct knock to the medial side of the knee.⁷ Lateral patellar dislocation in an acute setting presents with an inability to weight-bear with the knee held in flexion. Most of the lateral patellar dislocations tend to reduce spontaneously or with close reduction in the emergency department.^{8,9} However, there is an increasing evidence to suggest that traumatic lateral patellar dislocation may not be an innocuous injury. There is an increasing focus on risk stratification to identify associated injuries, which may require stabilization or predictors for recurrence.¹⁰ Complementary imaging, particularly magnetic resonance imaging (MRI) is becoming valuable and increasingly being used to evaluate concurrent soft-tissue injuries and/or osteochondral fractures.¹¹ The commonly described primary signs on MRI include disruptive injury to the medial retinaculum and medial patellofemoral ligament (MPFL) along with characteristic kissing contusions seen in the inferomedial pole of the patella and the anterolateral aspect of the lateral femoral condyle.^{12,13}

It is well-known that an impaction injury may happen following traumatic lateral dislocation of the patella.^{1,12,14} It has been reported that more than 90% patients have features of bone edema on the lateral femoral condyle following a such an injury. Up to 40% of these patients may demonstrate osteochondral lesions of the lateral femoral condyle on MRI.¹⁵ Traditionally, secondary osseous signs associated with ligamentous injuries such as the "lateral femoral notch sign" in the anterior cruciate ligament (ACL) tears involve sulcus depth of more than 1.5 or 2 mm.¹⁶⁻¹⁸

In this study, we highlight an atypical secondary feature on MRI following lateral patellar dislocation seen in certain patients. This is characterized by an impaction lesion of more than 2 mm in depth on the non-articular surface of the lateral femoral condyle. We describe this new ancillary finding as lateral femoral condyle "CRATER" sign of Bhamidipaty Rajesh Iyengar Kartik (BRIK). We assessed the presence of associated incidental osseous lesions at this site exploring the possible biomechanics and clinical significance of the lateral femoral condyle "CRATER" sign of BRIK.¹⁹

Patients and Methods

Patients

Following local hospital committee ethics approval, a search of our Radiology Information System (RIS) and Picture

Archiving and Communication System (PACS) was performed to identify 50 consecutive patients referred with a traumatic lateral patellar dislocation of the knee joint for an MRI over a 7-year period. All lateral patellar dislocations had been reduced spontaneously after the initial injury. These patients had characteristic features of acute injury suggested by osseous edema of lateral femoral condyle and medial part of the patella on MRI. The MRI studies of 50 consecutive knees without patellar dislocation were assessed for a comparative cohort analysis. The age and sex in each case were recorded.

Image Analysis

Images from each of the MRI study were reviewed by the senior author (single reviewer), a fellowship-trained musculoskeletal radiologist with more than 10 years' experience. Patients with a history of previous surgery were excluded. Imaging protocols and assessment consisted as a minimum of axial proton density (PD) or PDFS, T1-weighted, proton density fat suppressed (PDFS), STIR coronal, and PDFS sagittal images of the knee joint. Radiological images were analyzed for the presence of bone defects on the peri-articular, lateral side of the knee. The location of any bony defects, bone bruising, edema, contusion of the lateral femoral condyle were noted in both group of patients. If there was a osseous defect on the lateral femoral condyle surface, its location, site, and depth were recorded (►Fig. 1). A bone defect of more than 2 mm in depth was considered significant as noted in similar ancillary signs reported in the literature.¹⁶⁻¹⁸ To

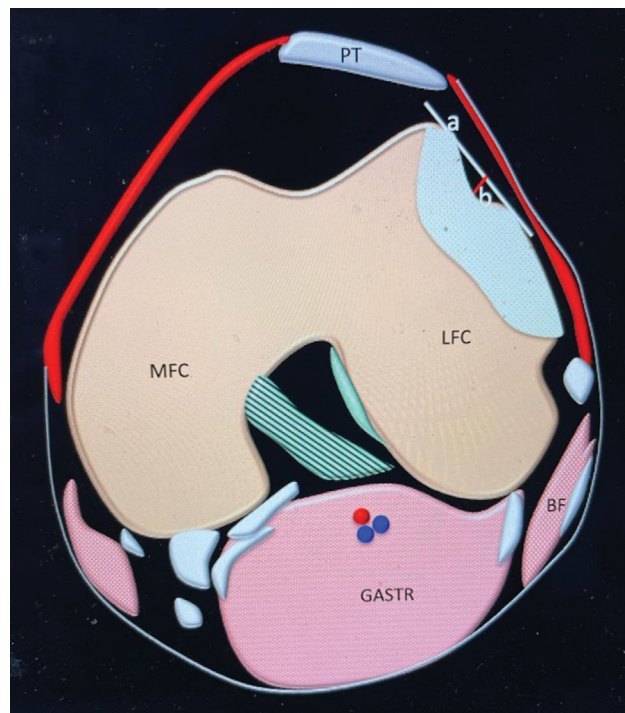


Fig. 1 Schematics of axial of knee showing crater of the lateral femoral condyle with osseous edema (blue), *a* is the tangential line of the crater and *b* is the depth of the crater. BF(biceps femoris), GASTR (gastrocnemius), LFC(lateral femoral condyle), MFC (medial femoral condyle), PT (patellar tendon).

document the location of the osseous “crater” of more than 2 mm in depth, the lateral femoral condyle was divided into anterior, middle, and posterior thirds. The medial supporting structures (superficial and deep MCL, medial patella-femoral ligament (MPFL) posterior oblique ligament [POL]) were not assessed in this study.

Microsoft Excel data sheet was used for data collection and analysis.

Results

Baseline Demographics

Of the patients included in the study, 50 were referred following a traumatic lateral patellar dislocation of the knee joint, there were 25 male and 25 female patients with a mean age of 23 years (12–57). In the control group, there were 28 male and 22 female patients with a mean age 23.4 years (13–57 years).

Assessment of bone defects in the lateral femoral condyle revealed the presence of co-incidental bone defects in nearly half of the patients belonging to the control group (24/50) although none of them were more than 2 mm in depth. On the contrary, review of MRI in patients following acute lateral patellar dislocation revealed bone defects of less than 2 mm in 14 patients, while 33 patients had no visible bone defects (► Fig. 2). The crater was identified and measured at the level of lower pole of the patella (► Fig. 3).

Three patients had an osseous “crater” of more than 2 mm in depth on the non-articular surface of the lateral femoral condyle (► Fig. 4). Patient characteristics and the depth measurements of “crater” found on non-articular surface of the lateral femoral condyle (LFC) is shown in (► Fig. 2). Crater was noted in anterior one-third in all three patients.

Discussion

Traumatic lateral patellar dislocation characteristically present with an obvious deformity and most resolve with spon-

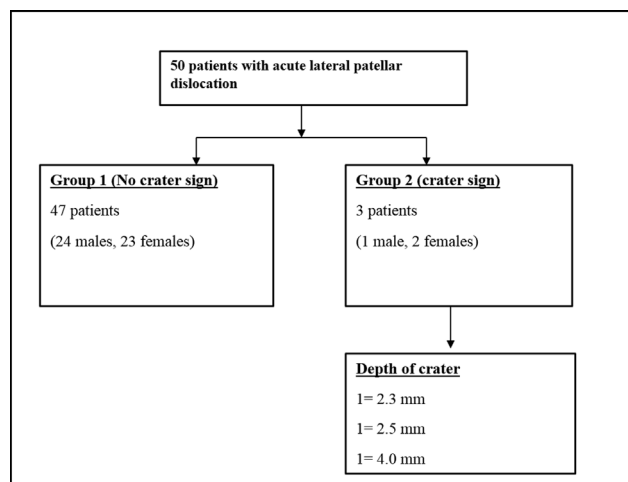


Fig. 2 Patient characteristics, presence and the depth measurements of bone lesions and “crater” found on non-articular surface of the lateral femoral condyle (LFC) following patellar dislocation and control group.

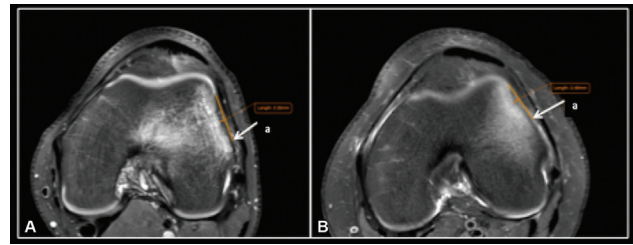


Fig. 3 Axial PDFS of knee of two different patients showing lateral femoral condyle crater sign with a depth of more than 2 mm. a is the tangential line of the crater.

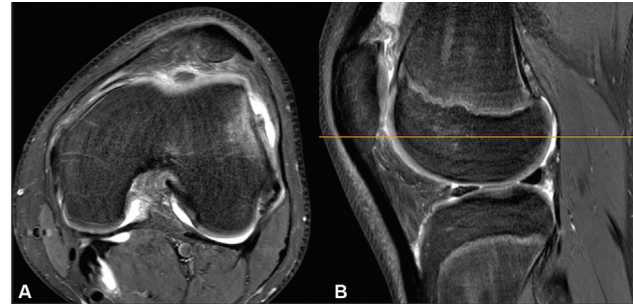


Fig. 4 PDFS axial (A) and sagittal (B) showing level of measurement of crater in relation to the lateral femoral condyle.

taneous reduction or reduce with close reduction in an emergency department setting.²⁰ However, although these injuries are common and most are managed conservatively, treatment algorithm of primary patellofemoral dislocation still appears to be controversial with evolving guidelines.⁸ It is reported that up to one-third of patients will also show concomitant injury to the major ligaments of the knee or concomitant osteochondral injuries, which may not be obvious on plain radiography.²¹ This may lead to prolonged morbidity and the risk of recurrence.²² Consequently, complementary imaging in the form of computed tomography and MRI is increasingly being utilized to exclude associated injuries that may require surgical intervention or a targeted rehabilitation regime.^{8,13,23} MRI provides an excellent, non-invasive modality to assess concomitant knee injuries alongside a focused clinical examination to plan appropriate patient management.

In patients with traumatic lateral patellar dislocation, along with the characteristic injury pattern to the MPFL, kissing contusions of the patella and the lateral femoral condyle, lipohemarthrosis, joint effusion, bone bruising, contusion, osteochondral fractures or features of underlying patellar instability such as trochlear dysplasia can be evaluated with MRI. In the context of trauma, these represent the residual footprints from the severity of the knee injury and help the clinician to direct patient treatment.

While numerous studies have described the above bone bruising and soft-tissue injury patterns, these have not assessed the depth and location of impaction injury on lateral femoral condyle following a lateral patellar dislocation. Our study has revealed features of a unique pattern of impacting lesion on the anterior half and non-articular part

of the lateral femoral condyle. The depth of this osseous crater on non-articular anterior one-third of lateral femoral condyle is more than 2 mm and was found in 6% of the patients evaluated with MRI following relocation of the patellar dislocation. We hypothesize that this pattern of bone lesion of more than 2 mm in the anterior one-third of the lateral femoral condyle represents a clinically significant injury. As the knee joint is one of the commonly imaged joint, co-incidental osseous lesions are not uncommon.¹⁹ It is acknowledged associated incidental osseous lesions may be found at the site of MRI imaging, which may need further evaluation. However, a bone defect of more than 2 mm in depth has been traditionally considered significant as noted in similar ancillary signs reported in the literature on MRI of knee joint.^{16–18} This seems to be strengthened by the finding that none of the patients in the control group revealed any defects more than 2 mm in depth.

We believe the significant bone defect results when patellar dislocation occurs with a substantial force and relocates back in the trochlear groove. The presence of this lateral femoral condyle “crater sign” may direct the clinician to ensure there is no associated concomitant injury and decide whether a longer period of immobilization or a targeted rehabilitation regime is required. In addition, the presence of such a lateral femoral condyle “crater sign” in MRI of the knee undertaken for other symptoms may indicate that the patient has had a previously reduced patellar dislocation. In the absence of osseous marrow edema, a positive “crater sign” will represent the residual footprint of such an injury and could explain current symptoms or features of instability. An heightened awareness may mitigate the incidence of recurrence and help the clinician to direct appropriate patient treatment.

The “crater sign” may also assist in the evaluation and management of trochlear dysplasia (TD). TD, which is characterized by an abnormally shaped trochlear groove has a well-established relationship with recurrent patellar instability and dislocation.^{24–26} The presence of “crater sign” may represent an additional contributory factor to be considered in the management of patients with TD and patellar instability. However, this hypothesis will require further study and validation to establish such a correlation.

The lateral femoral condylar notch sign seen in ACL injuries is in the anterior part of the lateral femoral condyle that is covered by articular cartilage unlike those that are seen with patellar dislocations, which are in the lateral nonweight bearing part of the lateral femoral condyle.

Limitations of the Study

There were a few limitations to this study. This was a retrospective study. Second, the sample size was small. However, considering increasing evidence to suggest that traumatic lateral patellar dislocation may not be an isolated injury, our finding may initiate larger prospective studies to confirm the significance of the lateral femoral condyle “CRATER” sign of BRIK.

Conclusion

We report and describe a rare radiological finding and an ancillary sign in patients with traumatic lateral patellar dislocation. The presence of lateral femoral condyle “CRATER” sign of BRIK suggests a clinically significant injury to the affected knee. It may signpost the clinician to rule out associated injuries and formulate a focused management plan. It may represent the residual footprint of a significant patellar dislocation and carry implications in the management of patellar instability in patients with trochlear dysplasia. Further studies are required to consolidate these findings and understand the significance of the lateral femoral condyle “CRATER” sign of BRIK.

Funding

None.

Conflict of Interest

None declared.

References

- Guerrero P, Li X, Patel K, Brown M, Busconi B. Medial patellofemoral ligament injury patterns and associated pathology in lateral patella dislocation: an MRI study. *Sports Med Arthrosc Rehabil Ther Technol* 2009;1(01):17. Doi: 10.1186/1758-2555-1-17
- Grelsamer RP, Klein JR. The biomechanics of the patellofemoral joint. *J Orthop Sports Phys Ther* 1998;28(05):286–298. Doi: 10.2519/jospt.1998.28.5.286
- Stefancin JJ, Parker RD. First-time traumatic patellar dislocation: a systematic review. *Clin Orthop Relat Res* 2007;455(455):93–101
- Krebs C, Tranovich M, Andrews K, Ebraheim N. The medial patellofemoral ligament: Review of the literature. *J Orthop* 2018;15(02):596–599. Doi: 10.1016/j.jor.2018.05.004
- Desio SM, Burks RT, Bachus KN. Soft tissue restraints to lateral patellar translation in the human knee. *Am J Sports Med* 1998;26(01):59–65
- Placella G, Tei M, Sebastiani E, et al. Anatomy of the medial patello-femoral ligament: a systematic review of the last 20 years literature. *Musculoskelet Surg* 2015;99(02):93–103
- Lowe M, Meta M, Tetsworth K. Irreducible lateral dislocation of patella with rotation. *J Surg Case Rep* 2012;2012(03):10. Doi: 10.1093/jscr/2012.3.10
- Johnson DS, Turner PG. Management of the first-time lateral patellar dislocation. *Knee* 2019;26(06):1161–1165. Doi: 10.1016/j.knee.2019.10.015
- Duthon VB. Acute traumatic patellar dislocation. *Orthop Traumatol Surg* 2015;101(1, Suppl):S59–S67. Doi: 10.1016/j.otsr.2014.12.001
- Rund JM, Hinckel BB, Sherman SL. Acute patellofemoral dislocation: controversial decision-making. *Curr Rev Musculoskelet Med* 2021;14(01):82–87. Doi: 10.1007/s12178-020-09687-z
- Pope TL Jr. MR imaging of patellar dislocation and relocation. *Semin Ultrasound CT MR* 2001;22(04):371–382. Doi: 10.1016/s0887-2171(01)90027-7
- Elias DA, White LM, Fithian DC. Acute lateral patellar dislocation at MR imaging: injury patterns of medial patellar soft-tissue restraints and osteochondral injuries of the inferomedial patella. *Radiology* 2002;225(03):736–743. Doi: 10.1148/radiol.2253011578
- Earhart C, Patel DB, White EA, Gottsegen CJ, Forrester DM, Matcuk GR Jr. Transient lateral patellar dislocation: review of imaging findings, patellofemoral anatomy, and treatment options. *Emerg Radiol* 2013;20(01):11–23. Doi: 10.1007/s10140-012-1073-9

- 14 Kirsch MD, Fitzgerald SW, Friedman H, Rogers LF. Transient lateral patellar dislocation: diagnosis with MR imaging. *Am J Roentgenol* 1993;161(01):109–113. Doi: 10.2214/ajr.161.1.8517287
- 15 Diederichs G, Issever AS, Scheffler S. MR imaging of patellar instability: injury patterns and assessment of risk factors. *Radiographics* 2010;30(04):961–981. Doi: 10.1148/rg.304095755 Erratum in: *Radiographics*. 2011 Mar-Apr;31(2):624
- 16 Lodewijks PCAM, Delawi D, Bollen TL, Dijkhuis GR, Wolterbeek N, Zijl JAC. The lateral femoral notch sign: a reliable diagnostic measurement in acute anterior cruciate ligament injury. *Knee Surg Sports Traumatol Arthrosc* 2019;27(02):659–664. Doi: 10.1007/s00167-018-5214-x
- 17 Pao DG. The lateral femoral notch sign. *Radiology* 2001;219(03):800–801. Doi: 10.1148/radiology.219.3.r01jn12800
- 18 Saad A, Almeer G, Azzopardi C, Gupta H, Botchu R. New secondary sign of ACL tear – the medial femoral notch sign (Gupta-Botchu sign). *Indian J Med Sci* 2021;73(01):124–126
- 19 Kransdorf MJ, Peterson JJ, Bancroft LW. MR imaging of the knee: incidental osseous lesions. *Magn Reson Imaging Clin N Am* 2007;15(01):13–24. Doi: 10.1016/j.mric.2007.02.002
- 20 Longo UG, Ciuffreda M, Locher J, Berton A, Salvatore G, Denaro V. Treatment of primary acute patellar dislocation: systematic review and quantitative synthesis of the literature. *Clin J Sport Med* 2017;27(06):511–523. Doi: 10.1097/JSM.0000000000000410
- 21 Nakagawa S, Arai Y, Inoue H, et al. Two patients with osteochondral injury of the weight-bearing portion of the lateral femoral condyle associated with lateral dislocation of the patella. *Case Rep Orthop* 2014;2014:876410. Doi: 10.1155/2014/876410
- 22 Jain NP, Khan N, Fithian DC. A treatment algorithm for primary patellar dislocations. *Sports Health* 2011;3(02):170–174. Doi: 10.1177/1941738111399237
- 23 Kapur S, Wissman RD, Robertson M, Verma S, Kreeger MC, Oostveen RJ. Acute knee dislocation: review of an elusive entity. *Curr Probl Diagn Radiol* 2009;38(06):237–250. Doi: 10.1067/j.cpradiol.2008.06.001
- 24 Bollier M, Fulkerson JP. The role of trochlear dysplasia in patellofemoral instability. *J Am Acad Orthop Surg* 2011;19(01):8–16. Doi: 10.5435/00124635-201101000-00002
- 25 Dejour H, Walch G, Nove-Josserand L, Guier C. Factors of patellar instability: an anatomic radiographic study. *Knee Surg Sports Traumatol Arthrosc* 1994;2(01):19–26. Doi: 10.1007/BF01552649
- 26 Batailler C, Neyret P. Trochlear dysplasia: imaging and treatment options. *EFORT Open Rev* 2018;3(05):240–247. Doi: 10.1302/2058-5241.3.170058