

# AUSTRIAN SYNDROME WITH A DELAYED ONSET OF HEART FAILURE

YONG-MIN KIM, MD, SUNG-AI KIM, MD, MIN-GANG KIM, MD, YOUNG-SEOK KWON, MD, EUN JI KIM, MD, SANG-HO JO, MD, HYUN-SOOK KIM, MD, SANG-JIN HAN, MD, WOO JUNG PARK, MD AND CHONG-YUN RHIM, MD

DIVISION OF CARDIOLOGY, DEPARTMENT OF INTERNAL MEDICINE, HALLYM SACRED HEART HOSPITAL, HALLYM UNIVERSITY COLLEGE OF MEDICINE, ANYANG, KOREA

A 59-year-old man treated with pneumococcal meningitis 4 months ago was hospitalized for acute heart failure and performed aortic valve replacement by rupture of aortic valve. The frequent association of pneumococcal meningitis and endocarditis is known as Austrian syndrome. Though Austrian syndrome is a clinically rare disease, the evolution of pneumococcal endocarditis is very aggressive and associated with high mortality, and early recognition for evidence of endocardial lesion in patients with pneumococcal meningitis is important to reduce the complications and mortality rate.

**KEY WORDS:** Pneumococcus · Endocarditis · Meningitis.

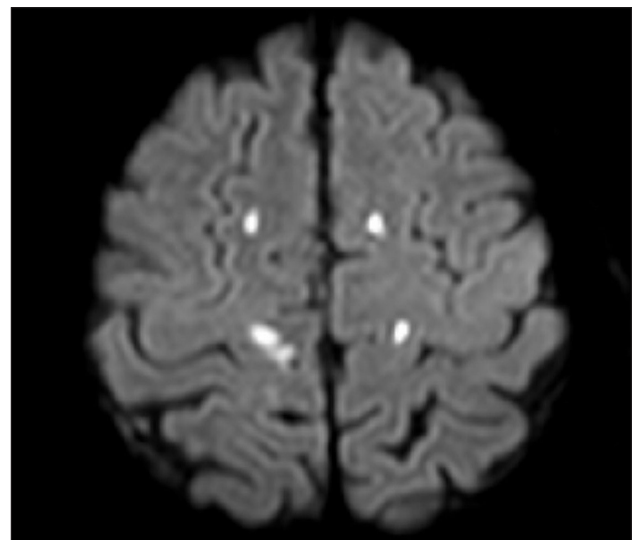
## INTRODUCTION

In this penicillin era, *Streptococcus pneumoniae* is still the most frequent microbial agent of community acquired bacterial meningitis in adults with high mortality.<sup>1)</sup> Also pneumococcal endocarditis (PE) responsible for less than 3% of all cases of endocarditis in native valve have aggressive clinical course with high morbidity and mortality.<sup>2,3)</sup> In 1957, Austrian<sup>4)</sup> described the frequent association of pneumococcal meningitis and endocarditis and stressed the importance of evaluation for evidence of endocardial lesions in patients with pneumococcal meningitis. We report a case of infective endocarditis with a delayed onset of heart failure in a patient treated with pneumococcal meningitis.

## CASE

A healthy 59-year-old man was first admitted with acute bacterial meningitis [cerebrospinal fluid (CSF) : WBC, 3,750/uL (polymorphonuclear neutrophil 97%); glucose, 33 mg/dL; protein, 151 mg/dL]. Cultures of both blood and CSF were positive for *S. pneumoniae*. On the fifth day of intravenous cephalosporin with relieving symptoms as fever and headache, the patient suddenly complained foot dropping. Brain magnetic imaging (MRI) showed multiple cerebral infarctions in both high frontal lobes (Fig. 1). A transthoracic echocardiogra-

phy (TTE) to evaluate cardioembolic source revealed no abnormal finding except for mild prolapsed motion of non-coronary cusp (NCC) of aortic valve (AV) with trivial aortic regurgitation (AR) (Fig. 2). After 2-week course of antibiotic



**Fig. 1.** Brain magnetic resonance imaging at the first admission with pneumococcal meningitis shows the multiple cerebral infarctions in both high frontal lobes.

• Received: July 23, 2010 • Revised: December 22, 2010 • Accepted: December 22, 2010

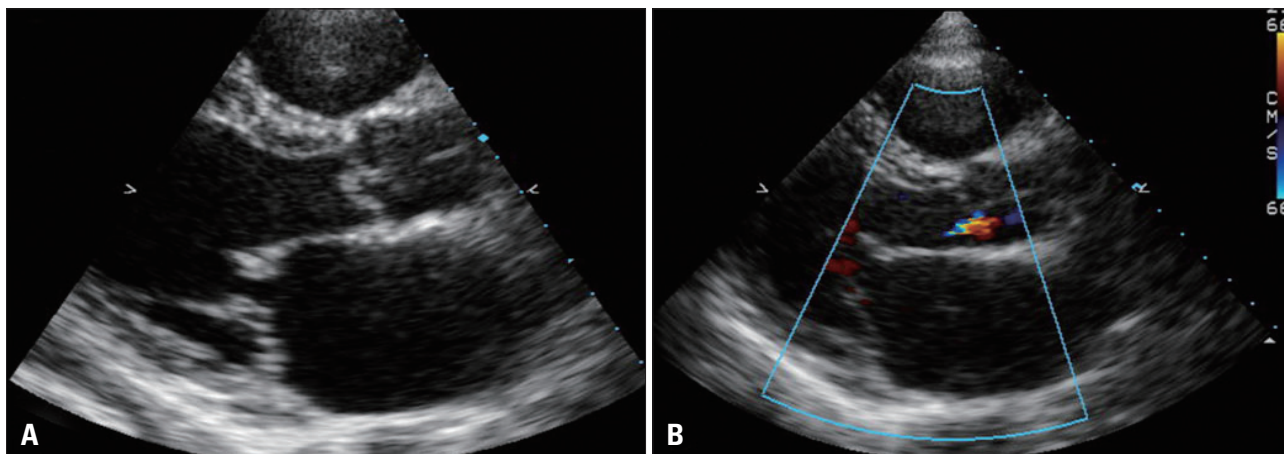
• Address for Correspondence: Sung-Ai Kim, Division of Cardiology, Department of Internal Medicine, Hallym Sacred Heart Hospital, Hallym University College of Medicine, 896 Pyeongchon-dong, Anyang 431-070, Korea Tel: +82-31-380-3977, Fax: +82-31-383-3486, E-mail: 237419@hallym.or.kr

• This is an Open Access article distributed under the terms of the Creative Commons Attribution Non-Commercial License (<http://creativecommons.org/licenses/by-nc/3.0>) which permits unrestricted non-commercial use, distribution, and reproduction in any medium, provided the original work is properly cited.

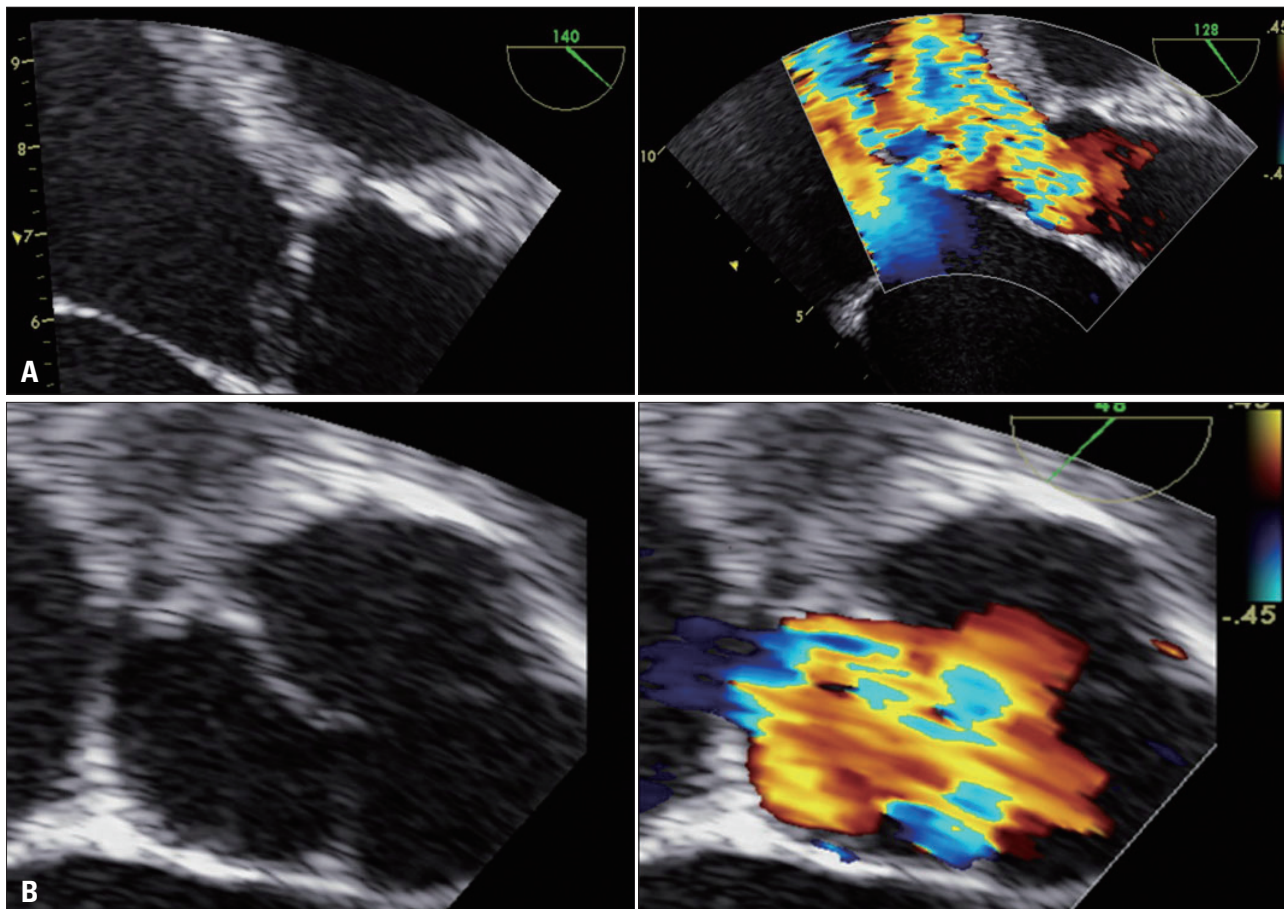
therapy and conservative care, the patient was discharged with symptom improvement.

After 4 months, the patient revisited our hospital with exertional dyspnea for 3 weeks. Physical examination revealed a blood pressure of 130/40 mmHg, a pulse of 70/min with a regular rhythm, a temperature of 36.5°C, and a respiratory rate of 25/min. Cardiac auscultation detected holodiastolic

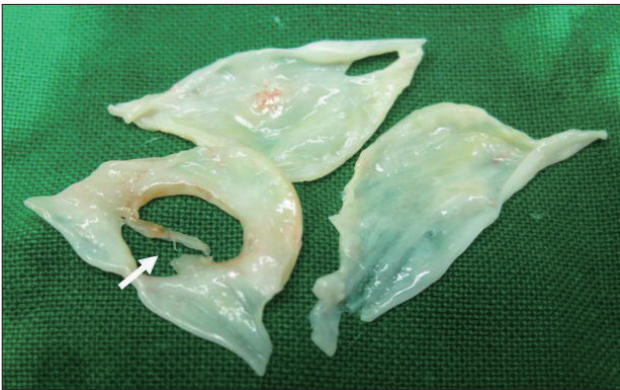
murmur at the left upper sternal border. A chest radiograph showed a significant cardiomegaly with pulmonary congestion and no pneumonic infiltration in both lung fields. Transesophageal echocardiography (TEE) revealed a more progressed prolaptic motion of NCC of AV compared to previous echocardiogram 4 months ago (at the time of diagnosis of bacterial meningitis) and aortic regurgitant flow was significantly



**Fig. 2.** Transthoracic echocardiogram at the first admission with pneumococcal meningitis shows a prolaptic motion of non-coronary cusp (A) with trivial aortic regurgitation (B).



**Fig. 3.** Transesophageal echocardiogram at the second admission with heart failure shows a prolaptic motion of non-coronary cusp (A) with aggravated aortic regurgitation (B).



**Fig. 4.** Post-operative finding of aortic valve revealed a rupture of septated large perforation of non-coronary cusp (NCC) (arrow). The free margin of NCC was diffusely thickened, suggesting healed bacterial endocarditis.

increased from trivial to severe grade of eccentric jet flow (Fig. 3A). In the 45-degree short-axis view of TEE, a perforation of NCC was suggested (Fig. 3B). No perivalvular abscess or vegetation was seen. At the day 11 of admission, hemodynamic status of the patient was deteriorated and the patient underwent replacement surgery on AV. Operative finding of AV revealed a rupture of septated large perforation of NCC and the free margin of NCC was diffusely thickened, suggesting healed bacterial endocarditis (Fig 4). AV was excised and replaced with a prosthesis (ATS prosthetic valve, 23 mm). The patient tolerated the operation and showed an uneventful recovery.

## DISCUSSION

We presented a case of PE with a delayed onset of heart failure in a patient treated with pneumococcal meningitis. Seeing that post-operative finding of AV, small septated perforation of AV in status of healed bacterial endocarditis may gradually increase in size and rupture leading to significant AR and heart failure.

The association of pneumococcal meningitis and endocarditis is referred as Austrian syndrome, in which he presented that 7 of the total 8 patients were initially hospitalized with laboratory and clinical evidences of meningitis, and then recognized PE with a rupture of AV.<sup>4)</sup> In a recent review, most cases of Austrian syndrome are middle-aged man and chronic alcoholics is the most common predisposing factor.<sup>5)</sup> *S. pneumoniae* has a predilection for native valve and the most frequent localization of the vegetation is AV.<sup>4,6)</sup> The clinical course of PE is usually acute and very aggressive, with a high rate of mortality (non-surgical 60%, early surgery 32%) and association with the rupture of AV.<sup>2,4,7)</sup> In most cases of Austrian syndrome, despite adequate antibiotic therapy, PE was acutely progressed and median time of diagnosis was 1 to 7 days after the antibiotic therapy of bacterial meningitis with a newly developed

dyspnea and/or cardiac murmur by valve destruction.<sup>5,7-10)</sup> Subacute evolution is less frequent and often involves mitral endocarditis.<sup>11)</sup> Unusually, delay in diagnosis of PE in this case may be contributed to the subacute evolution with late onset of heart failure. At the first admission for treatment of pneumococcal meningitis, although the patient had no symptom for heart failure and there was only trivial AR and no evidence of vegetation in the TTE, we should have performed a TEE with a suspicion for prolaptic motion of AV in relation to embolic source of multiple cerebral infarctions. Therefore, earlier suspicion for evidence of endocardial lesion was needed to reduce the possible complication as a rupture of AV.

Austrian syndrome is rare clinical entity. However, its clinical course is highly aggressive with the rapid valve destruction and thus this case further emphasizes being all aware of the association of meningitis and endocarditis in patients with pneumococemia.

## REFERENCES

1. Auburtin M, Porcher R, Bruneel F, Scanvic A, Trouillet JL, Bédos JP, Régnier B, Wolff M. *Pneumococcal meningitis in the intensive care unit: prognostic factors of clinical outcome in a series of 80 cases.* *Am J Respir Crit Care Med* 2002;165:713-7.
2. Aronin SI, Mukherjee SK, West JC, Cooney EL. *Review of pneumococcal endocarditis in adults in the penicillin era.* *Clin Infect Dis* 1998;26:165-71.
3. Lefort A, Mainardi JL, Selton-Suty C, Casassus P, Guillemin L, Lortholary O. *Streptococcus pneumoniae endocarditis in adults. A multicenter study in France in the era of penicillin resistance (1991-1998).* *The Pneumococcal Endocarditis Study Group. Medicine (Baltimore)* 2000;79:327-37.
4. Austrian R. *Pneumococcal endocarditis, meningitis, and rupture of the aortic valve.* *AMA Arch Intern Med* 1957;99:539-44.
5. Gonzalez-Juanatey C, Testa A, Mayo J, Gonzalez-Gay MA. *Austrian syndrome: report of two new cases and literature review.* *Int J Cardiol* 2006;108:273-5.
6. Lindberg J, Prag J, Schønheyder HC. *Pneumococcal endocarditis is not just a disease of the past: an analysis of 16 cases diagnosed in Denmark 1986-1997.* *Scand J Infect Dis* 1998;30:469-72.
7. Velazquez C, Araji O, Barquero JM, Perez-Duarte E, Garcia-Borbolla M. *Austrian syndrome: a clinical rarity.* *Int J Cardiol* 2008;127:e36-8.
8. Dalal A, Ahmad H. *Austrian syndrome (pneumococcal pneumonia, meningitis, and endocarditis): a case report.* *Am J Med Sci* 2008;336:354-5.
9. Rammeloo L, Hruda J, Sobotka-Plojhar M, Avis W, Schoof P. *Austrian syndrome in a child-aortic valve endocarditis following pneumococcal meningitis.* *Int J Cardiol* 2004;94:321-2.
10. du Cheyron D, Lesage A, Le Page O, Flais F, Leclercq R, Charbonneau P. *Corticosteroids as adjunctive treatment in Austrian's syndrome (pneumococcal endocarditis, meningitis, and pneumonia): report of two cases and review of the literature.* *J Clin Pathol* 2003;56:879-81.
11. Siles Rubio JR, Anguita Sánchez M, Castillo Domínguez JC, Ramírez Moreno A, Pavlovic D, Berjillos Cortés F, Vallés Belsué F. *Austrian's syndrome (endocarditis, meningitis and pneumonia caused by Streptococcus pneumoniae). Apropos of a rare case.* *Rev Esp Cardiol* 1998;51:1006-8.