



Published in final edited form as:

Biomed Res Clin Rev. 2022 ; 7(2): .

CNS Lymphoma: Clinical Pearls and Management Considerations

Michelot Michel¹, Noelle Lucke-Wold¹, Mohammad Reza Hosseini¹, Eric Panther¹, Ramya Reddy¹, Brandon Lucke-Wold^{1,*}

¹Department of Neurosurgery, University of Florida, Gainesville

Abstract

Primary CNS lymphoma presents unique challenges for the clinician. New evidence has emerged regarding the appropriate workup, management considerations, and treatment. In this paper, we highlight the clinical presentations, disease prognosis, and management considerations. We place specific emphasis on the decision tree for immunocompetent and immunocompromised. The key imaging characteristics are discussed. Once biopsy prove lymphoma, important management considerations are addressed. We highlight need for follow up and role for surgery verse radiation. Finally, we present emerging treatment options and pre-clinical work that will be making its way through the pipeline. This up-to-date review will serve as a key learning tool for clinicians and researchers

Keywords

CNS Lymphoma; management considerations; diagnosis; treatment

Introduction

Primary CNS lymphoma (PCNSL) represents a rare subset of non-Hodgkin lymphoma that is confined to the CNS without systemic involvement. PCNSL accounts for approximately 4% of newly diagnosed CNS tumors [1,2]. In the US, approximately 1500 patients are newly diagnosed each year [3]. PCNSL can arise in both immunocompetent and immunosuppressed patients, such as those with HIV/AIDS, post-transplant patients, and those on other immunosuppressive medications [3,4]. Although it is relatively rare in the immunocompetent population, the incidence rate has increased in recent years, with a predilection for patients over the age of 60 [5].

Clinical Presentations

PCNSL is classically isolated to the brain. Within the brain, it is often found in the periventricular white matter, basal ganglia, and corpus callosum [6]. To a lesser extent it can also arise from the spinal cord, cerebrospinal fluid, leptomeninges, and eyes [7,8].

this is an open-access article distributed under the terms of the Creative Commons Attribution License, which permits unrestricted use, distribution, and reproduction in any medium, provided the original author and source are credited.

*Corresponding Author: Brandon Lucke-Wold, Department of Neurosurgery, University of Florida, Gainesville.

The location of the lesion is the main driver of symptom presentation with up to 80% of patients presenting with focal neurological deficits [9,10]. Other presentations include neuropsychiatric symptoms and signs of elevated intracranial pressure [11]. Compared to other primary CNS lesions, seizures are relatively uncommon [11].

Disease Prognosis

Median overall survival (OS) for patients with untreated PCNSL is approximately 1.5 months [12]. OS rates at 5-years have been reported to be 29.3% [13]. Treatment of PCNSL has traditionally consisted of brain radiation and high-dose methotrexate (HDMTX), with many patients achieving a curative response. Although aggressive treatment and other favorable prognostic factors often lead to a cure, nearly 36% of patients relapse within 2 years of remission [14]. The prognosis of PCNSL relapse after primary radiation and chemotherapy is poor with a previously reported median survival of 2-4 months [15].

Diagnostic Workup

When suspicion arises for primary CNS lymphoma, diagnostic workup (Figure 1) includes imaging, biopsy, serological and cerebrospinal fluid (CSF) analysis, ophthalmologic examination, and evaluation for systemic involvement. We discuss some of the key principles of workup below.

Diagnostic Imaging

Contrast enhanced MRI is the primary imaging modality recommended to evaluate for primary CNS lymphoma. As soon as PCNSL is suspected, an imaging study should be performed. It is common for CT scans and MRI to reveal PCNSL, which is hypercellular, has a high nuclear/cytoplasmic ratio, disrupts blood-brain barriers, and attacks the superficial and periventricular regions of the brain. However, CT negative findings are not an absolute indication of PCNSL because false-negative CTs can also occur [16]. It is recommended to use fluid-attenuated inversion recovery (FLAIR) before and after contrast injection. Traditional sequences include T1WI pre, and post-contrast, FLAIR, T2WI and DWI [17]. Recently, CE-T2W FLAIR shows promise in assessing for subtle leptomeningeal and pachymeningeal disease [18].

The location of the lesion is predominantly supratentorial in the white matter of the frontal or parietal lobes or subependymal regions, although infratentorial lesions have been found to be associated with poorer prognosis and outcomes [19–21]. Other sites affected by primary CNS lymphoma include the eye, spinal cord, nerves, or disseminated systemic involvement [11].

Immunocompetency alters imaging findings

Imaging findings typically vary between immunocompetent patients and immunocompromised patients. Typical findings in immunocompetent patients include intense and homogeneously enhancing single lesions (60–70% of cases) or multiple lesions (30–40% of cases) without necrosis and with relatively minimal edema, usually localized in the periventricular space. In contrast, immunocompromised patients are more likely to have multifocal lesions with irregular or peripheral contrast enhancement in contrast-enhanced

T1 sequences due to the presence of necrotic regions. Hemorrhage is more common in this group; however, is not universally present [22]. This occasionally presents a diagnostic challenge as similar findings are present in immunocompromised patients with cerebral toxoplasmosis or progressive multifocal leukoencephalopathy as well. Thallium 201 single photon emission (SPECT) CT is a helpful adjuvant imaging tool in these clinical situations as increased uptake is observed in CNS lymphoma [23].

AIDS-defining illnesses, including cryptococcosis, can also present with peripherally enhancing cryptococcosis, but they can be distinguished by dilated perivascular spaces with pseudocyst formation and superimposed leptomeningeal enhancement. In addition to ring-enhancing tuberculomas, leptomeningeal enhancement, especially in the basal cisterns, and patchy meningeal enhancement are common findings in CNS tuberculosis [24].

After diagnosis confirmation and treatment initiation, contrast enhanced MRI is routinely performed to evaluate treatment response. The degree of contrast enhancement for these lesions may vary subtly between institutions, magnetic strength (tesla), contrast dosing, timing, and imaging protocols [18]. It is recommended to use the same scanner capabilities and protocols. This should include consistency in contrast dose and administration timing as these subtleties may alter the degree of detected lesion enhancement [18].

Differentiating PCNSL from glioblastoma on imaging

A diffusion-weighted image can be particularly useful in distinguishing PCNSL from other brain tumors, such as glioblastoma, due to PCNSL's high cellularity, which prevents water molecules from diffusing [25]. T1-weighted images frequently indicate hyper- or isointense lesions, whereas T2-weighted images frequently demonstrate isointense or hypointense lesions. Necrosis is common in conventional MR imaging in glioblastoma, while homogeneous enhancement without necrosis indicates PCNSL [26]. The conventional findings may, however, overlap in cases of atypical glioblastoma with or without necrosis and atypical PCNSL with necrosis, resulting in difficult differentiation [27]. Since the histological analysis has indicated that there are distinct differences in the microenvironmental tumor vasculature between these two tumor types [28], it is possible to assess microvascular permeability and neovascularization noninvasively using dynamic contrast-enhanced MRI (DCE) and dynamic susceptibility contrast MRI (DSC) [29]. According to DSC MRI, glioblastoma has a higher cerebral blood volume than PCNSL. Although DSC-MRI agents have a greater effect on T2 than DCE-MRI agents, T2 effects decrease when the agents enter the interstitial space [30], whereas T1 effects persist when they enter the interstitial space. Using pharmacokinetic parameters such as volume transfer constant, extravascular extracellular space, and vascular plasma space, T1-based DCE-MRI can be used to measure microcirculation permeability. As with rCBV, DCE-MRI results for differential diagnosis are not clarified. Some studies have found a higher permeability in PCNSL than in glioblastoma [31].

Differentiating PCNSL from toxoplasmosis on imaging

Primary CNS lymphoma and cerebral toxoplasmosis differ from one another in terms of contrast enhancement dynamics, with primary CNS lymphoma exhibiting delayed

enhancement [32]. Toxoplasmosis is usually detected as multiple nodular or ring-enhancing lesions on a contrast-enhanced CT or MRI scan with associated vasogenic edema often disproportionate to the size of the lesions. The basal ganglia and the frontal and parietal lobes are frequent sites of these lesions [33,34]. As a result of its high cellularity, primary CNS lymphoma often exhibits attenuating or hyperattenuating mass lesions during CT examinations. CT or MRI can reveal round or oval homogeneous contrast enhancement and varying levels of edema within the lesions in a multifocal or periventricular distribution following contrast administration [35]. Signal intensity patterns were described in an MRI study as a means of separating cerebral toxoplasmosis from other diseases, including lymphoma. On contrast-enhanced T1-weighted images, the “eccentric target” sign, consisting of the innermost enhancing eccentric core, intermediate hypointense zone, and peripheral hyperintense enhancing rim, indicates cerebral toxoplasmosis when compared with other parenchymal lesions. The “concentric target” sign has been observed in cerebral toxoplasmosis in one-third of cases [36]. On T2-weighted MRI images, concentric zones of hypo intensity and hyperintensity have been identified, but further confirmation is required [37]. Compared with the previously described target sign on contrast-enhanced T1-weighted images, a target sign visualized on T2-weighted or FLAIR images had a hypointense core, an intermediate hyperintense region, and a peripheral hypointense rim. 71% of the patients in the series had either a T1-weighted or a 2-weighted FLAIR target sign that was contrast-enhanced. According to a study involving 13 patients using dynamic susceptibility contrast-enhanced MRI, lymphomas had significantly higher relative cerebral blood volumes (rCBVs) than toxoplasmosis lesions [38]. Lesions resulting from toxoplasmosis had an average rCBV of 0.98, whereas lymphoma lesions had an average rCBV of 2.07. For image-based lesion segmentation, hemorrhage, micro vessels, and necrosis were excluded. The reason for the difference in rCBV is the absence of vasculature in cerebral toxoplasmosis and the hypervascularity in lymphoma foci [39].

Magnetic resonance spectroscopy

MR spectroscopy can be useful for distinguishing toxoplasmosis from lymphoma. Choline levels (a marker of cellular turnover) are typically decreased in toxoplasmosis lesions, whereas they are typically elevated in CNS lymphomas. As a result, this difference is not reliable for distinguishing cerebral toxoplasmosis from primary CNS lymphoma [40]. Both of these conditions can have overlapping characteristics with peripheral enhancement and restricted diffusion.

Biopsy

In primary CNS lymphoma, tissue biopsy remains the gold standard to establish the diagnosis. The preferred method of biopsy is stereotactic serial rotating approach. An open approach with resection has been associated with worse outcomes due to hemorrhage [11]. In 2016, the World Health Organization (WHO) adjusted its classification to incorporate molecular findings into brain tumor diagnosis. Molecular testing is now mandatory and even trumps histological phenotype [41,42]. Even with this additional available testing, diagnosis of primary CNS lymphoma proves difficult. Cells are small and frequently consist of lymphocytes with variable atypical cytology [43]. This is a primary reason for limiting steroids prior to biopsy to enhance diagnostic yield. Genetic analysis has recently

transitioned to the important role of the JAK-STAT pathway [44]. Particular emphasis has been placed on evaluation of Jak3 and Stat3 and the associated proinflammatory cascade [45]. Other important pathways identified and actively being investigated include NFkB DNA modification, CDKN2A deletions, B-cell receptor signaling, and mutations in MYD88, L265P and CD79B [44].

Ocular Involvement

Ocular involvement of primary CNS lymphoma in the initial stages are primarily asymptomatic. Intraocular involvement has been shown to occur in 15-25% of patients with primary CNS lymphoma¹⁶. The most common symptom observed is decreased visual acuity [46]. Due to the subtle presenting features, a thorough ophthalmologic exam with the use of slit lamp and fundoscopy is recommended but not routinely performed [47]. If exam findings are concerning, vitrectomy is recommended [46]. If vitreous biopsy is inconclusive, a chorioretinal biopsy can be used to exclude malignancy [17,18]. Chorioretinal biopsy can either be done through a transvitreal approach or transscleral approach [19].

Additional Diagnostics and Considerations

Presently, there are no serological studies that are clearly diagnostic for primary CNS lymphoma, although biomarkers are currently being investigated based on the inflammatory pathways highlighted above. As primary CNS lymphoma is associated with late HIV/AIDS illness, testing for HIV/AIDS status and CD4 counts is imperative during diagnostic workup [48,49]. Although a nonspecific marker of rapid cell turnover, elevated serum lactate dehydrogenase is associated with poor prognosis with primary CNS lymphoma [50], but otherwise due to poor specificity, has no diagnostic value.

Cerebrospinal fluid analysis

Cerebrospinal fluid (CSF) analysis is recommended but not required in all instances of primary CNS lymphoma [51]. Routine indices for CSF samples include cell count, protein, and glucose [8]. CSF cell counts and protein are normal in 33-60% of patients with primary CNS lymphoma [9–12]. Additionally, CNS lymphoma may show low CSF glucose (<73 mg/dL) [8–13]. Cytology of CSF fluid in suspected CNS lymphoma may also show irregularities such as large (>2.5 times normal), neoplastic, lymphoid cells [8–14].

CSF evaluation is more pertinent in cases of leptomeningeal involvement or where biopsy is not feasible. Of note, baseline diagnostic imaging should be performed prior to performing lumbar puncture to rule out risk of herniation and to prevent induction of seeding if dural enhancement noted [52]. Recommended studies include CSF protein, glucose, and a combination of both flow cytometry and cytology. CSF protein counts are commonly elevated whereas CSF glucose counts are noted to be decreased [50–53]. Individually, flow cytometry and cytology have poor sensitivity and specificity as lymphocytes can rarely be detected in CSF. To increase sensitivity, it is advised to combine cytology and flow cytometry and to collect more than 10.5 cc of CSF for flow cytometry alone [51–54]. When diagnostic uncertainty exists in patients with HIV/AIDS, Epstein Barr virus polymerase-chain reaction (PCR) may also prove helpful as it has a higher sensitivity and is commonly associated with primary CNS lymphoma in immunocompromised populations [23,48,55].

Emerging research has unveiled new CSF biomarkers that could accelerate diagnosis and reduce risks associated with biopsy. These CSF biomarkers include: A proliferation-inducing ligand (APRIL), B cell activating factor (BAFF), transmembrane activator and soluble CAML interaction (s-TACI), soluble B-cell maturation antigen (s-BCMA), and interleukin-10 [50–56]. Although these biomarkers show promise, further investigation with independent cohorts is needed before routine testing for diagnosis can be established.

Evaluation of systemic disease

To exclude the presence of systemic involvement, bone marrow aspiration and systemic imaging should be performed [51,60]. Bone marrow aspiration is not necessary for disease diagnosis in every case as the likelihood for positive marrow aspirate result is low [60]. Another alternative is CT Chest, Abdomen, and Pelvis or PET-CT Whole Body for staging purposes to assess systemic spread [61]. These studies can miss spread to the testes however and groups have argued that testicular ultrasound should be performed in men greater than 60 years old as well [49]. As testicular involvement is rare, having a cut off of age 60 increases diagnostic yield [62].

Role of corticosteroids in PCNSL management

In the acute stages of establishing diagnosis, as alluded to above, it is critical to avoid corticosteroids. If they had already been started by a provider not familiar with lymphoma workup, taper down to the lowest dose possible as quickly as possible. Exposure to corticosteroids causes cytolysis within lymphocytes and has been reported to negatively impact accurate tissue biopsy and flow cytometry of both vitreous aspirate and CSF [63]. In addition, it can also decrease contrast enhancement of the lesions on MRI [59,63].

High dose methotrexate as first-line chemotherapy

For newly diagnosed PCNSL, induction chemotherapy is generally used to achieve a complete radiographic response (CR), which is then followed by consolidation therapy with the goal of eliminating residual disease and prolonging OS. There are several methods of medical management that still need further evaluation via prospective trials. However, the current first-line treatment (Table 1) standard is HDMTX-based induction chemotherapy [12,24]. Methotrexate is an antifolate and antimetabolite, which is now considered to be the single most beneficial agent that crosses the BBB and yields cytotoxic levels in CSF [65]. However, there is no consensus on the optimal dose, schedule, or chemotherapy combination. HDMTX is typically given via intravenous infusions at doses ranging from 3-8 g/m² and for 10 days to no more than 2 to 3 weeks^{65,66}. Overall, response rates ranged from 35% to 74%, with median progression-free survival (PFS) of 10 to 12.8 months, and median OS of 25 to 55 months with HDMTX treatment [66–69].

Alternative chemotherapeutic combinations

Chemotherapeutic agents should include those known to cross the BBB [65]. Some prominent examples include cytarabine, temozolomide, rituximab, procarbazine, thiopeta, vincristine, carmustine, etoposide, ifosfamide, and cyclophosphamide [12]. Combo therapy of cytarabine and HDMTX showed an improved CR rate, 3-year PFS, and 3-year OS

compared to HDMTX alone [70]. Rituximab alone or in a combination regimen is still being tested in clinical trials [12,65]. It does have some limitations in terms of penetrating the BBB due to its large size, and thus is thought to be more effective early in treatment due to BBB breakdown within tumors [65]. However, HDMTX and rituximab combo therapy has been shown to improve CR and OS rate in newly diagnosed PCNSL in retrospective studies [71–73]. Furthermore, intrathecal chemotherapy has not been prospectively studied. Retrospective studies also did not demonstrate any additional benefit from adding intrathecal drugs in patients treated with 3 g/m² HDMTX [74–76]. Thus, its efficacy in PCNSL treatment is not clear and not currently advised as prophylaxis [65]. The paucity in evidence will require more investigation as to the efficacy of intrathecal chemotherapy. **Lastly**, another option is to add autologous stem cell transplantation (ASCT) or reduced-dose whole brain radiotherapy (WBRT) with first-line HDMTX.

Radiotherapy

Transitioning to the use of radiotherapy, it is important to note that the microscopically diffuse nature of PCNSL makes radiotherapy less effective than HDMTX as a standalone therapy [65]. One phase II clinical trial resulted in only an 11.6-month OS after a total dose of 40 Gy (with an additional 20 Gy to boost contrast enhancing lesions) [67]. In addition to inadequately controlling the progression of PCNSL, WBRT also leads to delayed neurotoxicity. This presents as white matter abnormalities, ventricular enlargement, and cortical atrophy on MRI. These neurocognitive deficits are particularly severe in the elderly [12,78]. A significant decline in the Karnofsky Performance Status Scale (20-50 points) with a marked reduction in quality of life has been observed in several studies following WBRT, especially in elderly populations [78,79]. While the mechanism of neurotoxicity is unclear, leading hypotheses include potential toxicity to vasculature, demyelination, or depletion of neural progenitor cells from the subventricular zone [80–82]. WBRT neurotoxicity is irreversible and is not used for newly diagnosed PCNSL. Thus, the consensus is to avoid WBRT as a standalone therapy, especially in elderly populations due to its delayed neurotoxic effects [65]. Reduced-dose WBRT in combination with HDMTX as first line therapy can be used in younger patients [12,64]. While the optimal dose has not yet been agreed upon, doses of 23–50 Gy to the whole brain, with or without a tumor bed boost, are currently used, with most protocols delivering a total dose of [40–45] Gy without boost, and standard fractionation (1.8-2 Gy/fraction) [65].

Autologous Stem Cell Transplantation (ASCT)

Another modality is high dose chemotherapy with ASCT (HDC/ASCT). Similar to radiotherapy, further investigation is needed to see if HDC/ASCT can be used as a first-line consolidation treatment for PCNSL. However, HDC/ASCT is an efficacious treatment in relapsed or refractory PCNSL, especially as salvage treatment in elderly patients [64,65]. In summary, while HDMTX is the agreed upon first line treatment for newly diagnosed PCNSL, it is recommended to use it in combination with other chemotherapeutic agents and possibly reduced-dose WBRT or ASCT, as these combinations show more disease control with less neurotoxicity as compared to WBRT alone [12].

Management considerations in elderly population

The previous discussions primarily focused on newly diagnosed PCNSL in younger populations. Best treatment protocols for elderly populations and refractory/relapsed PCNSL will now be explored. More than half of all PCNSL cases is in patients greater than 60 years old, making age itself a poor prognostic factor. Thus, it is important to avoid or at least defer WBRT until relapsed PCNSL due to the higher risk of neurotoxicity in elderly patients. Instead, HDMTX combination chemotherapy is considered the first-line treatment [12]. Unfortunately, more than half of HD-MTX responders' relapse with very poor prognosis, proving the need for regular neuroimaging after initial treatment [12]. One retrospective study showed the median OS was 2 months for primary refractory patients and 3.7 months for patients who relapsed within the first year of the initial therapy [83].

Salvage therapy and novel chemotherapeutic agents

There is no clear data on a single optimal protocol for salvage treatments. Salvage treatments (Table 1) depend highly on a patient's individual prognostic factors such as their age, previous treatments (and their responses), and comorbidities at the time of relapse [12]. Similar conclusions arise, however, in that monotherapies seem to be ineffective in relapsed/refractory disease, similar to newly diagnosed PCNSL. For example, when evaluating rituximab's efficacy as a monotherapy (up to 8 weekly doses of 375 mg/m²) in a single study of 12 patients with refractory or relapsed PCNSL, results showed responses detected via MRI in 36% of patients [65,84]. One option is to use HDMTX again if the patient previously showed a prolonged response to it. Evidence for this lies in retrospective studies, reporting response rates between 85% and 91% and median OS times of 41-62 months [85,86]. In younger patients with good performance status who did not receive high-dose chemotherapy or prior ASCT, an alternative option is to use ASCT. This seems to be more effective in younger patients who had more chemo-sensitive disease [87]. Lastly, there are several agents being investigated. Some target PD-1 based on observed PD-1 activity in other lymphomas while others are Bruton's tyrosine kinase (BTK) inhibitors. A few examples include nivolumab and ibrutinib among several others [87,89].

Recent advancements in clinical trials

Despite high relapse rates and associated neurotoxicity of treatment modalities, recent clinical trials have shown promising advancements in the treatment of this aggressive disease. Frigault et al. demonstrated the safety and efficacy of tisagenlecleucel (CD19-directed chimerical antigen receptor T-cell product) in patients with refractory PCNSL [13]. Other recent clinical trials have highlighted the safety and prospective optimal use of chemotherapeutic agents such as thiotepa [90], temozolomide [91], and pemetrexed [92] in the treatment of PCNSL [93–96]. Furthermore, innovative solutions to tackling difficulties in crossing the blood-brain barrier have been highlighted in recent studies. R-CHOP (rituximab, cyclophosphamide, doxorubicin, vincristine, and prednisone) is the mainstay of treatment in systemic diffuse large B cell lymphoma. It has not been utilized in the treatment of PCNSL due to difficulties with these agents in crossing the blood-brain barrier. Ferreri et al. recently showed that administration of R-CHOP preceded by NGR-hTNF (tumor necrosis- α coupled with the CD13+ vessel targeting peptide, NGR) showed

promising responses and a better ability of these agents to enter the CNS, highlighting the potential of an expanded chemotherapeutic arsenal against PCNSL [97,98].

Surgical resection of lesion

Historically, surgical resection of lymphoma has been associated with worse outcomes [11,99] However, more recent studies of biopsy with surgical resection have pointed to lower complication rates and improved survival [100–102]. This may be credited to the development of improved imaging modalities and neurosurgical equipment as well as the use of adjuvant radiotherapy and methotrexate/R-CHOP therapy [103].

Role of Ommaya Reservoir as a diagnostic and therapeutic tool

Prophylactic intrathecal chemotherapy can be administered to reduce CNS relapse. Intrathecal chemotherapy has historically been administered via lumbar puncture in the lumbosacral cerebrospinal fluid (CSF) space [104]. The Ommaya reservoir is a device that sits between the cranium and the skin with a catheter extending into one of the lateral ventricles [105]. This site can be used to sample CSF and as an intrathecal chemotherapy delivery point [104].

There are many advantages to the Ommaya reservoir (Figure 2) over lumbar puncture. First, Ommaya reservoirs deliver chemotherapeutics directly to the cerebral area rather than relying on CSF circulation from the lumbar region. Secondly, lumbar puncture can be a challenging procedure in patients with spinal deformities and obesity [104] Ommaya reservoirs have the advantage of being very efficient and simple to use when compared to repeated lumbar punctures [104] One study on children receiving chemotherapy through both the lumbosacral route and the intraventricular route (Ommaya reservoir) found that the patients strongly preferred the Ommaya device to repeated lumbar puncture [106].

Potential complications associated with the use of the Ommaya reservoir include bacterial infection and catheter misplacement [104]. Bacterial CNS infection associated with Ommaya reservoir placement is quite rare at 1-5.5% [107,108]. Catheter misplacement into the brain parenchyma used to be much more common. Ommaya catheter placement into the parenchyma could lead to focal leukoencephalopathy [104]. However, advancements in imaging and neurosurgical technology have led to a significant reduction in this complication.

Conclusion

PCNSL represents a rare and aggressive disease with poor prognosis. While it is most commonly diagnosed in the immunocompetent patient, studies have shown an increasing incidence of this diagnosis in the elderly population. Diagnosis revolves around initial imaging followed by stereotactic biopsy. In comparison to other primary CNS lesions, resection is generally not recommended, although there is limited evidence showing benefit given advances in neurosurgical technology and technique. Despite a generally favorable response to first line therapy with high dose methotrexate, PCNSL has a high relapse/refractory disease rate which is associated with a worse prognosis. Although much of the current literature regarding management is limited to retrospective studies, recent clinical

trials are showing promise and an expanded arsenal of therapeutic agents ranging from immunotherapy to agents that increase permeability of the blood-brain barrier. This is especially important given that there is a host of chemotherapy drugs such as R-CHOP that have been proven effective in systemic disease. Further studies will need to be conducted to better assess the efficacy and safety profile of these emerging regimens.

References

1. Hoffman S, Propp JM, (2006). McCarthy BJ. Temporal trends in incidence of primary brain tumors in the United States, 1985-1999. *Neuro Oncol.* 8(1):27–37. [PubMed: 16443945]
2. Villano JL, Koshy M, Shaikh H, Dolecek TA, McCarthy BJ. (2011). Age, gender, and racial differences in incidence and survival in primary CNS lymphoma. *Br J Cancer.* 105(9):1414–1418. [PubMed: 21915121]
3. Lukas RV, Stupp R, Gondi V, Raizer JJ. (2018). Primary Central Nervous System Lymphoma-PART 1: Epidemiology, Diagnosis, Staging, and Prognosis. *Oncology (Williston Park).* 32(1):17–22. [PubMed: 29447417]
4. Gibson TM, Morton LM, Shiels MS, Clarke CA, Engels EA. (2014). Risk of non-Hodgkin lymphoma subtypes in HIV-infected people during the HAART era: a population-based study. *Aids.* 28(15):2313–2318. [PubMed: 25111081]
5. Liu Y, Yao Q, Zhang F. (2021). Diagnosis, prognosis and treatment of primary central nervous system lymphoma in the elderly population (Review). *Int J Oncol.* 58(3):371–387. [PubMed: 33650642]
6. Küker W, Nägele T, Korfel A, et al. (2005). Primary central nervous system lymphomas (PCNSL): MRI features at presentation in 100 patients. *J Neurooncol.* 72(2):169–177. [PubMed: 15925998]
7. Herrlinger U (1999). Primary CNS lymphoma: findings outside the brain. *J Neurooncol.* 43(3):227–230. [PubMed: 10563427]
8. Grimm SA, Pulido JS, Jahnke K, et al. (2007). Primary intraocular lymphoma: an International Primary Central Nervous System Lymphoma Collaborative Group Report. *Ann Oncol.* 18(11):1851–1855. [PubMed: 17804469]
9. Giannini C, Dogan A, Salomão DR. (2014). CNS lymphoma: a practical diagnostic approach. *J Neuropathol Exp Neurol.* 73(6):478–494. [PubMed: 24806301]
10. Wang CC, Carnevale J, Rubenstein JL. (2014). Progress in central nervous system lymphomas. *Br J Haematol.* 166(3):311–325. [PubMed: 24837460]
11. Bataille B, Delwail V, Menet E, et al. (2000). Primary intracerebral malignant lymphoma: report of 248 cases. *J Neurosurg.* 92(2):261–266. [PubMed: 10659013]
12. Han CH, Batchelor TT. (2017). Diagnosis and management of primary central nervous system lymphoma. *Cancer.* 123(22):4314–4324. [PubMed: 28950405]
13. Frigault MJ, Dietrich J, Gallagher K, et al. (2022). Safety and efficacy of tisagenlecleucel in primary CNS lymphoma: a phase 1/2 clinical trial. *Blood.* 139(15):2306–2315. [PubMed: 35167655]
14. Jahnke K, Thiel E, Martus P, et al. (2006). Relapse of primary central nervous system lymphoma: clinical features, outcome and prognostic factors. *J Neurooncol.* 80(2):159–165. [PubMed: 16699873]
15. DeAngelis LM. (1999). Primary CNS lymphoma: treatment with combined chemotherapy and radiotherapy. *J Neurooncol.* 43(3):249–257. [PubMed: 10563431]
16. Haldorsen I, Espeland A, Larsson E-M. (2011). Central nervous system lymphoma: characteristic findings on traditional and advanced imaging. *American Journal of Neuroradiology.* 32(6):984–992. [PubMed: 20616176]
17. Shi YL, Zhao XX, Liu F. (2020). [Qualitative study on the cognition of acquired immunodeficiency syndrome occupational protection among the managers of multi-level stomatology medical institutions]. *Hua Xi Kou Qiang Yi Xue Za Zhi.* 38(4):410–414. [PubMed: 32865360]

18. Barajas RF, Politi LS, Anzalone N, et al. (2021). Consensus recommendations for MRI and PET imaging of primary central nervous system lymphoma: guideline statement from the International Primary CNS Lymphoma Collaborative Group (IPCG). *Neuro Oncol.* 23(7):1056–1071. [PubMed: 33560416]
19. Slone HW, Blake JJ, Shah R, Guttikonda S, Bourekas EC. (2005). CT and MRI findings of intracranial lymphoma. *AJR Am J Roentgenol.* 184(5):1679–1685. [PubMed: 15855138]
20. van Haeften TW, Veneman TF, Gerich JE, van der Veen EA. (1991). Influence of gliclazide on glucose-stimulated insulin release in man. *Metabolism.* 40(7):751–755. [PubMed: 1870430]
21. Tabouret E, Houillier C, Martin-Duverneuil N, et al. (2017). Patterns of response and relapse in primary CNS lymphomas after first-line chemotherapy: imaging analysis of the ANOCEF-GOELAMS prospective randomized trial. *Neuro Oncol.* 19(3):422–429. [PubMed: 27994065]
22. Haldorsen IS, Espeland A, Larsson EM. (2011). Central nervous system lymphoma: characteristic findings on traditional and advanced imaging. *AJNR Am J Neuroradiol.* 32(6):984–992. [PubMed: 20616176]
23. Hussain FS, Hussain NS. (2016). Clinical Utility of Thallium-201 Single Photon Emission Computed Tomography and Cerebrospinal Fluid Epstein-Barr Virus Detection Using Polymerase Chain Reaction in the Diagnosis of AIDS-Related Primary Central Nervous System Lymphoma. *Cureus.* 8(5): e606. [PubMed: 27330874]
24. Marcus C, Feizi P, Hogg J, et al. (2020). Imaging in differentiating cerebral toxoplasmosis and primary CNS lymphoma with special focus on FDG PET/CT. *AJR Am J Roentgenol.* 216:157–164. [PubMed: 33112669]
25. Schlegel U Primary CNS Lymphoma *Ther Adv Neurol Disord* 2009; 2 (2): 93–104. Received on September. 2011;12.
26. Kang KM, Choi SH, Chul-Kee P, et al. (2021). Differentiation between glioblastoma and primary CNS lymphoma: application of DCE-MRI parameters based on arterial input function obtained from DSC-MRI. *European Radiology.* 31(12):9098–9109. [PubMed: 34003350]
27. Al-Okaili RN, Krejza J, Woo JH, et al. (2007). Intraaxial brain masses: MR imaging–based diagnostic strategy-initial experience. *Radiology.* 243(2):539–550. [PubMed: 17456876]
28. Kickingereder P, Sahm F, Wiestler B, et al. (2014). Evaluation of microvascular permeability with dynamic contrast-enhanced MRI for the differentiation of primary CNS lymphoma and glioblastoma: radiologic-pathologic correlation. *American journal of neuroradiology.* 35(8):1503–1508. [PubMed: 24722313]
29. Hartmann M, Heiland S, Harting I, et al. (2003). Distinguishing of primary cerebral lymphoma from high-grade glioma with perfusion-weighted magnetic resonance imaging. *Neuroscience letters.* 338(2):119–122. [PubMed: 12566167]
30. You S-H, Choi SH, Kim TM, et al. (2018). Differentiation of high-grade from low-grade astrocytoma: improvement in diagnostic accuracy and reliability of pharmacokinetic parameters from DCE MR imaging by using arterial input functions obtained from DSC MR imaging. *Radiology.* 286(3):981–991. [PubMed: 29244617]
31. Lu S, Gao Q, Yu J, et al. (2016). Utility of dynamic contrast-enhanced magnetic resonance imaging for differentiating glioblastoma, primary central nervous system lymphoma and brain metastatic tumor. *European journal of radiology.* 85(10):1722–1727. [PubMed: 27666608]
32. Goldstein MA, Naidich TP, Silverman ME. (2009). Clinical importance of delayed MRI contrast enhancement of primary central nervous system lymphoma in AIDS. *Case Reports.* 2009:bcr1020081043.
33. Navia BA, Petito CK, Gold JW, Cho ES, Jordan BD, Price RW. (1986). Cerebral toxoplasmosis complicating the acquired immune deficiency syndrome: clinical and neuropathological findings in 27 patients. *Annals of neurology.* 19(3):224–238. [PubMed: 3963767]
34. Porter SB, Sande MA. (1992). Toxoplasmosis of the central nervous system in the acquired immunodeficiency syndrome. *New England Journal of Medicine.* 327(23):1643–1648. [PubMed: 1359410]
35. Lee Y-Y, Bruner JM, Van Tassel P, Libshitz HI. (1986). Primary central nervous system lymphoma: CT and pathologic correlation. *American journal of neuroradiology.* 7(4):599–604.

36. Kumar GS, Mahadevan A, Guruprasad A, et al. (2010). Eccentric target sign in cerebral toxoplasmosis: neuropathological correlate to the imaging feature. *Journal of Magnetic Resonance Imaging*. 31(6):1469–1472. [PubMed: 20512900]
37. Mahadevan A, Ramalingaiah AH, Parthasarathy S, Nath A, Ranga U, Krishna SS. (2013). Neuropathological correlate of the “concentric target sign” in MRI of HIV-associated cerebral toxoplasmosis. *Journal of Magnetic Resonance Imaging*. 38(2):488–495. [PubMed: 23440973]
38. Dibble EH, Boxerman JL, Baird GL, Donahue JE, Rogg JM. (2017). Toxoplasmosis versus lymphoma: cerebral lesion characterization using DSC-MRI revisited. *Clinical Neurology and Neurosurgery*. 152:84–89. [PubMed: 27940418]
39. Ernst TM, Chang L, Witt MD, et al. (1998). Cerebral toxoplasmosis and lymphoma in AIDS: perfusion MR imaging experience in 13 patients. *Radiology*. 208(3):663–669. [PubMed: 9722843]
40. Chinn R, Wilkinson ID, Hall-Craggs MA, et al. (1995). Toxoplasmosis and primary central nervous system lymphoma in HIV infection: diagnosis with MR spectroscopy. *Radiology*. 197(3):649–654. [PubMed: 7480733]
41. Louis DN, Perry A, Reifenberger G, et al. (2016). The 2016 World Health Organization Classification of Tumors of the Central Nervous System: a summary. *Acta Neuropathol*. 131(6):803–820. [PubMed: 27157931]
42. Louis DN, Perry A, Wesseling P, et al. (2021). The 2021 WHO Classification of Tumors of the Central Nervous System: a summary. *Neuro Oncol*. 23(8):1231–1251. [PubMed: 34185076]
43. Menon MP, Nicolae A, Meeker H, et al. (2015). Primary CNS T-cell Lymphomas: A Clinical, Morphologic, Immunophenotypic, and Molecular Analysis. *Am J Surg Pathol*. 39(12):1719–1729. [PubMed: 26379152]
44. Radke J, Ishaque N, Koll R, et al. (2022). The genomic and transcriptional landscape of primary central nervous system lymphoma. *Nat Commun*. 13(1):2558. [PubMed: 35538064]
45. Weerasinghe D, Menon P, Vucic S. (2017). Hyperpolarization-activated cyclic-nucleotide-gated channels potentially modulate axonal excitability at different thresholds. *J Neurophysiol*. 118(6):3044–3050. [PubMed: 28904107]
46. Hong JT, Chae JB, Lee JY, Kim JG, Yoon YH. (2011). Ocular involvement in patients with primary CNS lymphoma. *J Neurooncol*. 102(1):139–145. [PubMed: 20658258]
47. Abrey LE, Batchelor TT, Ferreri AJ, et al. (2005). Report of an international workshop to standardize baseline evaluation and response criteria for primary CNS lymphoma. *J Clin Oncol*. 23(22):5034–5043. [PubMed: 15955902]
48. Brandsma D, Bromberg JEC. (2018). Primary CNS lymphoma in HIV infection. *Handb Clin Neurol*. 152:177–186. [PubMed: 29604975]
49. Scott BJ, Douglas VC, Tihan T, Rubenstein JL, Josephson SA. (2013). A systematic approach to the diagnosis of suspected central nervous system lymphoma. *JAMA Neurol*. 70(3):311–319. [PubMed: 23319132]
50. Ferreri AJ, Blay JY, Reni M, et al. (2003). Prognostic scoring system for primary CNS lymphomas: the International Extranodal Lymphoma Study Group experience. *J Clin Oncol*. 21(2):266–272. [PubMed: 12525518]
51. Altube A, Ceres V, Malusardi C, et al. (2022). Multiparametric Flow Cytometry versus Conventional Cytology in the Study of Leptomeningeal Involvement in Malignant Hematological Diseases. *Lab Med*.
52. DeAngelis LM, Boutros D. (2005). Leptomeningeal metastasis. *Cancer Invest*. 23(2):145–154. [PubMed: 15813508]
53. Ayuso-Peralta L, Orti-Pareja M, Zurdo-Hernandez M, et al. (2001). Cerebral lymphoma presenting as a leukoencephalopathy. *J Neurol Neurosurg Psychiatry*. 71(2):243–246. [PubMed: 11459903]
54. Perske C, Nagel I, Nagel H, Strik H. (2011). CSF cytology--the ongoing dilemma to distinguish neoplastic and inflammatory lymphocytes. *Diagn Cytopathol*. 39(8):621–626. [PubMed: 21761583]
55. Wallace JL, Steel G, Whittle BJ. (1987). Gastrointestinal plasma leakage in endotoxic shock. Inhibition by prostaglandin E2 and by a platelet-activating factor antagonist. *Can J Physiol Pharmacol*. 65(7):1428–1432. [PubMed: 3478114]

56. Mulazzani M, Huber M, Borchard S, et al. (2019). APRIL and BAFF: novel biomarkers for central nervous system lymphoma. *J Hematol Oncol.* 12(1):102. [PubMed: 31615554]
57. Thaler FS, Laurent SA, Huber M, et al. (2017). Soluble TACI and soluble BCMA as biomarkers in primary central nervous system lymphoma. *Neuro Oncol.* 19(12):1618–1627. [PubMed: 28521029]
58. Wang L, Luo L, Gao Z, et al. (2017). The diagnostic and prognostic value of interleukin-10 in cerebrospinal fluid for central nervous system lymphoma: a meta-analysis. *Leuk Lymphoma.* 58(10):2452–2459. [PubMed: 28278715]
59. Balmaceda C, Gaynor JJ, Sun M, Gluck JT, DeAngelis LM. (1995). Leptomeningeal tumor in primary central nervous system lymphoma: recognition, significance, and implications. *Ann Neurol.* 38(2):202–209. [PubMed: 7654067]
60. von Baumgarten L, Illerhaus G, Korfel A, Schlegel U, Deckert M, Dreyling M. (2018). The Diagnosis and Treatment of Primary CNS Lymphoma. *Dtsch Arztebl Int.* 115(25):419–426. [PubMed: 29999484]
61. Ferreri AJ, Reni M, Zoldan MC, Terreni MR, Villa E. (1996). Importance of complete staging in non-Hodgkin's lymphoma presenting as a cerebral mass lesion. *Cancer.* 77(5):827–833. [PubMed: 8608471]
62. O'Neill BP, Dinapoli RP, Kurtin PJ, Habermann TM. (1995). Occult systemic non-Hodgkin's lymphoma (NHL) in patients initially diagnosed as primary central nervous system lymphoma (PCNSL): how much staging is enough? *J Neurooncol.* 25(1):67–71. [PubMed: 8523091]
63. Bruck W, Brunn A, Klapper W, et al. (2013). [Differential diagnosis of lymphoid infiltrates in the central nervous system: experience of the Network Lymphomas and Lymphomatoid Lesions in the Nervous System]. *Pathologe.* 34(3):186–197. [PubMed: 23471726]
64. Houillier C, Soussain C, Ghesquière H, et al. (2020). Management and outcome of primary CNS lymphoma in the modern era: An LOC network study. *Neurology.* 94(10): e1027–e1039. [PubMed: 31907289]
65. Hoang-Xuan K, Bessell E, Bromberg J, et al. (2015). Diagnosis and treatment of primary CNS lymphoma in immunocompetent patients: guidelines from the European Association for Neuro-Oncology. *Lancet Oncol.* 16(7): e322–332. [PubMed: 26149884]
66. Bühring U, Herrlinger U, Krings T, Thiex R, Weller M, Küker W. (2001). MRI features of primary central nervous system lymphomas at presentation. *Neurology.* 57(3):393–396. [PubMed: 11515505]
67. Batchelor T, Carson K, O'Neill A, et al. (2003). Treatment of primary CNS lymphoma with methotrexate and deferred radiotherapy: a report of NABTT 96-07. *J Clin Oncol.* 21(6):1044–1049. [PubMed: 12637469]
68. Gerstner ER, Carson KA, Grossman SA, Batchelor TT. (2008). Long-term outcome in PCNSL patients treated with high-dose methotrexate and deferred radiation. *Neurology.* 70(5):401–402. [PubMed: 18227422]
69. Herrlinger U, Küker W, Uhl M, et al. (2005). NOA-03 trial of high-dose methotrexate in primary central nervous system lymphoma: final report. *Ann Neurol.* 57(6):843–847. [PubMed: 15929034]
70. Ferreri AJ, Reni M, Foppoli M, et al. (2009). High-dose cytarabine plus high-dose methotrexate versus high-dose methotrexate alone in patients with primary CNS lymphoma: a randomised phase 2 trial. *Lancet.* 374(9700):1512–1520. [PubMed: 19767089]
71. Birnbaum T, Stadler EA, von Baumgarten L, Straube A. (2012). Rituximab significantly improves complete response rate in patients with primary CNS lymphoma. *J Neurooncol.* 109(2):285–291. [PubMed: 22570142]
72. Gregory G, Arumugaswamy A, Leung T, et al. (2013). Rituximab is associated with improved survival for aggressive B cell CNS lymphoma. *Neuro Oncol.* 15(8):1068–1073. [PubMed: 23502429]
73. Holdhoff M, Ambady P, Abdelaziz A, et al. (2014). High-dose methotrexate with or without rituximab in newly diagnosed primary CNS lymphoma. *Neurology.* 83(3):235–239. [PubMed: 24928128]

74. Pirotte B, Levivier M, Goldman S, Brucher JM, Brotchi J, Hildebrand J. (1997). Glucocorticoid-induced long-term remission in primary cerebral lymphoma: case report and review of the literature. *J Neurooncol.* 32(1):63–69. [PubMed: 9049864]
75. Brück W, Brunn A, Klapper W, et al. (2013). [Differential diagnosis of lymphoid infiltrates in the central nervous system: experience of the Network Lymphomas and Lymphomatoid Lesions in the Nervous System]. *Pathologe.* 34(3):186–197. [PubMed: 23471726]
76. Porter AB, Giannini C, Kaufmann T, et al. (2008). Primary central nervous system lymphoma can be histologically diagnosed after previous corticosteroid use: a pilot study to determine whether corticosteroids prevent the diagnosis of primary central nervous system lymphoma. *Ann Neurol.* 63(5):662–667. [PubMed: 18481293]
77. Nelson DF, Martz KL, Bonner H, et al. (1992). Non-Hodgkin's lymphoma of the brain: can high dose, large volume radiation therapy improve survival? Report on a prospective trial by the Radiation Therapy Oncology Group (RTOG): RTOG 8315. *Int J Radiat Oncol Biol Phys.* 23(1):9–17. [PubMed: 1572835]
78. Correa DD, Shi W, Abrey LE, et al. (2012). Cognitive functions in primary CNS lymphoma after single or combined modality regimens. *Neuro Oncol.* 14(1):101–108. [PubMed: 22013168]
79. Hottinger AF, DeAngelis LM, Yahalom J, Abrey LE. (2007). Salvage whole brain radiotherapy for recurrent or refractory primary CNS lymphoma. *Neurology.* 69(11):1178–1182. [PubMed: 17846417]
80. Chari DM, Huang WL, Blakemore WF. (2003). Dysfunctional oligodendrocyte progenitor cell (OPC) populations may inhibit repopulation of OPC depleted tissue. *J Neurosci Res.* 73(6):787–793. [PubMed: 12949904]
81. Lai R, Abrey LE, Rosenblum MK, DeAngelis LM. (2004). Treatment-induced leukoencephalopathy in primary CNS lymphoma: a clinical and autopsy study. *Neurology.* 62(3):451–456. [PubMed: 14872029]
82. Monje ML, Vogel H, Masek M, Ligon KL, Fisher PG, Palmer TD. (2007). Impaired human hippocampal neurogenesis after treatment for central nervous system malignancies. *Ann Neurol.* 62(5):515–520. [PubMed: 17786983]
83. Langner-Lemercier S, Houillier C, Soussain C, et al. (2016). Primary CNS lymphoma at first relapse/progression: characteristics, management, and outcome of 256 patients from the French LOC network. *Neuro Oncol.* 18(9):1297–1303. [PubMed: 26951382]
84. Batchelor TT, Grossman SA, Mikkelsen T, Ye X, Desideri S, Lesser GJ. (2011). Rituximab monotherapy for patients with recurrent primary CNS lymphoma. *Neurology.* 76(10):929–930. [PubMed: 21383331]
85. Pentsova E, Deangelis LM, Omuro A. (2014). Methotrexate re-challenge for recurrent primary central nervous system lymphoma. *J Neurooncol.* 117(1):161–165. [PubMed: 24481997]
86. Plotkin SR, Betensky RA, Hochberg FH, et al. (2004). Treatment of relapsed central nervous system lymphoma with high-dose methotrexate. *Clin Cancer Res.* 10(17):5643–5646. [PubMed: 15355887]
87. Soussain C, Hoang-Xuan K, Taillandier L, et al. (2008). Intensive chemotherapy followed by hematopoietic stem-cell rescue for refractory and recurrent primary CNS and intraocular lymphoma: Société Française de Greffe de Moëlle Osseuse-Thérapie Cellulaire. *J Clin Oncol.* 26(15):2512–2518. [PubMed: 18413641]
88. Nayak L, Iwamoto FM, LaCasce A, et al. (2017). PD-1 blockade with nivolumab in relapsed/refractory primary central nervous system and testicular lymphoma. *Blood.* 129(23):3071–3073. [PubMed: 28356247]
89. Grommes C, Pastore A, Palaskas N, et al. (2017). Ibrutinib Unmasks Critical Role of Bruton Tyrosine Kinase in Primary CNS Lymphoma. *Cancer Discov.* 7(9):1018–1029. [PubMed: 28619981]
90. Fox CP, Ali AS, McIlroy G, et al. (2021). A phase 1/2 study of thiotepa-based immunochemotherapy in relapsed/refractory primary CNS lymphoma: the TIER trial. *Blood Adv.* 5(20):4073–4082. [PubMed: 34464973]

91. Chiesa S, Hohaus S, Falcinelli L, et al. (2020). Chemoradiotherapy with temozolomide after high-dose methotrexate for primary CNS lymphoma: a multicenter phase I study of a response-adapted strategy. *Ann Hematol.* 99(10):2367–2375. [PubMed: 32816079]
92. Dietrich J, Versmee L, Drappatz J, et al. (2020). Pemetrexed in Recurrent or Progressive Central Nervous System Lymphoma: A Phase I Multicenter Clinical Trial. *Oncologist.* 25(9):747–e1273. [PubMed: 32520407]
93. Ferreri AJ, Cwynarski K, Pulczynski E, et al. (2016). Chemoimmunotherapy with methotrexate, cytarabine, thiotepa, and rituximab (MATRix regimen) in patients with primary CNS lymphoma: results of the first randomisation of the International Extranodal Lymphoma Study Group-32 (IELSG32) phase 2 trial. *Lancet Haematol.* 3(5):e217–227. [PubMed: 27132696]
94. Glass J, Won M, Schultz CJ, et al. (2016). Phase I and II Study of Induction Chemotherapy With Methotrexate, Rituximab, and Temozolomide, Followed By Whole-Brain Radiotherapy and Postirradiation Temozolomide for Primary CNS Lymphoma: NRG Oncology RTOG 0227. *J Clin Oncol.* 34(14):1620–1625. [PubMed: 27022122]
95. Chen YB, Batchelor T, Li S, et al. (2015). Phase 2 trial of high-dose rituximab with high-dose cytarabine mobilization therapy and high-dose thiotepa, busulfan, and cyclophosphamide autologous stem cell transplantation in patients with central nervous system involvement by non-Hodgkin lymphoma. *Cancer.* 121(2):226–233. [PubMed: 25204639]
96. Omuro A, Correa DD, DeAngelis LM, et al. (2015). R-MPV followed by high-dose chemotherapy with TBC and autologous stem-cell transplant for newly diagnosed primary CNS lymphoma. *Blood.* 125(9):1403–1410. [PubMed: 25568347]
97. Ferreri AJM, Calimeri T, Ponzoni M, et al. (2020). Improving the antitumor activity of R-CHOP with NGR-hTNF in primary CNS lymphoma: final results of a phase 2 trial. *Blood Adv.* 4(15):3648–3658. [PubMed: 32766857]
98. Ferreri AJM, Calimeri T, Conte GM, et al. (2019). R-CHOP preceded by blood-brain barrier permeabilization with engineered tumor necrosis factor- α in primary CNS lymphoma. *Blood.* 134(3):252–262. [PubMed: 31118164]
99. DeAngelis LM, Yahalom J, Heinemann MH, Cirrincione C, Thaler HT, Krol G. (1990). Primary CNS lymphoma: combined treatment with chemotherapy and radiotherapy. *Neurology.* 40(1):80–86. [PubMed: 2296388]
100. Jelicic J, Todorovic Balint M, Raicevic S, et al. (2016). The possible benefit from total tumour resection in primary diffuse large B-cell lymphoma of central nervous system - a one-decade single-centre experience. *Br J Neurosurg.* 30(1):80–85. [PubMed: 26337736]
101. Rae AI, Mehta A, Cloney M, et al. (2019). Craniotomy and Survival for Primary Central Nervous System Lymphoma. *Neurosurgery.* 84(4):935–944. [PubMed: 29660011]
102. Weller M, Martus P, Roth P, Thiel E, Korfel A. (2012). Surgery for primary CNS lymphoma? Challenging a paradigm. *Neuro Oncol.* 14(12):1481–1484. [PubMed: 22984018]
103. Labak CM, Holdhoff M, Bettgowda C, et al. (2019). Surgical Resection for Primary Central Nervous System Lymphoma: A Systematic Review. *World Neurosurg.* 126:e1436–e1448. [PubMed: 30904794]
104. ilson R, Osborne C, Halsey C. (2018). The Use of Ommaya Reservoirs to Deliver Central Nervous System-Directed Chemotherapy in Childhood Acute Lymphoblastic Leukaemia. *Paediatr Drugs.* 20(4):293–301. [PubMed: 29850985]
105. Ommaya AK. (1963). Subcutaneous reservoir and pump for sterile access to ventricular cerebrospinal fluid. *Lancet.* 2(7315):983–984. [PubMed: 14059058]
106. Steinherz P, Jereb B, Galicich J. (1985). Therapy of CNS leukemia with intraventricular chemotherapy and low-dose neuraxis radiotherapy. *J Clin Oncol.* 3(9):1217–1226. [PubMed: 3861774]
107. Peyrl A, Chocholous M, Azizi AA, et al. (2014). Safety of Ommaya reservoirs in children with brain tumors: a 20-year experience with 5472 intraventricular drug administrations in 98 patients. *J Neurooncol.* 120(1):139–145. [PubMed: 25017328]
108. Mead PA, Safdieh JE, Nizza P, Tuma S, Sepkowitz KA. (2014). Ommaya reservoir infections: a 16-year retrospective analysis. *J Infect.* 68(3):225–230. [PubMed: 24321561]

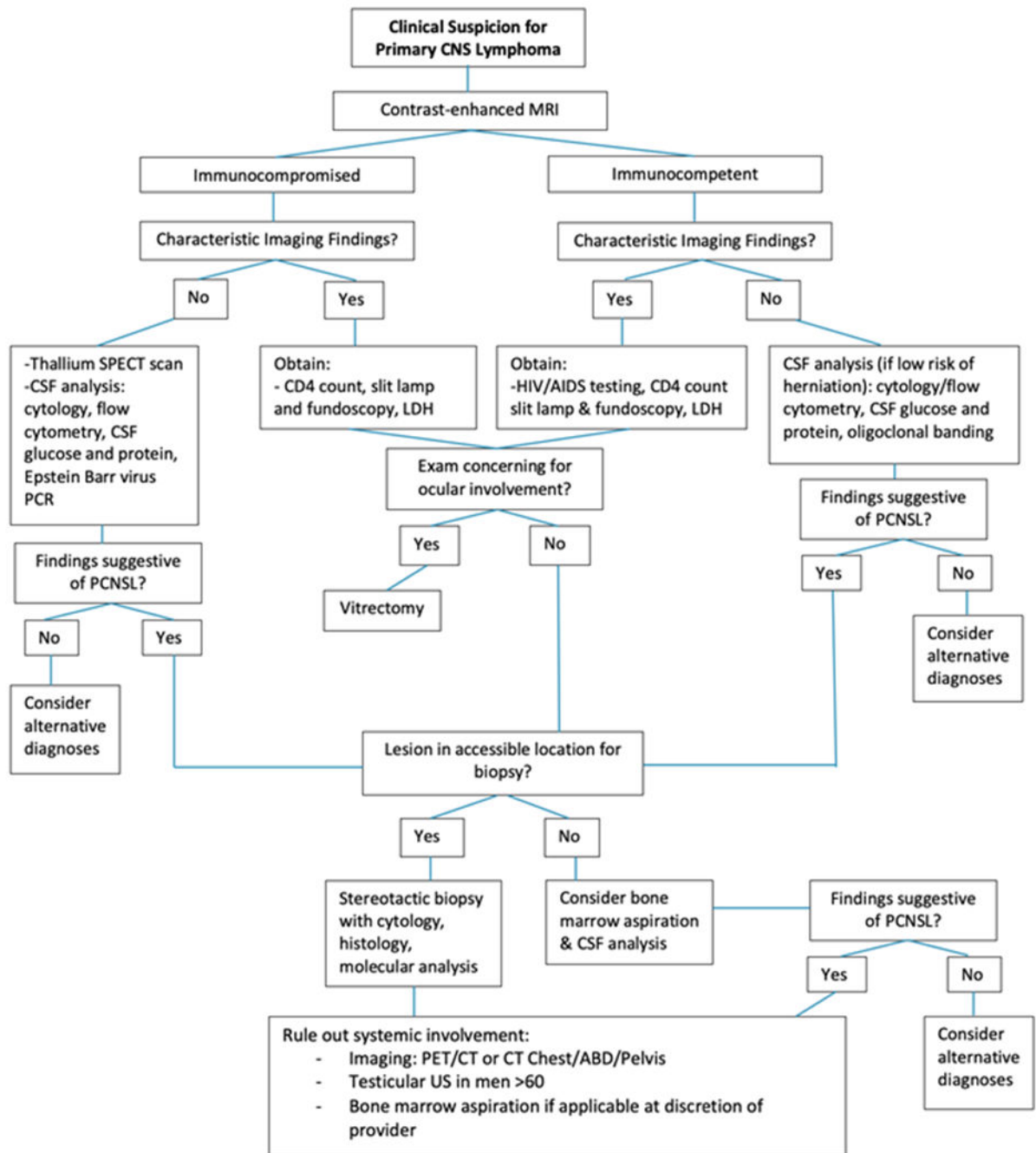


Figure 1:
Diagnostic algorithm of suspected primary CNS lymphoma

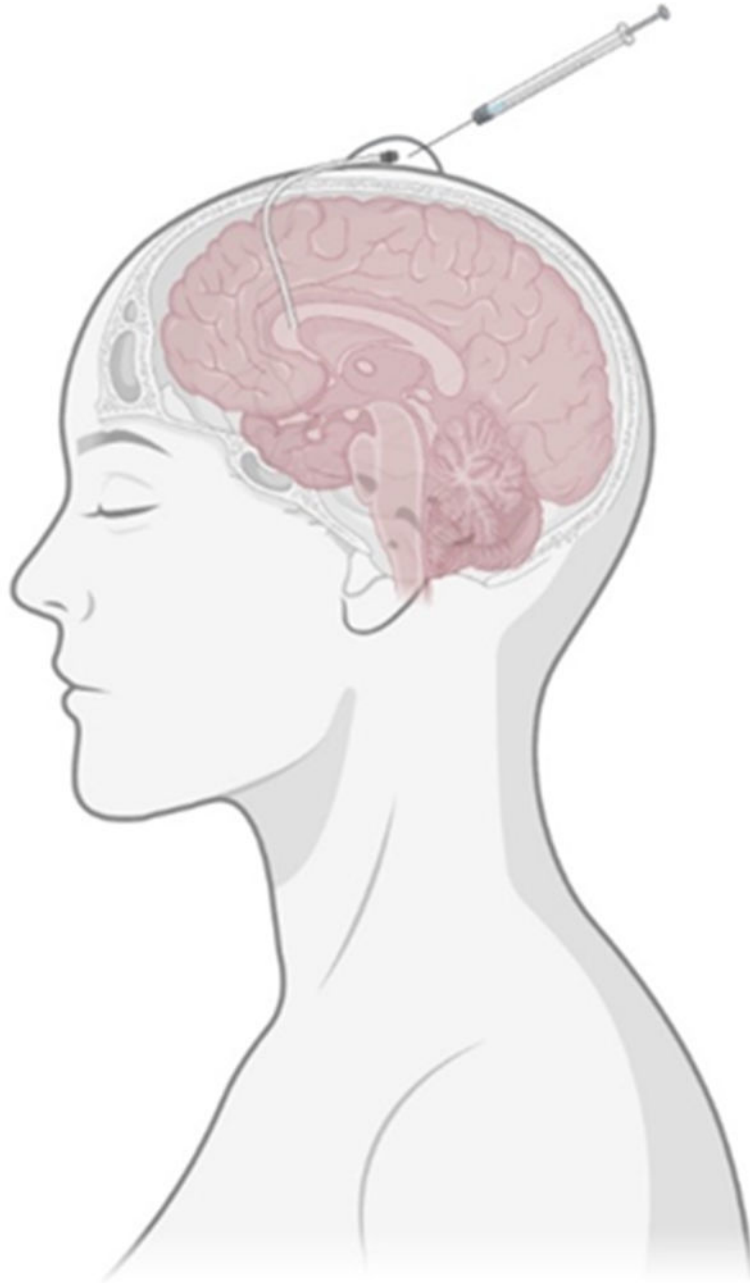

Figure 2:
Schematic of Ommaya reservoir and catheter placement

Table 1:

Summary of Medical Management of PCNSL.

First-Line Treatment	HD-MTX Chemotherapy
To be combined with...	Other chemotherapeutic agents that cross BBB (eg: rituximab, cytarabine, etc.)*
	Reduced-dose WBRT** ASCT
Salvage Chemotherapy Used for refractory PCNSL, partial response, or stable disease persists after first-line treatment	HD-MTX Rechallenge (if previous HD-MTX response was prolonged)
	High dose chemotherapy + ASCT (if treatments not given previously; more effective in younger patients with good performance status)
	WBRT**
Consolidation Treatment	HD-MTX + ASCT
	Reduced-dose WBRT**

HD-MTX = High dose Methotrexate, BBB = Blood brain barrier, WBRT = whole brain radiotherapy, ASCT = autologous stem cell transplantation

* Avoid intrathecal drugs

** Avoid as first-line treatment and defer to only relapsed/refractory cases in elderly population