

A COVID-19 family cluster with retinitis pigmentosa and hypogammaglobulinemia

Abeer N. Alshukairi^{1,2}, Yasser A. Aldabbagh^{1,3}, Najla M. Sayes¹, Manal M. Al Gethamy⁴, Mohammed G. Alghamdi⁵, Zuhair A. Rahbeeni⁶, Ashraf Dada^{2,7}

Departments of ¹Medicine and ⁷Pathology and Laboratory Medicine, King Faisal Specialist Hospital and Research Center, ⁵Department of Medicine, King Fahd General Hospital, Jeddah, ²College of Medicine, Alfaisal University, ⁶Department of Medical Genetics, King Faisal Specialist Hospital and Research Center, Riyadh, ³Department of Infectious Diseases, Al Moosa Specialist Hospital, Al-Ahsa, ⁴Department of Medicine, Al Nour Specialist Hospital, Makkah, Kingdom of Saudi Arabia

Address for correspondence:

Dr. Abeer N. Alshukairi, Department of Medicine, King Faisal Specialist Hospital and Research Center, Jeddah, P. O. Box: 40047, Jeddah 21499, Kingdom of Saudi Arabia. E-mail: abeer.alshukairi@gmail.com

Submission: 14-11-2021
Accepted: 30-11-2021
Published: 14-01-2022

Access this article online

Quick Response Code:



Website:

www.thoracicmedicine.org

DOI:

10.4103/atm.atm_520_21

Abstract:

Hypogammaglobulinemia is a heterogeneous group of innate and acquired antibody deficiency with variable disease severity, recurrent pneumonia, and bronchiectasis. The outcome of COVID in patients with hypogammaglobulinemia is variable depending on age, comorbidities, type of immunodeficiency, and use of immunoglobulins. We report the favorable outcome of two family members diagnosed with *DNAJC17*-related retinitis pigmentosa and hypogammaglobulinemia syndrome and infected with SARS-CoV-2 following contact with their mother who had COVID-19. We describe the different immune dysfunction in these patients and their impact on the course and management of SARS-CoV-2 infection.

Keywords:

COVID-19, hypogammaglobulinemia, outcome, retinitis pigmentosa

Hypogammaglobulinemia is a heterogeneous group of innate and acquired antibody deficiency with various disease severity, recurrent pneumonia, and bronchiectasis.^[1] While COVID-19 patients with chronic obstructive pulmonary diseases had severe disease,^[2] the outcome of patients with hypogammaglobulinemia infected with SARS-CoV-2 is variable depending on the type of immunodeficiency and use of immunoglobulins.^[3] Secondary immunodeficiency had a worse outcome compared to primary immunodeficiency because patients were old and had underlying comorbid diseases.^[4] We report the outcome of two siblings with retinitis pigmentosa (RP) and hypogammaglobulinemia syndrome and we describe their different therapeutic modalities based on the immunologic dysfunction of each patient.

This is an open access journal, and articles are distributed under the terms of the Creative Commons Attribution-NonCommercial-ShareAlike 4.0 License, which allows others to remix, tweak, and build upon the work non-commercially, as long as appropriate credit is given and the new creations are licensed under the identical terms.

For reprints contact: WKHLRPMedknow_reprints@wolterskluwer.com

The study was approved by the Institutional Research Board. The parents provided informed consent to share the information of their children for publication in a confidential manner as the patients have a developmental disability.

Case Reports

Both siblings had recurrent infections and decreased visual acuity during childhood and were diagnosed to have primary hypogammaglobulinemia and retinal degeneration. The association between RP and hypogammaglobulinemia was sporadically reported.^[5] A genetic evaluation was performed to identify the association between hypogammaglobulinemia and RP. Both patients had a gene mutation *DNAJC17*, and a novel syndrome of RP and hypogammaglobulinemia was described in two families in Saudi Arabia, as previously described.^[6] They were started on monthly intravenous immunoglobulins at the age

How to cite this article: Alshukairi AN, Aldabbagh YA, Sayes NM, Al Gethamy MM, Alghamdi MG, Rahbeeni ZA, *et al.* A COVID-19 family cluster with retinitis pigmentosa and hypogammaglobulinemia. *Ann Thorac Med* 2022;17:66-9.

of 2 years. The male patient had normal absolute T-lymphocytes and B-lymphocytes CD19. The female patient had low absolute T-lymphocytes CD4 and B-lymphocytes CD19 [Table 1]. They had recurrent otitis media, pneumonia, cellulitis, and diarrhea at the age of 4 months. They had decreased visual acuity at the age of 6 months. They had developmental delay and were legally blind at the age of 12 years. The male patient had growth hormone deficiency and recurrent meningoencephalitis. The female patient was started on subcutaneous immunoglobulins at the age of 22 years in view of difficult vascular access and multiple episodes of catheter-related bacteremia. Both patients are chairbound. Both parents are cousins and they are carriers of the *DNAJC17* variant. They have three boys and three girls, and no other members have RP or hypogammaglobulinemia. Both patients were infected with SARS-CoV-2 based on positive nasopharyngeal polymerase chain reaction swab following contact with their mother who had COVID-19. They did not receive COVID-19 vaccine. The father requested to provide full resuscitation for both patients and he agreed to give them any COVID-19 therapeutic modalities that would save their lives even if they were not previously studied.

Case 1

A 21-year-old male patient presented with fever, cough, headache, abdominal pain, and diarrhea. He had no dyspnea. His baseline oxygen saturation was 97% on ambient air. His laboratory investigation was significant for leukopenia ($1.1 \times 10^9/l$), elevated C-reactive protein (CRP) (246 µg/l), D-dimer (1.48 µg/ml), and

ferritin level (1909 ng/ml). The patient’s chest X-ray showed a right perihilar infiltrate on admission that progressed to bilateral middle and lower zone opacities on the 2nd day of admission [Figure 1]. His oxygen saturation dropped to 94% and required oxygen support with a low-flow nasal cannula 2 L/min. Despite receiving dexamethasone and broad-spectrum antibiotics, his condition did not improve. Based on desaturation, high inflammatory parameters, and concern of progression to cytokine storm, he received one dose of tocilizumab 8 mg/kg, day 6 post hospitalization. Subsequently, his fever resolved, his oxygen saturation and inflammatory parameters improved. After 6 days of hospitalization, he was discharged home in a stable condition [Table 2].

Case 2

A 30-year-old female patient presented with fever, cough, and abdominal pain. She had no dyspnea. Her baseline oxygen saturation was 98% on ambient air.

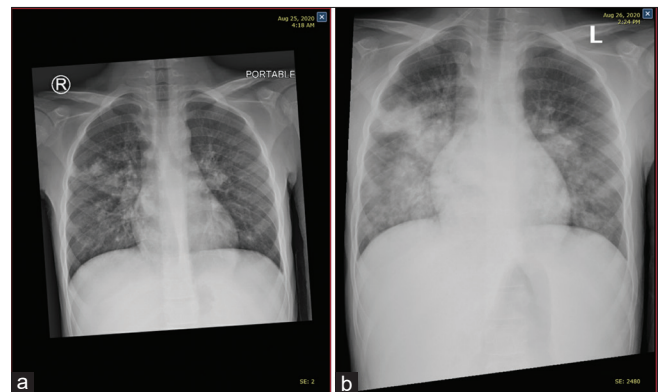


Figure 1: Chest Xray showed radiological progression of case 1

Table 1: Demographic, genetic, and immunological characteristics of our COVID-19 family cluster

	Case 1	Case 2
Age (years)	21	30
Gender	Male	Female
Weight (kg)	30.4	46.7
Height (cm)	149	155
Body mass index	13.7	20.1
Genetic mutation	<i>DNAJC17</i> ; two pathogenic copies	<i>DNAJC17</i> ; two pathogenic copies
Immunoglobulin levels	Date obtained: 2019	Date obtained: 2019
IgG	9.94 (normal)	9.10 (normal)
IgG1	5.04 (low)	5.50 (low)
IgG2	2.62 (low)	2.10 (low)
IgG3	1.93 (high)	0.49 (normal)
IgG4	0.36 (high)	0.50 (high)
IgM	0.3 (low)	0.3 (low)
IgA	0.5 (low)	1.5 (normal)
Lymphocytes subset	Date obtained: 2015	Date obtained: 2015
Absolute total T-CD3	3018 (normal)	982 (normal)
Absolute T-CD4	955 (normal)	459 (low)
Absolute T-CD8	1387 (high)	321 (low)
Absolute total B-CD19	205 (normal)	72 (low)
Absolute total NK CD59 and 16	617 (high)	67 (low)

Her white blood cell count was normal ($4.18 \times 10^9/l$). She had elevated CRP (379 mg/l), D-dimer (1.25 $\mu\text{g/ml}$), and ferritin level (815 ng/ml). Her chest X-ray on admission showed a patchy infiltration in the right lower zone. After 48 h, she had clinical and radiological deterioration: her chest X-ray showed diffuse infiltration of the right hemithorax and her oxygen saturation was 94% [Figure 2]. She was started on broad-spectrum antibiotics and antiviral therapy (favipiravir). She received COVID-19 convalescent plasma. She improved and was discharged home after 4 days of hospitalization [Table 2].

Discussion

COVID-19 patients with inherited and acquired B-cell deficiency have a delay in the development of SARS-CoV-2-specific antibodies and delayed viral clearance. Convalescent plasma was used successfully in these patients.^[7] We used convalescent plasma in the female patient in view of her significant B-cell depletion and low B-lymphocytes CD19; in addition, she had low

T-lymphocytes CD4. Recently, SARS-CoV-2 monoclonal antibodies were used successfully to treat persistent COVID-19 infection in patients with rituximab-induced hypogammaglobulinemia.^[8] On the other hand, we used tocilizumab as an immune-modulating agent for our male patient who had normal B-lymphocytes CD19, normal T-lymphocytes CD4, and concern of cytokine storm based on desaturation and high inflammatory parameters. The use of tocilizumab in COVID-19 patients with hypogammaglobulinemia was limited and the risk of infection is not known.^[9]

Although these two patients in our report had hypogammaglobulinemia, their management was individualized based on the associated T-lymphocyte dysfunction, which will determine the risk of cytokine storm and specific use of immune-modulating agents such as interleukin-6 inhibitors. Mathew *et al.* showed a heterogeneous immune response in different patient categories depending on disease severity and outcome ranging from T-cell activation to T-cell depletion. They postulated that different therapeutic options could be offered depending on the immune response module.^[10] Bange *et al.* described the different humoral and T-cell responses in various solid cancer and hematological malignancies. Patients with solid cancer had intact humoral and cellular responses leading to a favorable outcome, while patients with hematological malignancies had B-cell and T-cell dysfunction resulting in a poor outcome. A subpopulation of patients with hematological malignancies and B-cell depletion survived as they had a specific CD8 T-cell response, indicating that patients with impaired humoral antibody response would have a favorable response in the presence of intact T-cell immune responses.^[11]

Our report has its limitations; we described a family cluster of only two patients. Future studies are needed to determine the use of optimal immune-modulating therapy in patients with hypogammaglobulinemia based on the analysis of specific case-based cell-mediated and humoral immune responses.

Table 2: Laboratory parameters and therapeutic modalities in our COVID-19 family cluster

	Case 1	Case 2
White blood cells (highest) – $\times 10^9/L$	6.33	7.37
White blood cells (lowest) – $\times 10^9/L$	1.1	4.18
Neutrophils (highest) – %	69.5	79.8
Lymphocytes (lowest) – %	35	12.2
Platelets (lowest) – $\times 10^9/L$	233	200
CRP (highest) – mg/L	246	379
Lactic dehydrogenase (highest) – IU/L	333	209
Ferritin (highest) – ng/ml	1909	815
D-dimer (highest) – $\mu\text{g/ml}$	1.48	1.25
Alanine transaminase (highest) – IU/L	13	14
Creatinine (highest) – mmol/l	45	58
Antibiotics	Yes	No
Dexamethasone	Yes	Yes
Antivirals (favipiravir)	No	Yes
Tocilizumab	Yes	No
Convalescent plasma	No	Yes

CRP=C-reactive protein

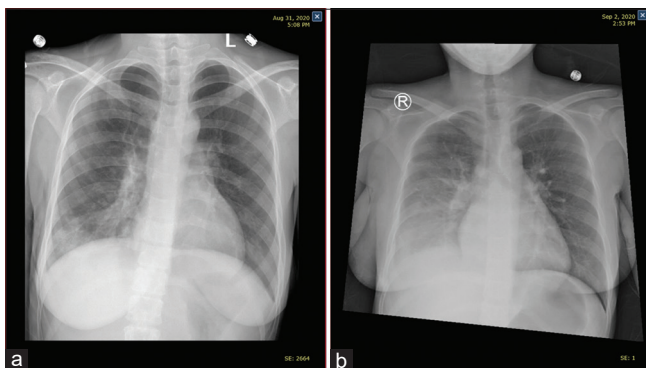


Figure 2: Chest Xray showed radiological progression of case 2

Ethics approval

The study was approved by the Institutional Research Board of King Faisal Specialist Hospital and Research Center, Jeddah, Saudi Arabia, IRB 2021-19.

Declaration of patient consent

The authors certify that they have obtained all appropriate patient consent forms. In the form, the patients' parents have given their consent for images and other clinical information to be reported in the journal. The patients' parents understand that names and initials will not be published and due efforts will be made to conceal identity, but anonymity cannot be guaranteed.

Acknowledgment

We would like to thank our patients who contributed to this work.

We thank Professor Fowzan S Alkuraya for his critical reading of this manuscript.

Financial support and sponsorship

Nil.

Conflicts of interest

There are no conflicts of interest.

References

1. Cinetto F, Scarpa R, Rattazzi M, Agostini C. The broad spectrum of lung diseases in primary antibody deficiencies. *Eur Respir Rev* 2018;27:180019.
2. Geng J, Yu X, Bao H, Feng Z, Yuan X, Zhang J, *et al.* Chronic diseases as a predictor for severity and mortality of COVID-19: A systematic review with cumulative meta-analysis. *Front Med (Lausanne)* 2021;8:588013.
3. Cohen B, Rubinstein R, Gans MD, Deng L, Rubinstein A, Eisenberg R. COVID-19 infection in 10 common variable immunodeficiency patients in New York City. *J Allergy Clin Immunol Pract* 2021;9:504-7.e1.
4. Shields AM, Burns SO, Savic S, Richter AG; UK PIN COVID-19 Consortium. COVID-19 in patients with primary and secondary immunodeficiency: The United Kingdom experience. *J Allergy Clin Immunol* 2021;147:870-5.e1.
5. Starr JC, Brasher GW, Dominguez J, Rao A. Retinitis pigmentosa and hypogammaglobulinemia. *South Med J* 2006;99:989-91.
6. Patel N, Aldahmesh MA, Alkuraya H, Anazi S, Alsharif H, Khan AO, *et al.* Expanding the clinical, allelic, and locus heterogeneity of retinal dystrophies. *Genet Med* 2016;18:554-62.
7. Murphy MF, Dzik S. COVID-19, plasma, and hypogammaglobulinemia. *Blood* 2020;136:2245-6.
8. Luitel P, Vais D, Gidron A. Successful treatment of persistent coronavirus disease 2019 infection in a patient with hypogammaglobulinemia with REGN-COV2: A case report. *Open Forum Infect Dis* 2021;8:ofab335.
9. Weifenbach N, Jung A, Lötters S. COVID-19 infection in CVID patients: What we know so far. *Immun Inflamm Dis* 2021;9:632-4.
10. Mathew D, Giles JR, Baxter AE, Oldridge DA, Greenplate AR, Wu JE, *et al.* Deep immune profiling of COVID-19 patients reveals distinct immunotypes with therapeutic implications. *Science* 2020;369:eabc8511.
11. Bange EM, Han NA, Wileyto P, Kim JY, Gouma S, Robinson J, *et al.* CD8⁺ T cells contribute to survival in patients with COVID-19 and hematologic cancer. *Nat Med* 2021;27:1280-9.