

The use of buccal fat pad free graft in closure of soft-tissue defects and dehiscence in the hard palate

Access this article online

Website:
www.amsjournal.com

DOI:
10.4103/2231-0746.200326

Quick Response Code:



Fares Kablan

Department of Oral and Maxillofacial Surgery, The Baruch Pade Medical Center, Poria, Tiberias, Israel

Address for correspondence:

Dr. Fares Kablan, The Baruch Pade Medical Center,
Poria, M.P. The Lower Galilee, Tiberias, Israel.
E-mail: kablanp1@gmail.com

ABSTRACT

Introduction: The integrity of the palatal mucosa can be lost due to congenital, pathological, and iatrogenic conditions. Various surgical techniques have been suggested for the closure of palatal defects. The aim of the current study is to present the free buccal fat pad graft as a novel technique to repair the soft-tissue defects at the palate. **Patients and Methods:** During a 2-year period, the free fat tissue graft harvested from the buccal fat pad (BFP) (FBFG) and used to reconstruct five soft-tissue defects of the palate in five patients (2 women, 3 men; mean age, 34 years; range, 22–58 years). In two patients, the palatal defect size was 2–3 cm and resulted from the resection of pleomorphic adenoma. In two other patients, the defect was due to odontogenic lesion, and in the last patient, the etiology was an iatrogenic dehiscence during maxillary segmentation surgery. Patients were examined every 2 weeks in the first 3 months and thereafter every 3 months. **Results:** Five patients were treated with FBFG to reconstruct palatal defects and were followed up for 6–24 months. The healing process of the BFP and the recipient sites were uneventful, with minimal morbidity. At 3 months after the surgery, there was complete epithelialization of the graft at the recipient sites. **Conclusions:** Harvesting of FBFG is a simple procedure with minor complications; manipulation and handling the graft are easy. The use of FBFG in reconstruction of small and medium palatal defects is encouraging with excellent clinical outcomes.

Keywords: Buccal fat pad, free fat tissue, oral lesions reconstruction, palatal defects, soft-tissue grafts

INTRODUCTION

Pathologic conditions from an odontogenic origin (abscesses, cysts, and tumors), residual defects, following clefts surgeries, surgical defects after excisions of various cancerous lesions, trauma, and even iatrogenic injuries during segmentation surgeries of the maxilla, can lead to loss of the palatal mucosa integrity.

Palatal fistulas and dehiscence may become a major burden on patient's quality of life and a surgical challenge for the treating doctor. Various surgical techniques have been suggested for the closure of palatal defects which include secondary healing, palatal flaps, tongue flaps, turnover flaps of adjacent mucoperiosteum, and pedicled flap from the buccal fat pad (BFP).^[1-9]

The use of BFP as a pedicled flap (PBFPF) as a graft for intraoral defects is a common procedure since its first publication by Egyedi in 1977,^[10] and the outcomes from the use of this flap for closure of intraoral defects have been encouraging. The

This is an open access article distributed under the terms of the Creative Commons Attribution-NonCommercial-ShareAlike 3.0 License, which allows others to remix, tweak, and build upon the work non-commercially, as long as the author is credited and the new creations are licensed under the identical terms.

For reprints contact: reprints@medknow.com

Cite this article as: Kablan F. The use of buccal fat pad free graft in closure of soft-tissue defects and dehiscence in the hard palate. *Ann Maxillofac Surg* 2016;6:241-5.

success of the PBFPF has been attributed to its rich vascular supply, less donor site morbidity, almost constant weight for all individuals, ease to harvest, and the fast epithelialization during 3–6 weeks.^[11-14] Low complications rate also has been reported regarding the PBFPF and includes distant dehiscence and necrosis, limitation in mouth opening, mild obliteration of the vestibule, limitation of passing it through dentate areas that can compromise the blood supply, and the limitation of its applications at large defects and in lesions at the anterior regions in the oral cavity.^[11]

Following years of handling the fat tissue by the author in various surgeries, it has been noted that the fat tissue from the BFP that is free from its blood supply can survive and heal very good so that it can be used as a free graft.

The concept of transplanting an autogenous fat as free graft is well documented for cosmetic surgery. It has been used more than 100 years, and its clinical behavior, characteristics, and healing are all well known in this area of medicine.^[15] The main mechanism of healing of free fat grafts (FFGs) is by fibrosis.^[16]

In 1983, Neder reported the use of BFP as a free graft for oral lesion reconstruction in two patients.^[17] Kablan and Laster in 2012 first reported the use of free buccal fat graft (FBFG) with bone augmentation. In their report, they discussed the advantages of the FBFG and the clinical and histologic healing stages, and the main healing nature of the FBFGs was fibrosis of the graft.^[18] Additional use of the FBFG was also reported by the author with excellent outcomes.^[19]

The aim of the present report was to introduce additional use of the FBFG in the treatment small- to medium-sized defects of the palatal mucosa.

PATIENTS AND METHODS

Methods

During a 2-year period, the free fat tissue graft harvested from the BFP (FBFG) and used to reconstruct five soft-tissue defects of the palate in five patients (2 women, 3 men; mean age, 34 years; range, 22–58 years). In two patients (Case 1 and 5), the palatal defect size was 2–3 cm and resulted from the resection of pleomorphic adenoma. In one another patient (Case 4), the defect was a palatal fistula from radicular odontogenic cyst that involved tooth 24. In additional patient (Case 2), the palatal dehiscence was secondary to incomplete healing from the previous resection of ameloblastic fibroma at the anterior maxilla, and in the last patient (Case 3), the etiology was an iatrogenic dehiscence during the maxillary segmentation surgery [Table 1].

Patients were examined every 2 weeks in the first 3 months and thereafter every 3 months. The period for the future follow-up period depends on etiology of the original lesion.

Technique

The donor site

The FBFG was harvested from the BFP through the standard approach [Figure 1]. This approach allows access to the BFP through a small horizontal incision in the free mucosa above the second and the third maxillary molars [Figure 1a]. Through blunt dissection, the fat tissue is accessed [Figure 1b and c] and easily mobilized to the oral cavity by progressive blunt dissection [Figure 1d]. The desired FBFG is harvested [Figure 1e and f], the BFP is pushed back in its place, and the incision is sutured [Figure 1g].

Case presentations

Case 1 [Figure 2]

A 29-year-old female patient was admitted to our department, complaining about a painless swelling on the hard palate. The history revealed that the swelling was detected 3 years ago. The lesion was growing slowly.

Intraoral examination revealed an oval-shaped circumscribed lesion, adherent to the underlying structures, covered with slightly erythematous palatal mucosa. The size of the lesion was 2 cm in diameter and extended from the mid-palatal area to the left alveolar ridge with smooth and intact overlying mucosa. The Panorax radiograph was uneventful. Clinical diagnosis of pleomorphic adenoma was suspected and confirmed with incisional biopsy. Figure 2a and b demonstrates the lesion after biopsy. Excision of the tumor was done under general anesthesia. A wide local resection including the periosteum with 0.5 cm borders was performed with blade [Figure 2c-e], and hemostasis was done by electrosurgery. The bone was not involved. To cover the surgical defect, FBFG was harvested from the left BFP, and its dimensions were 4 cm in length and 2 cm in width [Figure 2f]. After undermining of the recipient site soft tissue, the FBFG was secured with horizontal and interrupted sutures to the surgical defect [Figure 2g and h]. Prefabricated acrylic stent was used on the upper jaw to support the graft in position for the first 3 days.

Follow-up examinations at 3 days [Figure 2i], at 2 weeks [Figure 2j and k], after the surgery, showed uneventful recovery. At 1 month after the surgery, the FBFG showed complete epithelialization, and a residual oronasal fistula between the hard and soft tissue palate was found [Figure 2l]. The patient was advised to use the acrylic stent to prevent regurgitation of fluid/food into the nose and to prevent speech problems. Two months after

Table 1: Patients and the treated lesions: Location, etiology, defect size, and follow-up

Age	Gender	Location	Etiology	Defect size, mm (length/width)	Follow-up
28	Female	Left posterior hard palate	Pleomorphic adenoma	25/20	1 year
35	Female	Right anterior palate	Postsurgical defect	8/5	1 year
22	Male	Midline	Iatrogenic 2-piece segmented maxilla	20/2	2 years
34	Male	Left anterior hard palate	Odontogenic cyst fistula	8/5	2 years
58	Male	Left posterior hard palate	Pleomorphic adenoma	30/30	6 months

the surgery, the fistula was healed spontaneously [Figure 2m]. The 12-month follow-up recall revealed a good healing of the palate without recurrent of the tumor. The grafted palatal site was as the same color and architecture of the contralateral site [Figure 2n]. The patient will be followed up for 5 years.

Case 2 [Figure 3]

A 35-year-old female patient was referred due to swelling at the hard palate, mobility of the left upper lateral incisor with food retention at the palatal side of this tooth.

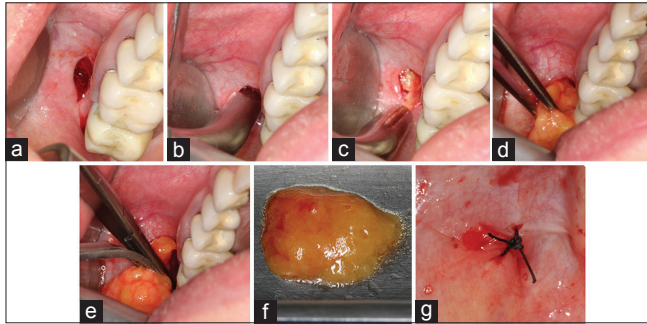


Figure 1: Harvest of the free buccal fat pad graft. (a) Small horizontal incision above the second and third maxillary molars. (b and c) The fat tissue is reached with blunt dissection. (d) The fat tissue is easily mobilized to the oral cavity. (e) The desired fat tissue volume is harvested. (f) The free buccal fat pad graft. (g) Suturing of the donor site incision

On examination, the buccal side architecture was healthy [Figure 3a]. A painless solid swelling at the palatal region was extended from tooth 11 to 13 [Figure 3b]; this area was smooth except contraction of the soft-tissue palatal to tooth 12 (fissure like). The computed tomography demonstrated a radiolucent lesion [Figure 3c]. Under local anesthesia, the patient underwent resection of the lesion with peripheral osteotomy [Figure 3d]. At this stage, the root of tooth 12 was involved; however, after meticulous debridement, the tooth was preserved. The contraction site underwent refreshment and primary closure [Figure 3e]. The histological examination revealed ameloblastic fibroma. Due to the complete resection of the lesion and the peripheral osteotomy, the decision was to follow-up the case without additional surgical intervention. Two months after the missed last recall, the patient came again to the department complaining about food impaction and high mobility of tooth 12 that necessitated splinting to the adjacent teeth by her dentist. On examination, at the palatal side, there was dehiscence of the soft tissue with entire exposure of the root at tooth 12 and accumulation of calculus [Figure 3f]. The buccal side was intact [Figure 3g]. At second surgery, the root of 12 was resected leaving its crown temporary for esthetic reasons [Figure 3h]. The soft tissue underwent deepithelialization and refreshments [Figure 3i].

The right BFP was addressed for FBFG [Figure 3j], and the desired FBFG volume was obtained [Figure 3k]. The FBFG was easily spread over the recipient site, and meticulous suturing

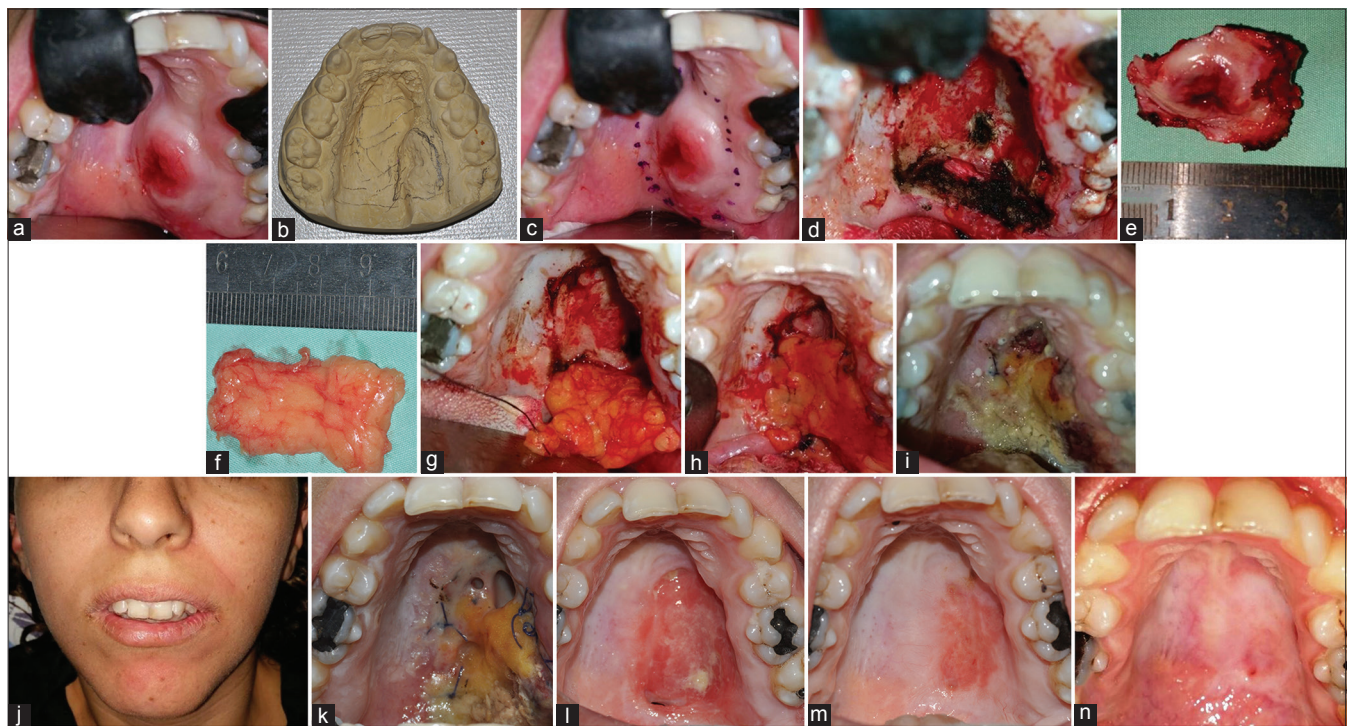


Figure 2: Case 1. (a) Pleomorphic adenoma of the left palate. (b) Study model that demonstrates the palatal lesion. (c) The planned excision of the tumor, the posterior border involves the soft palate. (d) Intraoperative view, the surgical palatal defect. (e) The macroview of the resected specimen (2–3 cm). (f) The free buccal fat pad graft (2–4 cm). (g) Intraoperative view, the free buccal fat pad graft at the recipient site. (h) The free buccal fat pad graft after suturing to the recipient site. (i) 3-days follow-up. (j) Extraoral view after 2 weeks, uneventful recovery. (k) Two weeks after the surgery demonstrates signs of healing with granulation tissue at the peripheral regions of the free buccal fat pad graft. (l) One-month follow-up, epithelialization of the free buccal fat pad graft with fat remnants and fistula at the anterior border of the soft palate. (m) Two-month follow-up, spontaneous closure of the soft palate fistula and complete epithelialization of the free buccal fat pad graft. (n) 12 month follow-up

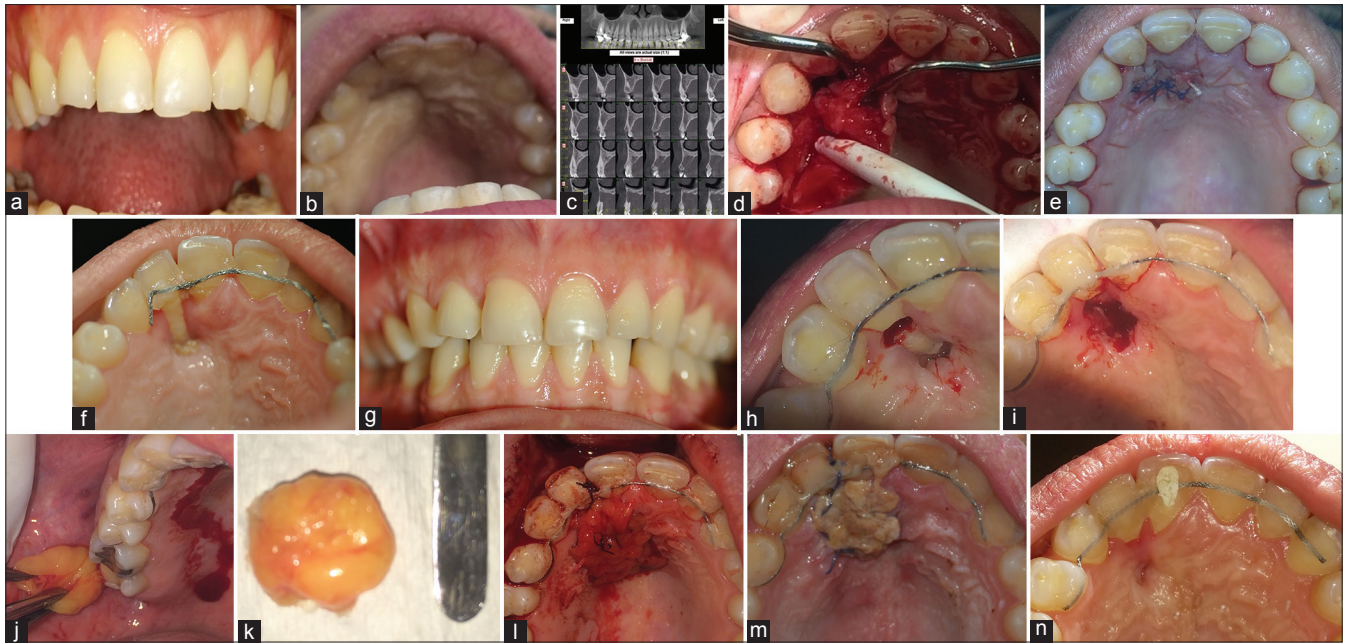


Figure 3: Case 2: Odontogenic lesion. (a) Buccal side clinical view. (b) Palatal side clinical view, swelling at the anterior lateral area. (c) Computed tomography, radiolucent lesions with resorption of tooth 12 root. (d) Intraoperative view, a solid lesion. (e) Primary closure of the soft tissue contraction. (f) Two months after the first surgery, soft tissue dehiscence and exposure of root 12. (g) Buccal view at 2 months. (h) Surgery two, resection of tooth 12 root. (i) Excision and refreshment of the soft tissue dehiscence. (j) Free buccal fat pad graft donor site. (k) The free buccal fat pad graft. (l) Suturing and fixation of the free buccal fat pad graft at the recipient site. (m) Free buccal fat pad graft, 2 weeks follow-up. (n) Twelve months follow-up after the second surgery

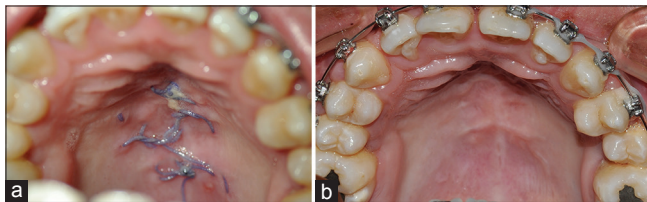


Figure 4: A case. (a) Fat remnants at 2 weeks after the fix of the iatrogenic dehiscence with free buccal fat pad graft. (b) Three months after the surgery, good healing

was performed [Figure 3l]. At 2 weeks follow-up, the healing of the FBFG at the recipient site was uneventful [Figure 3m]. One year after the FBFG, there was satisfied healing of the recipient site [Figure 3n]. Long-term follow-up is necessary for this lesion.

RESULTS

FBFGs were used in five hard palate defects, in five patients. The healing process was uneventful. The BFPs healed very well without complications and esthetic disturbances.

In two cases, the FBFG was used to reconstruct a soft-tissue defect, following resection of pleomorphic adenoma; the healing process went very well in one patient; in the additional patient (Case 1), a residual oronasal communication was observed after 2 weeks and was healed spontaneously after 3 months. In two cases, the FBFG was used to cover a residual defect with etiology of odontogenic lesions, with good outcomes. The last case was treated with FBFG due to iatrogenic injury to the soft tissue of the hard palate during two-piece maxillary osteotomy [Figure 4a], the dehiscence healed very well by the use of this graft, and full

integrity of the palatal soft tissue was observed 3 months after the injury [Figure 4b].

In all the patients, at 3 months after the treatment with FBFG, the recipient sites healed very well and were covered with contact epithelium. The FBFGs have been followed up 6–24 months.

DISCUSSION

The BFP is located in the masticatory space and consists of central body (corpus) with four extensions: buccal, pterygoid, superficial, and deep temporal. The total estimated volume is 10 ml and its lower thickness is 6 mm. The body and the buccal extension make up more than 50% of the BFP. They are accessible from the oral cavity and are the portions of the BFP that may be used as donor sites for fat tissue grafts.^[11-14]

The BFP has been used for several reconstruction applications in oral and maxillofacial area more than three decades. The predictable outcomes, the ease to harvest the graft, and the low complication rates make the (PBFPG) Pedicled buccal fat pad graft an attractive flap to close small- to medium-sized lesion in the posterior regions of the oral cavity.^[11] The nature of healing of the pedicled BFP has been widely reported, and the main mechanism of the healing process is by fibrosis and fast epithelialization of the graft.^[11,12,14]

Autologous FFGs are widely used in cosmetic surgery, and it is well-documented that the major healing process of the FFG is fibrosis of the fat tissue.^[15,16]

In maxillofacial surgery, the author was the first to investigate and report the clinical and histologic healing process of the FBFG.

In that report, immature fibrosis was seen 1 month and mature fibrosis of the FBFG was seen at 4 months after the surgery.^[18]

Kablan and Laster discussed in their article the disadvantages and limitations of the pedicled BFP and showed the advantages of the FBFG, especially its use in the entire oral cavity.^[18]

In the present paper, an additional clinical application of the FBFG is reported. The FBFG was utilized to reconstruct small- to medium-sized defects in the hard palate. The meticulous, but ease, handling of the graft at the recipient site with excellent suturing to secure and adapt the FBFG to the recipient bed left the graft stable enhances its healing and its fast epithelialization. During the follow-up period of the patients, the clinical and the histological healing process was the same like the stages that were previously reported by the author.^[18,19]

During the clinical follow-up period of the cases, epithelialization of the graft began at the 2nd week. The epithelium grew from the borders of the graft at the interface with the recipient site soft tissue; at this stage, the majority of the flap still exists; however, by 4–6 weeks after the surgery, the FBFG was completely epithelialized, and the recipient site was covered with smooth, soft tissue. After 3–4 months postsurgery, the recipient site color was the same as the surrounding tissue. At this stage, it was shown histologically by the previous publication of the author that the FBFG was covered with oral epithelium after the completion of its healing (exactly as the recipient site epithelium), with fibrous healing inside the graft.^[18]

With our rich experience in the use of the FBFG, as a soft-tissue graft in the oral cavity, the FBFG has several advantages over the PBFPF that include (1) less fat volume should be extracted from the BFP to reconstruct the same defect because there is no loss of fat tissue for the pedicle. (2) There is no limiting in mouth opening after the surgery. (3) The vestibular depths dose is not affected. (4) There is no fear of dental injury to the graft in full arches patients. (5) The main advantages of the FBFG are there is no anatomical limitation in the use of BFP, and the FBFG can be used in any region at the oral cavity.

CONCLUSION

In this patient series, the FBFG was proven as a simple procedure that can be performed quickly with minimal morbidity. The donor sites healed very well, without any cosmetic disturbances, making the harvesting of FBFGs a minor and insignificant procedure. The ability of the FBFG to survive its free transfer and the nature of healing that is same as the healing of the pedicled BFP is encouraging the use of BFP as free graft. Other clinical applications of the FBFG have been performed by the author and will be published in future.

Financial support and sponsorship

Nil.

Conflicts of interest

There are no conflicts of interest.

REFERENCES

- Gullane PJ, Arena S. Palatal island flap for reconstruction of oral defects. *Arch Otolaryngol* 1977;103:598-9.
- Díaz FJ, Dean A, Alamillos FJ, Naval L, Fernández J, Monje F. Tongue flaps for reconstruction of the oral cavity. *Head Neck* 1994;16:550-4.
- Anavi Y, Gal G, Silfen R, Calderon S. Palatal rotation-advancement flap for delayed repair of oroantral fistula: A retrospective evaluation of 63 cases. *Oral Surg Oral Med Oral Pathol Oral Radiol Endod* 2003;96:527-34.
- Seckel NG. The palatal island flap on retrospection. *Plast Reconstr Surg* 1995;96:1262-8.
- Moghe S, Pillai AK, Prabhu S, Nahar S, Kartika UK. Pleomorphic adenoma of the palate. Report of a case. *Int J Sci Study* 2014;2:54-6.
- Alkan A, Inal S. Closure of palatal defects following excision of palatal pleomorphic adenomas. *J Contemp Dent Pract* 2008;9:99-107.
- Lehman JA Jr., Curtin P, Haas DG. Closure of anterior palate fistulae. *Cleft Palate J* 1978;15:33-8.
- Murthy J. Descriptive study of management of palatal fistula in one hundred and ninety-four cleft individuals. *Indian J Plast Surg* 2011;44:41-6.
- Erdogan O, Esen E, Ustün Y. Bony palatal necrosis in a diabetic patient secondary to palatal rotational flap. *J Diabetes Complications* 2005;19:364-7.
- Egyedi P. Utilization of the buccal fat pad for closure of oro-antral and/or oro-nasal communications. *J Maxillofac Surg* 1977;5:241-4.
- Singh J, Prasad K, Lalitha RM, Ranganath K. Buccal pad of fat and its applications in oral and maxillofacial surgery: A review of published literature (February) 2004 to (July) 2009. *Oral Surg Oral Med Oral Pathol Oral Radiol Endod* 2010;110:698-705.
- Tideman H, Bosanquet A, Scott J. Use of the buccal fat pad as a pedicled graft. *J Oral Maxillofac Surg* 1986;44:435-40.
- Loh FC, Loh HS. Use of the buccal fat pad for correction of intraoral defects: Report of cases. *J Oral Maxillofac Surg* 1991;49:413-6.
- Martín-Granizo R, Naval L, Costas A, Goizueta C, Rodríguez F, Monje F, *et al.* Use of buccal fat pad to repair intraoral defects: Review of 30 cases. *Br J Oral Maxillofac Surg* 1997;35:81-4.
- Shiffan MA, editor. *Autologous Fat Transfer: Art, Science and Clinical Practice*. Springer-Verlag Berlin Heidelberg; 2010. Part I. p. 3-40.
- Nguyen A, Pasyk KA, Bouvier TN, Hassett CA, Argenta LC. Comparative study of survival of autologous adipose tissue taken and transplanted by different techniques. *Plast Reconstr Surg* 1990;85:378-86.
- Neder A. Use of buccal fat pad for grafts. *Oral Surg Oral Med Oral Pathol* 1983;55:349-50.
- Kablan F, Laster Z. The use of free fat tissue transfer from the buccal fat pad to obtain and maintain primary closure and to improve soft tissue thickness at bone-augmented sites: Technique presentation and report of case series. *Int J Oral Maxillofac Implants* 2014;29:e220-31.
- Kablan F. The use of buccal fat pad free graft in regenerative treatment of peri-implantitis: A new and predictable technique. *Ann Maxillofac Surg* 2015;5:179-84.