

Pancreatic Head Mass: A Rare Manifestation of Granulomatosis With Polyangiitis

Michael Castillo, MD¹, Adalberto Gonzalez, MD¹, Asad Ur Rahman, MD², Jeevna Kaur, MD¹, Pablo Bejarano, MD³, Vaibhav Wadhwa, MD², Alison Schneider, MD², and Ronnie Pimentel, MD²

¹Department of Internal Medicine, Cleveland Clinic Florida, Weston, FL

²Department of Gastroenterology and Hepatology, Cleveland Clinic Florida, Weston, FL

³Department of Pathology, Cleveland Clinic Florida, Weston, FL

ABSTRACT

Granulomatosis with polyangiitis may rarely present as an inflammatory pancreatic mass and mimic pancreatic cancer. We report a 73-year-old man who presented with fever and weight loss. Computed tomography imaging demonstrated a mass in the pancreatic head along with multiple cavitary pulmonary nodules. Our differential included metastatic pancreatic cancer vs an autoimmune process. Positive cytoplasmic antineutrophil cytoplasmic antibodies coupled with the lung biopsy findings established the diagnosis of granulomatosis with polyangiitis, a very rare cause of pancreatic masses. After completion of immunosuppressive therapy, magnetic resonance imaging demonstrated no evidence of a pancreatic mass. More studies are required to establish the management of these masses.

INTRODUCTION

A solid pancreatic mass is malignant 88%–95% of the time.^{1,2} The remaining cases include a variety of inflammatory masses that may mimic malignancy. Granulomatosis with polyangiitis (GPA) is a rare cause of an inflammatory mass that is particularly difficult to diagnose without other systemic manifestations. We report a case of GPA presenting as an inflammatory pancreatic mass that was initially suspected to be metastatic pancreatic cancer. We take the opportunity to provide a review of the literature on similar presentations and discuss the management of suspected cases.

CASE REPORT

A 73-year-old man presented to the emergency department with a three-month history of generalized weakness, fevers, weight loss, and maxillary sinus pain. His medical history was significant for chronic sinusitis and recurrent nasal polyps since childhood. He also described a history of lower extremity rashes that usually self-resolved. He denied any history of cigarette smoking, alcohol use, recent travel, sick contacts, or significant family history. His vital signs were normal on admission. Physical examination revealed 2–3 cm nodular purple plaques with necrotic centers (Figure 1). Pertinent negative findings included no evidence of jaundice, abdominal tenderness, distention, or palpable masses. His laboratory studies were significant for leukocytosis of 20 k/ μ L, mildly elevated alkaline phosphatase at 148 U/L, normal kidney function, normal transaminases, and normal bilirubin.

Abdominal computed tomography (CT) demonstrated a low-attenuation mass in the pancreatic head measuring 2.0 cm in diameter, which appeared inseparable from the posterior wall of the duodenal bulb and the medial wall of the duodenal sweep (Figure 2). In addition, thoracic CT revealed multiple bilateral necrotic and cavitary pulmonary nodules ranging from 1.6 to 5 cm in diameter (Figure 3). There was no evidence of hepatic involvement per CT imaging. Given the patient's age, sex, symptoms, and imaging findings, our initial diagnostic impression was pancreatic cancer. Carbohydrate antigen 19-9 and carcinoembryonic antigen were within normal limits. Thus, an autoimmune workup was performed which revealed negative antinuclear antibody,

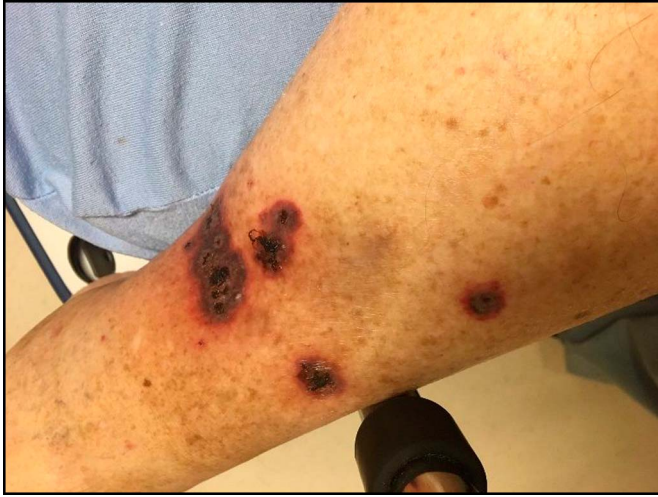

Figure 1. Bilateral lower extremity lesions described as nodular purple plaques with necrotic centers.

normal IgG4 levels, positive rheumatoid factor, elevated erythrocyte sedimentation rate, elevated immunoglobulin E levels, and elevated cytoplasmic antineutrophil cytoplasmic antibodies. Skin biopsy yielded leukocytoclastic vasculitis with granular fluorescence of C3 and immunoglobulin G. Biopsy of lung nodules revealed extensive necrosis with acute neutrophilic infiltrates, fibrin thrombi, and multinucleated giant cells without the formation of granulomas (Figure 4).

The patient was diagnosed with GPA and treated with intravenous methylprednisolone 80 mg for 3 days, followed by prednisone 60 mg, and immunosuppression with rituximab. He was discharged with plans for a repeat imaging and possible endoscopic ultrasound (EUS) with a fine-needle aspiration of the pancreatic mass if no significant improvement with immunosuppression. After 2 months of treatment, repeat thoracic CT demonstrated regression of majority of the lung masses.

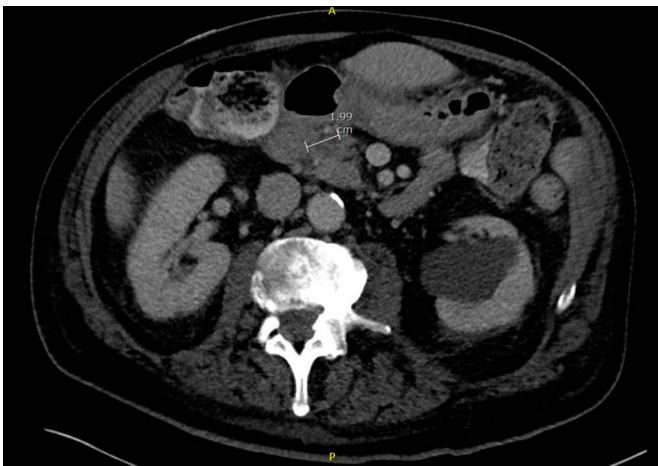


Figure 2. Low-attenuation mass in the pancreatic head measuring 2.0 cm in diameter, which appears inseparable from the posterior wall of the duodenal bulb and the medial wall of the duodenal sweep.

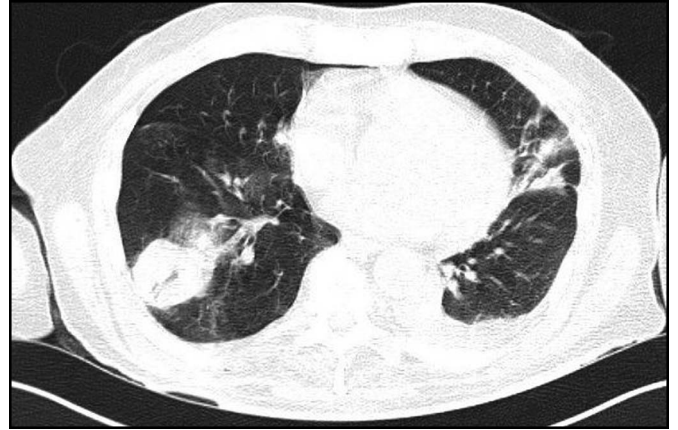


Figure 3. A 3.9 × 3.9 cm size rounded subpleural lesion in the posterior aspect of the right lung with a small focus of cavitation.

Magnetic resonance imaging of the pancreas obtained 5 months after completion of immunosuppressive therapy demonstrated no evidence of a pancreatic mass (Figure 5).

DISCUSSION

This case demonstrates a very rare cause of a solid pancreatic mass. To our knowledge, there are only 8 previously reported cases of pancreatic masses caused by GPA.^{3–9} In all previous cases, primary pancreatic adenocarcinoma was the initial diagnostic impression. Our patient's presentation was very concerning for pancreatic cancer, given his advanced age, male gender, symptoms, weight loss, and imaging findings.^{10,11} Pancreatic adenocarcinoma is located in the head of the pancreas in 60%–70% of cases, and most are hypoattenuating on contrast abdominal CT.¹² However, the absence of cholestatic hyperbilirubinemia, biliary dilation, pancreatic dilation, and a normal CA 19-9 rose suspicion of an alternative diagnosis.¹³

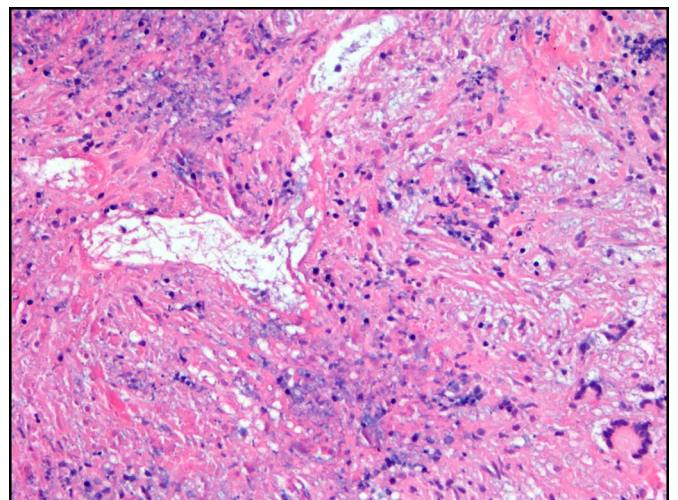


Figure 4. Lung biopsy tissue showing extensive necrosis in all fields with areas of basophilic (purple/blue) quality and necrotic blood vessels accompanied by multinucleated giant cells in the right lower corner (200× magnification).

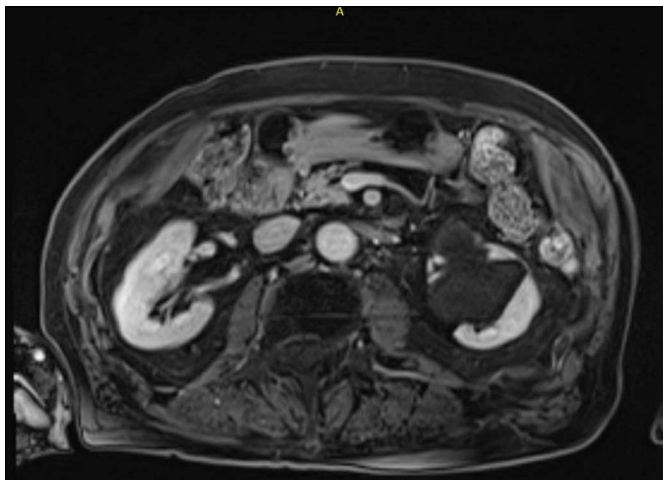


Figure 5. Magnetic resonance imaging of pancreas without contrast was obtained after 5 months and completion of immunosuppressive therapy demonstrating no evidence of pancreatic mass.

Owing to the patient's history of recurrent sinusitis, nasal polyps, and skin lesions, an autoimmune etiology was explored. The differential diagnosis included autoimmune pancreatitis (AIP); however, serum IgG4 levels were normal, and imaging was not characteristic of the "sausage-shaped" pancreas classically described in AIP. Although type-2 AIP is typically serum IgG4 negative, it is also generally associated with younger age of onset and the presence of chronic inflammatory bowel disease, which this patient did not have. A positive cytoplasmic antineutrophil cytoplasmic antibodies coupled with the lung and skin biopsy findings established the diagnosis of GPA, a very rare cause of pancreatic masses. A multidisciplinary team was involved in the decision to forego obtaining a confirmatory biopsy by EUS because of the high clinical suspicion for GPA. Instead, a less aggressive approach was taken by monitoring symptoms and obtaining follow-up

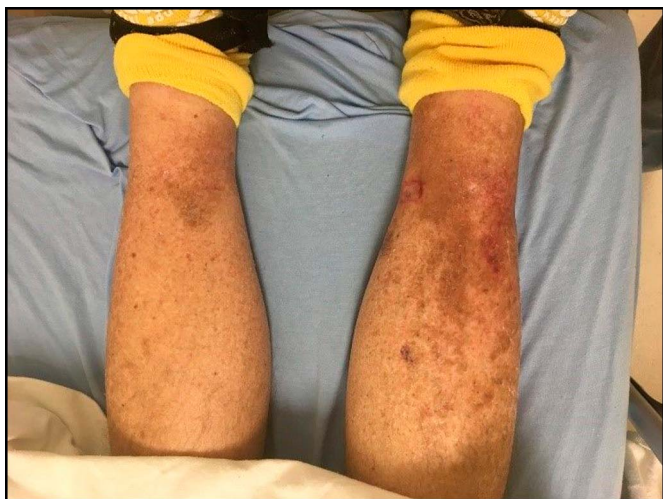

Figure 6. Lower extremity lesions observed 2 months poststeroid and rituximab therapy.

imaging after a significant trial of immunosuppressive therapy. The resolution of the pancreatic mass on magnetic resonance imaging and improvement in other signs and symptoms after immunosuppressive therapy confirmed our diagnosis (Figure 6).¹⁴ Most cases detailing gastrointestinal manifestations of GPA present with pancreatitis, pancreatic insufficiency,¹⁵ or painless jaundice, but very few have reported pancreatic masses.

A literature review between 1992 and 2014 found 8 cases detailing inflammatory pancreatic masses due to GPA. A complete description of the previous 8 cases can be found in Table 1. The mean age of the patients was 61 years old, and 6 of 8 were women. Five patients presented with abdominal pain, whereas 3 presented with painless jaundice. Half of them had anti-PR3 positivity, whereas 2 had anti-myeloperoxidase antibodies. Systemic manifestations were found in 6 patients and included morning stiffness, lung masses, biliary obstruction, phlebotrombosis, sinusitis, and orchitis. In each case, the mass was initially thought to be primary pancreatic adenocarcinoma. EUS-guided biopsy was performed in one patient and was found to be negative for malignant cells. Six of 8 patients underwent pancreatectomy, whereas 2 patients received only medical treatment with resolution of symptoms. All patients achieved full recovery, and those receiving immunosuppressants remained asymptomatic.

Necrotizing vasculitides can mimic pancreatic carcinoma and should be considered in the differential diagnosis of atypical cases. It is important to distinguish a pancreatic mass caused by GPA from malignancy because of the significant differences in treatment and overall prognosis. Given the high mortality rates of pancreatic adenocarcinoma, it is not unreasonable for these patients to undergo surgical resection; however, pancreatectomies also entail high intraoperative risks.^{3,16} In this case, our team was able to diagnose and successfully treat the patient without adding an additional risk of developing complications from interventions such as EUS-guided biopsy or pancreatectomy. More studies are needed to determine whether these pancreatic masses, with lower suspicion for malignancy, should be biopsied or followed with imaging.

DISCLOSURES

Author contributions: M. Castillo, A. Gonzalez, A. Ur Rahman, J. Kaur, V. Wadhwa, A. Schneider, and R. Pimentel wrote the manuscript and approved the final version. P. Bejarano provided the images and approved the final version. M. Castillo is the article guarantor.

Acknowledgments: The authors would like to acknowledge Albert Parlade for providing the radiological images.

Financial disclosure: None to report.

Table 1. Clinical summary of previously reported cases of pancreatic GPA

Author, year	Age/ Sex	Presenting symptoms	Systemic manifestations	Autoantibodies	Surgical treatment	Medical therapy	Outcome
Kontis et al, ³ 2014	57/M	Abdominal pain, nausea	None	c-ANCA (–) p-ANCA (–)	Distal pancreatectomy, splenectomy, left colectomy, and small bowel resection	None	Full recovery, asymptomatic
Kontis et al, ³ 2014	68/F	Abdominal pain, jaundice, weight loss	Involved the common bile duct, morning stiffness	c-ANCA (–) p-ANCA (+)	Percutaneous, transhepatic biliary drain, total pancreatectomy	None	Full recovery, asymptomatic
Valerieva et al, ⁴ 2013	62/F	Abdominal pain, nausea, fever	Sinusitis, phlebotrombosis	c-ANCA (+) p-ANCA (–)	Pancreatic resection, pancreatico-jejunoanastomosis, splenectomy	Steroids, azathioprine	Asymptomatic on steroids
Hamilton et al, ⁵ 2011	78/F	Nonspecific	Multiple lung masses	c-ANCA (+) p-ANCA (–)	None	Steroids, cyclophosphamide	Asymptomatic on steroids
Tinazzi et al, ⁶ 2007	48/F	Epigastric pain	None	c-ANCA (–) p-ANCA (–)	Whipple	None	Full recovery
Marroun et al, ⁷ 2006	68/F	Painless jaundice	Sinusitis, orchitis	c-ANCA (–) p-ANCA (+)	Whipple	Steroids, cyclophosphamide	Asymptomatic on steroids
Christl et al, ⁸ 2004	50/F	Abdominal pain, weight loss	None	c-ANCA (+) p-ANCA (–)	Distal pancreatectomy	Steroids	Loss to follow up
O'Neil et al, ⁹ 1992	62/M	Painless jaundice	Lung mass	c-ANCA (+) p-ANCA (–)	None	Steroids, cyclophosphamide	Asymptomatic on steroids

c-ANCA, cytoplasmic antineutrophil cytoplasmic antibodies; p-ANCA, perinuclear anti-neutrophil cytoplasmic antibodies; GPA, granulomatosis with polyangiitis.

Previous presentation: This case was presented at the American College of Gastroenterology Annual Scientific Meeting; October 5–10, 2018; Philadelphia, Pennsylvania.

Informed consent was obtained for this case report.

Received May 1, 2019; Accepted September 23, 2019

REFERENCES

- Sheehan M, Latona C, Aranha G, Pickleman J. The increasing problem of unusual pancreatic tumors. *Arch Surg*. 2000;135(6):644–50.
- Frampas E, Morla O, Regenet N, Eugene T, Dupas B, Meurette G. A solid pancreatic mass: Tumour or inflammation? *Diagn Interv Imaging*. 2013;94(7-8):741–55.
- Kontis E, Papalexopoulou N, Zen Y, Prachalias AA. Isolated primary pancreatic Wegener's granulomatosis: Report of two cases. *JOP*. 2014;15(4):403–6.
- Valerieva Y, Golemanov B, Tzolova N, Mitova R. Pancreatic mass as an initial presentation of severe Wegener's granulomatosis. *Ann Gastroenterol*. 2013;26(3):267.
- Hamilton L, Gaffney K, Andreou A, Saada J. Delayed presentation of Wegener's granulomatosis with pancreatic involvement. *Int J Rheum Dis*. 2011;14(4):e54–5.
- Tinazzi I, Caramaschi P, Parisi A, Faccioli N, Capelli P, Biasi D. Pancreatic granulomatous necrotizing vasculitis: A case report and review of the literature. *Rheumatol Int*. 2007;27(10):989–91.
- Marroun I, Delevaux I, Andre M, et al. Pancreatic involvement in Wegener's granulomatosis: A rare and difficult diagnosis. *Rev Med Interne*. 2006;27(2):144–7. [French.]
- Christl SU, Borchard F, Keller R, Engemann R, Fischbach W. Pancreatic tail tumor as an unusual first manifestation of Wegener's disease. *Z Gastroenterologie*. 2004;42(6):513–6.
- O'Neil KM, Jones DM, Lawson JM. Wegener's granulomatosis masquerading as pancreatic carcinoma. *Dig Dis Sci*. 1992;37(5):702–4.
- Low G, Panu A, Millo N, Leen E. Multimodality imaging of neoplastic and nonneoplastic solid lesions of the pancreas. *Radiographics*. 2011;31(4):993–1015.
- Porta M, Fabregat X, Malats N, et al. Exocrine pancreatic cancer: Symptoms at presentation and their relation to tumour site and stage. *Clin Transl Oncol*. 2005;7(5):189–97.
- Scialpi M, Reginelli A, D'Andrea A, et al. Pancreatic tumors imaging: An update. *Int J Surg*. 2016;28:S142–55.
- Sivarman A, Muthukrishnan A, Senguttuvan NB, Suchak SA, Kannan U. Predictors of malignancy in pancreatic head mass: A prospective study. *Pan Afr Med J*. 2011;9(1):30.
- Peddu P, Quaglia A, Kane PA, Karani JB. Role of imaging in the management of pancreatic mass. *Crit Rev Oncol Hematol*. 2009;70(1):12–23.
- Pezzilli R, Broccoli PL, Melandri R, Vandelli A, Re G, Fontana G. Exocrine pancreatic involvement in Wegener's granulomatosis. A case report. *Ital J Gastroenterol*. 1991;23(5):258–60.
- Asbun HJ, Conlon K, Fernandez-Cruz L, et al. When to perform a pancreatoduodenectomy in the absence of positive histology? A consensus statement by the International study group of pancreatic surgery. *Surgery*. 2014;155(5):887–92.

Copyright: © 2019 The Author(s). Published by Wolters Kluwer Health, Inc. on behalf of The American College of Gastroenterology. This is an open-access article distributed under the terms of the Creative Commons Attribution-Non Commercial-No Derivatives License 4.0 (CCBY-NC-ND), where it is permissible to download and share the work provided it is properly cited. The work cannot be changed in any way or used commercially without permission from the journal.