

# Richter's Type Recurrent Indirect Inguinal Hernia, an Extremely Rare Occurrence: A Case Report

Agegnehu Bayeh <sup>1</sup>, Simachew Limenh<sup>2</sup>

<sup>1</sup>Department of Surgery, College of Medicine and Health Sciences, Bahir Dar University, Bahir Dar, Ethiopia; <sup>2</sup>Department of Midwifery, College of Medicine and Health Sciences, Bahir Dar University, Bahir Dar, Ethiopia

Correspondence: Agegnehu Bayeh, Tel +251 923486085, Email [agegnehuberie@gmail.com](mailto:agegnehuberie@gmail.com)

**Background:** Richter's type recurrent indirect inguinal hernia remains to be an extremely rare entity reported scarcely. It may present with grave complications in the absence of symptoms and signs of intestinal obstruction. The aim of this study is to report a rare case of Richter's hernia after a previously repaired indirect inguinal hernia.

**Case Presentation:** A 31-year-old male farmer came up with complaints of colicky abdominal pain and two episodes of vomiting. He had a previous right inguinal surgery. A physical examination revealed a full abdomen with right inguinal tenderness and oblique surgical scar. Abdominal ultrasound showed a bowel segment entrapped in the deep inguinal ring of the inguinal canal. Right inguinal exploration was done, and the finding was a gangrenous Richter's type recurrent indirect inguinal hernia. The patient was discharged and improved on the seventh post-operative day after resection and anastomosis.

**Discussion:** Richter's hernia is a rare form of hernia that occurs when the anti-mesenteric border of the bowel is partly trapped in a tight hernial ring. Its rarity, combined with the fact that it may present in the absence of typical symptoms and signs of intestinal obstruction and local physical findings, poses a diagnostic challenge which often end up with complications like gangrenous bowel at the time of diagnosis.

**Conclusion:** Richter's hernia can occur in an extremely rare form as Richter's type recurrent indirect inguinal hernia. A high degree of suspicion, an early referral and timely imaging on the provider's side may prevent mortality and morbidity.

**Keywords:** Richter's hernia, recurrent hernia, modified Bassini's repair, resection and anastomosis, case report

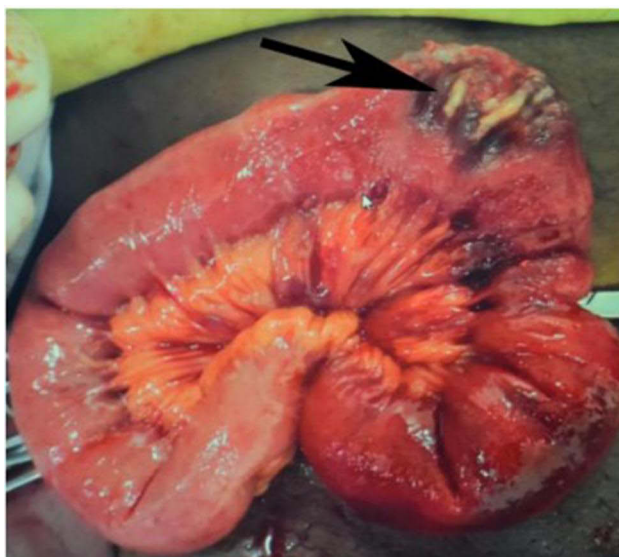
## Introduction

Richter's hernia is rarely encountered hernia.<sup>1-3</sup> Its occurrence as a recurrent indirect inguinal hernia is an extremely rare finding with conspicuously visible paucity in the report of such cases.<sup>4</sup> It is a difficult-to-diagnose hernia which may occur in the absence of symptoms and signs of intestinal obstruction.<sup>1</sup> This may lead to delayed diagnosis and complications like gangrenous bowel, perforation, and fistula formations.<sup>2,3,5,6</sup> We reported a case of Richter's hernia after a previously repaired indirect inguinal hernia (Richter's type recurrent indirect inguinal hernia) in a 31-year-old male complicated with gangrenous bowel. A high degree of suspicion and timely appropriate imaging investigations in the first encounter of such cases may prevent morbidity and mortality.

## Case Presentation

A 31-year-old male farmer visited a health center in his vicinity after a day of vague abdominal pain and one episode of vomiting. As it was understood from his referral paper, after clinical history, physical examination and stool examination, he was sent back home with oral analgesics and ciprofloxacin for the stool examination that showed many pus cells. On the second day as part of his attempt to get relief, he went to contact religious fathers for the holy or blessed water. On the third day of his complaint, he revisited the health center for no improvement. At this time, he was referred for a better workup.

During his evaluation at the hospital, he had a colicky abdominal pain, nausea and two episodes of vomiting. He had no fever, groin swelling, abdominal distension or trauma, or known chronic illnesses like diabetes mellitus and



**Figure 1** An intra-operative photograph showing a gangrenous Richter's type recurrent indirect inguinal hernia (black arrow), North-Western Ethiopia.

hypertension. He passed loose stools and reported to have a previous surgery at the age of 25 for a right groin protruding mass. A review of his clinical chart revealed that he had an elective repair of right indirect inguinal hernia six years back. The procedure done was modified Bassini's repair which is a tissue-based hernia repair with no application of mesh. The intra-operative findings at the time were omentum and a short loop of distal ileum in the sac. His three-day hospital stay and subsequent two post-operative follow-up visits were uneventful. Findings of the physical examination done at the emergency outpatient department were as follows: vital signs (PR = 116, Temperature = 37.8°C, RR = 24, and BP = 115/70 mmHg), full abdomen, old right inguinal oblique surgical scar and tenderness limited to the right inguinal region. No inguinal mass or skin changes.

Complete blood count showed a white blood cell count of 14,100 cells/ $\mu$ L and hemoglobin concentration of 12.7 g/dL. An erect plain abdominal x-ray was taken and read to show distended central bowel loops and rectal gas shadow with a final comment of partial small bowel obstruction. An abdominal ultrasound examination identified a fascial defect of 2.3 cm size as well as an entrapped bowel in the right inguinal region with no blood flow.

He was admitted to the emergency department, resuscitated with intravenous crystalloid fluids and counselled and prepared for right inguinal exploration. After securing an informed written consent, the right inguinal canal was explored under general anesthesia and the intra-operative finding was a gangrenous anti-mesenteric border of distal ileum trapped in the deep inguinal ring with an imminent rupture, a Richter's type of recurrent indirect inguinal hernia (Figure 1). The inguinal ring was laterally widened and the hernia sac opened. A loop of ileum containing the gangrenous part was pulled out, and resection of the gangrenous segment and end-to-end ileo-ileal hand sewn anastomosis and narrowing of the deep inguinal ring were done. After a thorough irrigation of the surgical wound with normal saline, the abdominal wall layers were approximated. A mesh repair was not attempted because it was a gangrenous bowel. He was given intravenous ceftriaxone and metronidazole for three days which was changed to oral ciprofloxacin and metronidazole for seven days. His post-operative course was smooth and uneventful. He was discharged after staying in the hospital for seven days. No complications were noticed during his subsequent post-operative follow-up visits at two weeks, a month, and two months after the date of discharge.

## Discussion

Richter's hernia is a rarely happening hernia that occurs as a result of the entrapment of part of the antimesenteric wall of a bowel in a tight hernial ring.<sup>1,7</sup> The first report of such type of hernia dates back to 1598 by Fabricius Hildanus. Later in 1778, August Gottlieb Richter provided its first scientific description. Sir Frederick Treves proposed the name "Richter's hernia" with his excellent overview of this rare hernia in 1887.<sup>1</sup>

Richter's hernia is commonly seen in the femoral ring.<sup>1</sup> However, it may occur in any sites of hernia like inguinal hernia, incisional, umbilical and Spigelian hernias.<sup>2,3,8-11</sup> With the era of laparoscopic procedures, reports of cases of port-site Richter's hernias have been increasing.<sup>12-15</sup>

The bowel segment commonly affected in Richter's hernia is the distal part of the small intestine.<sup>1</sup> However, other segments of the gastrointestinal tract may also be involved.<sup>4,8,9</sup> In the current case report, the distal ileum approximately 65 cm from the ileocecal junction was found to be entrapped in the deep inguinal ring of the right inguinal canal.

Cases may not have symptoms and signs of intestinal obstruction. This misleading presentation may lead to delayed diagnosis and grave complications like gangrenous bowel, perforation, and enterocutaneous fistula.<sup>1-3</sup> The absence of cardinal symptoms and signs of small intestinal obstruction in our case has contributed to the delayed diagnosis and gangrenous bowel.

Recurrences of inguinal hernia can occur after mesh or non-mesh hernia repairs.<sup>16,17</sup> Naveen et al showed a recurrence of inguinal hernia in 5.7% of cases after modified Bassi's repair.<sup>18</sup> However, the occurrence of Richter's type indirect inguinal hernia has been extremely rarely reported.<sup>4</sup> No mesh application in the previous surgery and early return to his strenuous farming activities, which was a week after the procedure, were two important risk factors for the recurrence of the hernia.

## Conclusion

Richter's hernia known for its rarity can occur as a recurrent indirect inguinal hernia. A high degree of suspicion of such extremely rare form of a rare hernia and an early referral and timely imaging investigations may prevent morbidity and mortality from this difficult-to-diagnose hernia.

## Ethical Approval

As our initial intention in our approach to the patient was to treat and due to the nature of a case report study, an ethical approval and consent to participate was not obtained.

## Consent for Publication

An informed written and signed consent for publication was obtained from the patient. In line with the Declaration of Helsinki, any information that could lead to the identification of the individual has been kept confidential.

## Acknowledgment

Our heartfelt gratitude goes to the patient for his willingness and contribution in the case report.

## Author Contributions

Both authors made a significant contribution to the work reported, whether that is in the conception, study design, execution, acquisition of data, analysis and interpretation, or in all these areas; to part in drafting, revising or critically reviewing the article; gave final approval of the version to be published; have agreed on the journal to which the article has been submitted; and agree to be accountable for all aspects of the work.

## Funding

All resources for this case report have been covered by the authors only.

## Disclosure

The authors declare that they have no conflicts of interest in relation to this work.

---

## References

1. Steinke W, Zellweger R. Richter's hernia and Sir Frederick Treves: an original clinical experience, review, and historical overview. *Ann Surg.* 2000;232(5):710-718. doi:10.1097/00000658-200011000-00014

2. Ahi KS, Moudgil A, Aggarwal K, Sharma C, Singh K. A rare case of spontaneous inguinal faecal fistula as a complication of incarcerated Richter's hernia with brief review of literature. *BMC Surg.* 2015;15:67. doi:10.1186/s12893-015-0055-8
3. Faridi SH, Siddiqui B, Khan MA, Anees A, Ali SA. Suprapubic fecal fistula due to Richter's Inguinal Hernia: a case report and review of literature. *Iran J Med Sci.* 2013;38(2):129–131.
4. Rao SD, Kanagavel M. Recurrent Inguinal Hernia as Richter's Hernia. *Surg Med Open Acc J.* 2019;3(1). doi:10.31031/SMOAJ.2019.03.000552
5. Hajong R, Khongwar D, Komut O, Naku N, Baru K. Spontaneous enterocutaneous fistula resulting from Richter's Hernia. *JCDR.* 2017;11(8): PD05–PD06. doi:10.7860/JCDR/2017/27789.10370
6. Weledji EP, Puepi MA, Chichom AM. A rare spontaneous enterocutaneous fistula. *JSCR.* 2014;11. doi:10.1093/jscr/rju121
7. Regelsberger-Alvarez CM, Pfeifer C. Richter Hernia. Updated 2021 Jul 25. In: *StatPearls [Internet]*. Treasure Island (FL):StatPearls Publishing; 2022. Available from <https://www.ncbi.nlm.nih.gov/books/NBK537227/>. Accessed July 5, 2022.
8. Katragadda K, DeStefano LM, Khan MF. A case of Richter hernia: a rare entity. *ACS Case Rev Surg.* 2019;2(3):5–7.
9. Schmuter G, Narula N, Mukherjee I. Rare presentation of incarcerated incisional Richter's Hernia of the cecum. *Cureus.* 2021;13(8):e16971. doi:10.7759/cureus.16971
10. Chen W, Liu L, Huang H, Jiang M, Zhang T. A case report of spontaneous umbilical enterocutaneous fistula resulting from an incarcerated Richter's hernia, with a brief literature review. *BMC Surg.* 2017;17:15. doi:10.1186/s12893-017-0216-z
11. Parambath AN, Hajaji K, Hilil SAA. Spigelian hernia with Richter-type herniation of the ileum: a rare cause of right iliac fossa pain mimicking acute appendicitis. *JEMTAC.* 2012;2012(1):7. doi:10.5339/jemtac.2012.7
12. Rammohan A, Naidu RM. Laparoscopic port site Richter's hernia – an important lesson learnt. *IJSCR.* 2011;2:9–11. doi:10.1016/j.ijscr.2010.11.002
13. Chorti A, AbuFarha S, Michalopoulos A, Papavramidis TS. Richter's hernia in a 5-mm trocar site. *SAGE Open Med Case Rep.* 2019;7:1–4. doi:10.1177/2050313X18823413
14. Tonouchi H, Ohmori Y, Kobayashi M, Kusunoki M. Trocar site Hernia. *Arch Surg.* 2004;139:1248–1256. doi:10.1001/archsurg.139.11.1248
15. Albaqami AM, Al-Salam HA, Alhagbani MA, et al. Laparoscopic port site Hernia: a rare etiology of intestinal obstruction. *Cureus.* 2021;13(11): e19681. doi:10.7759/cureus.19681
16. Lockhart K, Dunn D, Teo S, et al. Mesh versus non-mesh for inguinal and femoral hernia repair. *Cochrane Database Syst Rev.* 2018;9(9): CD011517. doi:10.1002/14651858.CD011517.pub2
17. Girón F, Hernandez JD, Linares JD, et al. Outcomes of 207 totally extraperitoneal hernia repairs using self-fixation mesh. *Sci Rep.* 2021;11:12507. doi:10.1038/s41598-021-92063-9
18. Naveen N, Srinath R, Comparative A. Study between Modified Bassini's Repair and Lichtenstein Mesh Repair (LMR) of Inguinal Hernias in Rural Population. *JCDR.* 2014;8(2):88–91. doi:10.7860/JCDR/2014/7431.4016

## Open Access Emergency Medicine

Dovepress

### Publish your work in this journal

The Open Access Emergency Medicine is an international, peer-reviewed, open access journal publishing original research, reports, editorials, reviews and commentaries on all aspects of emergency medicine. The manuscript management system is completely online and includes a very quick and fair peer-review system, which is all easy to use. Visit <http://www.dovepress.com/testimonials.php> to read real quotes from published authors.

Submit your manuscript here: <https://www.dovepress.com/open-access-emergency-medicine-journal>