

Management of a rare case of idiopathic multiple unerupted impacted permanent teeth in an adult female patient

Karunakar Shetty, Mahesh Kumar, Susan Amanna, Srirangarajan Sridharan¹, Satyanarayan Reddy²

Departments of Prosthodontics, ¹Periodontics and ²Conservative Dentistry and Endodontics, Bangalore Institute of Dental Sciences and Postgraduate Research Centre, Bengaluru, Karnataka, India

Abstract

This clinical case report describes the multi-disciplinary approach in the management of an unusual presentation of idiopathic multiple unerupted impacted permanent teeth in a 20-year-old female patient. The case was unique in that, not only were there multiple missing permanent teeth, but also over retained deciduous teeth and attrited existing permanent teeth with loss of vertical dimension of occlusion. Since the patient was young, it was decided to retain all the erupted permanent teeth and extract the infected deciduous teeth with the objective of fabricating overlay complete dentures. This is a simple, reversible and an economical treatment modality, which satisfies both the esthetic and functional demands where the extraction of teeth is not generally indicated and, in addition, provides a stable occlusion.

Key Words: Impacted teeth, over retained deciduous teeth, overlay complete dentures, unerupted teeth

Address for correspondence:

Dr. Karunakar Shetty, Department of Prosthodontics Bangalore Institute of Dental Sciences and Postgraduate Research Centre, Bengaluru, Karnataka, India.
E-mail: dr_karans@hotmail.com

Received: 10th June, 2014, **Accepted:** 28th April, 2015

INTRODUCTION

The eruption is the axial or occlusal movement of the tooth from its developmental position within the jaw to its functional position in the occlusal plane.^[1] The common and important reasons attributed to delayed eruption are usually an insufficient space, early loss of primary teeth with the eventual closure of space, crowding of arches and rotation of tooth buds. Excessive fibrous tissue over an erupting tooth is also one of the most common causes, with eruption cysts being relatively rare.^[1] Teeth that cease to erupt before emergence are known as impacted teeth.^[2] Complete lack of eruptive force can be the reason for unerupted tooth when the normal number of teeth

is present radiographically, although this is debatable, since few workers have debunked this claim^[3,4] syndromes, metabolic, and hormonal disorders are also other causes of multiple impacted permanent teeth. Finally, crowding and rotation of tooth buds can also lead to impacted teeth.^[5]

Impaction of teeth can result from a number of causes ranging from local infections to trauma to developmental anomalies including systemic disorders.^[6,7] Therefore, it is prudent to perform a thorough clinical examination and obtain adequate radiographs when teeth do not appear according to the usual eruption schedule.^[6]

The present clinical report describes the multi-disciplinary approach carried out in one such unusual presentation of multiple unerupted impacted permanent teeth along with overretained deciduous teeth in an adult female patient not associated with any syndrome or systemic disorder. The report mainly highlights the prosthodontic aspect of management in detail which involved fabrication of overlay complete dentures.

Access this article online	
Quick Response Code:	Website: www.j-ips.org
	DOI: 10.4103/0972-4052.161572

CLINICAL REPORT

A 20-year-old female patient was referred to the outpatient Department of Prosthodontics, Bangalore Institute of Dental Sciences, Bengaluru, Karnataka, India in June 2011 with the chief complaint of poor esthetics and difficulty in eating. History of systemic and embryological diseases, dysplastic syndromes and trauma in the facial region were consulted by the general physician. The patient was born to nonconsanguineous parents, and delivery and pregnancy history were noncontributory. Family history revealed that she was the second child of her parents, and her siblings did not have any physical or systemic abnormalities and had normal dentition.

On general examination, the patient was moderately built and adequately nourished and did not exhibit any physical or skeletal abnormality and showed no signs of mental retardation. On extra-oral examination, the patient had a straight profile, vertical growth pattern, and competent lips. Clinical examination revealed the presence of teeth as shown in Table I and Figure 1a and b. Deep folds in the commissures of the mouth were seen indicating loss of vertical dimension (VDO) of occlusion [Figure 1c]. Niswongers method was used to verify VDO of occlusion. The teeth appeared impacted, rotated, and crowded in the mandibular and maxillary anterior region and were not in the eruption path. Some impacted teeth in the mandibular anterior region were very close to the inferior border of the mandible. There were no cystic changes, and the jaw bones showed the normal trabecular pattern and density.

Table 1: Status of teeth

Dentition	Teeth erupted	Teeth unerupted	Teeth missing
Deciduous	51, 52, 53, 54, 55, 62, 63, 64, 65, 81, 82, 83, 84, 85, 71, 72, 73, 74, 75	None	None (61 exfoliated normally)
Permanent	16, 21, 26, 41, 46, 36	11, 13, 14, 15, 17, 22, 23, 24, 25, 27, 32, 33, 34, 35, 37, 42, 43, 44, 45, 47, 48	12, 31

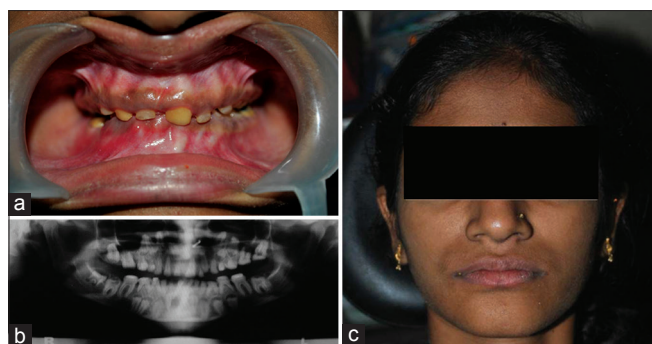

Figure 1: (a) Preoperative view, (b) Preoperative orthopantomogram, (c) Preoperative profile

Case management

Following evaluation of the clinical and radiographic findings, it was decided to extract the deciduous maxillary right lateral incisor and mandibular left central incisor as these teeth showed periapical infection around the roots and hence would not serve as favorable abutment teeth. As the patient was a young individual, preservation of all the remaining teeth was a priority and as finances were a concern for the family of the patient, a multi-disciplinary approach was proposed in collaboration and consultation with the specialties of oral surgery, orthodontics, endodontics and periodontics to fabricate an overlay complete denture over the remaining teeth.

At this point of time, it was also decided to leave the impacted unerupted teeth as they were. The patient was unwilling for any surgical intervention as deep impaction needs a lot of bone reduction for exposing teeth resulting in loss of ridge height with even more loss of VDO and compromised retention. Maxillary and mandibular preliminary impressions were made with irreversible hydrocolloid (Tropicalgin, Company Zhermack, Italy) using a perforated stock tray and primary diagnostic casts were prepared. As the VDO of occlusion was reduced, a soft splint with increased vertical height was given for a period of 30 days to raise the bite [Figure 2]. Initially, a hard splint was fabricated, which caused extreme discomfort to the patient, due to which it was decided to use a soft splint. As the VDO was increased over a period of 1-month, in the 1st week 2 mm splint was fabricated, 2nd week on the same splint an additional 1 mm bio star sheet was layered to increase the thickness and so on. By the end of 1-month the VDO was raised by 4 mm. The interocclusal distance was kept at 1.5 mm since the VDO was less and it was found to be suitable as far as phonetics was concerned. In addition, Silverman's closest speaking space was checked to verify speech and phonetics.

During this time, the four permanent first molars, maxillary and mandibular, were subjected to intentional root canal treatment

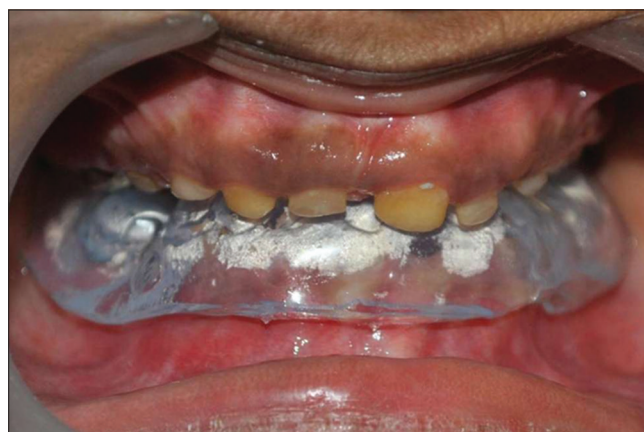

Figure 2: Soft splint to increase the vertical height

and crown lengthening as the retention would be compromised otherwise, since the existing crown length was around 1.5–2 mm overall and following preparation, the teeth length would be insufficient for retentive copings. Crown lengthening resulted in a 2 mm increase in length [Figure 3]. These copings were cemented with permanent luting cement [Figure 4] (Fuji I, company GC, America). Unavoidable undercuts in the remaining deciduous teeth were rounded off. Acrylic resin (DPI-RR Cold cure, Dental Products of India, Mumbai, Maharashtra, India) impression trays were fabricated. The tray was border molded with polyvinylsiloxane elastomeric impression material (Aqualil Soft Putty, Dentsply, Germany) and definitive impressions were made with polyvinylsiloxane elastomeric impression material (Aqualil light body consistency, Dentsply, Germany) [Figure 5] as the reproduction of details is finest with this material. Master casts were made with type III dental stone (Kalstone, Kalabhai Karson Pvt. Ltd., Mumbai, Maharashtra, India). Trial denture bases were fabricated with self-cure acrylic resin and occlusion rims were then fabricated over the trial denture base. Facebow transfer was made, and horizontal and vertical maxillomandibular relations were obtained with the record bases and the occlusion rims and the casts were secured to a Hanau articulator. Face bow transfer

was done to help orient the maxillary cast to the articulator. Mandibular cast was mounted in centric relation. Intraoral tracers were then attached to the maxillary and mandibular occlusal rims and centric and eccentric records were made following gothic arch tracing. Through these records, condylar guidances of 22.5° on the left condyle and 24° on the right condyle were adjusted. Incisal guidance of 12° was adjusted after placement of upper and lower anteriors.

Artificial teeth were selected and arranged in balanced occlusion on the record bases for a trial denture arrangement and were then evaluated intraorally for phonetics, esthetics, occlusal VDO and centric relation. Special care was taken to keep the labial maxillary rim without a flange. After the trial prosthesis was perfected, they were processed, subjected to laboratory remounting and selective grinding, finished, polished and delivered to the patient where clinical selective grinding was done [Figures 6 and 7]. Pressure points were determined using pressure indicating paste and were relieved. Following denture insertion, special instructions were given and the patient was scheduled for follow-up visits every month for the first 6 months and then every 3 months after that and she reported no complaints during the 2 years of follow-up [Figure 8].

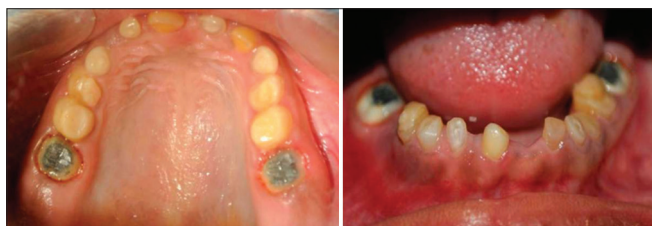

Figure 3: Endodontic treatment followed by crown lengthening (maxillary and mandibular first permanent molars)

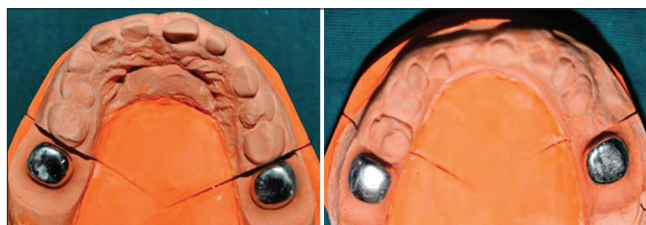


Figure 4: Metal copings on the maxillary and mandibular first permanent molars

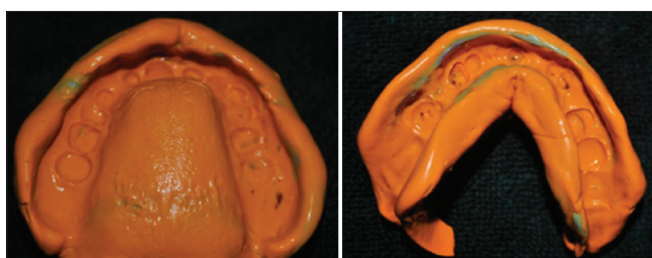


Figure 5: Definitive impressions made with polyvinyl siloxane elastomeric impression material

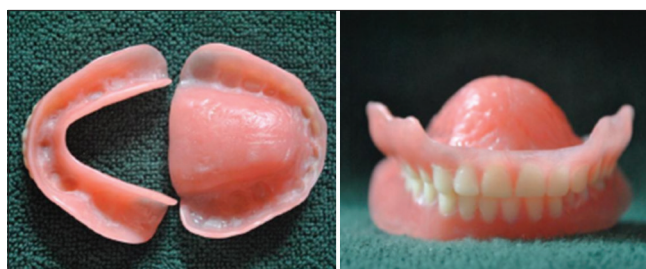

Figure 6: Finished and polished complete overdentures

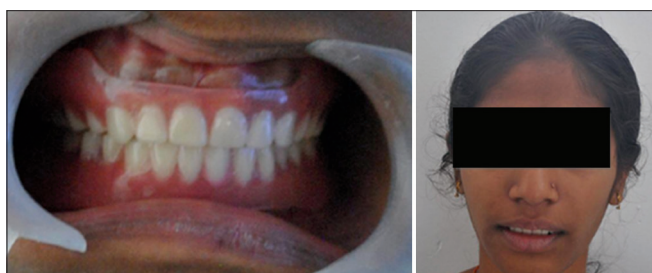

Figure 7: Insertion of complete overdentures

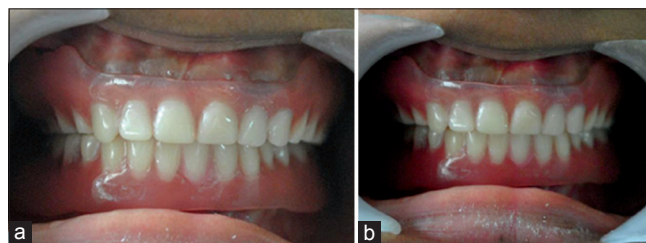


Figure 8: (a) Postinsertion follow-up (at 1-year), (b) Postinsertion follow-up (at 2 years)

DISCUSSION

Multiple impacted teeth with no obvious etiology are a rare dental anomaly. Few reports related to multiple impacted teeth with no known etiology exist in the literature.^[2,8-12] By the age of 7 years, primary maxillary central incisors should exfoliate and be replaced by permanent incisors. However, in the present case they were still present even at the age of 20 years. Likewise, over the retention of many other primary teeth was also found, which may be considered a consequence rather than a cause for failure of eruption. Since there is no eruptive mechanism; most of the primary teeth roots are not resorbed and are retained instead of undergoing exfoliation till the adolescent period. This may be one of the predictable causes for delayed exfoliation of primary teeth. Interdisciplinary management is essential in these cases for the optimal outcome to restore function and esthetics. A variety of treatment options are available to the dentist for oral rehabilitation of these patients. These include observation, surgical removal of hard and soft tissue obstructions, surgical uncovering and orthodontic repositioning^[9,13,14] with the advent of new designs in dental implants and their abutments; it is possible to consider replacing missing teeth with implant-borne prosthesis after extraction of the impacted teeth. Intervention by oral surgeons, periodontists, orthodontists and prosthodontists are also warranted, thus placing a significant emotional and financial burden on patients and their families.

In the present case, the patient belonged to the lower economic strata and was concerned primarily about her appearance because of which it was important to determine the cause of the problem, evaluate diagnostic data that included a temporomandibular disorder screening, and determine VDO of occlusion so that the patient could be categorized into one of the following categories: (1) Excessive wear with loss of VDO, (2) excessive wear without loss of VDO but with space available, or (3) excessive wear without loss of VDO but with limited space.^[15] Since the patient was in the category (1), overlay complete dentures were considered as a good alternative to the conventional removable dentures because they would provide better retention, stability, support, and stable occlusion. In addition, there would also be a decrease in the forward sliding of the prosthesis and better control of the mandibular movements because of the proprioceptive feedback which increases the chewing efficiency and even phonetics, as compared to the conventional complete dentures. The rate of the residual ridge resorption would also be decreased because of the transfer of compressive forces into the tensile forces by the periodontal ligament and better stress distribution.^[16] In addition, the absence of the labial flange in the maxillary overdenture was done to meet the esthetic requirements as the existing anterior teeth were retained. The labial flange would have compromised the lip support.^[17] This case report thus demonstrated that

overlay complete dentures were a reversible, relatively inexpensive method for the management of this case with idiopathic multiple unerupted permanent teeth and overretained deciduous teeth with loss of VDO. The treatment improved her esthetics, oral function and established a more favorable plane of occlusion and her confidence improved tremendously.

Declaration of patient consent

The authors certify that they have obtained all appropriate patient consent forms. In the form the patient(s) has/have given his/her/their consent for his/her/their images and other clinical information to be reported in the journal. The patients understand that their names and initials will not be published and due efforts will be made to conceal their identity, but anonymity cannot be guaranteed.

REFERENCES

1. Kumar GS. Orban's Oral Histology and Embryology. 12th ed. India: Mosby; 2009.
2. Sujatha G, Sivapathasundharam B, Sivakumar G, Nalinkumar S, Ramasamy M, Prasad TS. Idiopathic multiple impacted unerupted teeth: Case report and discussion. *J Oral Maxillofac Pathol* 2012;16:125-7.
3. Wood NK, Goaz PW. Differential Diagnosis of Oral and Maxillofacial Lesions. 5th ed. St. Louis: Mosby; 2007.
4. Wise GE, Frazier-Bowers S, D'Souza RN. Cellular, molecular, and genetic determinants of tooth eruption. *Crit Rev Oral Biol Med* 2002;13:323-34.
5. Yildirim D, Yilmaz HH, Aydin U. Multiple impacted permanent and deciduous teeth. *Dentomaxillofac Radiol* 2004;33:133-5.
6. Alling CC 3rd, Catone GA. Management of impacted teeth. *J Oral Maxillofac Surg* 1993;51:3-6.
7. Gorlin RJ, Cohen MM, Hennekam RC. Syndromes of the Head and Neck. 4th ed. US: Oxford University Press; 2001.
8. Babu V, Nagesh KS, Diwakar NR. A rare case of hereditary multiple impacted normal and supernumerary teeth. *J Clin Pediatr Dent* 1998;23:59-61.
9. Frank CA. Treatment options for impacted teeth. *J Am Dent Assoc* 2000;131:623-32.
10. Nadine AM. Case of new unerupted and impacted teeth in a man 21 years of age. *Dent Cosm* 1935;77:304-6.
11. Sivakumar A, Valiathan A, Gandhi S, Mohandas AA. Idiopathic failure of eruption of multiple permanent teeth: Report of 2 adults with a highlight on molecular biology. *Am J Orthod Dentofacial Orthop* 2007;132:687-92.
12. Yalcin S, Gurbuzer B. Multiple impacted teeth in the maxilla. *Oral Surg Oral Med Oral Pathol* 1993;76:130.
13. Kokich VG, Mathews DP. Surgical and orthodontic management of impacted teeth. *Dent Clin North Am* 1993;37:181-204.
14. Ohman I, Ohman A. The eruption tendency and changes of direction of impacted teeth following surgical exposure. *Oral Surg Oral Med Oral Pathol* 1980;49:383-9.
15. Rivera-Morales WC, Mohl ND. Restoration of the vertical dimension of occlusion in the severely worn dentition. *Dent Clin North Am* 1992;36:651-64.
16. Academy of Prosthodontics. Glossary of prosthodontic terms. *J Prosthet Dent* 2005;94:10-92.
17. Olvera N, Jones JD. Alternatives to traditional complete dentures. *Dent Clin North Am* 2014;58:91-102.

How to cite this article: Shetty K, Kumar M, Amanna S, Sridharan S, Reddy S. Management of a rare case of idiopathic multiple unerupted impacted permanent teeth in an adult female patient. *J Indian Prosthodont Soc* 2016;16:303-6.

Source of Support: Nil, **Conflict of Interest:** None.